

implants

international magazine of oral implantology



case report


Type 4 implant placement

interview

Periodontitis and peri-implantitis
in implant dentistry

events

Education across borders



KS system

BA SURFACE

*Strong!
Simple!
Easy!*

OSSTEM[®]
IMPLANT

AFI Avenir Park, Radlická 740/113c, 158 00, Prague 5, Czechia
T: +420 296 238 802 www.osstem.eu

Dr Georg Bach

President of the DGZI



Same procedure as **every** year?

Dear colleagues, when writing the editorial for this first issue of our **implants—international magazine of oral implantology**, the British cabaret sketch *Dinner for One* came to mind. Each time the legendary butler James asks the question “The same procedure as last year?”, he is answered with the catchphrase “The same procedure as every year, James!” by the lady of the house. Indeed, the situation in which we now find ourselves at the beginning of 2022 is reminiscent of exactly one year ago. In view of the agonising uncertainty, I too have the fear that it could be the same again at the beginning of 2023—the same procedure as...—because the fact is that the pandemic will not let us out of its clutches.

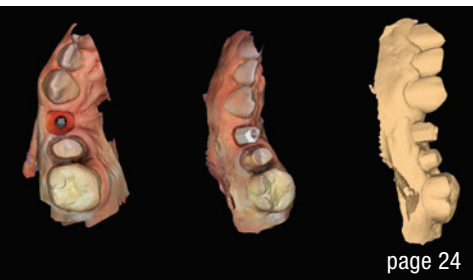
But what has happened in this past year, from editorial to editorial? The pandemic has changed our everyday lives and that of our practices for yet another year; it has thoroughly shaken things up again. But fortunately, there have also been beautiful moments, like the German Association of Dental Implantology's (DGZI's) grandiose birthday congress in Cologne last autumn, when the DGZI family celebrated the 50 plus one anniversary with many friends.

Do we have cause for resignation? There might be plenty of reasons, but resignation does not befit the spirit of our profession. Dentists are creators, and this should and will remain so. Let us—despite the adverse conditions—approach the new year positively and with vigour. The realisation that we are allowed to practise one of the most beautiful professions of all and the joy of our special discipline, dental implantology, allow us to generously overlook a thing or two.

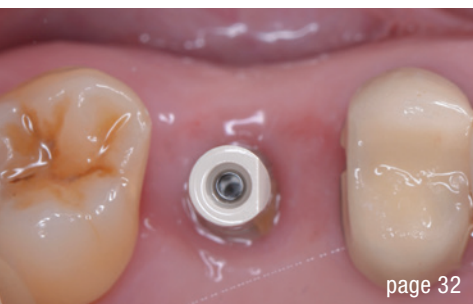Let us look forward to an exciting year and to many personal interactions with the members of our large and international DGZI family! I wish you well in your private and professional lives, success, much joy and, above all, the best of health.

Warm and collegial greetings,

Dr Georg Bach



page 24



page 32



page 44

Cover image courtesy of
bredent medical GmbH & Co. KG /
www.bredent-implants.com



editorial

- Same procedure as **every** year? 03
Dr Georg Bach

case report

- Radicular** transplantation 06
Dr Renaud Girieud

- Partial **extraction therapy** and implant treatment in the maxilla 12
Dr Snježana Pohl, Dr Mijo Golemac, Dr Daniela Grgić Miljanić,
Dr Pantelis Petrakakis & Prof. Jelena Tomac

- Resolving** severe bone **atrophy** 18
Dr Roberto Rossi, Dr Giovanni Franzone & Stefano Giuliani

- Type 4 implant placement** with custom healing abutment 24
Dr Pál Nagy

- Maxillary **molar replacement** with an implant and **immediate** restoration 32
Dr Leandro Soeiro Nunes

interview

- Periodontitis and **peri-implantitis** in implant dentistry 36
An interview with Dr Inga Boehncke

- Laser** protocol for **peri-implantitis** treatment 38
An interview with Dr Michał Nawrocki

news

- manufacturer news 40

- news 48

industry

- Osstem Europe: **New European headquarters** in Prague 43
Henrik Eichler

events

- Education across **borders** 44
Janine Conzato

about the publisher

- imprint 50

NovoMatrix™ Reconstructive Tissue Matrix – the next generation material

NovoMatrix™ Reconstructive Tissue Matrix is an acellular dermal matrix derived from porcine tissue intended for soft tissue applications. The proprietary LifeCell™ tissue processing is designed to maintain the biomechanical integrity of the tissue, which is critical to support tissue regeneration.

Indications

- Localized gingival augmentation to increase keratinized tissue (KT) around teeth and implants
- Alveolar ridge reconstruction for prosthetic treatment
- Guided tissue regeneration procedures in recession defects for root coverage

Product features

- Consistent thickness (1 mm)
- Pre-hydrated
- Controlled source

www.biohorizonscamlog.com

Before use, physicians should review all risk information, which can be found in the Instructions for Use attached to the packaging of each NovoMatrix™ Reconstructive Tissue Matrix graft. NovoMatrix™ is a trademark of LifeCell™ Corporation, an Allergan affiliate. ©BioHorizons. All rights reserved. Not all products are available in all countries.



Bone tissue augmentation

MinerOss™ A The allograft for outstandingly fast bone remodeling [1]

The scientific evidence shows that allografts are the second best option to patient's own bone compared to other bone substitutes. [2]

Benefits of MinerOss™ A human bone substitute [1, 3–5]

- Optimal osteoconductivity
- Fast graft incorporation
- Complete remodeling potential

www.biohorizonscamlog.com



- [1] Wen et al. J. Periodont. 2019, 1, 734.
[2] Schmitt et al. Clin Oral Implants Res. 2013, 24, 576.
[3] Kloss et al. Clin Oral Implants Res. 2018, 29, 1163.
[4] Solakoglu et al. Clin Implant Dent Relat Res. 2019, 21, 1002-1016.
[5] Kloss et al. Clin Case Rep. 2020, 8, 5.
References available at: www.biohorizonscamlog.com/references_minerossa

MinerOss™ A is a trademark of BioHorizons®. BioHorizons® is a registered trademark of BioHorizons. ©BioHorizons. All rights reserved. Not all products are available in all countries.



Radicular transplantation

The use of dental roots in the treatment of bone insufficiency

Dr Renaud Girieud, France

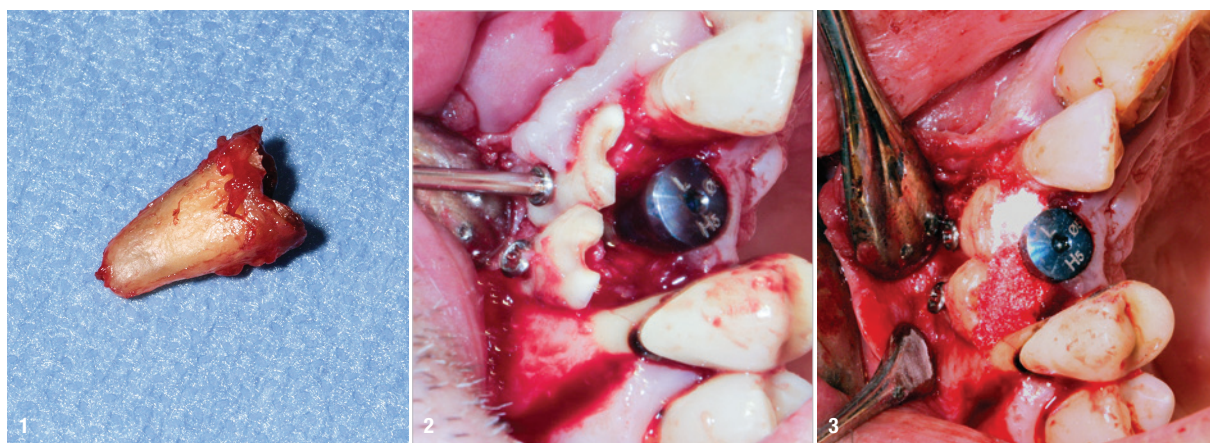


Fig. 1: Extracted root for radicular graft. **Fig. 2:** Radicular grafts are polarised. **Fig. 3:** Space between the graft and ridge filled with a filling material.

Treating bone insufficiency is a familiar challenge for all implant practitioners. Such insufficiency can compromise the placement of an implant, its long-term viability and even the anticipated aesthetic outcome. In summary, where there is a bone defect, there are two broad treatment types available to us. Firstly, there is guided bone regeneration. This combines a membrane and a biomaterial, of which there are several variants, depending on the type of membrane and the materials used.¹ Secondly, we can use autogenous bone in block or chip form as an onlay or supporting structure, according to the technique developed by Prof. Fouad Khoury.²

Depending on the skill and experience of the surgeon, these various techniques can necessitate several operations, and it can be months before an implant can be placed into the arch.

However, there is a third way to treat bone insufficiency, based on the principle of ankylosis and root resorption, by block grafting the roots of the patient's own teeth. We will use the term "radicular graft" to refer to the root fragments used. This technique was originally described by the team working with Prof. Frank Schwartz, who proposed the grafting of dental roots in pre-implant

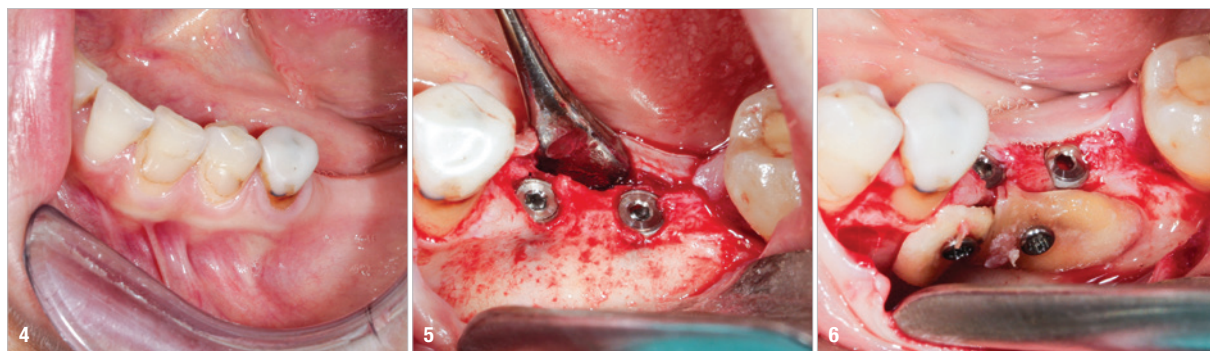

Fig. 4: Serious risk of dehiscence. **Fig. 5:** Low residual bone thickness in the vestibular area of the implants. **Fig. 6:** The roots were shaped to fit the defect and fixated at the insertion site using osteosynthesis screws.

*Long?
Short?
Ultrashort?*

The new copaSKY!

Innovative hybrid connection –
adequate space for soft tissue,
can be positioned subcrestally.



Open for next

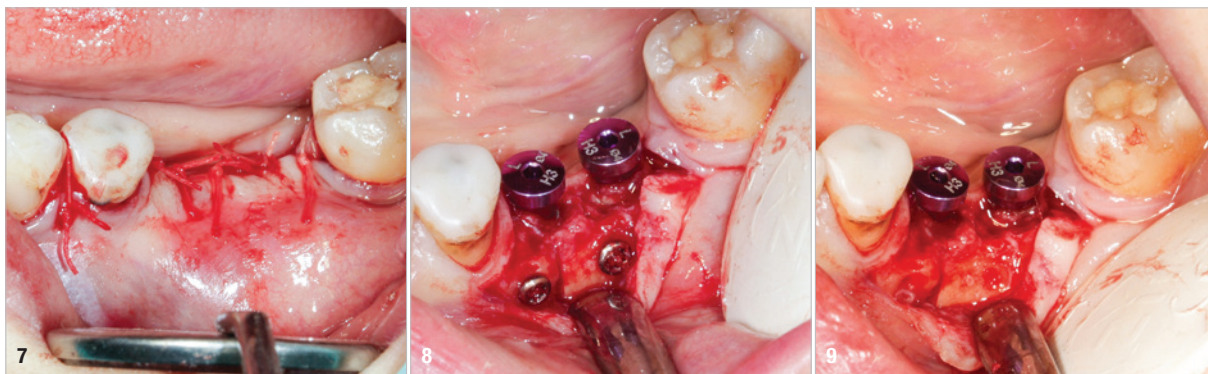

Fig. 7: A #4/0 rapidly resorbed braided thread was used for the sutures. **Fig. 8:** Healing abutments were connected to the implants. **Fig. 9:** The osteosynthesis screws were removed.

surgery in 2016.³ Through three clinical cases, we will discuss the scope of application for radicular grafts as we use them in our daily work in the dental surgery and how this has changed in comparison with the technique described by the team working with Prof. Schwartz.³ Our aim is to improve our patient's surgical experience and, whenever possible, to achieve bone augmentation and implant placement concomitantly. We have deliberately restricted our application to transverse bone insufficiency.

Materials and method

First, the root must be extracted; this will be the future radicular graft (Fig. 1). This is then prepared by polishing it gently to clean it and remove calculus deposits. The coronal section and any soft or decayed parts are removed.³ The root is cut into two using a disc. A diamond drill is used to clean the canals, and any debris from fillings is removed.³ If necessary, the root is cut again to shape it to match the defect, and holes are drilled into it for the osteosynthesis screws.³ The graft is fixated at the insertion site using osteosynthesis screws with the dentine in contact with the bone ridge and the cementum in contact with the soft tissue.³ Radicular grafts are actually polarised: the dentine must be in contact with the bone ridge to allow ankylosis, while the cementum, in contact with the soft tissue, acts as a barrier to prevent graft resorption by the soft tissue (Fig. 2). If the graft is being

used as a biological membrane and is intended to form a supporting structure, the space between the graft and the ridge is filled with a filling material (Fig. 3).

Case 1

A 36-year-old patient with teeth #36 and 37 missing and transverse bone insufficiency in the existing gap was treated. It would have been possible to place implants, but this would have left only a thin layer of vestibular bone at the neck of the implants. There was a serious risk of dehiscence, which can compromise the survival of the implant in the arch (Fig. 4).

We had three alternative courses of action: a bone block graft from the mandibular ramus,² a segmental osteotomy⁴ or a radicular graft, knowing that tooth #46 could not be saved. We chose the third option because it allowed for simultaneous implant placement and bone reconstruction. A large flap was elevated to assess the gap in the bone and in anticipation of closing the flap on an augmented ridge. Two implants were placed as normal despite the low residual bone thickness in the vestibular area of the planned positions for the implants (Fig. 5). The roots of tooth #46 were extracted atraumatically (root separation, use of piezo-surgery, etc.) and were then prepared as described. The roots were shaped to fit the defect and fixated at the insertion site using osteosynthesis screws (Fig. 6).³ The flap was mobilised and stretched

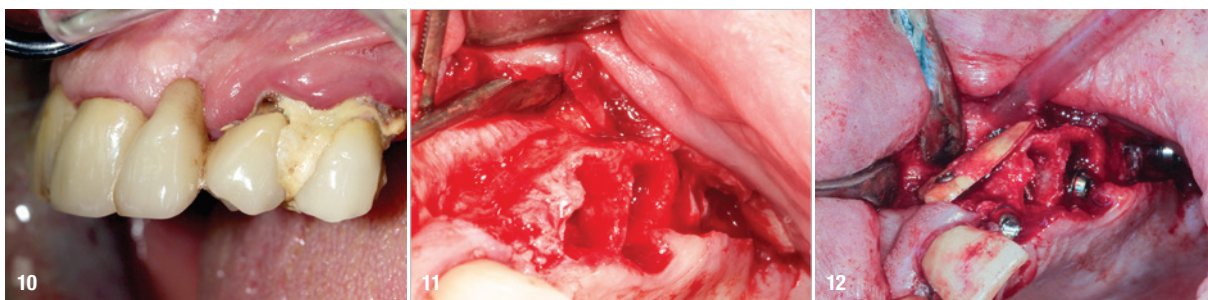
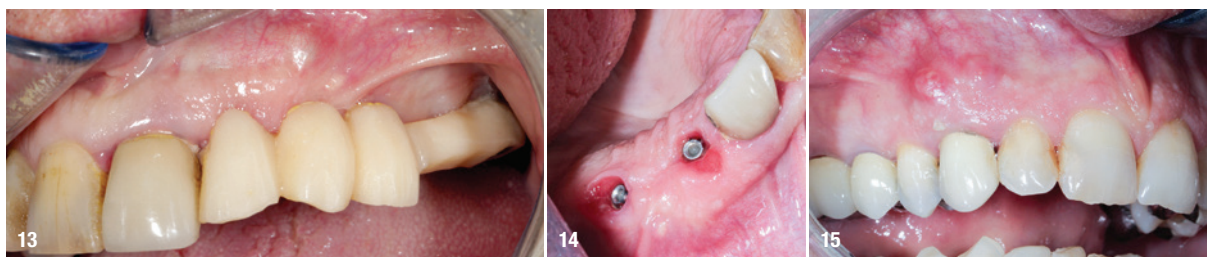


Fig. 10: Transverse bone insufficiency on the ridge of tooth #22. **Fig. 11:** Full-thickness flap elevation and extraction of teeth #23 and 24. **Fig. 12:** Edges of the radicular graft in contact with the alveolar bone.



Figs. 13 & 14: The osteosynthesis screws were not removed because they were not visible under the gingiva. **Fig. 15:** Radicular fracture at tooth #13 under a crown and with a fistula opposite.

to achieve edge-to-edge closure without tension, and a #4/0 rapidly resorbed braided thread was used for the sutures (Fig. 7). Four months after the bone augmentation and implant placement, healing abutments were connected to the implants and the osteosynthesis screws removed (Figs. 8 & 9). During the operation, time was taken to perform a visual check that ankylosis of the radicular grafts had been successful and that these were sound. Finally, a CBCT assessment was performed. The prosthesis was fitted by our colleague a few weeks later, once the soft tissue had healed.

Case 2

A 62-year-old patient with a bridge from tooth #21 to tooth #27 requiring replacement, teeth #21, 23, 24 and 27 with abutments and the crown of #22, 25 and 26 missing, was treated. The ridge of tooth #22 exhibited a transverse bone insufficiency which would have allowed the placement of an implant, but the aesthetic outcome would have been unsatisfactory (Fig. 10). First, the bridge of tooth #24 was sectioned distally and the root of tooth #27 extracted. After a two-month healing period, the patient was treated with simultaneous extraction, implantation and aesthetic restoration. The bridge was sectioned distally at tooth #21, a full-thickness flap was elevated and the teeth #23 and 24 were extracted, allowing the bone defect at tooth #22 to be assessed (Fig. 11). Implants were placed into sites #22, 24 and 27. The root of tooth #23 allowed us to compensate for the bone defect and achieve a satisfactory aesthetic result. The root was prepared as described. The radicular graft was fixated away

from the ridge, the edges of the graft in contact with the alveolar bone (Fig. 12). The spaces between the ridge, the graft and the alveoli were filled with a synthetic, hydroxyapatite-based biomaterial, the flap was stretched and sutured around the healing abutments, an impression was taken, and a temporary prosthesis from implant #22 to 27 was made during the day by the laboratory and fitted the same evening. The stitches were removed on the tenth day and the bridge after two months to check for the successful osseointegration of the implants. The osteosynthesis screws were not removed in this case because they were not visible under the gingiva (Figs. 13 & 14). A CBCT assessment was performed after six months to check that the graft had taken successfully. Finally, our colleague fitted the definitive prosthesis.

Case 3

A 55-year-old patient with a radicular fracture at tooth #13 under a crown and a fistula opposite was treated (Fig. 15). The plan was to treat this patient with simultaneous extraction, implantation and aesthetic restoration. Unfortunately, as sometimes happens and despite the precautions taken, a large part of the vestibular wall of the alveolus was extracted with the root, creating a significant bone defect. A full-thickness flap was elevated and the implant placed. The root was prepared and fixated with an osteosynthesis screw to replace the lost wall (Fig. 16). The space between the root and the implant was filled with a hydroxyapatite-based biomaterial (Fig. 17). This bone reconstruction was combined with a connective graft. The flap was stretched and sutured with a

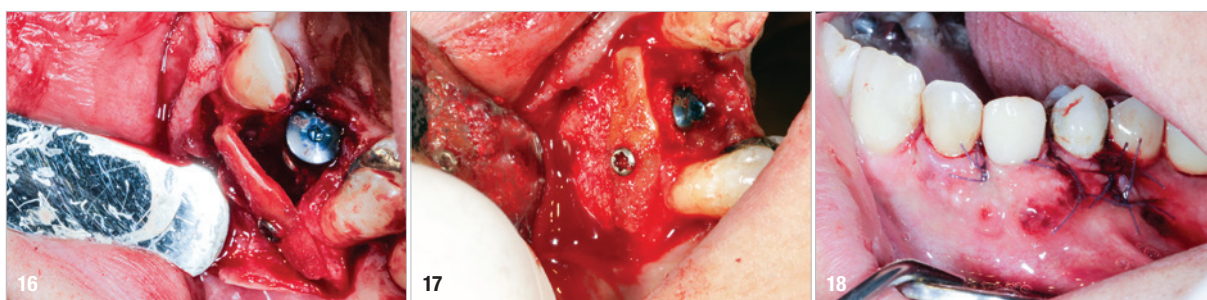

Fig. 16: Preparation of the root and fixation with an osteosynthesis screw to replace the lost wall. **Fig. 17:** The space between the root and the implant was filled with a hydroxyapatite-based biomaterial. **Fig. 18:** A #5/0 resorbable braided thread was used for the sutures.