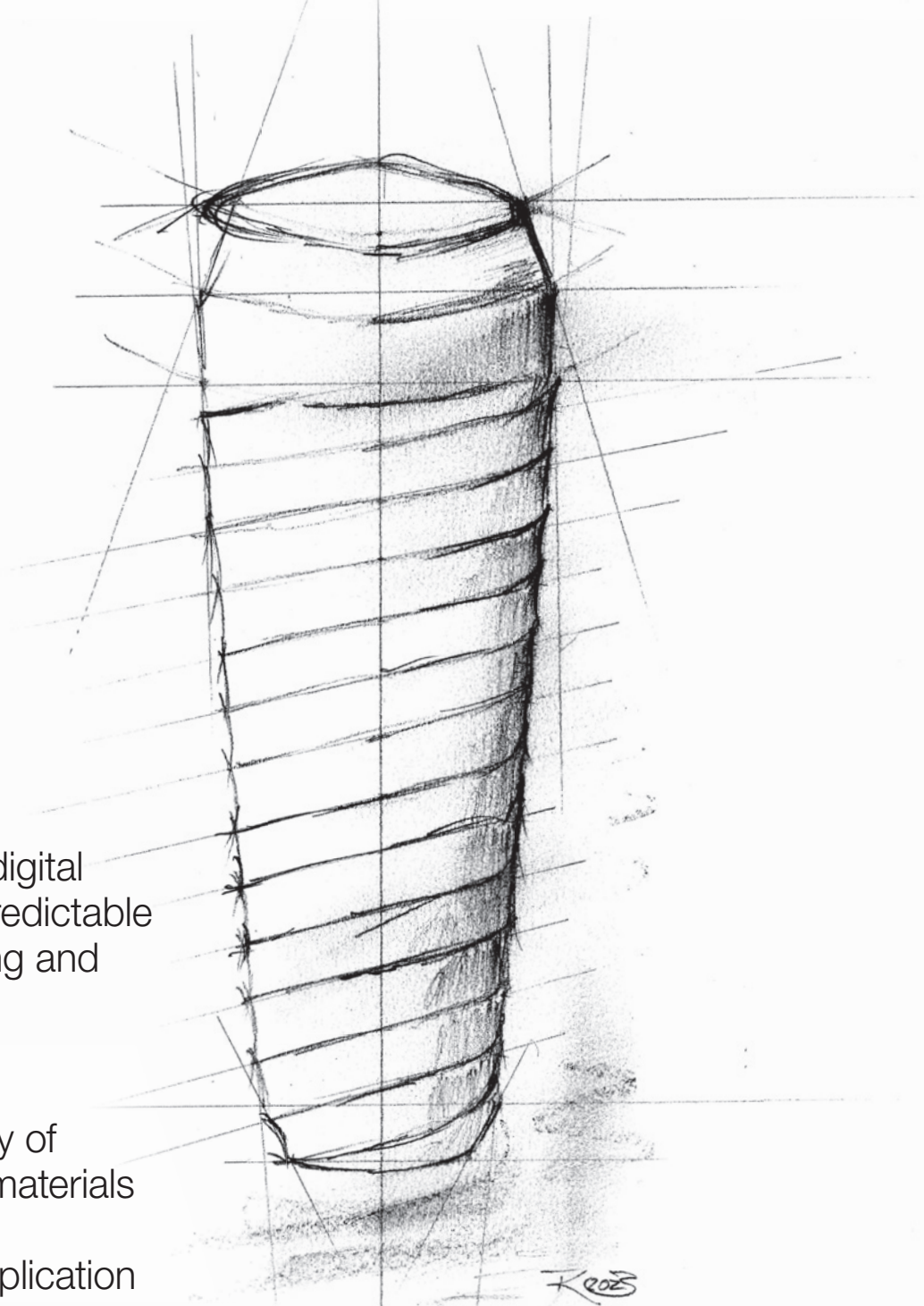


implants

international magazine of oral implantology



case report

A fully guided digital workflow for predictable implant planning and placement

research

Biocompatibility of CAD/CAM biomaterials for bone tissue engineering application

industry

Revolutionising implant dentistry

ITI
World
Symposium
Singapore
May 9 – 11
2024



Every patient has a story

Evidence meets patient perspectives to guide clinical care



LEARN MORE!

[www.iti.org/
worldsymposium](http://www.iti.org/worldsymposium)

3 days packed with lectures, cases, clinical procedures and discussions
50+ international experts live on stage | 5 main sessions with 9 real patient stories

Dr Georg Bach

President of the DGZI



A great congress in Hamburg

Dear colleagues and friends,

We are looking back on a fantastic DGZI annual congress!

Once again, the venerable Hanseatic city of Hamburg proved to be a good venue for the DGZI—a significantly increased number of participants, a consistently excellent atmosphere that ran like a golden thread through the two content-packed days and an extremely interesting programme—all of which is very pleasing! The oldest European implantology society will have very fond memories of Hamburg and would like to thank everyone involved—it really has been a pleasure.

My own highlight was our many foreign guests and partners, that we were finally able to welcome back to our annual congress after the coronavirus pandemic.

I will remember for a long time the cheerful discussions with the large Japanese delegation on the eve of the congress. In addition to the enhanced travel opportunities for the representatives of our foreign partners, we were also able to get the expert exams back on track in Hamburg and award our young colleagues the much-desired qualification “made in Germany”.

Another high point was the presentation of the Implant Dentistry Award. The outstanding papers submitted in advance by young female scientists were so impressive that the award ceremony was “spoilt for choice”. Congratulations to the two award winners once again!

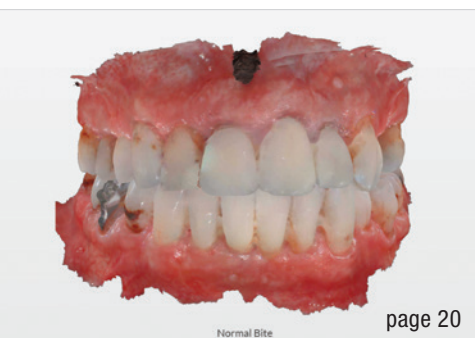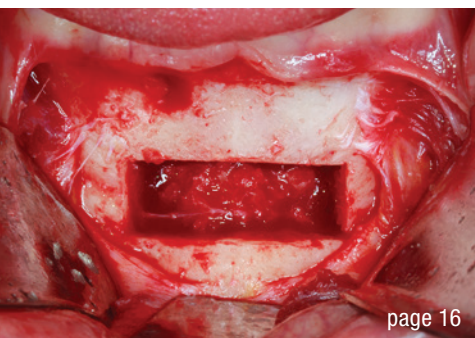
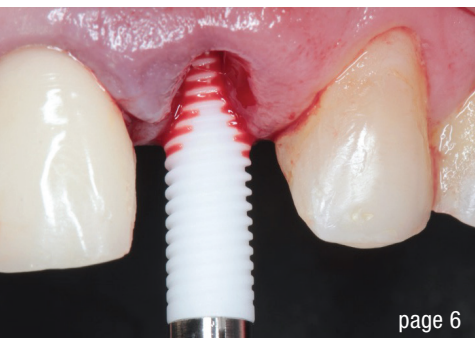So you see, I came back from Hamburg with a whole package of positive emotions and I’m certainly not the only one! And as we all know, the next congress is just around the corner—next year we’ll be moving to the Rhineland, where the big DGZI family will be meeting in Düsseldorf.

Enjoy reading the *implants* magazine!

Yours,

Dr Georg Bach

President of the German Association of Dental Implantology



editorial

A great congress in Hamburg

Dr Georg Bach

03

case report

Immediate placement and loading of ceramic implants in the aesthetic region: One-year follow-up—two case reports

Drs Alexandre Marques Paes da Silva, Dennis de Carvalho Ferreira, Thamires Alves Silva, Mayla Kezy Silva Teixeira, Daniel de Moraes Telles & Eduardo José Veras Lourenço

06

Extreme maxillary bone reconstruction with CERASORB Bioactive—a case report

Drs Fernando Duarte & Carina Ramos

16

A fully guided digital workflow for predictable implant planning and placement

Dr Beat R. Kurt

20

research

Biocompatibility of CAD/CAM biomaterials for bone tissue engineering application

Dr Katharina Pippich, Dr Katharina Hast, Adem Aksu, Stefanie Grom, Dr Tobias Wolfram, Frank Reinauer, Dr Dr Andreas Fichter, Dr Dr Achim von Bomhard

24

industry

Revolutionising implant dentistry

34

events

Implantology as a teamwork—Implantology is a **teamwork!**

Dr Georg Bach

36

news

manufacturer news

41

about the publisher

imprint

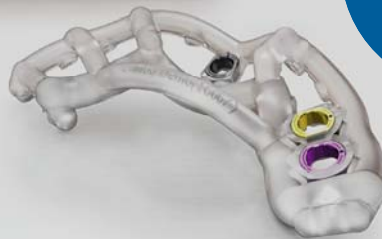42

Cover image courtesy of
TK @ www.oemus.com



TRULY CONICAL PRECISION

CONELOG[®]
SYSTEM



Fully
guided!

CONELOG[®] PROGRESSIVE-LINE conical performance^{1,2} at bone level

Precise conical connection

- long conus for reduced micromovements
- superior positional stability in comparison to other conical systems^{1,2}
- easy positioning with excellent tactile feedback
- integrated platform switching supporting the preservation of crestal bone

[1] Semper-Hogg, W, Kraft, S, Stiller, S et al. Analytical and experimental position stability of the abutment in different dental implant systems with a conical implant-abutment connection Clin Oral Invest (2013) 17: 1017
[2] Semper Hogg W, Zulauf K, Mehrhof J, Nelson K. The influence of torque tightening on the position stability of the abutment in conical implant-abutment connections. Int J Prosthodont 2015;28:538-41



VISIT OUR
WEBSITE!

 **biohorizons**
camlog

Immediate placement and loading of ceramic implants in the aesthetic region: One-year follow-up—two case reports

Drs Alexandre Marques Paes da Silva, Dennis de Carvalho Ferreira, Thamires Alves Silva, Mayla Kezy Silva Teixeira, Daniel de Moraes Telles & Eduardo José Veras Lourenço, Brazil

In the late 1990s, yttria-stabilised zirconia (Y-TZP) emerged as a versatile and promising material with wide applicability in implant dentistry. Among the advantages of this material, its white colour and opacity stand out, these properties allowing it to mimic the appearance of natural teeth. Owing to its mechanical properties, mainly the ability to withstand high masticatory loads, zirconia has been used not only for creating restorations but also for the manufacture of ceramic implants.¹

Y-TZP implants, in addition to being resistant and aesthetic, are highly biocompatible implants, have low affinity for bacterial plaque, are capable of stimulating osteogenic cells during the osseointegration process and boast corrosion resistance and radiopacity.² These characteristics have made these ceramic implants a possible substitute for titanium implants in oral rehabilitation, achieving predictable and reliable results.³ The aim of the

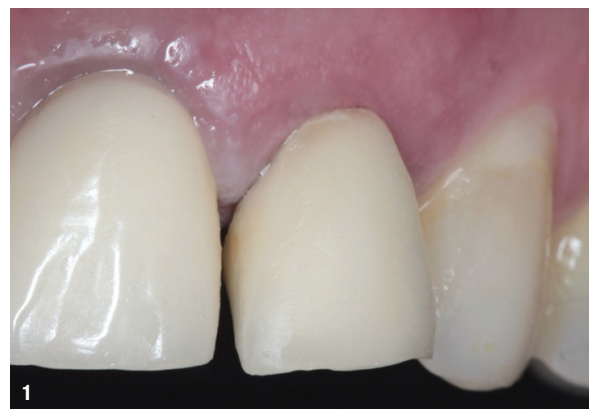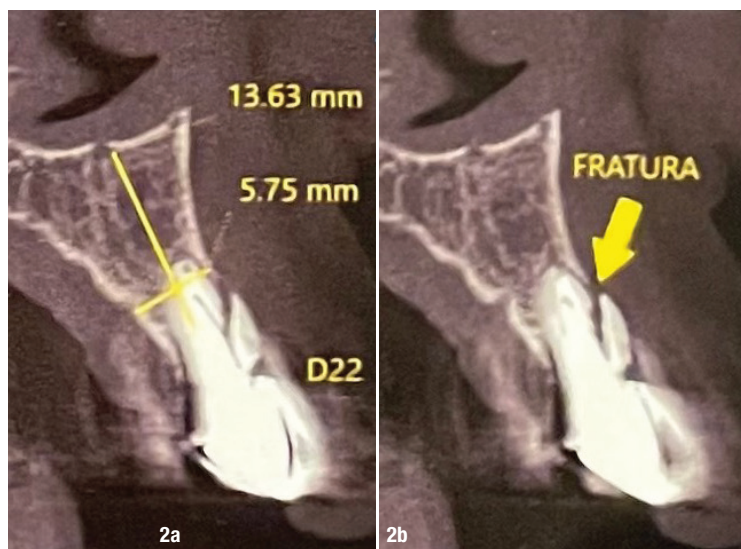


Fig. 1: Situation on initial clinical examination.

present study is to report two clinical cases of ceramic implantation in the aesthetic region using a surgical and prosthetic approach free of metal.

Case reports

The patients were referred to one private clinical centre in Rio de Janeiro in Brazil with the need for extraction and immediate placement and loading of single implants in the aesthetic region. In order to carry out the correct planning and diagnosis, the patients were asked to undergo a CBCT scan, a periapical radiograph and intra-oral photographs. The patients were non-smokers and were in good general health, without any systemic condition. Although the patients had good plaque control, they underwent supragingival scaling and root planning. This study was submitted to the ethics committee of the Universidade do Estado do Rio de Janeiro and approved (No. 5.598.463). The patients were previously invited to participate in and informed about the study and signed informed consent to participate, and all ethical aspects were followed.



Figs. 2a & b: CBCT image showing the vertical root fracture.



Simplify workflows and expand your practice

Expand your treatment offerings

DEXIS™ IOS Solutions seamlessly integrates into your dental workflow, helping you to simplify processes, increase productivity, and facilitate practice expansion. Say hello to more time for what really matters — your patients.

Find out more at dexis.com

© 2023 Dental Imaging Technologies Corporation. All rights reserved; DXIS00275 /RevA



NEW DEXIS IS 3800



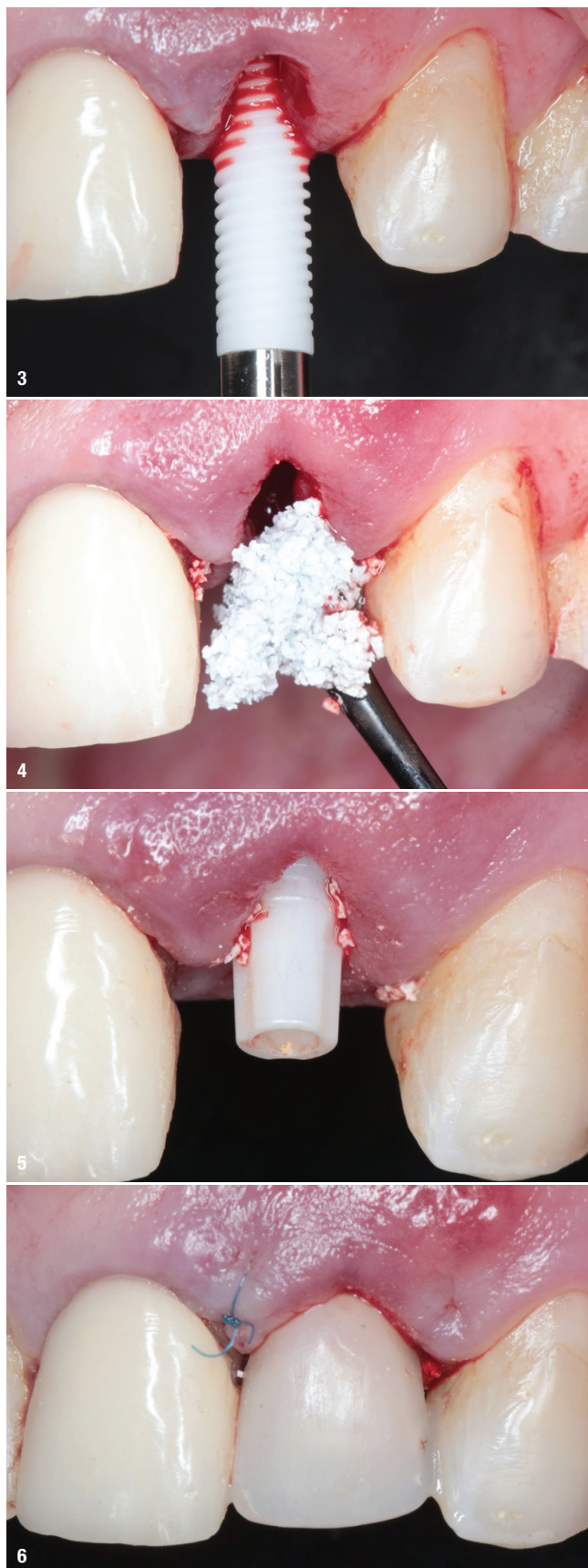


Fig. 3: Placement of the Zi implant. **Fig. 4:** Filling of the gap with bone grafting material. **Fig. 5:** Cemented zirconia abutment. **Fig. 6:** Immediate post-op situation with the provisional crown cemented.

Case 1

A 66-year-old female patient who was a smoker presented with the main complaint of a broken anterior tooth. On clinical examination, it was noted that the maxillary left lateral incisor had a metal-ceramic crown with a partially displaced cast metallic core (Fig. 1). The CBCT examination showed the presence of a vertical root fracture due to recurrent caries (Fig. 2). Given the clinical and radiographic situation, the proposed treatment was the extraction of the tooth in question, followed by immediate placement of a ceramic implant and immediate restoration with a crown.

The extraction was performed atraumatically with the aid of periostomes and forceps and a 3.75 × 13.0mm two-piece ceramic implant (Zi, Neodent) was placed in the fresh alveolus (Fig. 3). The insertion torque was 35Ncm, and this primary stability allowed for immediate loading. It should be noted that the implant was placed according to the manufacturer's recommendations at the level of the bone crest, and the gap was filled with bone substitute (maxresorb, botiss biomaterials; 0.5cm² of 0.5–1.0mm; Fig. 4). A 4.5 × 5.0 × 2.5mm (regular) zirconia abutment (Zi CR abutment) was seated (Fig. 5), and a provisional restoration was made with light-polymerising composite resin and cemented on the abutment (Fig. 6). At the end of the surgical procedure, a radiograph was taken (Fig. 7).

The three-month postoperative period was uneventful, and after this period, the patient returned to begin the final prosthetic phase. The final prosthesis was fabricated from monolithic zirconia using a digital workflow (Virtuo Vivo intra-oral scanner, Straumann; Figs. 8 & 9) and cemented on to the abutment with a dual adhesive cement (RelyX U200, 3M; Fig. 10). After 12 months of follow-up, the periapical radiograph showed the stability of the bone (Fig. 11).

After cementing the crown, it was observed that a new crown was needed for the adjacent tooth, the maxillary left central incisor, owing to the discrepancy in colour and dental anatomy. This prosthesis was also fabricated from monolithic zirconia using a digital workflow (Fig. 12) and cemented onto the prepared tooth with a dual adhesive cement (RelyX U200; Fig. 13).

Case 2

A healthy 70-year-old female patient presented with the main complaint of toothache in the region of the maxillary left lateral incisor. Upon clinical examination, it was noted that the tooth had a metal-ceramic crown and had not undergone endodontic

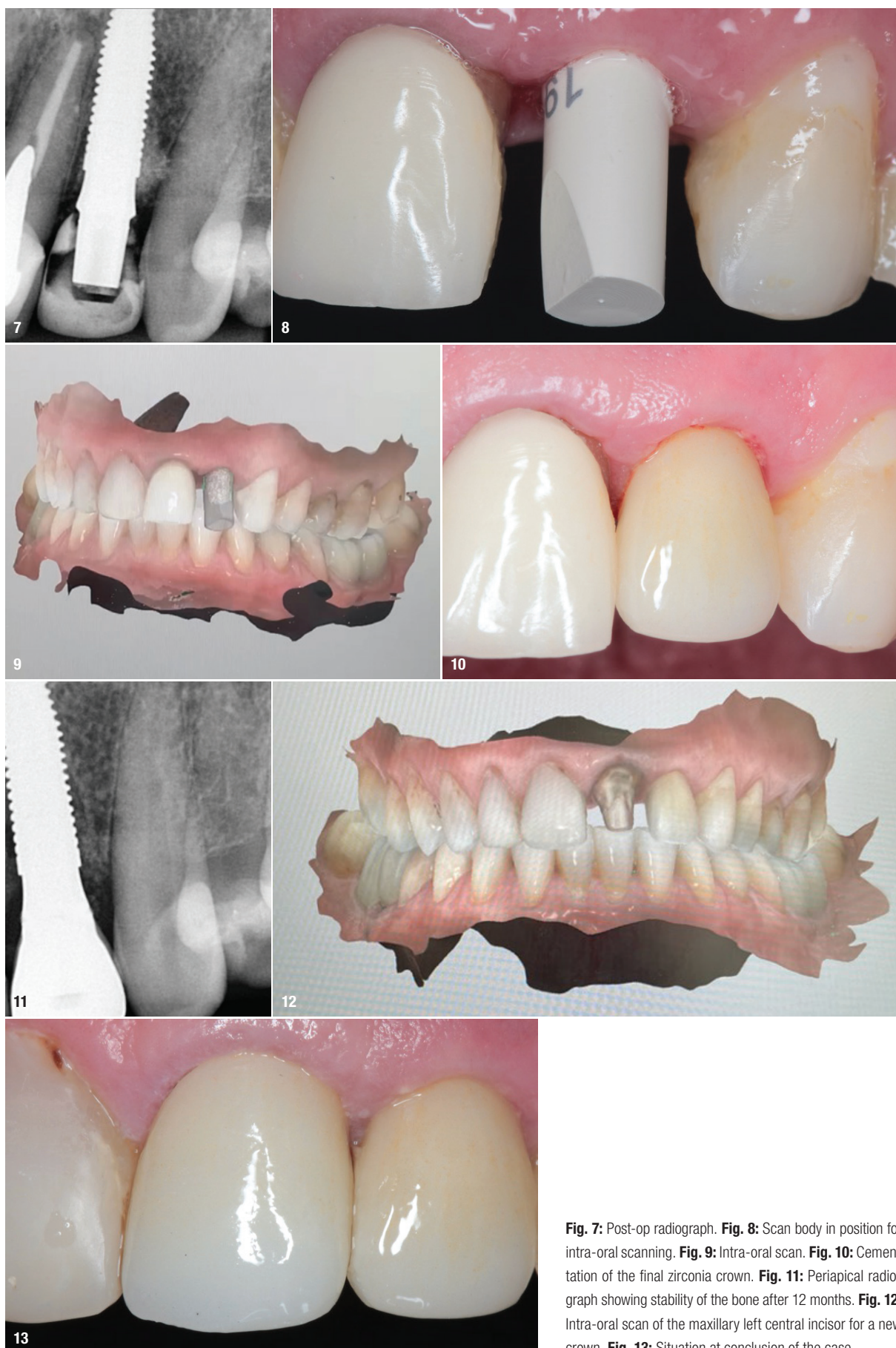

Fig. 7: Post-op radiograph. **Fig. 8:** Scan body in position for intra-oral scanning. **Fig. 9:** Intra-oral scan. **Fig. 10:** Cementation of the final zirconia crown. **Fig. 11:** Periapical radiograph showing stability of the bone after 12 months. **Fig. 12:** Intra-oral scan of the maxillary left central incisor for a new crown. **Fig. 13:** Situation at conclusion of the case.