

ORTHO TRIBUNE

The World's Orthodontic Newspaper • U.S. Edition

AUGUST/SEPTEMBER 2009

www.ortho-tribune.com

VOL. 4, Nos. 8 & 9



Change the world
One student's journey
to orthodontics

▶Page 12



Test your Web site
If you own a practice,
you'll want to read this

▶Page 17



New products
Powders, brackets and
lights make their debut

▶Page 28

Last chance to win free practice makeover!

Apply by Sept. 30

If you are ready to grow your orthodontic practice, apply now to win the second Levin Group Total Ortho Success™ Practice Makeover. The deadline to apply is Sept. 30, which means there are only a few weeks left to win one full year of free Levin Group Total Ortho Success™ Management and Marketing consulting programs.

When was the last time you took a close look at your practice's systems? Whether you are in the beginning stage of your career or already experienced and successful, growth is always within your

Levin Group
Total Ortho Success™
Practice
MAKEOVER

reach — even in this economy.

The winning orthodontic practice will experience improvements in every aspect of running a practice. This free, one-year management makeover will be a customized approach based on the orthodontic practice's unique needs, goals and potential.

To apply, go to www.levingrouportho.com or www.ortho-tribune.com. For more information, contact Lori Gerstley, professional relations manager at Levin Group, at (443) 471-5164 or lgerstley@levingroup.com.

Check out how last year's winner, Dr. Brian Hardy, has grown his practice since he started the makeover process at www.ortho-tribune.com and on page 14. **OT**

Ortho surgery and esthetics

By Prof. Nezar Watted, Prof. Josip Bill, Germany
& Dr. Ori Blanc & Dr. Benjamin Schlomi, Israel

Orthodontic treatment generally follows esthetic, functional, and prophylactic objectives, where individual aspects of isolated cases are accorded varying importance as they arise. Increasing esthetic expectations and awareness of modern dental treatment options disseminated by the media have resulted in increased interest and greater willingness of adults to consider orthodontic treatment. Esthetic orthodontics is thus primarily adult orthodontics.

→ **OT** page 4

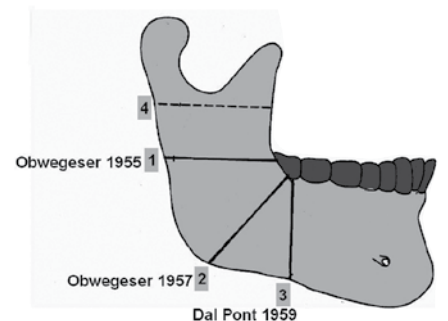


Fig. 1: Diagrammatic representation of the osteotomy lines on the outer (continuous line) and the inner compacta (dashed line) of the mandible; 4 = inner saw cut above the N. mandibularis.

Celebrities embrace braces

By Fred Michmershuizen, Online Editor

Who says braces are just for kids? More and more adults are getting them — even celebrities. Actors, professional athletes and pop stars, such as San Antonio Spurs player Manu Ginobili, actor Tom Cruise

and singer Gwen Stefani, are putting hardware in their mouths to improve their smiles. And these high-profile ortho patients are being noticed, as well.

“These adults are successful,

→ **OT** page 3

AD

OCTOBER
National
Orthodontic
Health Month

Hurry in for your FREE Consultation!
Don G. Lamparski, Jr., DMD, MDS
www.lamparski.com
This artwork is courtesy of
American Association of Orthodontists

**You need results?
Postcard Marketing
Works!**

It's time to build your practice.

**YOURTOWN
DIRECT** ☎ 780-2899

www.Yourtown-Direct.com
www.YourOrthoPostcards.com

PRSRT STD
U.S. Postage
PAID
Permit # 306
Mechanicsburg, PA

Dental Tribune America
213 West 35th Street
Suite #801
New York, NY 10001

AD

Dental Collab BETA

FIRST MONTH FREE
CODE: OTDC09

CREATE,
SHARE,
COLLABORATE.

Connect your treatment workspaces with dental professionals
invited to join your private network from around the globe.

www.DentalCollab.com

Systems thinking rather than linear thinking

By Dennis J. Tartakow, DMD, MEd, PhD,
Editor in Chief



Linear thinking can be defined as simplistic, cause-effect thinking. According to Ollhoff and Walcheski (2002), most individuals think in straightforward, cause-effect and short-term fashion; it is called linear thinking, or attention to content over process.

Understandably, there is a great deal of reinforcement that must transpire in order to not think linearly. This is because work ethics and patterns typically remain the same. It is difficult to change one's thinking, especially because most of us are preoccupied with content

and objectives taking center stage in our minds.

These interactive patterns can be seen everywhere, and most people think and act on a linear level, considering only the end-point of the content rather than the process. Once we are pressed to consider the process of differentiation including both functions (relationship development and integration), we better understand our own social behaviors and with greater appreciation.

Of course, most individuals never associate their learning process with systems thinking, but unconsciously live their lives systematically.

By breaking down the concept of a system and its variations, we begin to identify with our impressions of how this is integrated within our practices. When the system is interdependent, all parts of the system can be interrelated with all other parts. Systems can vary, such as: (a) open systems, where the system shares information with its environment; and (b) closed systems, where the system is self-contained.

Other key concepts in complex systems include (a) homeostasis, where the push of the system is to stay the same; (b) anxiety, where the feeling of dread or inadequacy exists toward

a particular issue; (c) differentiation, where you have your own goals and can define yourself, but are still able to stay in relationships, even with individuals of differing opinions; (d) emotional triangle, when two people are in disagreement and draw in a third to stabilize the conflict (This is not mediation, attempting to solve the conflict); (e) forces of togetherness, which is the push to think alike, to reduce creativity and the diversity of thought; and (f) identifying the patient, or the scapegoat.

In summation, the most important thing to remember is to recognize the differences between (a) linear thinking, considering only the content; and (b) systems thinking, considering the processes and the interactions.

Of course, this is not to imply that linear thinking is bad or wrong, but rather that it is only one level of thinking that is not seeing the big picture of the world and reality that is our environment.

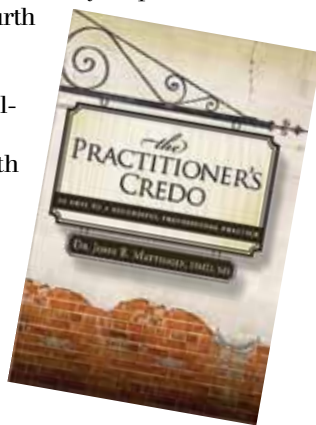To paraphrase the words of philosophers Edmund Burke (1729-1797) and George Santayana (1863-1952): Individuals who ignore history are doomed to repeat it; individuals who study history are doomed to know it is repeating. **OT**

Book review: 'The Practitioner's Credo: 10 Keys to a Successful Professional Practice'

By Gregg A. Tartakow, Associate Editor

Dr. John B. Mattingly, a practicing orthodontist for four decades, was concerned that orthodontic residents and young practitioners were not exposed to what it takes to conduct a successful practice. Motivated by a sincere commitment and genuine dedication to the "new-bees" of orthodontics, Mattingly provides a cookbook approach to the basic principles of office management by presenting the following 10 keys to a successful practice:

- The first key — practice leadership
- The second key — enthusiastic, effective staff
- The third key — practice ethics
- The fourth key — pursuit of excellence
- The fifth



- The sixth key — cutting-edge technology
- The seventh key — working environment
- The eighth key — essential and non-essential expenses
- The ninth key — marketing your practice
- The 10th key — "Ego": Don't get the big head

In addition to these 10 keys, four appendices are used to demonstrate the values of the (a) office manual, (b) sexual and environmental harassment policy, (c) exit survey prototype and (d) explanation and letters related to association [AAO] membership revocation.

"The Practitioner's Credo: 10 Keys to a Successful Professional Practice" is interesting reading, stimulating reflection and an enjoyable reference source for postgraduate orthodontic residents and seasoned teachers alike; it integrates theory and practice with regard to the art of thinking. The book is quite useful to beginning instructors as well as experienced teachers who are attempting to improve their thinking perspectives or reconsidering their approaches to pedagogy.

Several themes are repeated throughout the book, which I think is positive reinforcement. **OT**

Information

Mattingly, J.B. (2009). The practitioner's credo: 10 keys to a successful professional practice. Garden City, NY: Morgan James Publishing. 143 pages. ISBN: 978-1-60037-556-9.

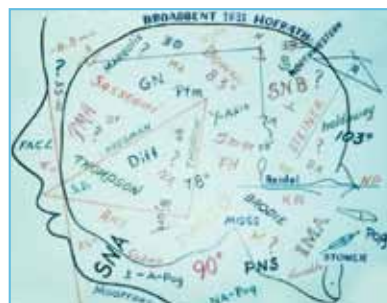

Image courtesy of Dr. Earl Broker.

Member Publication
AADE
American Association
of Dental Editors

ORTHO TRIBUNE
The World's Orthodontic Newspaper - U.S. Edition

Publisher & Chairman

Torsten Oemus
t.oemus@dental-tribune.com

Vice President Global Sales

Peter Witteczek
p.witteczek@dental-tribune.com

Chief Operating Officer

Eric Seid, e.seid@dental-tribune.com

Group Editor & Designer

Robin Goodman
r.goodman@dental-tribune.com

Editor in Chief Ortho Tribune

Prof. Dennis Tartakow
d.tartakow@dental-tribune.com

International Editor Ortho Tribune

Dr. Reiner Oemus
r.oemus@dental-tribune.com

Managing Editor/Designer

Ortho Tribune & Show Dailies
Kristine Colker
k.colker@dental-tribune.com

Managing Editor/Designer

Implant & Endo Tribunes
Sierra Rendon
s.rendon@dental-tribune.com

Online Editor

Fred Michmershuizen
f.michmershuizen@dental-tribune.com

Product & Account Manager

Humberto Estrada
h.estrada@dental-tribune.com

Product & Account Manager

Mark Eisen, m.eisen@dental-tribune.com

Marketing Manager

Anna Wlodarczyk
a.wlodarczyk@dental-tribune.com

Marketing & Sales Assistant

Lorrie Young, l.young@dental-tribune.com

C.E. Manager

Julia Wehkamp
j.wehkamp@dtamerica.com

Dental Tribune America, LLC
215 West 35th Street, Suite 801
New York, NY 10001
Phone: (212) 244-7181, Fax: (212) 244-7185



Published by Dental Tribune America

© 2009, Dental Tribune International GmbH. All rights reserved.

Dental Tribune makes every effort to report clinical information and manufacturer's product news accurately, but cannot assume responsibility for the validity of product claims, or for typographical errors. The publishers also do not assume responsibility for product names or claims, or statements made by advertisers. Opinions expressed by authors are their own and may not reflect those of Dental Tribune International.

OT Editorial Advisory Board

Jay Bowman, DMD, MSD
(Journalism & Education)

Robert Boyd, DDS, MEd
(Periodontics & Education)

Earl Broker, DDS
(T.M.D. & Orofacial Pain)

Tarek El-Baily, BDS, MS, MS, PhD
(Research, Bioengineering & Education)

Donald Giddon, DMD, PhD
(Psychology & Education)

Donald Machen, DMD, MSD, MD, JD, MBA
(Medicine, Law & Business)

James Mah, DDS, MSc, MRCD, DMSc
(Craniofacial Imaging & Education)

Richard Masella, DMD (Education)

Malcolm Meister, DDS, MSM, JD
(Law & Education)

Harold Middleberg, DDS
(Practice Management)

Elliott Moskowitz, DDS, MSd
(Journalism & Education)

James Mulick, DDS, MSD
(Craniofacial Research & Education)

Ravindra Nanda, BDS, MDS, PhD
(Biomechanics & Education)

Edward O'Neil, MD (Internal Medicine)

Donald Picard, DDS, MS (Accounting)

Howard Sacks, DMD (Orthodontics)

Glenn Sameshima, DDS, PhD
(Research & Education)

Daniel Sarya, DDS, MPH (Public Health)

Keith Sherwood, DDS (Oral Surgery)

James Souers, DDS (Orthodontics)

Gregg Tartakow, DMD (Orthodontics)
& Ortho Tribune Associate Editor

International Cone Beam Institute: educating, training, connecting

Organization wants every dental professional to become a cone-beam expert

The International Cone Beam Institute (ICBI) is an independent organization of cone-beam computerized tomography (CBCT) experts who provide the highest level of education, training and product information for 3-D technology to dental professionals worldwide at www.ExploreConeBeam.com.

As a vendor-neutral organization, this is an industry first — where a company is providing information to the dental professional, future imaging centers and the vendor on an international level.

General information such as the different cone-beam scanners available in the United States and international markets, as well as general information about available third-party software, is available to everyone without charge. ICBI provides in-depth and customized vendor analysis to help practitioners understand this comprehensive technology.

ICBI's educational faculty has the industry expertise to consult with dental professionals looking to incorporate CBCT into their practices, and to ensure that every question is answered during the decision-making process, including questions about medical billing and ROI (return on investment). For those who are already CBCT users, ICBI provides training to maximize the power of this technology and to help them achieve an expert level of confidence.

ICBI Web site members are able to review case studies and get advice from CBCT experts.

← 01 page 1

beautiful and total metal-mouths and brace-faces," blogger Lindsay Mannering recently wrote.

"And they don't care who knows it!" Mannering, who was stressed out about an upcoming visit to the dentist, posted a slideshow of famous people with braces on The Huffington Post.

The trend is not just for Americans, either. The British Society of Orthodontists is reporting a significant rise in the number of adults seeking orthodontic treatment.

"The British are supposedly famous for having ugly, snagged teeth, which perhaps explains why people are seeking aesthetic improvements in greater numbers — we now spend £360m a year on cosmetic dentistry," the British newspaper The Guardian wrote recently. 01



In addition, ICBI offers a connection to oral-maxillofacial radiologists who can provide reading services to aid in the interpretation of CBCT scans. ICBI also has a blog where users can exchange

case studies, ideas and techniques about how to capture the highest quality images.

ICBI members have access to special consulting services, online training and training seminars.

The International Congress of Oral Implantologists (ICOI), the world's largest implant education organization, fully endorses the ICBI. Additional partners of ICBI

include Dental Tribune International (www.dental-tribune.com) and Dental Tribune Study Club (www.DTStudyClub.com).

The ICBI wants every dental professional to become a CBCT expert. Upcoming seminars include Atlanta on Sept. 25–26, and Charlotte, S.C., on Oct. 9–10. For more information about these seminars, visit www.ExploreConeBeam.com.

AD

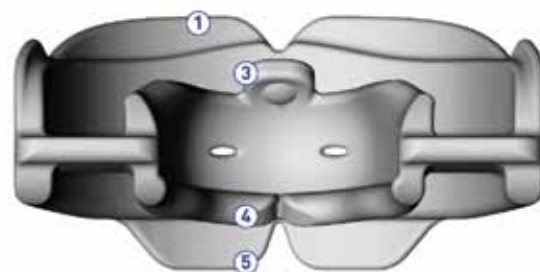


Now an early Class II correction with arch expansion and improved Myofunctional Effect™.

Interceptive Series™ appliances are aimed at a child's most rapid growth spurt — described by Ricketts as 5 to 8 years of age.

The key features of the **i-2™** are high extended **Reflex Sides**, and a **Frankel Inner Frame**, which actively expands the maxillary arch form. The **Positive Tongue Position Elevator**, identical to that on the **i-3™**, improves tongue posture in conjunction with the **Tongue Tag** — a feature common to all MRC Appliances incorporating the Myofunctional Effect™.

The added feature for more extreme Class II malocclusion is the extended **Lower Flange** and **Lip Bumper**. Class II malocclusions typically have strong overactive musculature in the mentalis area. Compared to other T4K®, the **Lip Bumper** on the **i-2™** extends further into the sulcus, and is designed specifically to deactivate the lower fibres of the orbicularis oris.



TECHNOLOGY

- 1 Reflex Sides
- 2 Frankel Inner Frame
- 3 Tongue Tag
- 4 Tongue Position Elevator
- 5 Extended Lower Flange
- 6 Lip Bumper



The **i-2™** is optimised to improve the maxillary arch form and treat factors contributing to **Class II malocclusion**.



Celebrating 20 years in 2009

CALL NOW FOR YOUR FREE MRC CLINICS® CD-ROM

1 866 550 4696


www.myoresearch.com

Align, Ormco end patent dispute, plan to collaborate

Align Technology, manufacturer and marketer of Invisalign, has reached a settlement with Ormco, a subsidiary of Danaher, to end all pending litigation between the parties and to begin a new strategic collaboration.

As part of the settlement, Align will make a cash payment of approximately \$13 million to Ormco and issue approximately 7.6 million shares of Align's common stock to Danaher, which after issuance will be equal to approximately 10 percent ownership interest in Align. The value of the shares is approximately \$77 million (based on the closing price of Align's common stock on Aug. 14).

Align and Ormco also have agreed upon an exclusive collaboration over the next seven years to develop and market an orthodontic product that combines the trademarked Invisalign system with Ormco's trademarked Insignia orthodontic brackets and arch wires system to treat the most complex cases. Each party will retain ownership of its pre-existing intellectual property.

(Sources: Align Technology and Danaher Corp.) 

 page 1

A peculiarity of orthodontic treatment in adults compared with pediatric or adolescent orthodontics is the age-associated involution of the connective tissues that leads to a reduction in cell density, thickening of the fibre bundles, delayed fibroblast proliferation and reduced vascularisation.

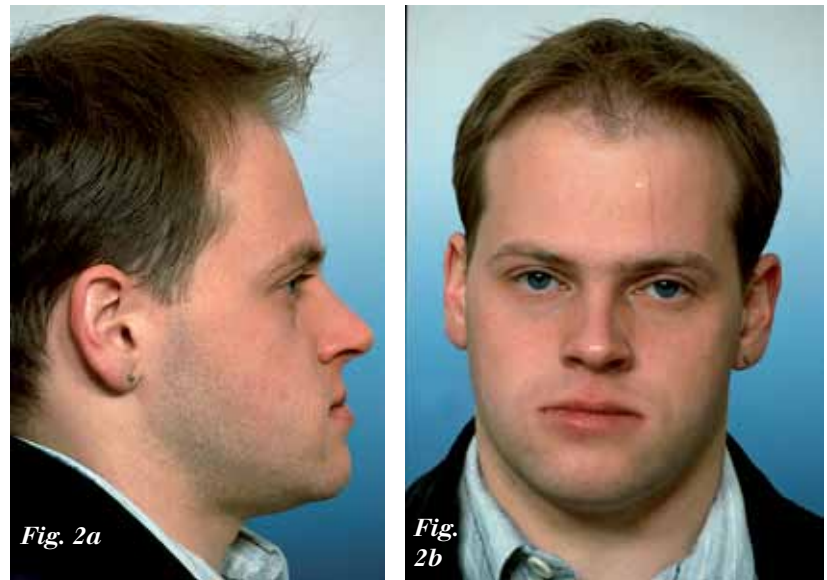
These are the causes of slower dental movement and delayed tissue and bone reactions.

Absent sutural growth, the age of the periodontium, specific periodontal diagnoses and tissue atrophy also make treatment in adults particularly challenging.

As a rule, esthetically oriented adult orthodontics therefore has an interdisciplinary inclination. Occlusion, function and esthetics are considered to be equivalent parameters in modern orthodontics and particularly here in combined orthodontic-maxillofacial surgical treatment.^{32,33}

This was achieved through optimisation of diagnostic tools and further development and increasing experience in orthopaedic surgery.⁴

Nowadays, treatment of adult patients with dental malposition and mastication impairment is one of the standard tasks of the orthodontist. If the discrepancies in spatial allocations of the upper and lower dentition are particularly pronounced and where the cause is primarily skeletal and not only dentoalveolar, conventional orthodontic therapy is limited, and combined orthodontic-surgical therapy is indicated for remodelling of the jaw bases.



Figs. 2a, b: Lateral view of the 25-year-old male patient, showing lower facial retrusion diagonally forward. The frontal view shows the right-sided deviation due to the laterognathia. The upper-lip vermillion is relatively weakly developed (b).

Treatment for a skeletal dysgnathia (Class III) using combined orthodontic-maxillofacial surgical correction is discussed in this article.

Development of maxillofacial surgery of the mandible

The first orthodontic-maxillofacial surgical procedure on the mandible described in the literature was that of the American surgeon Hüllihen in 1848.¹⁵ This procedure was a segmental osteotomy of the anterior mandible (a posterior shift [retrusion] of a protruding mandibular alveolar process, following a burn injury).

Toward the end of the 19th century, the method of orthodontic-maxillofacial surgical correction

of dysgnathias by surgical retrusion or protrusion of the mandible was revisited. Jaboulay¹⁴ described resection of the Processus condylaris and Blair¹, osteotomy on the Corpus mandibulae.

The continuity resection in the horizontal branch by Blair was the first surgical prognathism procedure.

The patient first visited the dentist Whipple in St. Louis in 1891 and was referred to the then most renowned orthodontist Dr Edward Hartley Angle², who ultimately recommended the surgical procedure mentioned above.

Six years later, the procedure in this osteotomy on the Corpus mandibulae was also published by the Hamburg surgeon Floris.¹¹

AD

Dental Collab BETA

FIRST MONTH FREE
CODE: OTDC09



CREATE, SHARE & COLLABORATE.

Connect your treatment workspaces with dental professionals that you invite to join your private network from around the globe.

www.DentalCollab.com

FINALLY, A SOLUTION CONNECTING DENTAL PROFESSIONALS:

- ▶ 1-on-1 Mentoring **WITH** Experts & Peers
- ▶ GP's Collaborate **WITH** Specialists
- ▶ Specialists Coordinate **WITH** Referrals
- ▶ On-line Consultation **WITH** Patients
- ▶ Share Cases **WITH** Labs & Suppliers

DENTAL TRIBUNE

WEB APPLICATION HIGHLY RECOMMENDED BY
DENTALTRIBUNE.COM AND DTSTUDYCLUB.COM



SECURE, CLOUD HOSTING
AMAZON WEB SERVICES PLATFORM

modulusmedia
CONFIGURED FOR YOUR BUSINESS.

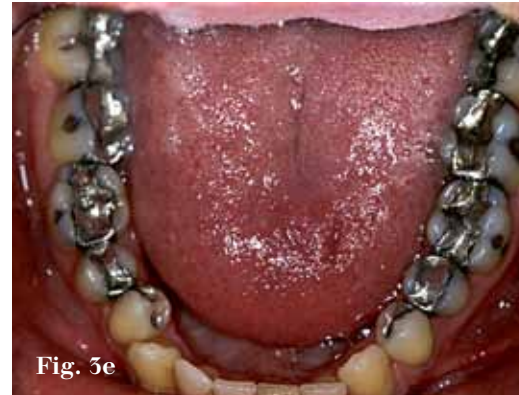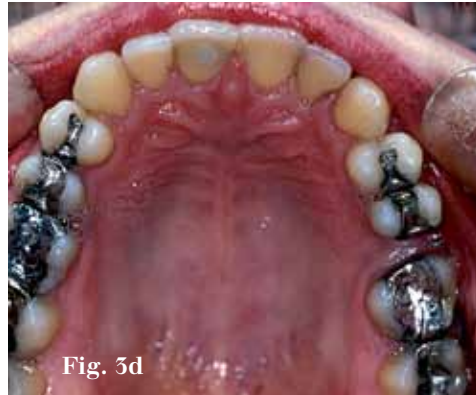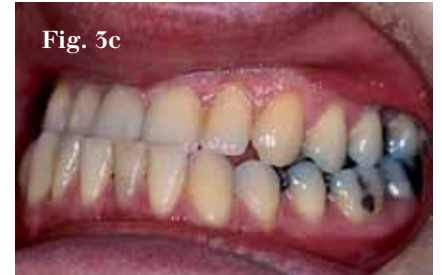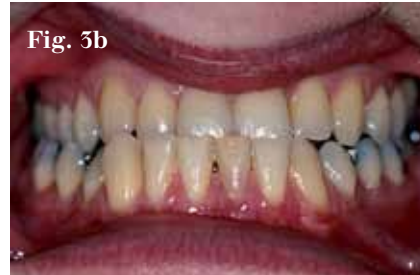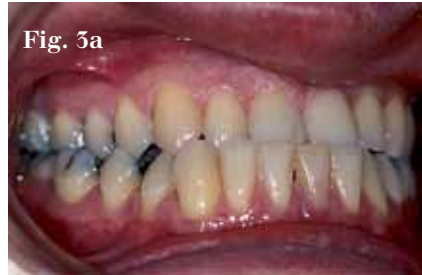POWERED AND MANAGED BY
MODULUS MEDIA INC.



Parallel with this development in the United States, Von Auffenberg⁵ in Europe conceived a step-by-step osteotomy for correcting a mandibular retrusion, which was performed by Von Eiselberg in 1901.

The era of orthodontic surgery in Europe began only after World War I. The experience gained there led to a substantial extension of the indications for orthodontic-maxillofacial surgical procedures, as well as to the transferral of this surgical technique to the area of elective procedures.^{5,6,16-18,24}

In the early 1920s, Bruhn and Lindemann set transversal osteotomy of the Ramus mandibulae as the standard method at the time for the surgical correction of mandibular prognathism. This method, which continued to have many adherents well into the 1960s, is today known as the Bruhn-Lindemann procedure.^{1,6,25,45}



Figs. 3a-e: Clinical situation before the start of treatment.

→ [OT](#) page 6

www.ortho-tribune.com

Missed the last edition of Ortho Tribune? You can read some of its content online!

Digital treatment: A look at two SureSmile cases — high quality, less time (Part 3 of 3)

www.ortho-tribune.com/articles/content/scope/specialities/section/case_reports/id/390

Ethical and moral scenario planning for orthodontics (Part 3 of 3)

www.ortho-tribune.com/articles/content/scope/politics/region/usa/id/387

Here's some other online content that might be of interest ...

Utilizing fixed orthodontics to prepare cases for aligners

www.ortho-tribune.com/articles/content/scope/specialities/section/case_reports/id/347

Dr. Arthur Wool reflects on his career

www.ortho-tribune.com/articles/content/scope/specialities/section/interviews/id/338

Orthodontists practice what they preach

www.ortho-tribune.com/articles/content/scope/news/region/usa/id/399

MRC celebrates 20 years of ingenuity

www.ortho-tribune.com/articles/content/scope/business/region/usa/id/337

AD

Your days of juggling are over.

Ortho2 Practice Management Software transforms your office from a three-ring circus to a more efficient and profitable orthodontic practice with:

Superior practice management • Imaging and ceph tracing • Email, text, and voice messaging • Online forms and account access • And much more!

See why Ortho2 is the gold standard in practice management software.
(800) 678-4644 • www.ortho2.com

ORTHO2
Practice Complete Management.

← 01 page 5

In 1935, Wassmund, who saw its drawbacks in a possible dislocation of the proximal segment by the muscles inserted there, described a modification of the Bruhn-Lindemann surgical technique.²⁶ In the early 1950s, a new era in orthodontic surgery of the mandible was begun with Kazanjian's resumption^{12,15,25} of the technique of transverse, oblique severing of the ascending ramus, first performed by Perthes in 1922.²²

Shuchard modified this method in 1954 by enlarging the bony insertion surface, and in 1955 Obwegeser introduced sagittal splitting at the horizontal ramus of the mandible. He shifted the buccal osteotomy line obliquely from the last molar to the posterior margin of the jaw angle.¹⁹⁻²¹

In 1959, Dal Pont moved this buccal osteotomy line from the last molar to the inferior margin of the mandible.^{8,9} Since then, this method of sagittal split at the mandible has been called sagittal split according to Obwegeser-Dal Pont (Fig. 1). Epker¹⁰ developed the incomplete sagittal split into a routine method.

Clinical case presentation: history and diagnosis

A 25-year-old patient presented on his own initiative. He complained of functional (impairment of mastication and jaw joint pain) and esthetic impairment (sunken face with facial asymmetry). He had undergone orthodontic treatment between the ages of 8 and 15 and reported pain in the area of the anterior mandible.

The lateral image showed a retrusive lower face inclined forward with mid-facial hypoplasia — regio infraorbitale — a flat upper lip and an elongated lower face compared with the mid-face — 47%:53% instead of 50%:50%²⁹ (Table I; Fig. 2a).

Owing to the negative sagittal overjet, there was a positive lower lip step. The frontal image shows mandibular deviation (laterognathia) to the right, which can be traced to growth asymmetry in the jaw (Fig. 2b). In addition, there was a Class III dysgnathia angle with conspicuous mandibular midline deviation to the right, frontal and right lateral crossbite, anterior mandibular labial tilt and a steep anterior mandible. Tooth 26 had been missing for some time (Figs. 3a-e).

FRS analysis (Table I, II) clearly

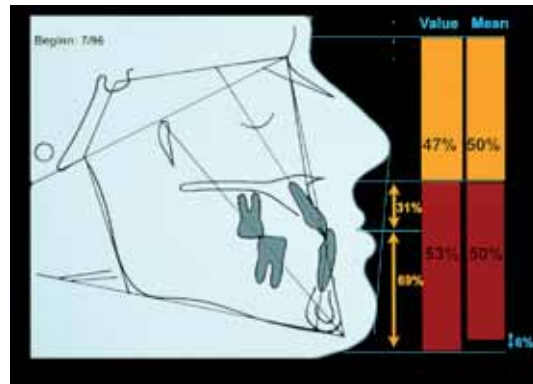


Fig. 4: The cephalometric X-ray shows the disharmonious arrangement in the vertical axis. The lower face shows an approximately 60 percent enlargement in relation to the upper face.

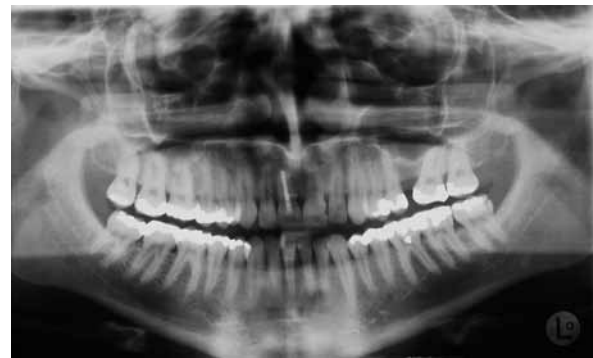


Fig. 5: Orthopantomographic image before the start of orthodontic treatment. An apical lucency at tooth 31. Pronounced maxillary-antrum expansion between teeth 25 and 27. Orthodontic closure of the gap is difficult.

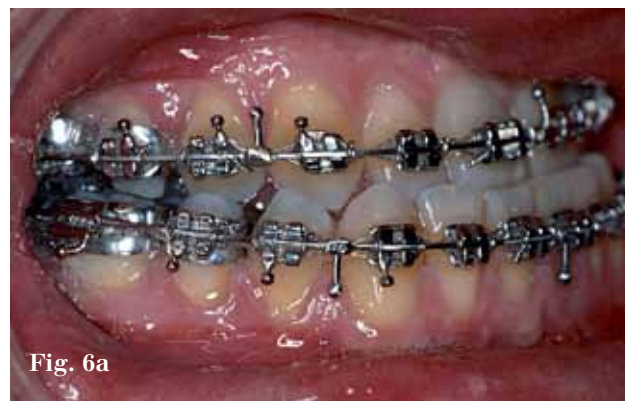

Fig. 6a

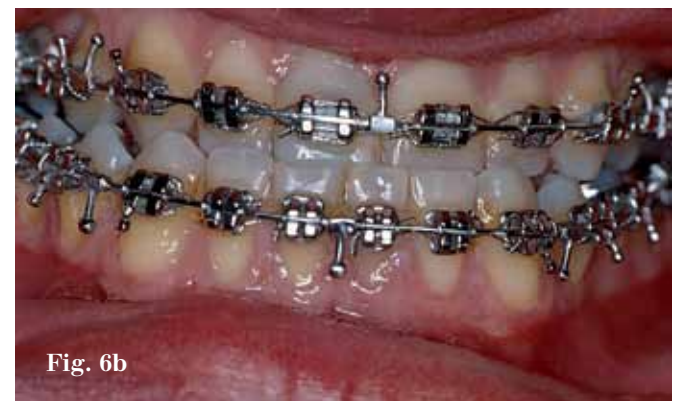

Fig. 6b

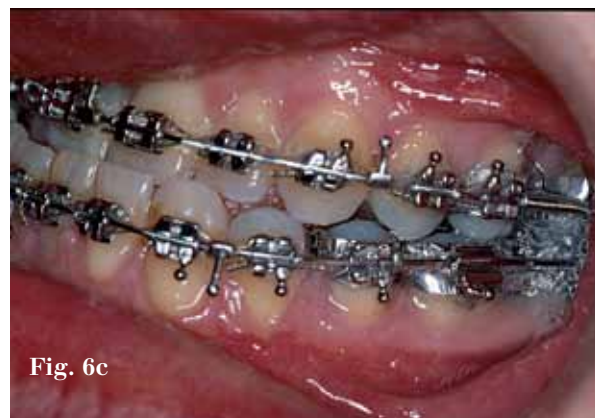

Fig. 6c

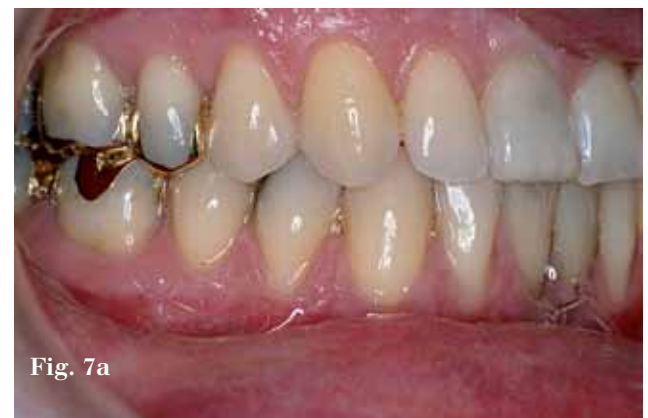

Fig. 7a

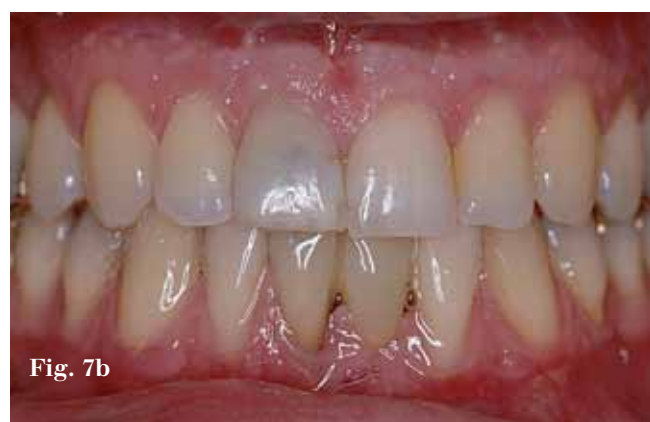

Fig. 7b

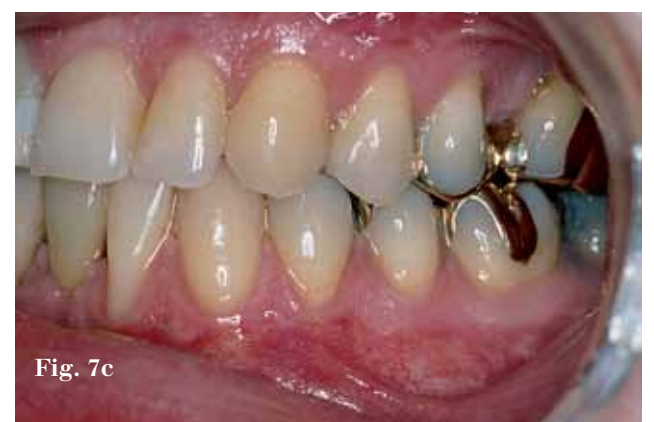

Fig. 7c

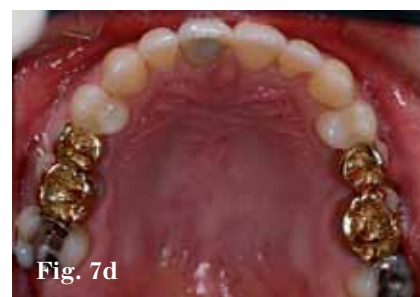

Fig. 7d

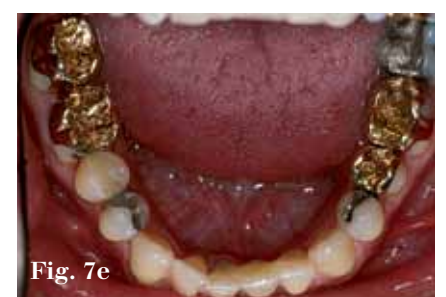

Fig. 7e

shows the strongly sagittal and relatively weak vertical dysgnathia both

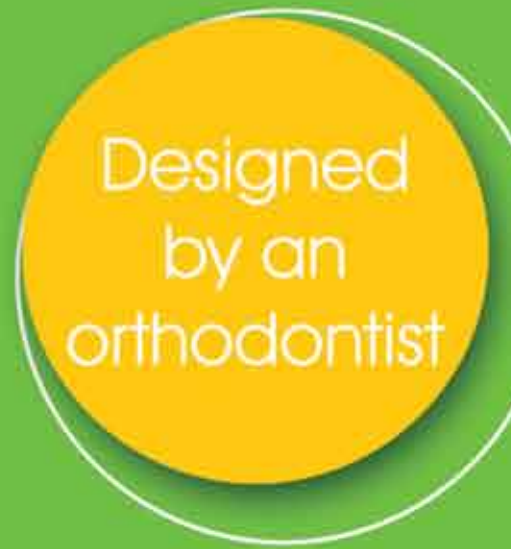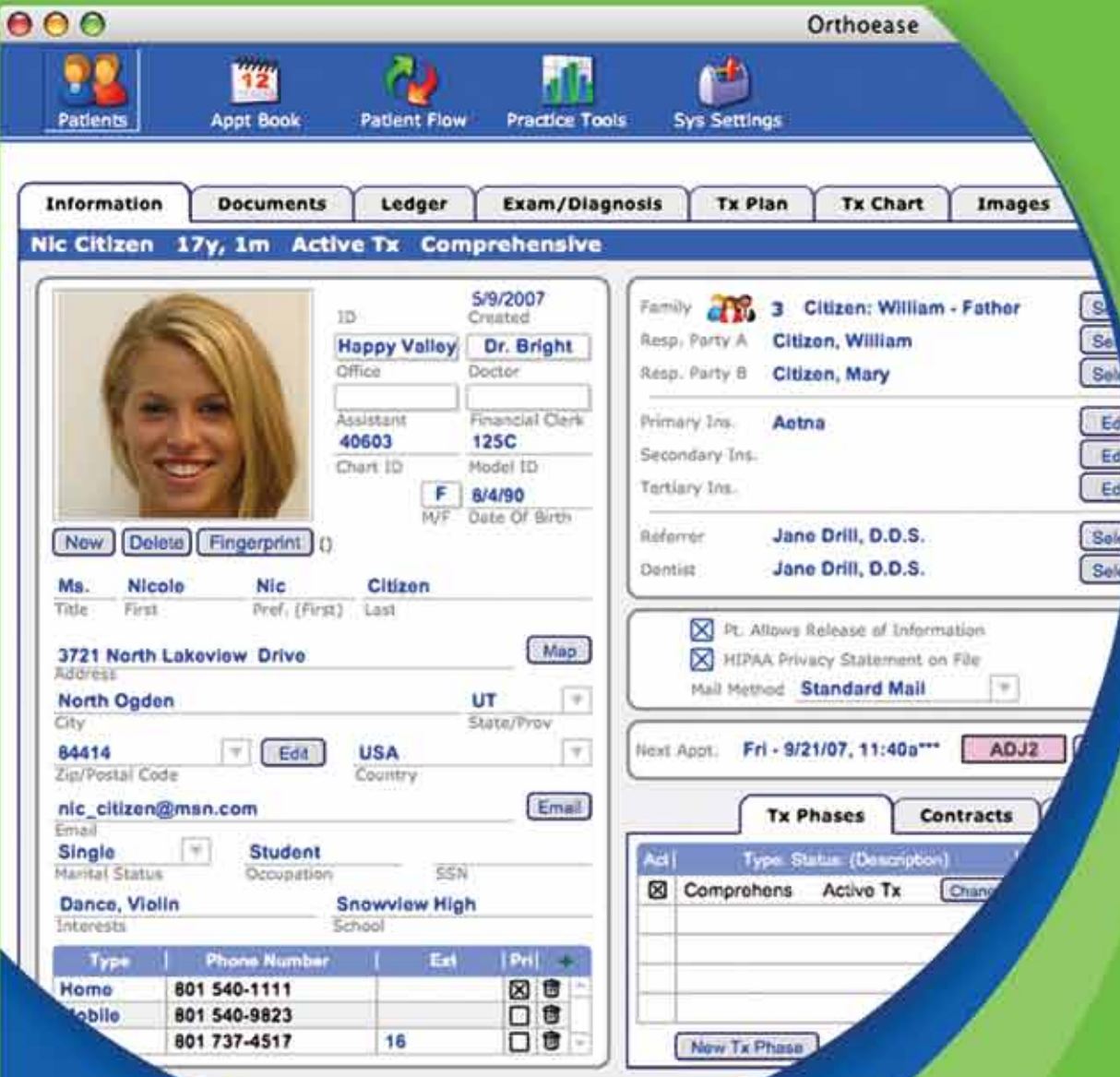
→ 01 page 8

Figs. 6a-c: Situation after orthodontic preparation for the surgical procedure.

Figs. 7a-e: Occlusion at the end of treatment; there is a neutral stable occlusion with physiological anterior bite in the sagittal and vertical axes and a correct midline (a-c). Monitoring images of the upper and lower jaws. A ceramic bridge was made in the lower jaw (d & e).

AD

Dental Collab BETA
 FINALLY A SOLUTION FOR GETTING THAT SECOND OPINION.
 WWW.DENTALCOLLAB.COM
 FIRST MONTH FREE
 CODE: OTDC09
 IT'S NEW



OrthoEase

The most **intuitive** practice management software program yet!

Featuring:

- Paperless Charting • Comprehensive Imaging & Analysis
- Ready-To-Use Scheduling Templates
- Automated Data Backup • World Class Support
- Industry's Best Financial and Management Reporting



Improve your case acceptance and manage your practice with ease

www.orthoease.com • 1-800-217-2912

← OT page 6

in the soft-tissue profile and in the skeletal region.

The parameters indicated a mesiobasal jaw relationship and a growth pattern with an anterior course: the vertical grouping of the soft-tissue profile showed a disharmony between the mid-face and the lower face ($G^2-Sn:Sn-Me^2$; 47%:55%).

This was relatively weakly expressed in the bony structures ($N-Sna:Sna-Me$; 44%:56%).

In the region of the lower face there was also mild disharmony ($Sn-Stm:Stm-Me^2$; 31%:69%).

Complementary assessment of the mandible showed that the area from the subnasal-labral inferius to the soft-tissue chin ($Li-Me^2$), which should have been 1:0.9, was shifted

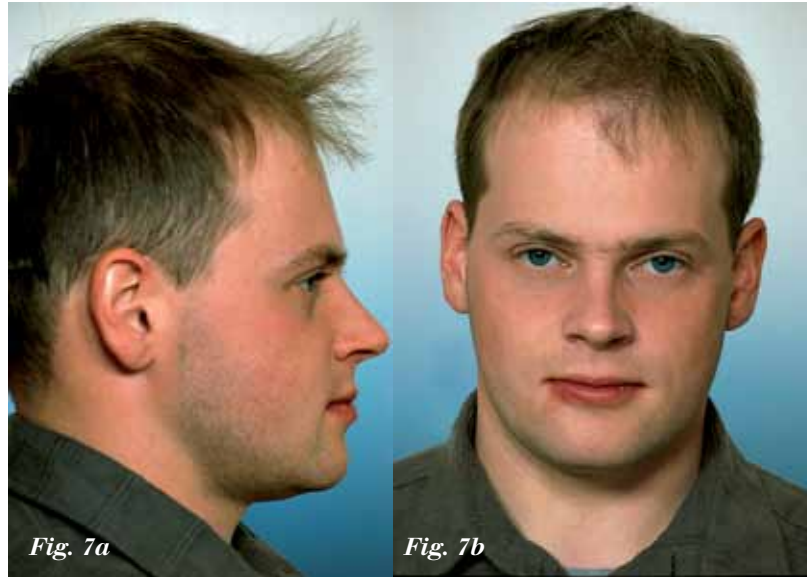


Fig. 7a

Fig. 7b

in favor of the $Li-Me^2$ part (0.9:1; Fig. 4). The panoramic image showed a

lucency of teeth 51 and 41. A root canal procedure followed by root

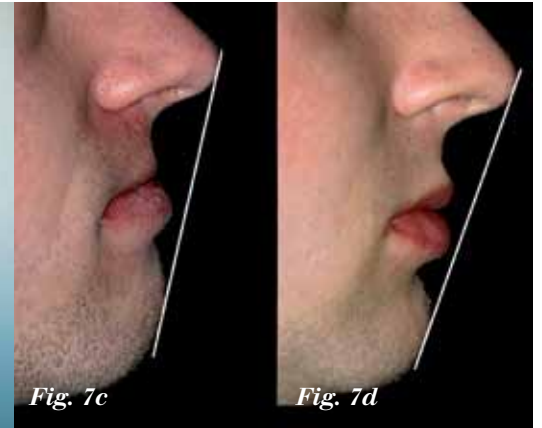


Fig. 7c

Fig. 7d

Figs. 8a-d: The extra-oral treatment results. The sagittal, vertical and transverse were corrected (a, b). Change in the oral profile: left pre-op, right post-op (c, d).

apex resection was thus performed (Fig. 5).

AD

BUILD A LEVIN PRACTICE™ WITH LEVIN GROUP'S TOTAL ORTHO SUCCESS™



Our commitment is to help every orthodontist grow regardless of the economy. Every practice has the potential to transform into A Levin Practice™ and anticipate these results:

- Continually increasing production
- Continually increasing profit
- Continually increasing referrals
- A low stress practice environment
- High levels of professional satisfaction
- Reaching financial independence sooner

Orthodontists who grow their practices are implementing effective marketing and management systems allowing them to outperform other practices. You can't afford to sit back and wait for something to happen. You have to act now to make a difference! To learn more about Levin Group's comprehensive consulting programs and seminars, go to www.levingrouportho.com or call 888.973.0000.

"Successful people have always been the ones who act on opportunities. Don't miss yours!"

Roger P. Levin, DDS - Chairman & CEO, Levin Group, Inc.



Next Seminar for Orthodontists:



Grow Your Ortho Practice 30% Now!
Orlando, FL
December 3 - 4, 2009

Visit

www.levingrouportho.com
for a complete list of upcoming seminars!

Levin Group Inc.

www.levingrouportho.com

888.973.0000

Copyright© 2009 by Levin Group, Inc. All rights reserved.

Therapeutic objectives and treatment planning

The objectives of this combined orthodontic-maxillofacial surgical treatment were:

1. The establishment of neutral, stable, and functional occlusion with physiological condylar positioning;
2. The optimisation of the facial esthetics;
3. The optimisation of the dental esthetics, considering the periodontal situation;
4. The assurance of the stability of the results achieved;
5. Meeting the patient's expectations.

The improvement of the facial esthetics, not only in the sagittal axis in the region of the lower face (the mandibular region) but also in the region of the mid-face (hypoplasia) and in the transverse axis, should be noted as specific treatment objectives. The change in the region of the mid-face was intended to affect the upper lip and the upper-lip vermillion. These treatment objectives were achieved by two procedures:

1. A dorsal extension of the mandible with lateral sweep to the left for correction of the sagittal and transverse defects, as well as occlusion and the soft-tissue profile.
2. Bone augmentation in the mid-face for harmonization of the face. It would not have been possible to achieve the desired treatment objectives with respect to function and esthetics using orthodontic procedures alone.²⁷

Therapeutic procedure

Correction of the pronounced dysgnathia was done in six phases:^{28,30-35}

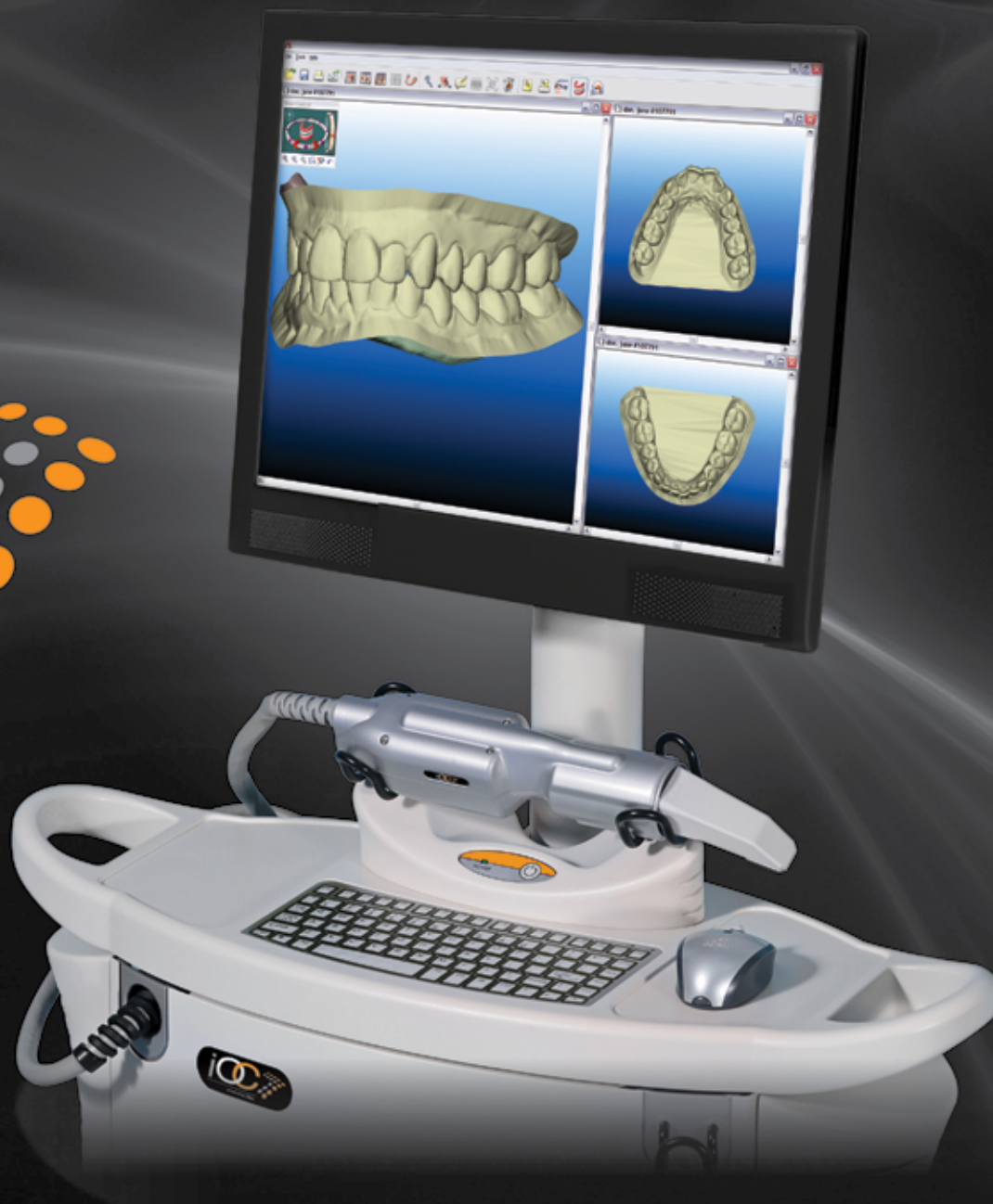1. Splint therapy: a flat bite guard splint was installed for six weeks in order to determine the physiological condylar position or centrics before the final treatment planning. By doing this, the forced bite could be demonstrated to its full extent.

→ OT page 10

INTRODUCING



powered by iTero.



- **OPTIMAL CONTROL**
THE IOC SCANNER IMPROVES DIAGNOSTIC ACUITY, TREATMENT PLANNING, AND CHAIRSIDE CONSULTATION WITH THE PATIENT.
- **OPTIMAL CONSISTENCY**
DIGITAL ORTHODONTIC SCANNING REMOVES THE UNCERTAINTIES ASSOCIATED WITH CONVENTIONAL ALGINATE AND PVS IMPRESSIONS.
- **OPTIMAL CONVENIENCE**
INTUITIVE SOFTWARE AND AUTOMATED PROMPTS FACILITATE EASE OF USE AND WIDESPREAD ADOPTION BY OFFICE STAFF.
- **OPTIMAL CONNECTIVITY**
THE IOC DIGITAL TECHNOLOGY ENHANCES PATIENT COMMUNICATION AND ACCELERATES TREATMENT ACCEPTANCE.

A **Digitally Perfect** Orthodontic Impression

The new **iOC Scanner** provides a precise orthodontic impression that is, quite literally, digitally perfect. Powered by iTero, the **iOC Scanner** uses parallel confocal imaging to digitally capture the contours of tooth and gingival structures,

producing an accurate digital orthodontic scan in just minutes. The **iOC Scanner** is designed expressly for seamless integration with OrthoCAD iCast, OrthoCAD iQ, and the suite of digital imaging solutions developed by Cadent.

OrthoCAD.

www.cadentinc.com
1-800-577-8767