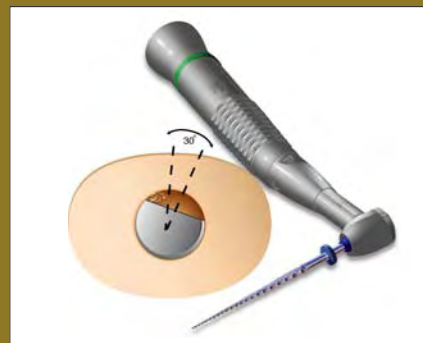


Inside this issue

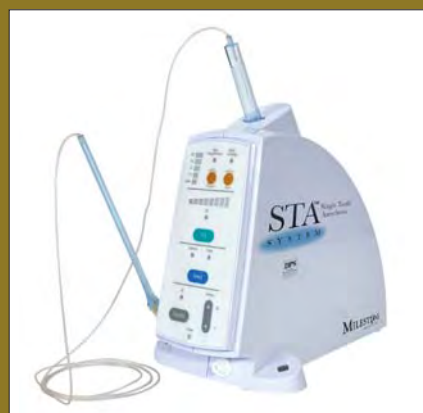Endodontic shaping



The entire discussion of endodontic instruments is often limited to which rotary NiTi system works best. The major manufacturers have tried to make it a given that rotary NiTi in one form or another is truly the only way to go. However, underneath that doctrinaire exterior lie clues to the fact that rotary NiTi cannot be the entire story. Dr. Barry Lee Musikant and Dr. Allan S. Deutsch explain.

Page 7

Single tooth anesthesia



The STA (single tooth anesthesia) System from Milestone Scientific utilizes computer-controlled local anesthetic delivery to create a comfortable injection process for both the dentist and the patient. STA allows dentists to stop administering block injections, and it is ideal for endodontists as they focus on one tooth at a time.

Page 13

AAE Fall Conference

"Implants in Endodontics — Treatment Planning and Placement Techniques" is the theme for the AAE Fall Conference, scheduled to take place this November in San Francisco. The 11 hours of endodontic-related continuing education will feature workshops and lectures presented by Dentsply Tulsa Dental Specialties and Nobel Biocare, as well as sessions on experiences with implants in both the clinical practice and the educational environment.

Page 14

Endodontic success and obturation: to have and to hold

By E. Steve Senia, DDS, MS, BS, and Greg Goldfaden, DMD

As mentioned in previous articles (see "Endodontic success: it's all about the apical third," Endo Tribune, March 2008; and "Endodontic success and working length: thinking 3-dimensionally," Endo Tribune, April 2008), cleaning the canal is the most important part of endodontic treatment. This doesn't mean that an effective seal is not important — it is. It means that an obturation can only be as good as the instrumentation. No obturation technique can seal a canal when tissue or debris prevents the filling material from occupying the entire canal space. However, although cleaning is most important (apical lesions can heal without an obturation), the amount of time a canal remains that way (clean) is time limited. A clean canal will likely become contaminated if the obturation is inadequate or the restoration fails. We chose the words in the title — to have and to hold — to emphasize the importance of having a clean canal and then holding it with an effective obturation for long-term success.

The goal of obturation — sealing a canal from post-treatment contami-

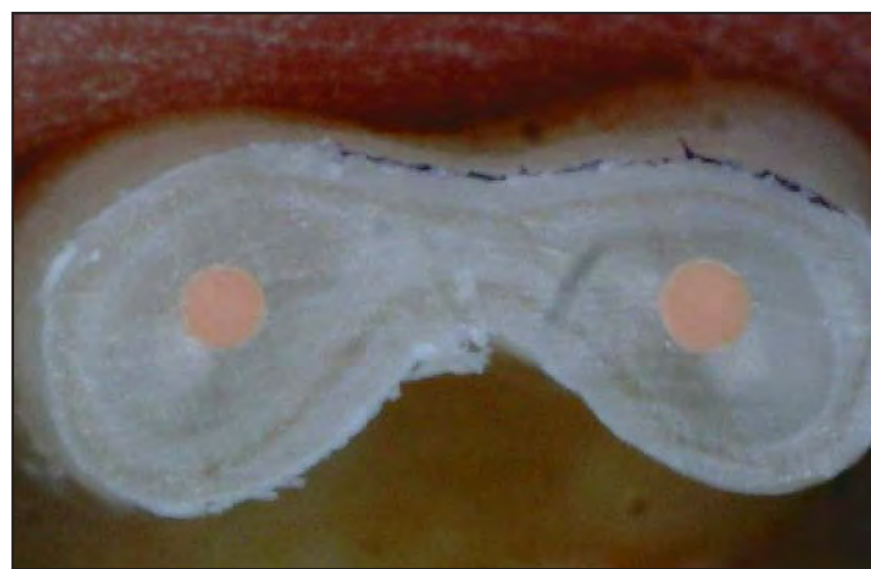


Fig. 1: SimpliFill (SF) obturation cross-section: The round canal prepared by LightSpeedLSX is the key to an effective seal with SimpliFill. The SimpliFill is pressed into the apical third with firm pressure; sealer is distributed by hydraulic forces around the SF and into any open spaces.

nation — is usually done with gutta-percha (GP) or Resilon (R) and sealer. The importance of sealer must not be underestimated. Without sealer there is no seal — it is the very reason why all techniques use sealer. Think of sealer as being similar to the gasket used where a garden hose connects to a faucet. If it is missing or

defective, the water will leak out at the connection — no matter how much it is tightened. Likewise, without sealer the filling will leak no matter how much it is condensed.

On occasions, we hear comments

→ **ET** page 2

Pulpal anesthesia: evidence-based decision making

By Stephen F. Schwartz, DDS, MS

One of the most stressful events in endodontic treatment is the inability to achieve total pulpal anesthesia. It is not only stressful for the patient but the dentist as well. Failure to obtain desired levels of anesthesia has a cascading negative effect on the procedure, the patient, the dentist and practice efficiency and productivity. In a referral practice limited to endodontics, all of these events are even more greatly amplified.

When we think of the inability to achieve the desired level of anesthesia, we are usually dealing with mandibular molars. The usual chain of events goes something like this:

1. Placement of topical anesthetic in the penetration zone for a traditional mandibular block for two to three minutes.

2. Delivery of 1.8 ml of our anesthetic of choice.

3. 10–20 minutes for the anesthetic to take effect.

4. Discovery either before or during the procedure of inadequate pulpal anesthesia.

5. Removal of the rubber dam and a second mandibular block or a

painful intra-pulpal injection or a PDL (intra-ligamentary) injection.

Assuming the second attempt is successful in allowing for pulp extirpation, the time involved is in excess of 45 minutes and the proce-

→ **ET** page 9

PRSR† STD
U.S. Postage
PAID
Permit # 306
Mechanicsburg, PA

Obturation

← **EI** page 1

about sealer being dissolved from canals. For this to happen would require a huge amount of saliva and the case would most likely fail anyway, even without the sealer dissolving. Sealer may be resorbed apically, but only when inflammation is present. However, a successful root canal begins the healing process. The inflammatory process subsides and sealer resorption does not occur. If sealer resorbed without inflammation, all root canal treatment would be in jeopardy.

mm from WL, it means the fit is correct. If the tip goes to WL without resistance, the SF is too small. Cut 1 mm off the tip or use the next larger size. If the SF meets resistance more than 4 mm from WL, it's too large and the next smaller size is used. Those with some experience usually skip this step, because SF consistently trial fits correctly.

After trial fitting, place sealer in the canal and on the SF. Use your sealer of choice, but do not use GP sealer with Resilon or Resilon sealer with GP. The carrier is advanced slowly to resistance and then the SF is pushed firmly to WL. Release the carrier from the SF with four complete counter-clockwise rotations. If the SF doesn't release and comes




Fig. 2: SimpliFill (SF): A 5 mm cone of gutta-percha or Resilon attached to a stainless steel carrier. The carrier is removed from the canal after SF is pressed into place, sealing the apical third of the canal. SimpliFill is available in sizes ranging from ISO 35 to 150 in 25, 31 and 50 mm (veterinarians) lengths.



Fig. 3: SimpliFill needle and syringe: an easy way to back fill behind SF. The needle's hub is filled with sealer that is syringed into the canal to the orifice. Then, one or more cones are placed for a continuous filling of gutta-percha (GP) or Resilon (R) from orifice to working length (WL).



Fig. 4: HotShot gun: cordless, fast and convenient for backfilling behind the SF. Needle gauges are 20, 23 and 25, either fixed or able to swivel 360 degrees. Swiveling allows the needles to be used in many cases (reducing the number of times it needs to be bent) before being discarded.

Obturation using SimpliFill®

SimpliFill (SF) is a tapered gutta-percha or Resilon cone cut to a 5 mm length. It is threaded onto the tip of a stainless steel carrier (Fig. 2) that serves to press the SF into the apical third. When the SF tip reaches working length (WL), the carrier is unthreaded and removed from the canal. SF is an effective seal because the apical canal shape prepared by LightSpeedLSX™ instruments is mostly parallel. Pressing the tapered SF into this parallel preparation is like pressing a cork into a wine bottle. The hydraulic pressures developed from the tight fit forces the sealer into any open spaces.

The SimpliFill technique

A SF Apical Plug matching the Final Apical Instrument Size (FAS) is trial fitted without sealer by setting the rubber stop at WL and slowly advancing SF in the canal until a slight resistance is felt. If resistance is felt (cone binds on walls) when the SF tip is between 2 mm and 4



Fig. 5: EndoPAX pluggers: two double-sided pluggers with four tip sizes — 50 and 70 and 90 and 120. They have a special coating called GTX, which keeps the GP/R from sticking to the plugger.

out with the carrier, it means the SF is too small. Use the next larger size.

The tight fitting SF fills the apical 5 mm and forces sealer into any existing voids. It's as simple as that — hence the name SimpliFill. It has been shown to be a rapid, simple and effective obturating system.¹⁻⁵

Once in place it does not require additional manipulation. The round cone tightly fits the round preparation made by the LSX, and the sealer takes care of any irregularities (Fig. 1). Also, the canal does not

→ **EI** page 4

EI Corrections

Endo Tribune strives to maintain the utmost accuracy in its news and clinical reports. If you find a factual error or content that requires clarification, please report the details to Mr. Fred Michmershuizen, managing editor, at f.michmershuizen@dtamerica.com.

Tell us what you think!

Do you have general comments or criticism you would like to share? Is there a particular topic you would like to see more articles about? Let us know by e-mailing us at feedback@dtamerica.com. If you would like to make any change to your subscription (name, address or to opt out) please send us an e-mail at database@dtamerica.com and be sure to include which publication you are referring to. Also, please note that subscription changes can take up to 6 weeks to process.

ENDO TRIBUNE

The World's Endodontic Newspaper · U.S. Edition

Publisher
Torsten R. Oemus
t.oemus@dtamerica.com

President
Eric Seid
e.seid@dtamerica.com

Group Editor
Robin Goodman
r.goodman@dtamerica.com

Editor-in-Chief Endo Tribune
Frederic Barnett, DMD
BarnettF@einstein.edu

International Editor Endo Tribune
Prof. Dr. Arnaldo Castellucci

Managing Editor Endo Tribune
Mr. Fred Michmershuizen
f.michmershuizen@dtamerica.com

Managing Editor Implant Tribune
Sierra Rendon
s.rendon@dtamerica.com

Managing Editor Ortho Tribune
Kristine Colker
k.colker@dtamerica.com

Product & Account Manager
Humberto Estrada
h.estrada@dtamerica.com

Advertising & Event Coordinator
Anna Wlodarczyk-Kataoka
a.wlodarczyk@dtamerica.com

Marketing & Sales Assistant
Lorrie Young
l.young@dtamerica.com

Director E-publishing & E-learning
Ovidiu Ciobanu PhD, MBA, DMD
ovidiu@doctor.com

Design Support
Yodit Tesfaye
y.tesfaye@dtamerica.com

Dental Tribune America, LLC
213 West 35th Street, Suite #801
New York, NY 10001
Tel.: (212) 244-7181
Fax: (212) 244-7185



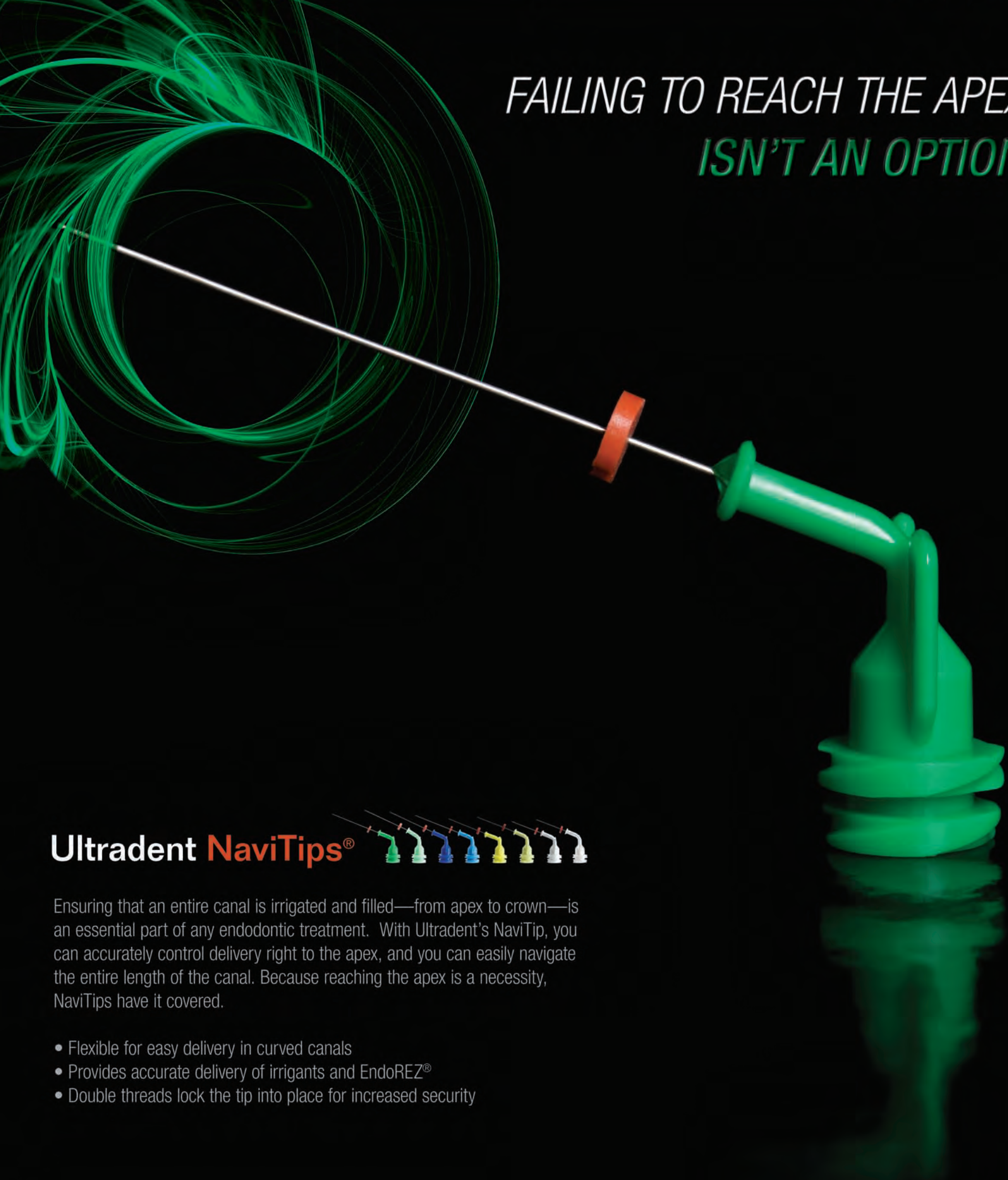
Published by Dental Tribune America
© 2008, Dental Tribune America, LLC.
All rights reserved.

Dental Tribune America makes every effort to report clinical information and manufacturer's product news accurately, but cannot assume responsibility for the validity of product claims, or for typographical errors. The publishers also do not assume responsibility for product names or claims, or statements made by advertisers. Opinions expressed by authors are their own and may not reflect those of Dental Tribune America.

Editorial Advisory Board

Frederic Barnett, DMD (*Editor-in-Chief*)
Roman Borczyk, DDS
L. Stephen Buchanan, DDS, FICD, FACD
Gary B. Carr, DDS
Prof. Dr. Arnaldo Castellucci
Joseph S. Dovgan, DDS, MS, PC
Unni Endal, DDS
Fernando Goldberg, DDS, PhD
Vladimir Gorokhovskiy, PhD
Fabio G.M. Gorni, DDS
James L. Gutmann, DDS, PhD (honoris causa), Cert Endo, FACD, FICD, FADI
William "Ben" Johnson, DDS
Kenneth Koch, DMD
Sergio Kuttler, DDS
John T. McSpadden, DDS
Richard E. Mounce, DDS, PC
John Nusstein, DDS, MS
Ove A. Peters, PD Dr. med dent., MS, FICD
David B. Rosenberg, DDS
Dr. Clifford J. Ruddle, DDS, FACD, FICD
William P. Saunders, PhD, BDS, FDS, RCS Edin
Kenneth S. Serota, DDS, MMSc
Asgeir Sigurdsson, DDS
Yoshitsugu Terauchi, DDS
John D. West, DDS, MSD

*FAILING TO REACH THE APEX
ISN'T AN OPTION*



Ultradent NaviTips®



Ensuring that an entire canal is irrigated and filled—from apex to crown—is an essential part of any endodontic treatment. With Ultradent's NaviTip, you can accurately control delivery right to the apex, and you can easily navigate the entire length of the canal. Because reaching the apex is a necessity, NaviTips have it covered.

- Flexible for easy delivery in curved canals
- Provides accurate delivery of irrigants and EndoREZ®
- Double threads lock the tip into place for increased security

SAVE 30% WHEN YOU PURCHASE A 50 PK

LIMITED TIME OFFER VALID 9/1/08 - 10/31/08 • CALL AND MENTION SOURCE CODE 8112

800.552.5512 ULTRADENT.COM

© 2008 Ultradent Products, Inc. All rights reserved.

ULTRADENT
PRODUCTS, INC.

← **ET** page 2

have to be highly tapered — weakening the root — to accommodate condensing instruments.

Backfilling techniques

After obturating the apical 5 mm, the remainder of the canal is ready for a post. Not having to remove filling material saves time and avoids the possibility of disturbing the apical seal. If a post space is not required, the remainder of the canal can be filled using one of the two following techniques.

SimpliFill Syringe:

The hub of a needle is filled with sealer and attached to the syringe (Fig. 3). The needle (ISO size #55) is advanced until it touches the top of the SF (or close to it) and sealer is expressed. When sealer fills the canal to the orifice the needle is withdrawn. Then, a standardized cone (also called a backfill cone), the same size as SF, is advanced through the sealer until it touches the top of the SF. Most dentists then add accessory cones as space permits. The result is a continuum of easily removed obturating material, making retreatment or post space creation much easier if required in the future.

HotShot™ Gun:

LightSpeed Technology (now Discus Dental) was the first company to introduce a cordless handpiece for NiTi rotary preparation. As a natural follow-up the company now offers a cordless obturating device, the HotShot (Discus Dental, Culver City, Calif.) (Fig. 4) that is used to fill the remainder of the canal with warm gutta-percha or Resilon. HotShot is not recommended for sealing the apical third, but it is a great supplement after SF is placed there. The HotShot gun is light, easy to handle, very easy to clean and uses needles that swivel 360 degrees, which makes filling difficult canals easier. It uses separate pellets instead of incorporating the filling material with the needle as with some designs, requiring discarding the needle when empty. HotShot needles can usually be used many times, reducing the cost. Swivel needles reduce the number of times it needs to be bent, which also adds to needle longevity.

Select a needle (available in gauges 20, 23, 25), attach it to the HotShot and bend the needle using the wrench provided. The 23 gauge needle is by far the most popular, followed by the 25 and then the 20 gauge. A pellet is loaded and the temperature set to 150° C for Resilon and either 180° C or 200° C for GP (depending on material and your preference). When HotShot reaches the desired temperature (about one minute) you are ready to begin.

Backfilling with HotShot is relatively easy, although there are a few technique nuances. The canal should have sufficient sealer remaining from

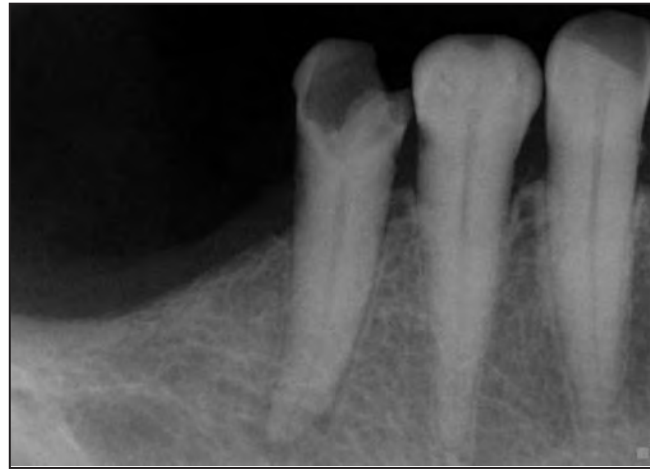

Fig. 6a: Pre-op.

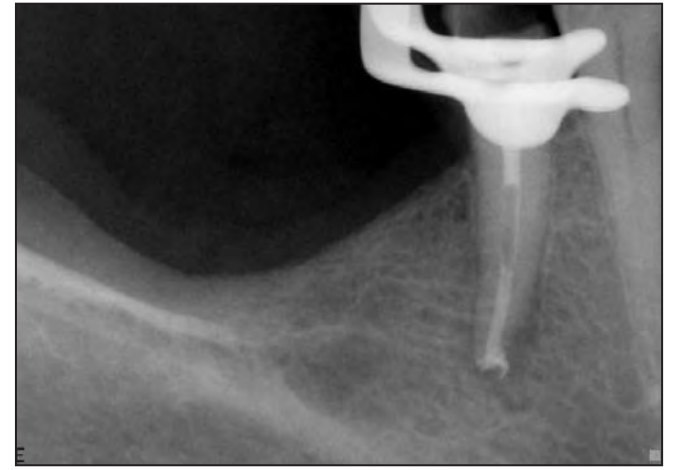


Fig. 6b: Immediately after placing SF.

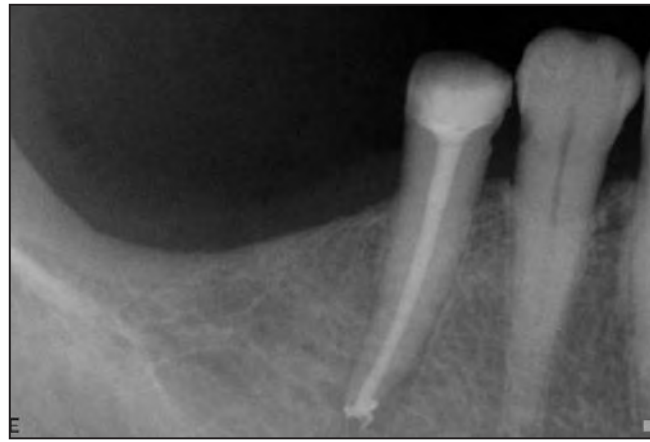

Fig. 6c: Final radiograph after composite filling.

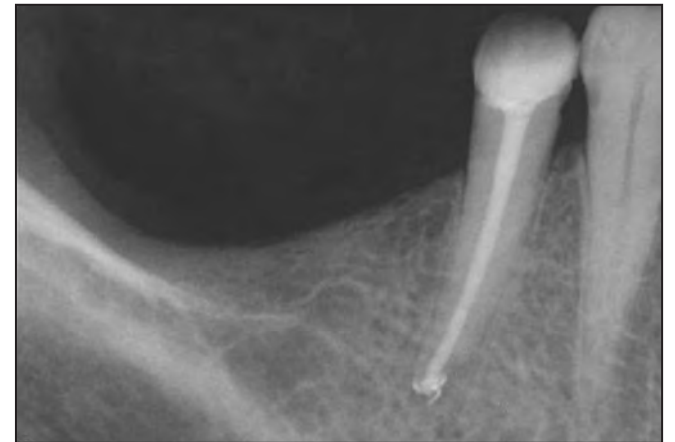

Fig. 6d: Three-month recall.

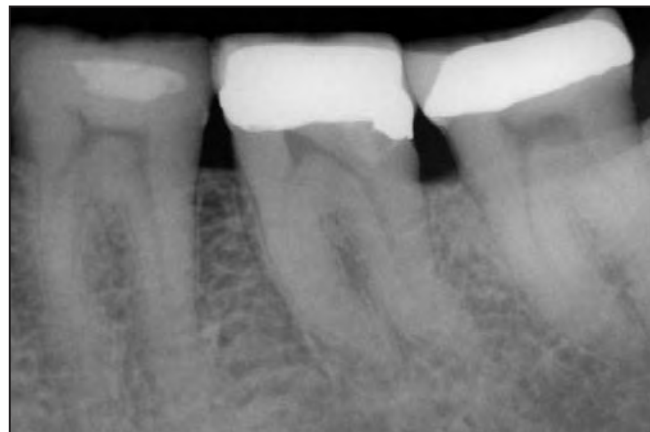

Fig. 7a: Pre-op.

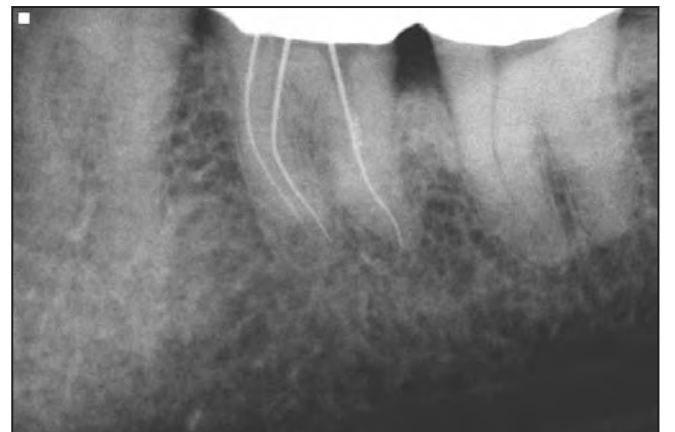

Fig. 7b: Working length determination.

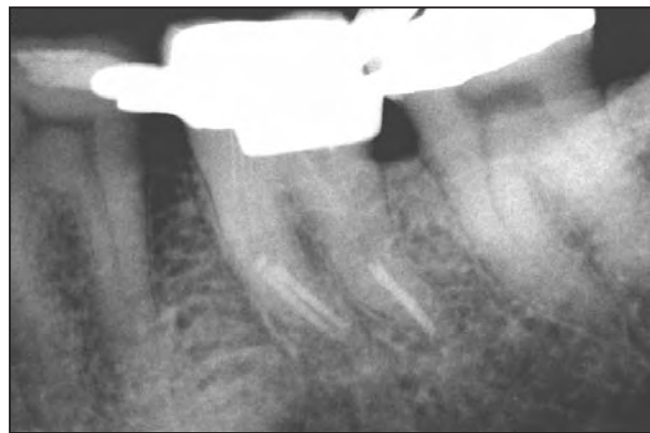

Fig. 7c: After placing SF.

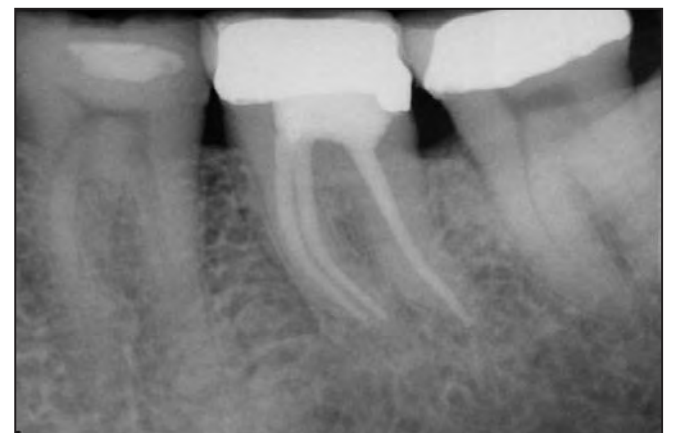

Fig. 7d: Final radiograph.

the SF step, but be sure to remove excess sealer with a paper point. Before entering the canal, express about 1 mm of the material (GP or Resilon) out the end of the needle and dip it in the sealer. Advance the tip of the needle (with GP/R still slightly beyond the tip) in the canal until it touches the top of SF. Leave it there for at least five seconds to fuse the new material with the top of the SF. Skipping this step can result in pulling the backfill-

ing material out of the canal when withdrawing the needle. Do not fill the entire canal in one step! Just fill about 2 to 4 mm and then withdraw the needle from the canal. At the end of the withdrawal, wipe the side of the needle against the side of the canal to remove excess material attached to it. Pack what was placed in the canal with the EndoPAX Pluggers (Discus Dental) (Fig. 5). Repeat until the entire canal is filled.

Cases — courtesy of Greg Goldfaden, DMD

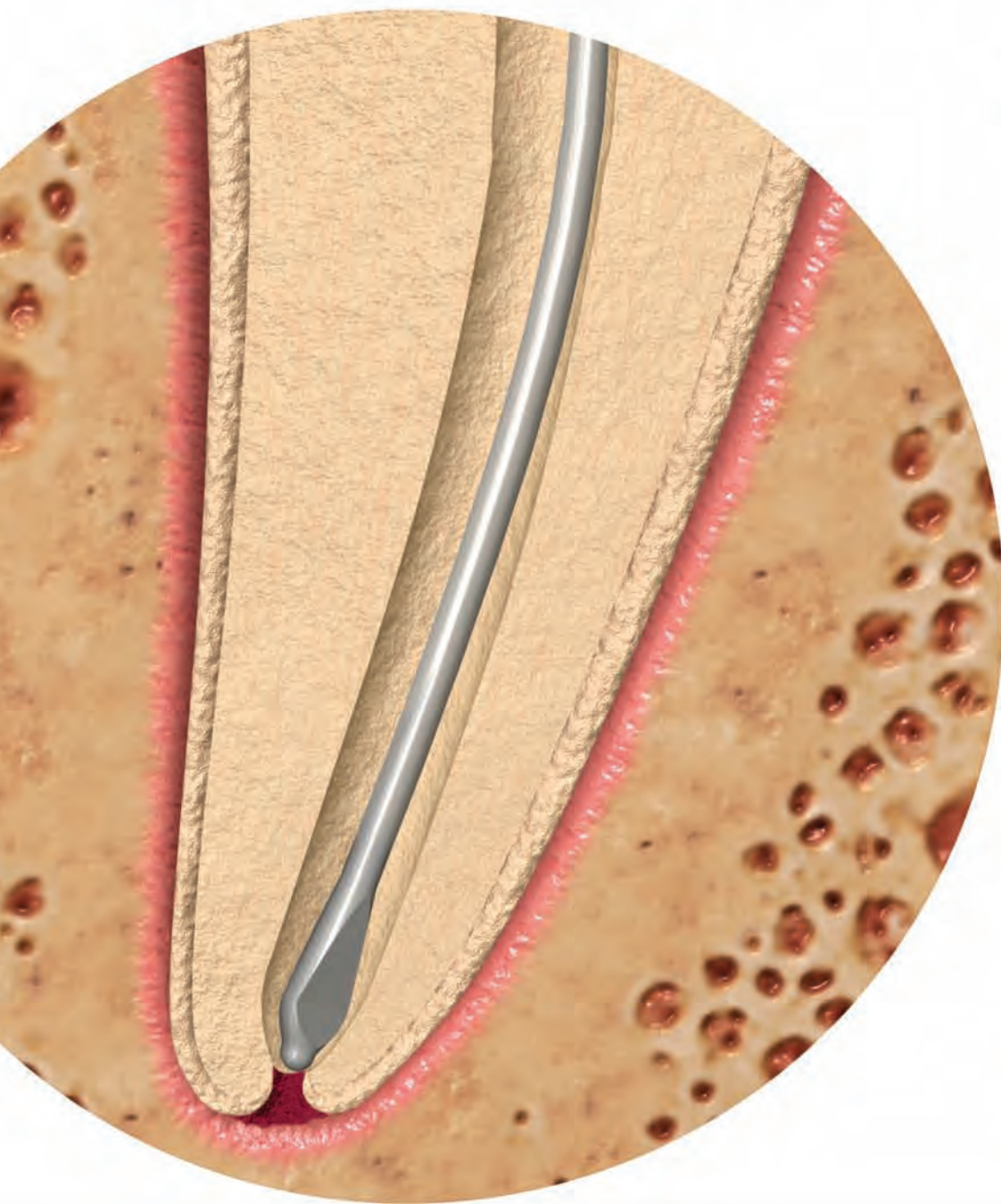
Case No. 1: Tooth #29

Diagnosis — pulp necrosis with chronic periradicular periodontitis. Instrumentation with LightSpeedLSX (Final Apical Preparation Size = #70); irrigation with EndoVac™, obturation with SimpliFill GP #70, SimpliSeal sealer; backfill with the HotShot Gun (Discus Dental) (Figs. 6a-6d).

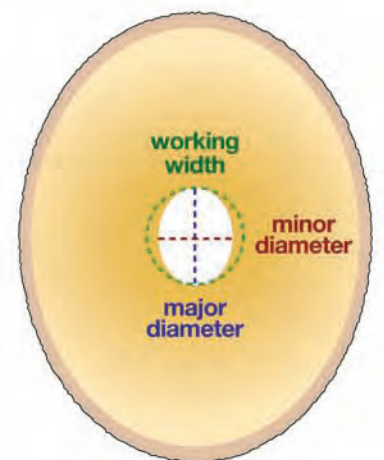
→ **ET** page 6

360° clean. 100% confidence.

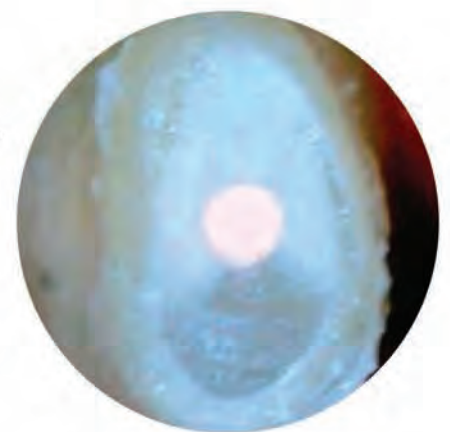Biologically Optimal Preparations™
that are safe, conservative and predictable.



Canals are oval, not round.
LightSpeedLSX™ addresses working length and working width... mastering the apical third.



The result:
A Biologically Optimal Preparation™. Note the perfectly round shape, complete absence of necrotic debris, and abundance of healthy dentin surrounding it.



cross-section 1mm from the apex

Call for your demonstration today:

800-817-3636

www.discusdental.com/endo

LightSpeedLSX™

EndoPAL™



Powerful and long-lasting.
The cordless EndoPAL™ handpiece delivers optimal speed and torque for LSX instrumentation.

EndoVac®



True apical negative pressure.
EndoVac® is the only endodontic root canal irrigation system that can safely and abundantly deliver irrigant to the apical 1mm.

SimpliFill®



The ideal apical seal.
Each 5mm SimpliFill® Apical Plug perfectly fits its corresponding LSX preparation size. Optimized by design and available in Gutta Percha & Resilon®.

HotShot™



Cordless. Clean. Thermoprotected.
Maximize your degrees of freedom with the HotShot™ gun – the ultimate in backfill obturation.

**Smart
ENDODONTICS™**

DISCUS DENTAL

← **ET** page 4

Once the canal is instrumented to working length with the Light-SpeedLSX Final Apical Size (FAS), an important step for proper fit of the SimpliFill Apical Plug is to create a “ramp” 4 mm short of working length with the next larger LSX. This helps guide the SF into place. Final irrigation and rinse using the EndoVac system does a great job of removing any remaining debris that may be left after instrumentation. After drying the canal, a SF Plug is selected to match the FAS (#70 in this canal).

If, for some reason, the SF does not fit properly, a different size can be selected. For example, if the SF is too small, it will not remain in the canal. Instead, when one tries to release it from the carrier, it will come out still attached to the carrier. If the SF is too large it will not reach full working length. While fitting issues are rare, I recommend trial fitting the SF until you gain experience and confidence with SimpliFill, which shouldn't be very long.

The canal is coated with Simpli-Seal sealer using paper points. The rubber stop on the SF carrier (Fig. 2) is set to working length (WL) and the SF coated with sealer. Slowly advance SF into the canal, pause at the resistance, then push with firm pressure until the stop reaches the reference point. I like to take a

check film to make sure I am happy with the placement of the SF (Fig. 6b). If, for any reason, SF does not fit to your liking, it can be removed very easily by inserting a Hedström file into the SF, turning it several clockwise turns (until the SF is engaged) and pulling SF out of the canal.

The canal is now ready for the backfill portion of the obturation. I use the HotShot Gun (Fig. 4). I like to get the HotShot needle as close to the top of the SF as possible. When in place in the canal, I express a small amount of warm gutta-percha and compact it with the Smart EndoPAX Pluggers (Discus Dental). I find that by doing small increments of the backfill at a time, it makes for a properly condensed canal with less of a chance for voids in the filling material. The increments should continue until the canal is fully obturated. In this case a composite filling was placed immediately (Fig. 6c). A three-month recall film (Fig. 6d) shows almost complete healing.

This case will always be special to me because it was my first case completed using the Smart Endo system and shows how quickly and easily the technique can be learned. The rapid healing is a true testament for the importance of thorough apical cleaning and the likelihood that it will increase our success rate.

Case No. 2: Tooth #18

Diagnosis — Irreversible pulpitis. Instrumentation with Light-SpeedLSX (FAS, MB = #50, ML = #50, D = #70; irrigation with EndoVac; obturation with SimpliFill GP) (Figs. 7a–7d).

As I began working on this case, I realized that the canal anatomy was more complicated than normal, so I took a working length film to visual-

ize the curves that were involved (Fig. 7b). After instrumentation, I irrigated using the EndoVac system and dried the canals using paper points. Sealer was placed in the canal and on the SF Plugs. In this case I used firm pressure when seating the plugs to make sure to negotiate all curves (Fig. 7c). The backfill was completed with the HotShot. A final film was taken to confirm complete obturation with no voids (Fig. 7d), and a composite filling placed. I have found that instrumenting and obturating all types of root canal anatomy, including difficult cases, can be achieved using the Smart Endo system.

Conclusion


Obtaining a clean canal is always the most important part of endodontic treatment. However, although it initiates the healing process, adequate obturation and restoration are necessary to maintain the cleanliness of the canal for long-term success (no recontamination). A simple, effective and predictable obturation technique is required to achieve this goal.

We wish to thank Steven S. Senia, BSIE, MBA, for his assistance with this article.

About the authors

E. Steve Senia, DDS, MS, BS

Dr. E. Steve Senia earned a DDS degree from Marquette University in 1965. He re-entered the Air Force (previously served as a pilot) and completed a GPR Residency. In 1969, he received a MS and Certificate in Endodontics from Ohio State University. He served in the Air Force and retired in 1981 as a colonel and chairman of endodontics at Lackland AFB, Texas. He then became professor and director of the Endodontic Postdoctoral Program at the University of Texas Dental School at San Antonio. He retired in 1992. Dr. Senia is a Diplomate of the American Board of Endodontics. He is a former member of the Editorial Board and the Scientific Advisory Panel of the Journal of Endodontics, an editorial advisor for the journal of Endodontic Practice and a consultant for the NASA Space Program. He has lectured and published extensively and is the co-inventor of the LightSpeed root canal instrumentation and SimpliFill obturation systems. You may contact Dr. Senia at DrSteveSenia@aol.com.



Greg Goldfaden, DMD

Dr. Greg Goldfaden, is in private practice in Aventura, Fla., specializing in endodontics. He graduated from Emory University with a BA in 1998. He received his DMD from the University of Florida in 2005, and his Certificate of Advanced General Studies in Endodontics from Boston University Goldman School of Dental Medicine in 2005. He is currently National Board Eligible and has completed the first stage of certification. You may contact Dr. Goldfaden at Grg5050@aol.com.



References

1. Maria D. Santos, William A. Walker, and David L. Carnes. Evaluation of Apical Seal in Straight Canals after Obturation Using the LightSpeed Sectional Method. *J Endodon* 1999; 25: 609–12.
2. Sadegh Namazikhah, Ramiar Shirani, Amir Mohseni, and Fariborz Farsio. Dye Leakage Study: Comparing Conventional and New Techniques. *Journal of the California Dental Association* 2000; 28 : 435–42.
3. Guy Shipper and Martin Trope. In Vitro Microbial Leakage of Endodontically Treated Teeth Using New and Standard Obturation Techniques. *J Endodon* 2004; 30: 154–8.

If you want to learn more about the SimpliFill Obturation Technique, call Discus Dental at (800) 817-3636 and ask for a free DVD with animations of the procedure.

AD

Sign me up for Endo Tribune!

I'm a GP	<input type="checkbox"/> please send <i>Dental Tribune</i> every other week (free!) <input type="checkbox"/> please send <i>Dental Tribune</i> every week for \$99/year and one free specialty: <input type="checkbox"/> Endo Tribune <input type="checkbox"/> Implant Tribune <input type="checkbox"/> Ortho Tribune
I'm a specialist	<input type="checkbox"/> please send the monthly newspaper for my specialty (free!) <input type="checkbox"/> please send a monthly newspaper for a different specialty @ \$59/year <input type="checkbox"/> Endo Tribune <input type="checkbox"/> Implant Tribune <input type="checkbox"/> Ortho Tribune

Name _____	Phone _____
Address _____	E-mail _____
_____	Signature _____
City, State & Zip _____	Date _____

Payment via: <input type="checkbox"/> Check <input type="checkbox"/> Mastercard <input type="checkbox"/> Visa <input type="checkbox"/> AMEX	Please remit payment to: Dental Tribune America LLC 213 W. 35th Street, Ste. 801 New York, NY Tel. (212) 244-7181 Fax (212) 244-7185
Card #: _____	

For more information, please contact us at database@dtamerica.com

For a **free online subscription** to the newspaper of your choice, please provide a valid e-mail address. Subscribers will occasionally receive e-mail newsletters filled with info about events, products, technology and general news.

Trends in endodontic shaping

By Barry Lee Musikant, DMD, and Allan S. Deutsch, DMD

If the major manufacturers of endodontic instruments had their way, the entire discussion of instruments would be limited to which rotary NiTi system works best. They have tried to make it a given that rotary NiTi in one form or another is truly the only way to go. However, underneath that doctrinaire exterior lie clues to the fact that rotary NiTi cannot be the entire story. Consider the following:

- A glide path is an absolute essential prior to the use of rotary NiTi.
- Straight-line access by means other than rotary NiTi is strongly recommended.

- The recognition that abrupt apical curves must be addressed by means other than rotary NiTi.

In addition, the following precautions are strongly recommended:

- Single use of the instruments.
- Recapitulation in the presence of any apical resistance.
- The practical limitation of tip size and taper of rotary NiTi as the canals become more curved, not necessarily related to the needs of canal shaping.

- That they all be used with an expensive, torque-sensing electric handpiece.

Furthermore, even more recently, the initial shaping of canals traditionally done manually has had its options expanded by the recognition that a reciprocating handpiece can be a useful tool and an alternative to the initial manual shaping of canals by K-files.

It is the intent of this article to produce a series of rational options that will make endodontics as it is now being marketed safer, more efficient, far less costly and far less taxing to learn and master. In that quest we will show the following:

- That reamers are more efficient than K-files or any other type of file.
- That relieved reamers are more efficient than non-relieved reamers.
- That relieved reamers produce a superior tactile sense compared to K-files.
- That engine-driven reciprocation combined with relieved reamers can shape canals distortion-free very rapidly.
- That the substitution of reciprocation for rotation eliminates the two main causes of instrument breakage, namely torsional stress and cyclic fatigue.

- Taper lock, the main cause of torsional stress, is virtually eliminated by the use of a 30-degree reciprocating handpiece.

- That reciprocation is so atraumatic to the instruments that they can be used many times without concern for breakage.

- That the multiple use of robust instruments used in an atraumatic fashion will reduce the cost per use of these instruments compared to rotary NiTi by about 90 percent.

- That relieved reamers, predominantly stainless steel, used in a reciprocating handpiece become a rational choice over the use of rotary NiTi.

Why would anyone think that reamers are superior to K-files? If the answer were so obvious, why have the vast majority of graduating dentists still learned to initially shape canals with K-files? We suspect the answer is equal parts inertia and lack of focus, but before that statement can carry any weight we must first prove convincingly that what we are saying makes sense.

K-reamers and K-files both have working lengths of 16 mm. Within

that working length K-files have 50 flutes while reamers have 16 flutes (Fig. 1). If both reamers and files are made from a square wire, it follows that each flute has four contact points. If 50 flutes are present then there will be a total of 120 contact points for the K-file while the 16 flutes of a reamer will produce 64 contact points. Logically, the less the engagement along length the less the resistance to apical negotiation. This being the case, we must conclude that ream-

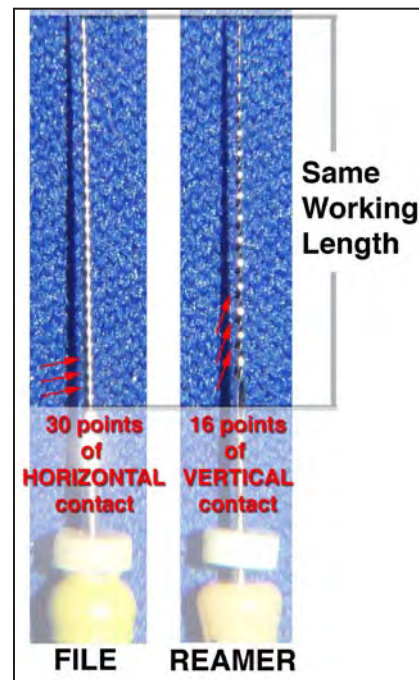
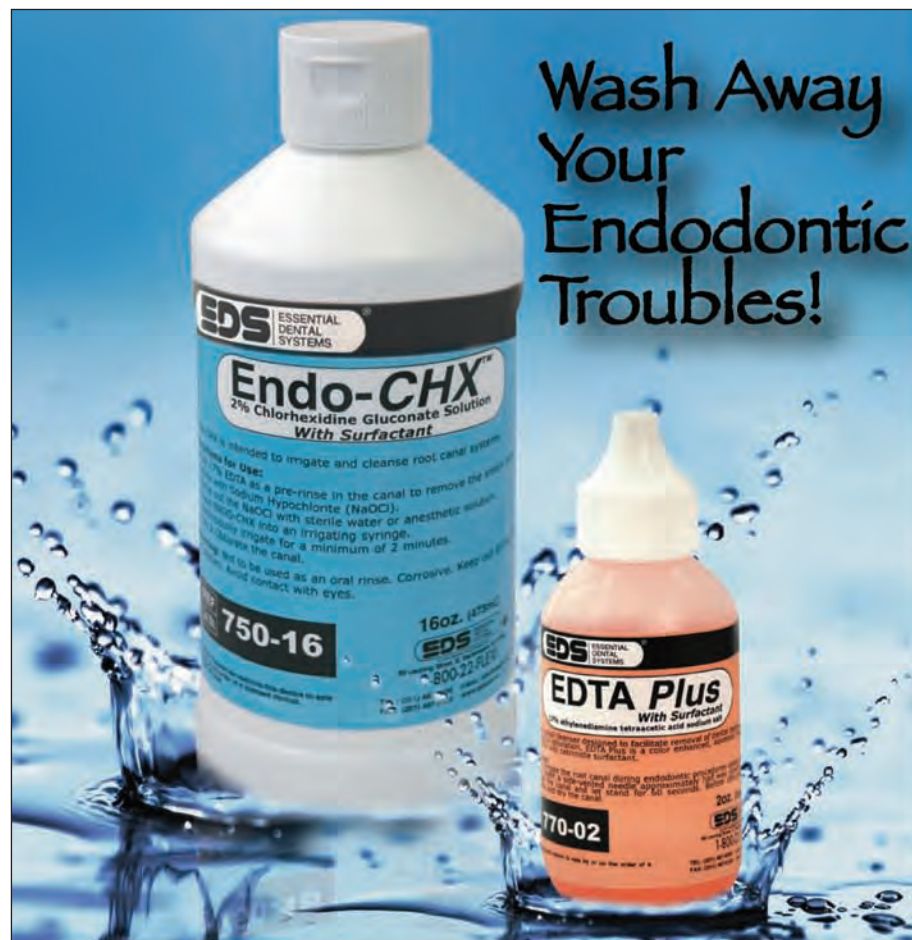

Fig. 1: K-files have 30 flutes, while reamers have 16 flutes.



Endo-CHX™ is the only 2% chlorhexidine cleared by the FDA for endodontic use. Irrigate and cleanse your root canal at the same time.

17% EDTA Plus™ removes the smear layer and opens the dentinal tubules.

Conditions canal walls for sealer & cement penetration and increased fiber post retention.

Both products contain a surfactant to reduce surface tension and improve irrigant penetration into the tubules. They are color enhanced to ensure easy recognition during the irrigation procedure.



89 Leuning Street • S. Hackensack, NJ 07606
800-22-FLEXI • 201-487-9090
Fax: 201-487-5120 • www.edsdental.com

Fearless Engine Driven Endodontics

Challenge yourself! A hands-on experience that teaches techniques to achieve the results you read about:

Learn to use instruments and proper irrigation that efficiently shape the canal without any fear of separation.

Learn to create complete three dimensional obturation with simple, inexpensive, and predictable techniques.

Learn in an environment that lets you use microscopes, ultrasonics, specialty burs to access and find canals.

See a series of 3D access photos that will clearly let you experience the depth and feel of endodontic access.

After taking this course, you will know what it takes for you to get better at a discipline of dentistry that is rewarding both as an art form and financially.

Dr. Musikant and Dr. Deutsch introduce logic & common sense that is undeniable. Their "less talk, more action" approach to educating through extensive hands-on participation is refreshing.



Additional Dates Available.

Visit: www.essentialseminars.org

Call: 1-888-5-Hands-On

or visit www.essentialseminars.org for complete course info and registration.


Courses are limited to dentists only. When contacting Essential Dental Seminars, please ask for Ms. Ginger Pterro. Essential Dental Seminars is a division of Essential Dental Systems, Inc. Cancellation Policy: Cancellations up to five full business days before the date of the seminar will incur a 50% cancellation fee. If notification of cancellation is received after 5 days of the seminar, no refund will be issued. Essential Dental Seminars reserves the right to cancel any course at any time. If Essential Dental Seminars deems it necessary to cancel a course all registered participants will be notified and tuition fees will be refunded in full. All refunds are limited to the tuition fee.

Essential Dental Seminars presents "The Safe Side of Engine Driven Endodontics":

Location: Essential Dental Seminars
89 Leuning St.
South Hackensack, NJ 07606
Date: Nov. 7-8, 2008

Time: 8:30 am - 6:00 pm.

Fee: \$1195.00 17 CE Credits



Approved PACE Program Provider
FAGDMAGD Credits
Approval does not imply acceptance
by a state or provincial board of
dentistry or AGD endorsement.
5/31/2008 to 5/31/2012

ers are superior to files given the goals we wish to achieve with them. Furthermore, the fewer the flutes the more vertically oriented the flutes, which then cut more efficiently when the motion is a horizontal watch winding or reciprocation. Again, the reamers with 16 flutes have flutes that are about twice as vertical as those on a K-file with its 50 flutes. In addition, the fewer the flutes the less work-hardened the instrument, making one with half the number of twists about twice as flexible.

The blades on any instrument become more effective the closer the cutting action is perpendicular to the plane of motion. Horizontal motion calls for vertical blades just as vertical motion would call for horizontal blades. Today, we no longer emphasize vertical motions for shaping because they tend to produce apically impacted debris.

With reduced resistance to engagement, greater ease of shaving dentin off the canal walls and superior tactile perception of what the tip of the instrument is encountering, the reamer performs better than all file designs. This superior tactile perception combined with a 30-degree reciprocating engine (Fig. 2) allows the incorporation of a cutting tip that while having the ability to pierce tissue rather than impact it, cannot make its own pathway unless obviously excessive force is applied.

Every advantage that accrues to reamers is accentuated when the reamers are relieved along length. There is less engagement along length that enhances the ease of apical negotiation and the instruments are even more flexible, which together further improve tactile perception. Shaping using a reciprocating handpiece or manual watch winding motion is very similar to the balanced force technique, which gives the dentist the ability to shape significantly curved canals using stainless steel reamers and files. By keeping the apical third of the canal free of debris, the relieved reamers can be used to shape complex apical anatomy. By instrumenting 1 mm over the apex through a size 20, we establish an exit for any debris that is not removed coronally.

Experience has shown that this debris has little potential for producing postoperative pain and the extended reamer is never taken so far that it hits the ligament. We must remember that the correct length through complete instrumentation is the apical constriction that is most often a good millimeter or more from the PDL. With the canals in the apical third free of most of the debris, the balanced force produced either manually or by the reciprocating handpiece will shape complex anatomy distortion free.

Because separation is not a concern, the shaping can routinely be taken to a minimum of 35, allowing for a diameter that the literature says is the minimum dimension compatible with efficient irrigation.

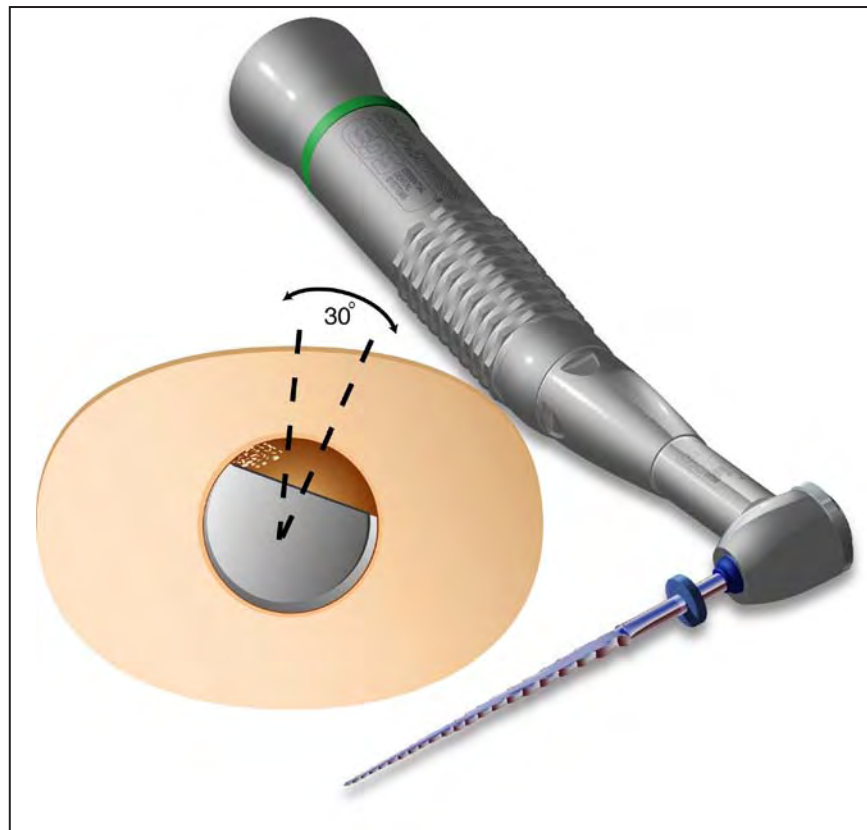


Fig. 2: Superior tactile perception is combined with a 30-degree reciprocating engine.

Relieved reamers are asymmetric instruments that have the capability of helping the dentist distinguish between a round and oval canal. This is not a trivial pursuit. Many canals have a bucco-lingual dimension that is two to three times the mesio-distal width. If not aware of this, an apical preparation that is inadequate in mechanical removal may result while not allowing a wide enough preparation for adequate irrigation to compensate for the less than adequate mechanical debridement.

Just like rotary NiTi, a system based on relieved reamers powered by a 30-degree reciprocating handpiece is constantly improving and refining itself. Today, we do most of our initial instrumentation with 17 percent EDTA flooding the canals. EDTA is a chelating agent as well as a mild acid. Together these two properties soften the walls of the dentin, allowing for even easier penetration of the canal length.

From a practical point of view, the problems long associated with rotary NiTi are never a concern when relieved reamers coupled to a reciprocating handpiece are substituted. Instruments, for all intents and purposes, do not break. It is not a consideration. This alone makes them an interesting option for anyone who has faced "separation anxiety." However, the virtual elimination of breakage is only one aspect of its advantages. Having a system predominantly composed of relieved reamers offers the additional following advantages:

- They are routinely used many times, with dullness — not fear of separation — being the reason they are replaced.

- Because they are significantly less expensive than rotary to start and are then used a minimum of six to seven times, they are anywhere

from 10 to 20 times less expensive on a per-use basis.

- Because of their superior tactile perception, the dentist can differentiate between a tight canal and hitting a wall.

- Because they are asymmetric along length they can differentiate between a round and oval canal, telling the dentist when he must widen the canal more to compensate for the larger bucco-lingual diameter of the canals.

- Because they are composed mainly of stainless steel reamers they can easily be pre-bent to conform to the most abrupt apical

curves that may be present.

- Used with 17 percent EDTA, the glide path is rapidly shaped through a 35 to the apex and 40 1 mm short. In fact, we do not differentiate between glide path creation and the final shaping of the canal. It is all one seamless continuous process.

- A 35 apical preparation assures the dentist that adequate irrigation with NaOCl, 17 percent EDTA and 2 percent CHX can be accomplished.

- Even in the most difficult canals it rarely takes more than two to five minutes to shape a canal to completion from the time the measurement was taken with the apex locator.

- While the complete shaping sequence comprises 10 instruments, as one becomes experienced with this system these steps can often be truncated down to four to five instruments with no increase in separation concerns.

All these advantages are based on reamers that negotiate through canals with far more ease than any file design and the power of balanced force that is inherently incorporated into a handpiece that produces a rapid 30-degree reciprocating motion. By following these simple principles we have done away with the need for awesome new and very expensive technologies that keep trying to fit a square peg (rotary NiTi) into a round hole (safe, rapid and predictable shaping).

As is always the case, the claims we make for this alternative way of doing safe, effective, economically sound endodontics are subject to your evaluation. We expedite your ability to make those evaluations by offering endodontic workshops. For more information please call (888) 542-6376.

About the authors

Barry Lee Musikant, DMD and Allan S. Deutsch, DMD

Dr. Musikant (right, above) and Dr. Deutsch are co-directors of dental research and co-founders of Essential Dental Systems (EDS), a dental products manufacturing company located in South Hackensack, N.J. The company's roots stem from the desire for product improvements to the items of focus in their lectures and daily practice. Dr. Musikant's and Deutsch's lecture schedules have taken them to more than 400 international and domestic locations.

They have co-authored more than 250 articles in dentistry in various major international and U.S. dental journals. As partners in the largest endodontic practice in Manhattan, their combined 60-plus years of practice experience have crafted them into top authorities in endodontics.

You may contact Dr. Musikant or Dr. Deutsch at info@edsdental.com.



Anesthesia

← ET page 1

cedure has only just begun. The inefficiency in this scenario does not consider the loss of confidence by the patient, the stress on the patient and the doctor, the disruption of the office schedule and the financial cost attendant to decreased efficiency.

Now let's examine the same scenario utilizing intraosseous anesthesia (IOA). Intraosseous anesthesia involves an injection that penetrates through the gingiva and cortical bone and then the anesthetic solution is delivered into the underlying cancellous bone (Fig.1). There are devices on the market such as the X-tip™, Stabident and IntraFlow™ (Fig. 2) to facilitate this type of injection. IOA from an evidence-based perspective has in excess of an 85% success rate for total pulpal anesthesia as demonstrated by numerous studies¹⁻⁵, while the mandibular block enjoys a statistically significant lower success rate⁶⁻⁹, using the same criteria of success. The intraosseous injection could have been utilized as either the primary or secondary route of administration in the first scenario. If used as the primary, the odds of successful pulpal anesthesia would have been increased¹⁰ and the procedure could have been started within five minutes post injection with the added benefit of no lip numbness for the patient. As a secondary injection given immediately after the mandibular block, the advantages gained would be lingual anesthesia, even greater odds of total pulpal anesthesia and almost immediate initiation of treatment. The time saved would have been significant, but more importantly the procedure would have been less stressful to both the patient and the dentist and would have resulted in almost immediate pain relief for those patients presenting with an acute pulpitis.

In examining the reasons why intraosseous anesthesia, clearly the obvious choice in evidence-based decision making, is not more widely used, we must look first to our dental schools. Anesthesia in most dental schools is taught by the oral surgery department. These very well-trained individuals have virtually no need for pulpal anesthesia for endodontic or restorative procedures and therefore are more familiar and comfortable with block and infiltration techniques. A second reason is the comfort level or fear expressed by the average practitioner with an injection that penetrates the bone. Based on this fear, many would rather opt for the more traditional intraligamentary or PDL injection. From an evidence-based perspective, this route of administration enjoys a lower percentage of

success¹¹ and can have the negative effect of patient discomfort and the potential for driving bacteria and pocket contents deep into the periodontal ligament space with unintended consequences and a low probability of total pulpal anesthesia. It has been found that IOA has on average about a 15-20 minute maximum pulpal anesthetic effect, while the duration and pulpal anesthetic effect of PDL injection is much shorter and less profound. It has recently been shown that an additional IO injection can extend the maximum effect of the anesthesia for an additional 15 minutes.¹²

If we are going to continue to meet our patients' needs and expectations while practicing in an environment of evidence-based decision making, we must change that

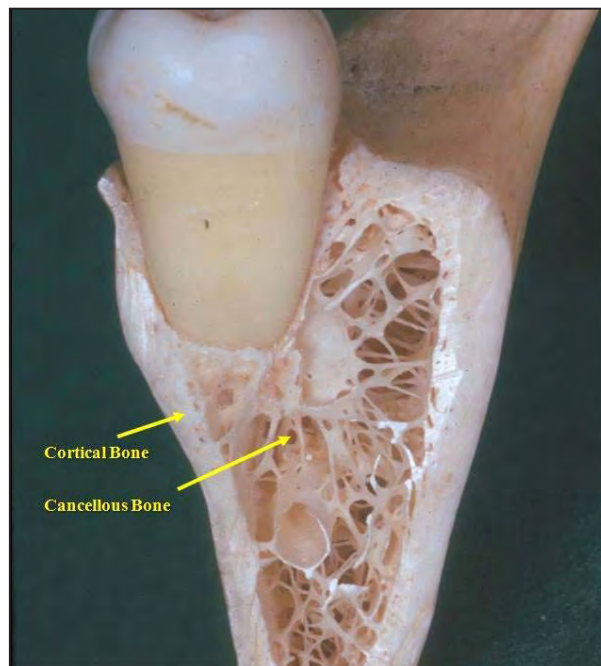


Fig. 1: Mandible cross section.

AD

GOLDEN MISCH
physics
forceps

simple • predictable • non-surgical

DENTISTRY TODAY
TOP 100
PRODUCTS 2007
★★★★★

DENTISTRY TODAY
TOP 100
PRODUCTS 2008
★★★★★

Take advantage of our
90 day trial period

Visit us at CDA in
San Francisco
Booth# 1035

**Call now and mention
this ad for a FREE DVD.**
1 877 987 2284

learn more about the physics forceps at
GOLDENMISCH.COM

Coming this Fall
4 credit course on
Atraumatic Extractions
by Golden Misch

ADVANCEMENTS IN DENTISTRY

Supporting Comments for the New Extraction Forceps



Anthony S. Feck, DMD

I have never looked forward to doing extractions in my practice. It can take just a few minutes or more than half an hour if I hear that dreaded 'cracking' sound indicating I have broken a crown or a root. Since using the Physics Forceps *that* sound is a thing of the past. These new forceps don't rely on brute force, but rather, use the simple concept of leverage. Instead of grasping, pushing, twisting and pulling the clinical crown, this technique employs a slow, steady rotational force that literally rolls the tooth free from the PDL. Seldom do new innovations come along that truly revolutionize the way a dentist approaches a service – this is one!



Louis Malcmacher, DDS, MAGD

Faster, easier and better - these are the three magic attributes that I look for whenever I evaluate new products. The GoldenMisch Physics Forceps are by far one of the greatest advancements I have seen in exodontia in my 28 year career. Using these unique instruments greatly reduces buccal bone loss during the extraction, making implant support and esthetic success much more predictable. The amount of time, effort and frustration saved is incredible, especially with challenging teeth. The Physics Forceps are an absolute must for every dental practice and I highly recommend them in my lectures.