

## Direct pulp capping with MTA: a case report

By Arnaldo Castellucci, MD, DDS

### What did we know before MTA?

On no other subject in dentistry has there been as much written and discussed as the maintenance of the vitality of an exposed pulp. Everything, including the droppings of the

English sparrow,<sup>8</sup> has been tried.

At the beginning of the century, to avoid extirpation at all costs, any attempt at maintaining the vitality of the pulp was justified, because there was no way to perform proper endodontic therapy and the success rate was higher after pulp capping as compared to pulpectomy and canal treatment.

Today, however, given the abundant research that has been performed, such an attitude is no longer acceptable. The exposed pulp horn must no longer produce the same fear that it did 50 years ago.

Herman<sup>5</sup> first introduced the use of calcium hydroxide in such cases, and Teuscher and Zander<sup>27</sup> first described the formation of the dentin bridge below the treatment. Using labeled radioactive calcium, Pisanti and Sciaky<sup>19</sup> demonstrated that calcium hydroxide does not participate actively in the formation of the dentin bridge, and concluded that the calcium of the dentin bridge came from the bloodstream only.

Via<sup>36</sup> noted that after 24 months 68.9 percent of the cases that he had treated with calcium hydroxide had failed, primarily as a result of internal resorption.

Ostrom and Lyon<sup>17</sup> and Quigley<sup>22</sup> also reported high failure rates, in addition to the observation of zones of pulp degeneration below the dentinal bridges.

Mitchell and Shankwalker<sup>14</sup> have described the intense calcification that occurs in the pulp tissue following such treatment. This phenomenon has also been described by Baume.<sup>3</sup> The quality and quantity of newly formed dentin is unpredictable.<sup>21</sup> Other authors<sup>14,18</sup> have shown that the radiopaque zone observed beneath the site of exposure cannot always be related to the calcific barrier. Tziafas and Beltes<sup>35</sup> have also demonstrated that many radiopaque zones are in fact zones of necrosis present beneath the capping material. The radiopaque quality of these zones can be attributed to impregnation with calcium salts, which derive at least in part from the capping agents.<sup>7,26</sup>

From these and other similar research, it is clear that, independent of the size of the exposure, pulp capping, when performed in a desperate attempt to maintain the vitality of a condemned pulp, is not only an unpredictable procedure with an uncertain prognosis, but it is also dangerous, because it may cause internal resorption, calcific pulp degeneration, or both. This may make routine endodontic therapy difficult, if not impossible, even though it will

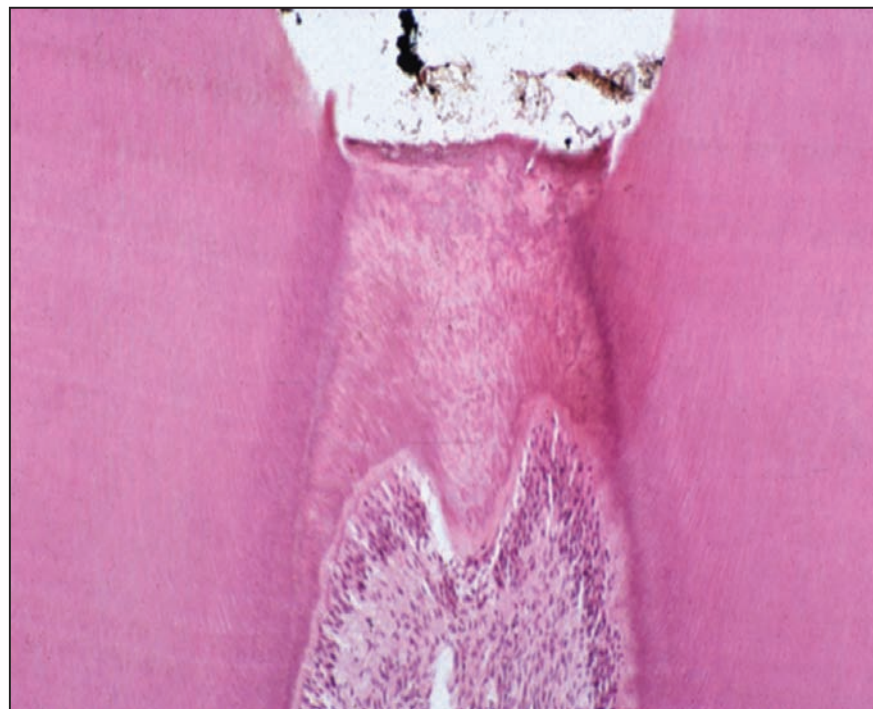


Fig. 1: Histologic appearance of a pulp capping procedure. The MTA is at the top of the picture. Vital pulp tissue is surrounded by normal dentin. Between the two is the dentin bridge, which has formed after the placement of the ProRoot MTA. (Courtesy of Dr. M. Torabinejad).

shortly be necessary.<sup>15</sup>

Weine<sup>37</sup> states that calcium hydroxide is the material of choice in direct pulp capping, but if such therapy fails and the tooth becomes symptomatic, it may be difficult, if not impossible, to treat it by traditional endodontics because of severe calcifications in the root canal, which are frequently associated with internal resorption, as described also by other authors.

Seltzer and Bender<sup>25</sup> concur with Weine in stating that sometimes, notwithstanding the formation of the dentinal bridge, the remaining pulp is chronically inflamed and can be-

come necrotic. Internal resorption has been found in at least 33 percent of the teeth treated with pulpotomy and calcium hydroxide. In others, complete mineralization with the disappearance of the remaining pulp tissue has been reported. Such mineralization may obstruct the canal at such a point as to complicate its instrumentation if endodontic therapy becomes necessary in the future.

What makes pulpotomy or pulp capping with calcium hydroxide dan-

→ **ET** page 2

### Inside this issue

#### ESMD to hold its first magnification congress

"To See or Not to See" is the theme for the first Congress of the European Society of Microscope Dentistry (ESMD). The event, for those who are interested in worldwide innovations in the use of magnification techniques in dentistry, will be held Sept. 18-20 in Amsterdam.

Page 8

#### AMED plans its seventh microscope meeting

The Academy of Microscopic Enhanced Dentistry (AMED) will take the technology of the dental microscope to the next level at Summit of the Masters, its seventh annual Meeting & Scientific Session, to be held Oct. 30 to Nov. 1 in Scottsdale, Ariz.

Page 8

#### Medidenta offers cordless thermal condenser



The Endotec II from Medidenta is a cordless thermal endodontic condenser that makes warm lateral condensation easier and faster and provides superior adaptation to the canal wall. It is touch activated for precise temperature control and has a patented tip that fits curved canals and provides calibrated and rapid heating.

Page 10

### Safe, efficient and predictable canal instrumentation with the Twisted File

Dr. Richard Mounce will offer an hourlong Webinar covering the design, manufacture, capabilities, sequence and indications for the Twisted File (TF), followed by a real-time question-and-answer session, on Sept. 9 at 7 p.m. EST. Participants will earn one unit of continuing education credit. The fee is USD \$95. At the end of the Webinar, the participant should be familiar with:

- The biologic objectives of root canal therapy.
- The importance and methods of effective bio-mechanical cleansing of the root canal system.
- Effective rotary nickel titanium file utilization with the Twisted File and prevention of iatrogenic events.

As a participant, you require nothing more than an online computer with audio. After viewing the live event, you will have access to the archived presentation for 30 days.

To register, visit: [www.dtiinstitute.com/webinar/Twisted-File/](http://www.dtiinstitute.com/webinar/Twisted-File/).



## MTA

← **ET** page 1

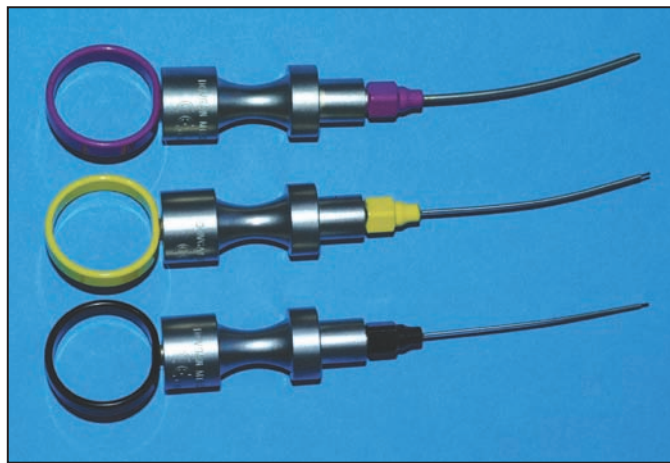
gerous is that the pulp tissue is in some way stimulated to become isolated from communication with the outside and thus form the dentinal bridge without knowing when to stop making these calcific depositions. The process of apposition, which is known to be associated with resorption, therefore continues.

Schultz et al.<sup>24</sup> claim that "exposure of the pulp tissue that occurs during the preparation of the cavity requires a decision as to whether it is better to attempt capping of the pulp or to treat the tooth endodontically."

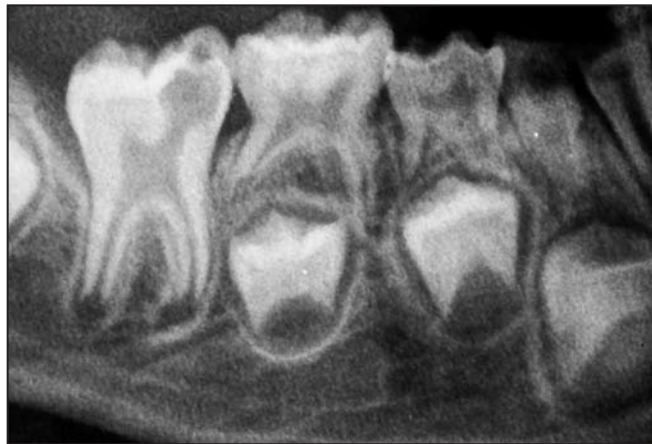In a histological assessment of the success of vital pulp therapies, Mulaney<sup>15</sup> emphasizes the importance of examining serial sections, since the dentin bridge is often incomplete and areas of necrosis are frequently present. He also notes the shortcoming of radiographic examination when used as the sole method of assessing success, since sufficient information regarding the



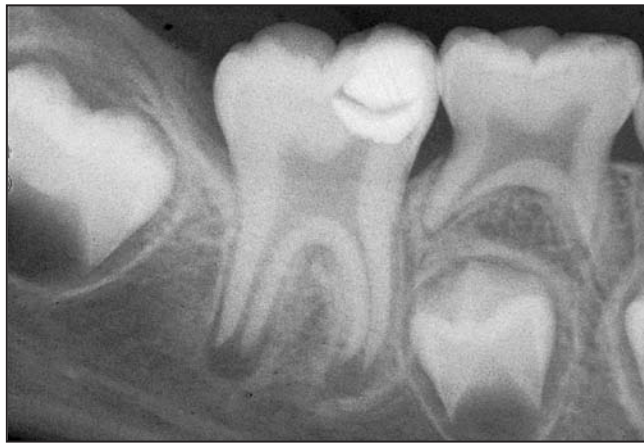**Fig. 2: White ProRoot MTA (Dentsply Tulsa Dental, Tulsa, Okla.).**



**Fig. 3: The Dovgan carriers, specifically designed for MTA (Quality Aspirators, Duncanville, Texas).**



**Fig. 4a: The radiograph shows the first molar only partially erupted (with the mesial cusps) and with a deep decay involving the pulp. The tooth is completely asymptomatic and responds to vitality tests. Note the immature apices.**



**Fig. 4b: Postoperative radiograph: the decay has been removed and MTA has been gently positioned over the pulp exposure.**

completeness of the dentinal bridge cannot be obtained.

Tronstad and Mjor<sup>54</sup> also state that, although the formation of the dentinal bridge has been used as one of the criteria of the success of direct pulp capping, it can also occur in teeth with irreversible inflammation.

Nevertheless, when the decision is made to undertake such therapy<sup>37</sup>

- because of the poor endodontic skill of the dentist,
- because of the anatomical challenges presented by the tooth and the dentist's inability to overcome them, or
- because the patient is unable to afford the fee,

the following criteria must be carefully confirmed:

1) The tooth must not be sensitive to heat or cold, nor must there be spontaneous pain.

2) There should be no pain on palpation or percussion.

3) There should be no periapical radiographic change.

4) Marked narrowing of the pulp chamber or root canal should not be present.

5) There should be no calcifications in the pulp chamber.

6) There should not be the slightest suspicion of bacterial infection, since asepsis is the most important factor in pulp healing following exposure.<sup>9</sup>

The indications for direct capping are therefore drastically reduced to the following:

a) The patient should be young and well motivated, so that he/she will easily return for checkups and necessary radiographs.

b) The exposure must be in healthy dentin and not below caries, and therefore not in infected dentin.

c) The maintenance of strict intraoperative asepsis is mandatory.

d) The pulp chamber must be free of calcifications, which occupy space and reduce the blood supply

to the pulp tissue which must heal.

Finally, Langeland<sup>12</sup> is also clearly opposed to indirect capping, which he calls an unacceptable procedure. The reasons for its apparent success, as for direct capping or pulpotomy, are due to the removal of most of the disintegrated tissue, but the technique is destined to fail because of the presence of bacteria and sometimes a small zone of pulp necrosis that is left in contact with the capping agent. The success of any therapy depends on the total removal of all the disintegrated tissue.

In conclusion, the dentist's efforts to maintain the vitality of a pulp that has been exposed are not only justified but obligatory in teeth with an immature apex, especially if the exposure is a result of recent trauma. The treatment of choice in such cases is undoubtedly pulpotomy, which is preferable to direct pulp capping. This therapy should be considered a provisional therapy, pending maturation of the apex and root. The pulp must be kept

→ **ET** page 4

## ENDO TRIBUNE

The World's Endodontic Newspaper · U.S. Edition

**Publisher**  
Torsten R. Oemus  
t.oemus@dtamerica.com

**President**  
Eric Seid  
e.seid@dtamerica.com

**Group Editor**  
Robin Goodman  
r.goodman@dtamerica.com

**Editor-in-Chief Endo Tribune**  
Frederic Barnett, DMD  
BarnettF@einstein.edu

**International Editor Endo Tribune**  
Prof. Dr. Arnaldo Castellucci

**Managing Editor Endo Tribune**  
Mr. Fred Michmershuizen  
f.michmershuizen@dtamerica.com

**Managing Editor Implant Tribune**  
Sierra Rendon  
s.rendon@dtamerica.com

**Managing Editor Ortho Tribune**  
Kristine Colker  
k.colker@dtamerica.com

**Product & Account Manager**  
Humberto Estrada  
h.estrada@dtamerica.com

**Advertising & Event Coordinator**  
Anna Wlodarczyk  
a.wlodarczyk@dtamerica.com

**Marketing & Sales Assistant**  
Lorrie Young  
l.young@dtamerica.com

**Director E-publishing & E-learning**  
Ovidiu Ciobanu PhD, MBA, DMD  
ovidiu@doctor.com

**Design Support**  
Yodit Tesfaye  
y.tesfaye@dtamerica.com

Dental Tribune America, LLC  
213 West 35<sup>th</sup> Street, Suite #801  
New York, NY 10001  
Tel.: (212) 244-7181  
Fax: (212) 244-7185



Published by Dental Tribune America  
© 2008, Dental Tribune America, LLC.  
All rights reserved.

Dental Tribune America makes every effort to report clinical information and manufacturer's product news accurately, but cannot assume responsibility for the validity of product claims, or for typographical errors. The publishers also do not assume responsibility for product names or claims, or statements made by advertisers. Opinions expressed by authors are their own and may not reflect those of Dental Tribune America.

## Editorial Advisory Board

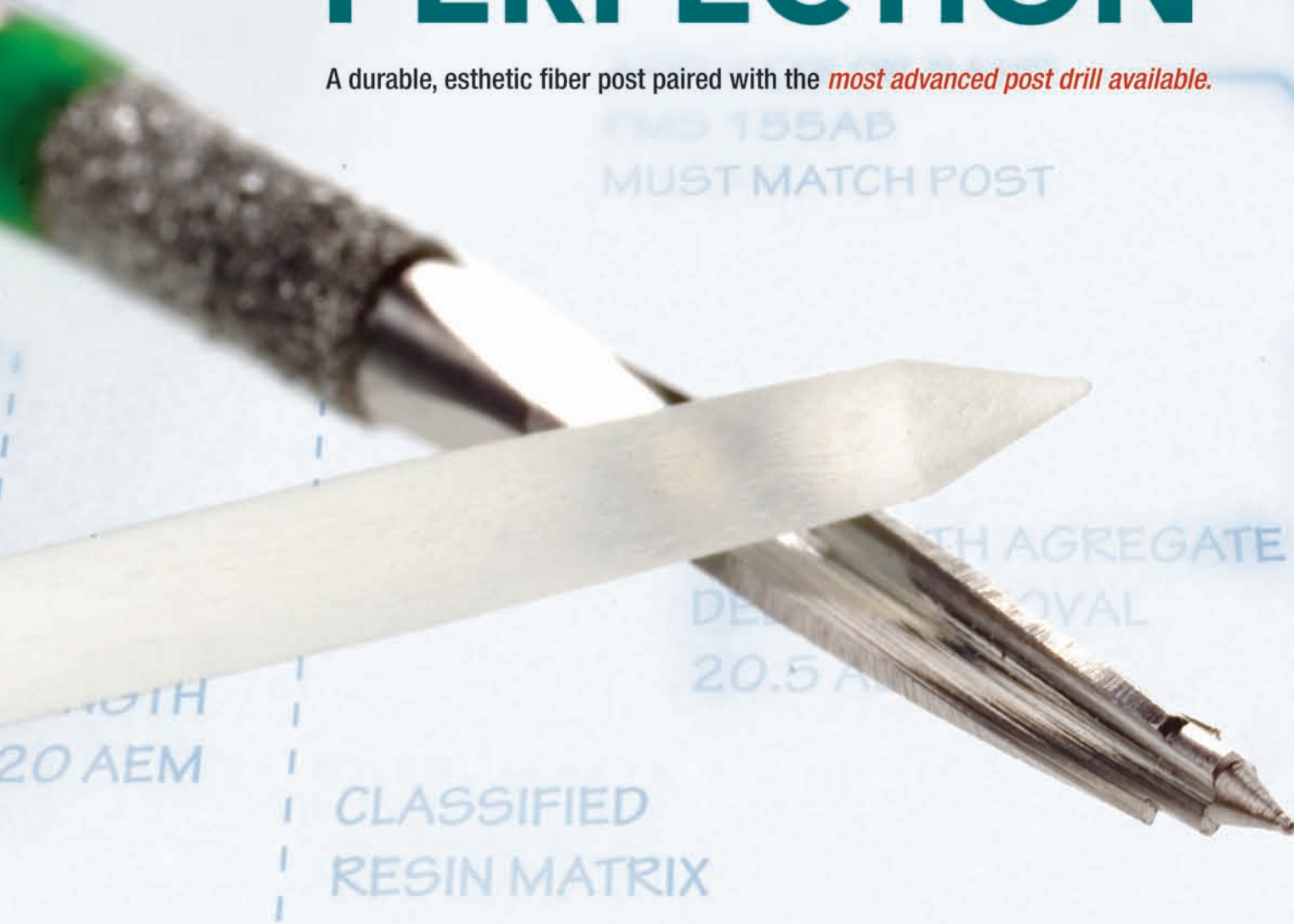Frederic Barnett, DMD (*Editor-in-Chief*)  
Roman Borczyk, DDS  
L. Stephen Buchanan, DDS, FICD, FACD  
Gary B. Carr, DDS  
Prof. Dr. Arnaldo Castellucci  
Joseph S. Dovgan, DDS, MS, PC  
Unni Endal, DDS  
Fernando Goldberg, DDS, PhD  
Vladimir Gorokhovskiy, PhD  
Fabio G.M. Gorni, DDS  
James L. Gutmann, DDS, PhD (honoris causa), Cert Endo, FACD, FICD, FADI  
William "Ben" Johnson, DDS  
Kenneth Koch, DMD  
Sergio Kuttler, DDS  
John T. McSpadden, DDS  
Richard E. Mounce, DDS, PC  
John Nusstein, DDS, MS  
Ove A. Peters, PD Dr. med dent., MS, FICD  
David B. Rosenberg, DDS  
Dr. Clifford J. Ruddle, DDS, FACD, FICD  
William P. Saunders, PhD, BDS, FDS, RCS Edin  
Kenneth S. Serota, DDS, MMSc  
Asgeir Sigurdsson, DDS  
Yoshitsugu Terauchi, DDS  
John D. West, DDS, MSD

**ET** Corrections

*Endo Tribune* strives to maintain the utmost accuracy in its news and clinical reports. If you find a factual error or content that requires clarification, please report the details to Mr. Fred Michmershuizen, managing editor, at f.michmershuizen@dtamerica.com.

# ENGINEERED TO PERFECTION


A durable, esthetic fiber post paired with the *most advanced post drill available.*




## UniCore® Fiber Post and Drill System

The UniCore system includes the durable, esthetic UniCore fiber post paired with the patented UniCore drill to create the profession's most advanced fiber post system. UniCore brings versatility to your post and core procedures, thanks to a 3-in-1 drill that not only creates a perfectly engineered post space, **but also removes obturators like ThermaFil, gutta percha, and even pre-existing fiber posts with ease!** UniCore offers a perfectly engineered combination of versatility, ease of use, esthetics, and adhesion. Get started with UniCore today!


- Advanced resin-based fiber post technology offers superior esthetics over metal or cast posts
- Replace old fashioned screw posts and cast posts with advanced fiber post technology
- Resin-based fiber post is 100% compatible with resin-based adhesives
- Post flexes and reacts similar to dentin, distributing stress loads throughout the tooth
- UniCore's drill not only prepares the post chamber, **it also removes stubborn obturators like ThermaFil carriers and fiber posts**
- Hardy, spill-proof modules eliminate hassle for your staff—no need to sort through organizer trays



The UniCore fiber post exceeds all ISO standards for radiopacity, making it easy to spot on radiographs.



The microporous surface of the UniCore post creates an intimate, complex surface for bonding inside the tooth.



Use PermaFlo DC cement to create a strong, bonded interface between the post, cement, and dentin.



## Save 25% on the UniCore Starter Kit

Use Source Code 8H04

**ULTRADENT**  
PRODUCTS, INC.  
800.552.5512 [ULTRADENT.COM](http://ULTRADENT.COM)

← ET page 2

vital, because it must still complete its primary, formative function. Seltzer and Bender<sup>25</sup> state that, once the development of the root has been completed, the pulp has no reason to remain there. Since it represents only a threat because of the calcifications and internal resorption that may develop, it must be removed, and the tooth must be treated endodontically. After all, who can inform the pulp to stay vital and inert inside the root canal after the dentin bridge has been completed and the apical closure has occurred?

On the other hand, pulp exposure in a tooth with a mature apex must be considered an indication for endodontic treatment, since, as Rebel<sup>25</sup> stated as long ago as 1922, “an exposed pulp is a lost organ.”

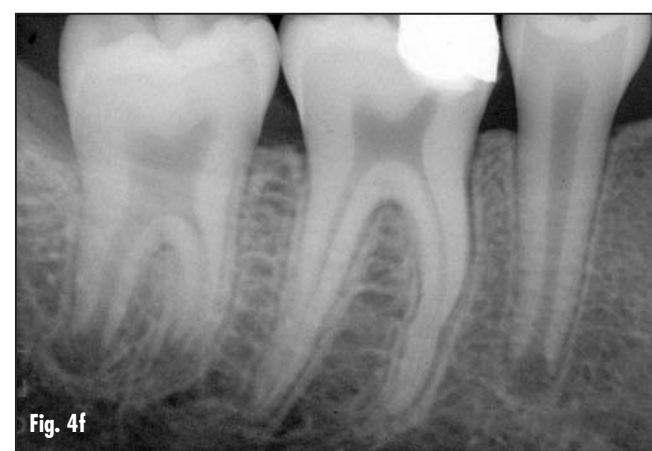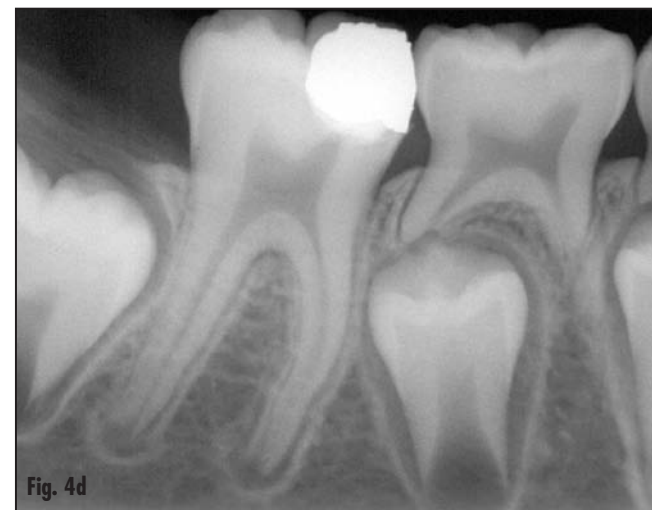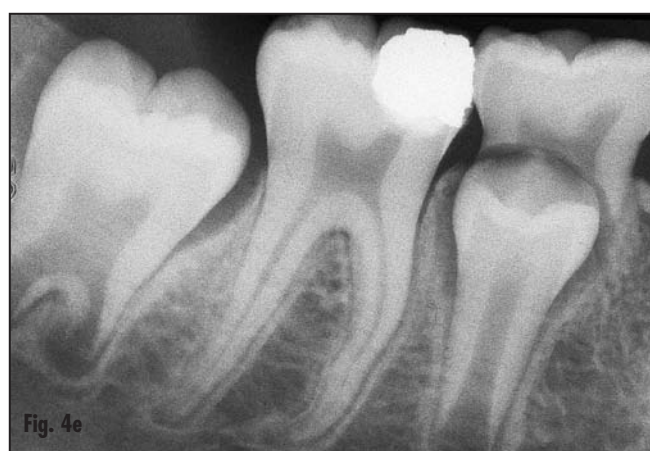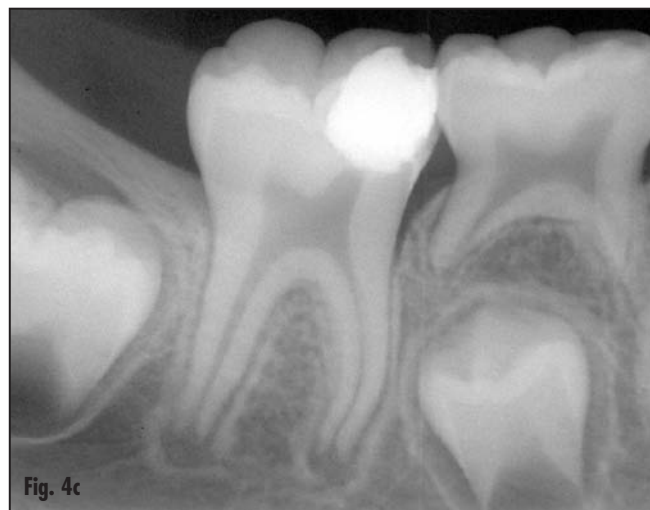#### What we know today

Recently, Dr. Mahmoud Torabinejad<sup>30</sup> of Loma Linda University in California has developed a new cement, Mineral Trioxide Aggregate (MTA; ProRoot MTA, Dentsply Tulsa Dental, Tulsa, Okla.) (Figs. 2, 3), which appears to have all of the characteristics requested of the ideal cement to seal pathways of communications between the pulp and the oral cavity (mechanical and carious pulp exposures), and between the root canal system and the periodontium (iatrogenic perforations, open apices, resorbed apices, root-end preparations).

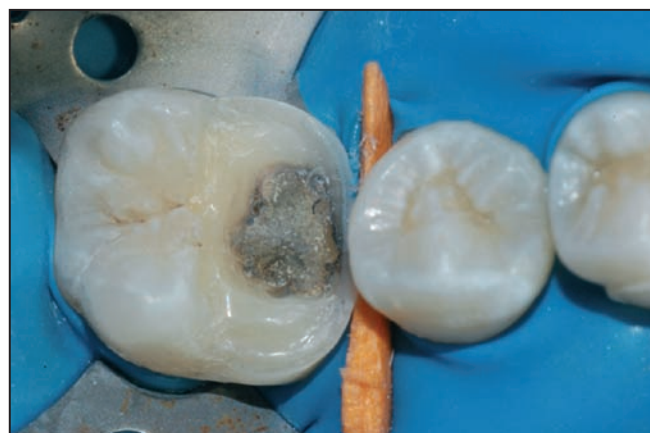MTA is an endodontic cement that is extremely biocompatible, capable of stimulating healing and osteogenesis, and is hydrophilic. MTA is a powder that consists of fine trioxides (tricalcium oxide, silicate oxide, bismute oxide) and other hydrophilic particles (tricalcium silicate, tricalcium aluminate, responsible for the chemical and physical properties of this aggregate), which set in the presence of moisture. Hydration of the powder results in formation of a colloidal gel with a pH of 12.5, that solidifies to a hard solid structure in approximately three to four hours.<sup>30</sup> This cement is different from other materials currently in use because of its biocompatibility, antibacterial properties, marginal adaptation and sealing properties, and its hydrophilic nature.<sup>30</sup>

In terms of biocompatibility, Koh et al.<sup>10,11</sup> and Pitt Ford et al.<sup>20</sup> demonstrated the absence of cytotoxicity when MTA came in contact with fibroblasts and osteoblasts, and the formation of dentin bridges when the material was used for direct pulp capping.

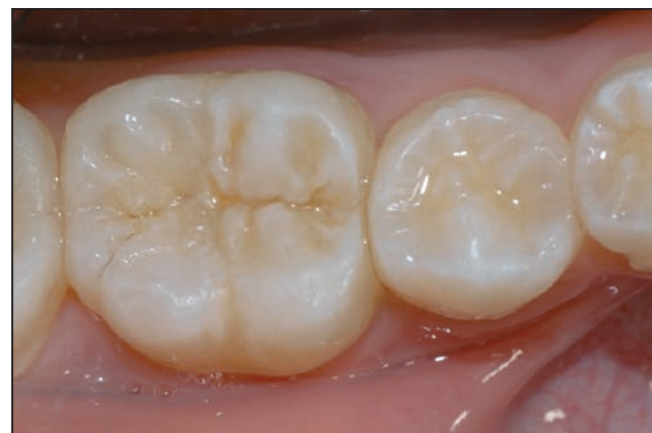Several *in vitro* and *in vivo* experiments<sup>2,16,29,31-33</sup> have shown that sealing ability and biocompatibility of MTA are superior to those of amalgam, Super-EBA and IRM; dye and bacterial leakage studies have confirmed the sealing ability of MTA; the cytotoxicity of MTA was



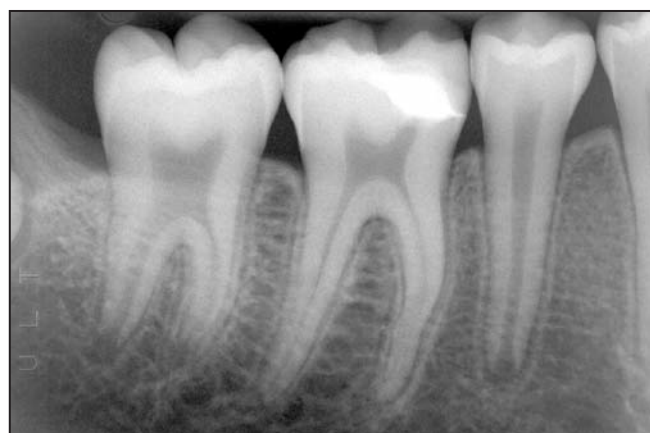**Figs. 4c-4f:** 7-, 22-, 40- and 53-month recall: the roots have completed their development and no sign of pulp calcification is present. The tooth is still responding normally to vitality tests.



**Fig. 4g:** Seven-year recall. The MTA just before the restoration.



**Fig. 4h:** The tooth has been restored with a composite onlay.



**Fig. 4i:** Nine-year recall. Note the integrity of the pulp horn and the pulp chamber free of calcifications.

found to be less than that of Super-EBA or IRM.

The characteristic that distinguishes MTA from other materials used to date in endodontics is its hydrophilic properties. Materials used to repair perforations, to seal the retro-preparation in surgical endodontics, to close open apices, or to protect the pulp in direct pulp cap-

ping, are inevitably in contact with blood and other tissue fluids. Moisture may be an important factor due to its potential effects on the physical properties and sealing ability of the restorative materials.<sup>29</sup> As shown by Torabinejad et al.,<sup>29</sup> MTA is the only material that is not affected by moisture or blood

contamination: The presence or absence of blood seems not to affect the sealing ability of the mineral trioxide aggregate. In fact, MTA sets only in the presence of water.<sup>30</sup>

MTA has been used also as a pulp capping material in exposed pulps<sup>20</sup> (Fig. 1) and today seems to be the material of choice.

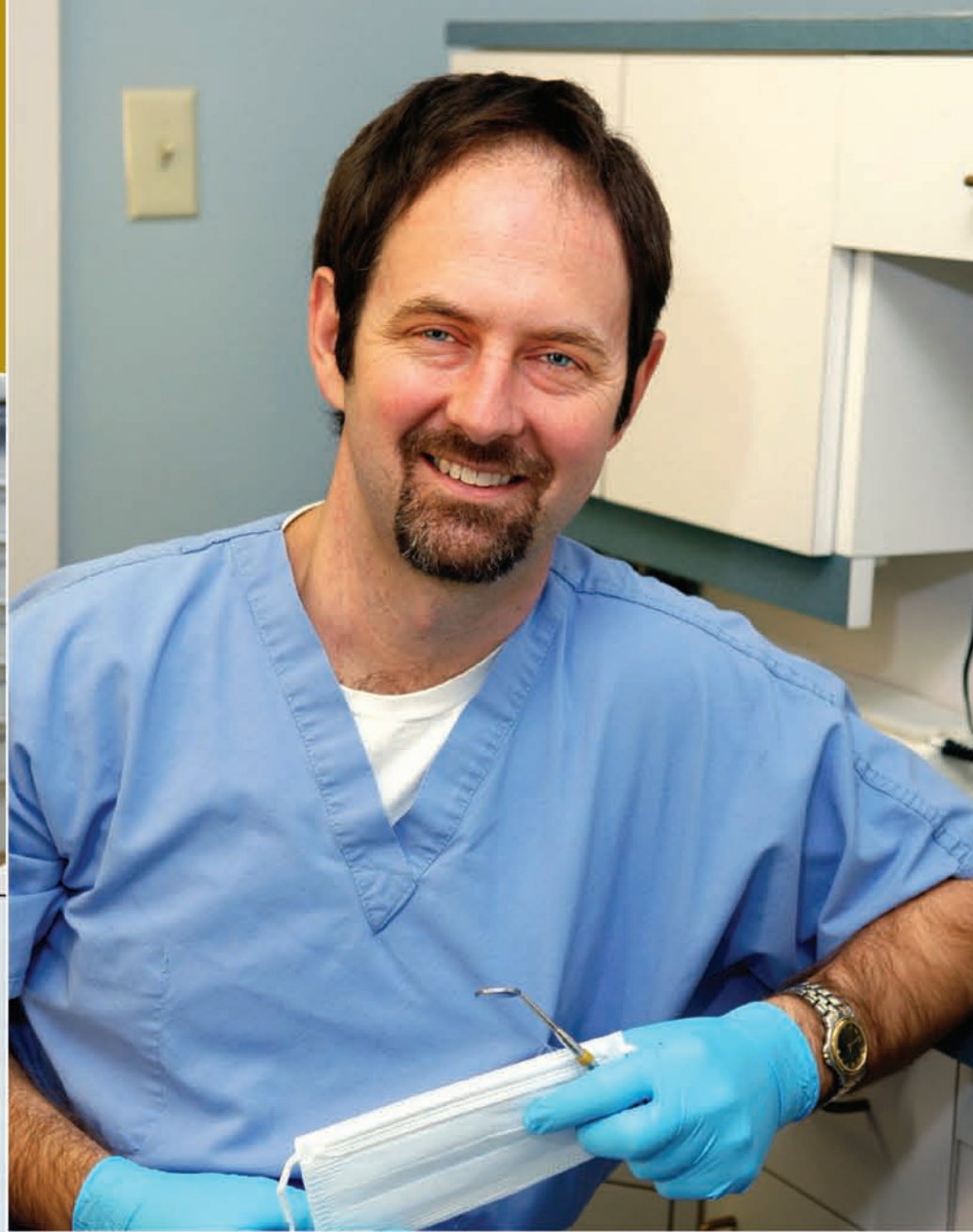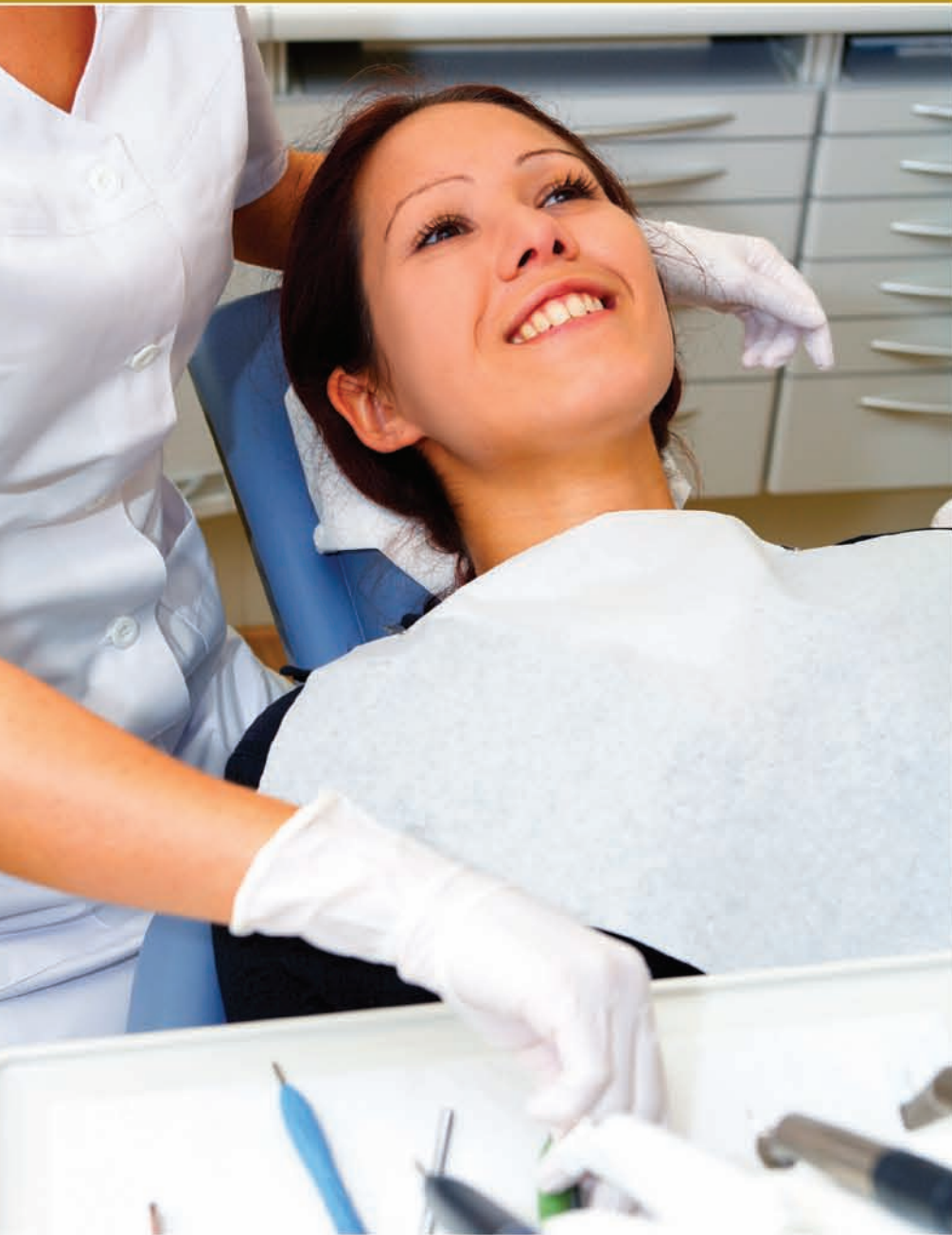Pulp capping is indicated for teeth

with immature apices when the dental pulp is exposed, and there are no signs of irreversible pulpitis.<sup>28</sup> In such cases the exposures must be sealed to preserve vitality of the pulp tissue. Recent studies have shown that MTA stimulates dentin bridge formation adjacent to the dental pulp. Dentinogenesis of MTA can be due to its sealing ability, biocompatibility, and alkalinity.<sup>20</sup>

Faraco and Holland<sup>4</sup> demonstrated that in teeth treated with MTA all bridges were tubular morphologically, and in some specimens the presence of a slight layer of necrotic pulp tissue was observed in the superficial portion of these bridges. This suggested that the material, similarly to calcium hydroxide, initially causes necrosis by coagulation in contact with pulp connective tissue. This reaction may occur because of the product's high alkalinity, whose pH is 10.2 during manipulation and 12.5 after three hours.<sup>30</sup> In a previous arti-

→ ET page 6

It's the best shot  
I've ever had.



## Single Tooth Anesthesia The Answer

**"The Most Predictable Intraligamentary Injection You'll Ever Give"**

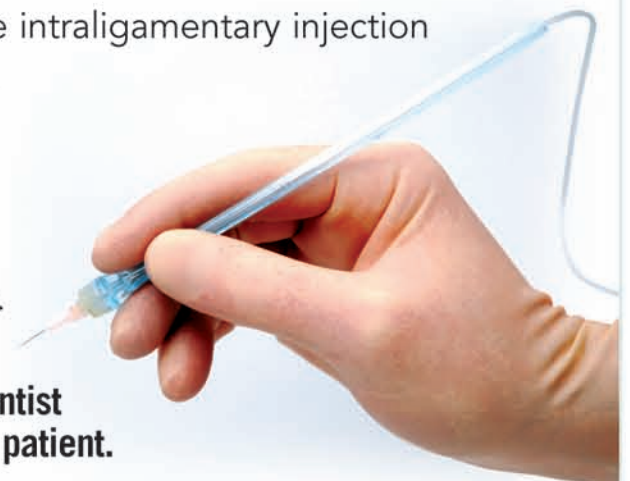### Endodontist Preferred. Patient Approved.

- STA provides confirmation when you're in the right location for the intraligamentary injection
- STA allows you to anesthetize one tooth – no collateral numbness
- STA delivers profound anesthetic for 30-45 minutes

**Stop waiting for the Block**, start using the STA intraligamentary injection as your PRIMARY technique and start working immediately.



**The more comfortable injection for the dentist  
is the MOST comfortable injection for the patient.**



**MILESTONE**  
SCIENTIFIC

800.862.1125

[www.stais4u.com](http://www.stais4u.com)

← ET page 4

cle, Holland et al.<sup>6</sup> demonstrated the presence of calcite crystals in contact with MTA implanted in rat subcutaneous tissue. Those calcite crystals attract fibronectin, which is responsible for cellular adhesion and differentiation. Therefore we believe that the MTA mechanism of action is similar to that of calcium hydroxide, but in addition, MTA provides a superior bacteria-tight seal.<sup>4</sup>

### Report

A 6-year-old girl was referred because of a deep decay in the

lower right first molar. The tooth was only partially erupted (with the mesial cusps), while the distal cusps were still unerupted. The mesio-buccal cusp presented a deep decay involving the pulp. The tooth was completely asymptomatic and responded to all vitality tests. The radiograph showed that the apices were immature (Fig. 4a).


After achieving anesthesia, the isolation with a rubber dam was achieved after etching the enamel buccal and lingual to the mesial cusps and after bonding two little pieces of composite to stabilize the rubber dam clamp. The removal of the decayed dentin involved a large

pulp exposure. The exposed pulp was irrigated with 5 percent NaClO to control bleeding. The MTA powder was mixed with sterile water, and the mixture was then placed in contact with the exposure using a Dovgan carrier. The mixture was gently compressed against the exposure site with a moist cotton pellet. A moist cotton pellet was then placed over the MTA, and the rest of the cavity was filled with a temporary filling material (Fig. 4b). After four hours, the patient was seen again, the rubber dam was repositioned, the temporary filling material and cotton pellet were removed, and the set of the material was assessed. Then, the tooth was temporarily restored and the patient was scheduled for regular recalls (Figs. 4c-4f).

After seven years the young patient was scheduled for the definitive restoration. The radiograph showed the complete formation of the root apices and the absolute absence of calcifications in the pulp chamber. The pulp horn under the capping material was intact. The tooth responded to all the vitality tests (Figs. 4g-4i).

### Conclusion

For sure MTA is to be preferred to the use of calcium hydroxide and today should be considered the material of choice when a direct pulp capping is indicated. Nevertheless, MTA has only recently been introduced, and no long-term studies on its efficacy have been published yet. Therefore, it is necessary to recall treated patients on a regular basis to determine if treatment has been successful, or if root canal therapy is needed.



This article is an excerpt from Dr. Arnaldo Castellucci's textbook "Endodontics," which is divided into three volumes and 35 chapters. Volumes 1 and 2 of this endodontic textbook are now available for the first time in English, completely revised with new chapters and many more color illustrations. Each volume comes complete with its own CD-ROM, which includes the complete text and illustrations in PDF files.

To order, contact Il Tridente S.R.L., Viale dei Mille 60, 50131 Firenze, Italy, Tel. +39 055 500 1312, Fax +39 055 500 0232, info@iltridente.it, or visit [www.iltridente.it](http://www.iltridente.it).

### About the author

#### Dr. Arnaldo Castellucci

Dr. Castellucci graduated in Medicine at the University of Florence in 1973 and specialized in Dentistry at the same University in 1977. From 1978 to 1980 he attended continuing education courses in endodontics at Boston University School of Graduate dentistry with Prof. Herbert Schilder. As well as running a practice limited to endodontics in Florence, Italy, Dr. Castellucci is past president of the Italian Endodontic Society, past president of the International Federation of Endodontic Associations, an active member of the European Society of Endodontology, an active member of the American Association of Endodontists, and a visiting professor of endodontics at the University of Florence Dental School. He is editor of The Italian Journal of Endodontics and of The Endodontic Informer, founder and president of The Warm Gutta Percha Study Club and The Micro-Endodontic Training Center, and he is international editor of Endo Tribune. An international lecturer, he is the author of the text "Endodontics," which is now available in English.



## References

- Barker, B.C.W., Lockett, B.C.: An unusual response by dog pulp to calcium hydroxide. *Oral Surg.* 32:785, 1971.
- Bates, C.F., Carnes, D.L., Del Rio, C.E.: Longitudinal sealing ability of mineral trioxide aggregate as a root end filling material. *J. Endod.* 22:575, 1996.
- Baume, L.J.: Diagnosis of disease of the pulp. *Oral Surg.* 29:102, 1970.
- Faraco, I.M., Holland, R.: Response of the pulp of dogs to capping with mineral trioxide aggregate or a calcium hydroxide cement. *Dent. Traumatol.* 17:163, 2001.
- Hermann, B.W.: Dentinobliteration der wurzelkanal nach behandlung mit kalzium. *Zahnaertzl. Rundsch.* 21:887, 1930.
- Holland, R., De Souza, V., Nery, M.J., Otoboni Filho, J.A., Bernabe, P.F., Dezan Junior E.: Reaction of rat connective tissue to implanted dentin tubes filled with mineral trioxide aggregate or calcium hydroxide. *J. Endod.* 25:161, 1999.
- Holland, R., Pinheiro, C.E., De Mello, W., Neri, M.J., De Souza, V.: Histochemical analysis of the dog's dental pulp after pulp capping with calcium, barium, and strontium hydroxides. *J. Endod.* 8:444, 1982.
- Hunter, W.C.: Saving pulp, a queer process. *Dent. Items Interest*, p. 352, 1883.
- Kakehashi, S., Stanley, H.R., Fitzgerald, R.J.: The effects of surgical exposure of dental pulps in germ-free and conventional laboratory rats. *Oral Surg.* 20:340, 1965.
- Koh, E.T., McDonald, F., Pitt Ford, T.R., Torabinejad, M.: Cellular response to mineral trioxide aggregate. *J. Endod.* 24:53, 1998.
- Koh, E.T., Torabinejad, M., Pitt Ford, T.R., Brady, K.: Mineral trioxide aggregate stimulates a biological response in human osteoblasts. *J. Biomed. Mater. Res.* 37:432, 1997.
- Langeland, K.: Tissue response to dental caries. *Endod. Dent. Traumatol.* 3:149, 1987.
- Langeland, K., Dowden, W.E., Tronstad, L., Langeland, L.K.: Human pulp changes of iatrogenic origin. *Oral Surg.* 32:943, 1971.
- Mitchell, D.F., Shankwalker, G.B.: Osteogenic potential of calcium hydroxide and other materials in soft tissue and bone wounds. *J. Dent. Res.* 37:1157, 1958.
- Mullaney, T.P., Lawson, B.F., Mitchell, D.F.: Pharmacologic treatment of pulpitis: a continuing investigation. *Oral Surg.* 21:479, 1966.
- Nakata, T.T., Bae, K.S., Baumgartner, J.C.: Perforation repair comparing mineral trioxide aggregate and amalgam. *Abs. n° 40. J. Endod.* 23:259, 1997.
- Perreira, J.C., Bramante, C.M., Berbert, A., Mondelli, J.: Effect of calcium hydroxide in powder or in paste form on pulp-capping procedures: histopathologic and radiographic analysis in dog's pulp. *Oral Surg.* 50:176, 1980.
- Pisanti, S., Sciaky, I.: Origin of calcium in the repair wall after pulp exposure in the dog. *J. Dent. Res.* 43:641, 1964.
- Pitt Ford, T.R., Torabinejad, M., Abedi, H.R., Bakland, L.K., Kariyawasam, S.P.: Mineral trioxide aggregate as a pulp capping material. *J. Am. Dent. Assoc.* 127:1491, 1996.
- Prush, R.J.: Pulp therapy for children and adolescents. In H. Gerstein ed.: *Techniques in clinical endodontics*. W.B. Saunders Company, Philadelphia, 1983.
- Ostrom, C.A., Lyon, H.W.: Pulpal response to chemically treated heterogeneous bone in pulp capping sites. *Oral Surg.* 15:362, 1962.
- Quigley, M.B.: A critical history of the treatment of pulpal exposures. *J. Dent. Child.* 23:209, 1956.
- Rebel, H.: Über die ausscheidung der freigelegten pulps. *Vort.* 55:1, 1922.
- Schultz, L.C. e coll.: *Odontoiatria conservativa*. Piccin ed., Padova, 1971.
- Seltzer, S., Bender, I.B.: *The dental pulp*. 3rd ed. Philadelphia, J.B. Lippincott Company, 1984.
- Shubic, I., Miklos, F.L., Lapp, R., Draus, F.J.: Release of calcium ions from pulp-capping materials. *J. Endod.* 4:242, 1978.
- Teuscher, G.W., Zander, H.A.: A preliminary report on pulpotomy. *Northwest Univ. Bull.* 39:4, 1938.
- Torabinejad, M., Chivian, N.: Clinical applications of mineral trioxide aggregate. *J. Endod.* 25:197, 1999.
- Torabinejad, M., Higa, R.K., McKendry, D.J., Pitt Ford, T.R.: Dye leakage of four root-end filling materials: effects of blood contamination. *J. Endod.* 20:159, 1994.
- Torabinejad, M., Hong, C.U., McDonald, F., Pitt Ford, T.R.: Physical and chemical properties of a new root-end filling material. *J. Endod.* 21:349, 1995.
- Torabinejad, M., Hong, C.U., Pitt Ford, T.R., Kettering, J.D.: Cytotoxicity of four root end filling materials. *J. Endod.* 21:489, 1995.
- Torabinejad, M., Rastegar, A.F., Kettering, J.D., Pitt Ford, T.R.: Bacterial leakage of mineral trioxide aggregate as a root end filling material. *J. Endod.* 21:109, 1995.
- Torabinejad, M., Watson, T.F., Pitt Ford, T.R.: The sealing ability of a mineral trioxide aggregate as a retrograde root filling material. *J. Endod.* 19:591, 1993.
- Tronstad, L., Mjor, I.A.: Capping of the inflamed pulp. *Oral Surg.* 34:477, 1972.
- Tziafas, D., Beltes, P.: Pulp capping with calcium hydroxide: diagnostic value of radiographic findings. *Endod. Dent. Traumatol.* 4:260, 1988.
- Via, W.F.: Evaluations of deciduous molars treated by pulpotomy and calcium hydroxide. *J. Am. Dent. Assoc.* 50:34, 1955.
- Weine, F.S.: *Endodontic therapy*. 3rd., St. Louis, The C.V. Mosby Company, 1982.



Summit  
OF THE MASTERS

*You're Participation is Requested*

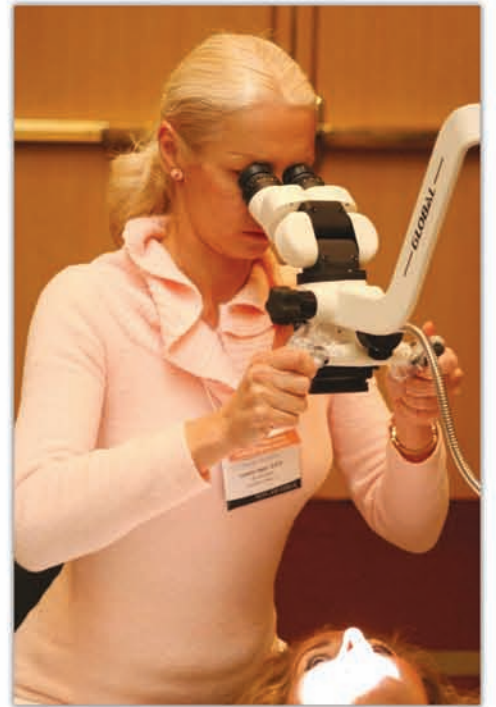
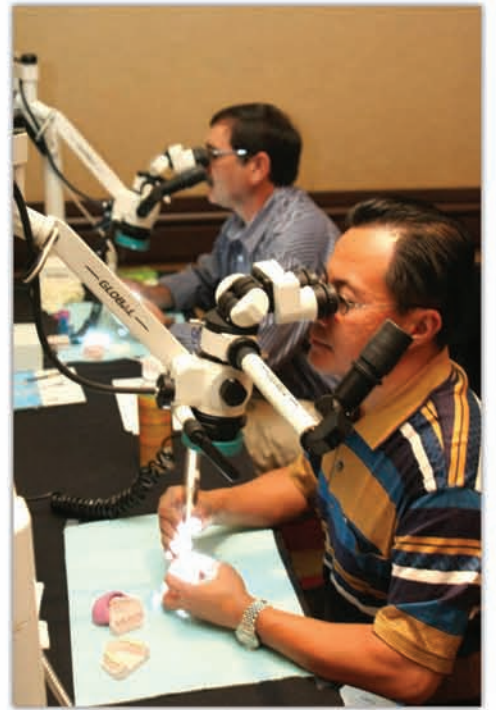
The dental operating microscope has added a new dimension to my practice that has improved my outcomes, increased the level of satisfaction of my patients, and made dentistry fun again. The impact on my practice has been incredible.

I invite you to join us at our annual meeting for a time of learning and a time for fun in lovely Scottsdale, AZ. Many exhibitors will be there, affording you the opportunity to "test-drive" the many microsurgical tools. It is an international, multidisciplinary program. There will be dentists from every walk of life there – microscope novices and masters – sharing their stories. It will be a meeting that will change your professional life, just as it changed mine.


**Adriana McGregor, DDS**  
**President, Academy of Microscope Dentistry.**

P.S. Check out the program schedule at AMED's website – [www.microscopdentistry.com](http://www.microscopdentistry.com)



Hands on Courses

*The Fairmont Scottsdale Princess*



*October 30 - November 1, 2008*



Sponsored in part by



## Upcoming events

Aug. 28-30

**Exceptional Practice Management Workshop**  
The Women of Dentistry Committee  
Villagio Inn & Spa, Napa Valley, Calif.  
Information: (416) 907-9836; [j.wehkamp@gmail.com](mailto:j.wehkamp@gmail.com)



Sept. 9

**WEBINAR: Predictable Canal Enlargement with the Twisted File**  
Dr. Richard Mounce  
Online Seminar  
Information: (416) 907-9836; [j.wehkamp@dtamerica.com](mailto:j.wehkamp@dtamerica.com)

Sept. 12-14

**2008 Fall Scientific Session**  
California Dental Association  
San Francisco  
Information: (312) 440-2500; [www.ada.org](http://www.ada.org)

Sept. 18-20

**European Society of Microscope Dentistry (ESMD) Congress**  
NH Grand Hotel Krasnapolsky, Amsterdam  
Information: Tel +31 73 690 14 15; Fax +31 73 690 14 17;  
[info@congresscare.com](mailto:info@congresscare.com); [www.esmd2008.org](http://www.esmd2008.org)



Oct. 2

**WEBINAR: Be THE Exceptional Practice!**  
Dr. Ron Scheffore  
Online Seminar  
Information: (416) 907-9836; [j.wehkamp@dtamerica.com](mailto:j.wehkamp@dtamerica.com)

Oct. 16-19

**149th Annual Scientific Session and Marketplace Exhibition**  
American Dental Association  
San Antonio  
Information: (312) 440-2500; [www.ada.org](http://www.ada.org)

Oct. 21

**WEBINAR: Cone Beams — A new dimension of dentistry**  
Dr. Daniel McEowen  
Online Seminar  
Information: (416) 907-9836; [j.wehkamp@dtamerica.com](mailto:j.wehkamp@dtamerica.com)

Oct. 30-Nov. 1

**Summit of the Masters, seventh annual Meeting & Scientific Session of the Academy of Microscope Enhanced Dentistry (AMED)**  
Scottsdale Princess Resort, Scottsdale, Ariz.  
Information: (260) 249-1028; [info@microscopedentistry.com](mailto:info@microscopedentistry.com);  
[microscopedentistry.com](http://microscopedentistry.com)



Nov. 4

**WEBINAR: Increase Net Revenue, Foster Employee Confidence: The Five Keys to Effective Employment Relations for the Dental Office**  
Michael Moore  
Online Seminar  
Information: (416) 907-9836; [j.wehkamp@dtamerica.com](mailto:j.wehkamp@dtamerica.com)

Nov. 6-8

**American Association of Endodontists 2008 Fall Conference**  
**Implants in Endodontics — Treatment Planning and Placement Techniques**  
Intercontinental Mark Hopkins, San Francisco  
Information: (800) 872-3636; (866) 415-9020; [www.aae.org](http://www.aae.org); [info@aae.org](mailto:info@aae.org)

Nov. 28-Dec. 5

**84th Annual Session, Greater New York Dental Meeting**  
Jacob K. Javits Convention Center, New York  
Information: (212) 398-6922; [www.gnydm.org](http://www.gnydm.org)

Nov. 30-Dec. 5

**Dental Tribune Symposia — “Getting Started in ...” Series**  
Greater New York Dental Meeting  
Information: (416) 907-9836; [j.wehkamp@dtamerica.com](mailto:j.wehkamp@dtamerica.com)

**Tell us  
what you  
think!**

Do you have general comments or criticism you would like to share? Is there a particular topic you would like to see more articles about? Let us know by e-mailing us at [r.goodman@dtamerica.com](mailto:r.goodman@dtamerica.com). If you would like to make any change to your subscription (name, address or to opt out) please send us an e-mail at [database@dtamerica.com](mailto:database@dtamerica.com) and be sure to include which publication you are referring to. Also, please note that subscription changes can take up to 6 weeks to process.

## Amsterdam is host city for first ESMD Congress



Amsterdam, host for the upcoming ESMD Congress, is a destination city that offers plenty to see and do.

The first Congress of the European Society of Microscope Dentistry (ESMD) will be held Sept. 18-20 at the NH Grand Hotel Krasnapolsky in Amsterdam. The theme of the event, which is aimed at those who are interested in worldwide innovations in the use of magnification techniques in dentistry, is “To See or Not to See.”

The Congress will emphasize practical applications. Lectures will be presented with clinical content in all dental disciplines: preventive, restorative, ergonomics, endodontics, periodontics, photography, implant dentistry and its periodontal aspects, and the latest sophisticated 3-D radiology. Revolutionary 3-D optical devices and their implementation in everyday dentistry will also be covered. According to event organizers, all of the presenters have microscope-centered practices and are highly skilled in the application of this technology in clinical dentistry.

“This is a combination never before seen in Europe — and hardly ever elsewhere,” said ESMD President Philippe Van Audenhove, LTH. “These three days in Amsterdam will give participants a 21st century upgrade in all dental disciplines.”

The scientific presentations will begin on Sept. 18 and will continue through Sept. 20. The program includes plenty of hands-on workshops, master classes and plenary sessions. After hours, attendees will have the opportunity to experience all that Amsterdam has to offer.

“A jam-packed social program will allow plenty of opportunities for the exchange of ideas and opinions, as well as for meeting fellow participants,” Van Audenhove said.

A targeted group of companies will be invited to exhibit their products and services. Certificates of attendance for all participants will be available at the registration desk.

For more information on the event, visit [www.esmd2008.org](http://www.esmd2008.org).

## Microscope dentistry: revolutionizing vision in our field

By Paul Anstey B.Ch.D. Diplomat,  
American Board of Endodontics

AMED — the Academy of Microscopic Enhanced Dentistry — was founded in 2001. Its core mission is that of exposing practitioners to the true value of visualization in everyday practice. Just as the breakthrough of magnification with loupes revolutionized our ability to see, so has the technology of the dental microscope taken us to the next level — a new era of precision dentistry.

There is no better way to stay on the cutting edge of your field than by attending Summit of the Masters, AMED’s seventh annual Meeting & Scientific Session, to be held Oct. 30 to Nov. 1 at the Scottsdale Princess Resort in Scottsdale, Ariz. You will be exposed to the power of the microscope via lectures and hands-on courses presented by some of the

greatest pioneers in the field. You will discover firsthand the value of this phenomenal technology through the options of restorative, periodontal and endodontic courses, where each participant will have a chance to begin developing the skills needed to work with this breakthrough device.

A new world awaits you at AMED! Come and discover how to truly maximize your potential, inject a new excitement in your art and separate your practice from the rest.

Visit us at [microscopedentistry.com](http://microscopedentistry.com) and revive your professional journey.

*Summit*  
OF THE MASTERS



# AAE calls on young athletes to use mouth guards

The American Association of Endodontists (AAE) is advising young athletes to watch their mouths.

"Traumatic dental injuries and knocked out teeth are most often associated with football or hockey, but spring sports, such as soccer and baseball, can present just as big a risk," the AAE warned in a press release. Soccer players are nearly eight times more likely to suffer dental injuries than are football players, and nearly 20 percent of baseball players will experience a dental injury, according to the AAE.

An athlete is 60 times more likely to suffer a dental injury, such as a knocked out tooth, when not wear-

ing a protective mouth guard, and the number of sports-related dental injuries is rising. As a result, AAE is urging all coaches and parents to make sure young athletes wear mouth guards for all sports, including lacrosse, softball, track and field, and gymnastics. Mouth guard usage prevents an estimated 200,000 injuries a year, the AAE reported.

"Mouth guards are not just for kids that play rough contact sports," said AAE President Shepard S. Goldstein, DMD. "It is essential that children's teeth be protected from dental injury when they play any physical sport. The AAE wants athletes, coaches and parents to know that mouth

guard use is imperative for all sports, even those not commonly thought of as being hazardous."

Mouth guards are available in three common varieties: standard, one-size-fits-all mouth guards; mouth-formed boil-and-bite mouth guards; and dentist-made custom mouth guards.

"While custom mouth guards professionally fitted by a dentist offer the best protection from dental injury, using any type of mouth guard helps to safeguard natural teeth and reduce the chance of dental trauma," the AAE says. "When using mouth guards, it's important to properly maintain and clean them to pre-

vent any possible infections."

A person who has had a tooth knocked out should try to see an endodontist within 30 minutes. Although it may be possible to save a tooth that has been outside the mouth for more than 30 minutes, "the chances of success are less the longer the tooth is out of the mouth."

The AAE offered the recommendations earlier this year as part of its Root Canal Awareness Week, held March 30 to April 5. The annual initiative focuses on dental education and is part of the AAE's commitment to promoting the value of preserving natural teeth.

Source: American Association of Endodontists

## Dr. Mo Kang appointed Weichman chair in endodontics

Dr. Mo K. Kang, a 2002 recipient of the American Association of Endodontists Foundation Endodontic Educator Fellowship Award, was recently named the first-ever Endowed Jack Weichman Chairman of Endodontics at University of California Los Angeles.



Dr. Mo K. Kang

The chair was created to support the teaching and research activities of an academic endodontist. The UCLA School of Dentistry teaches the specialty to students in its four-year doctor of dental surgery degree program as well as to graduate dentists enrolled in a two-year residency training program.

"The purpose of the Educator Fellowship Award is to help outstanding residents become academic leaders," said Dr. Denis E. Simon III, AAE Foundation president. "We are extremely proud to have one of our awardees become such an integral part of a prestigious university, teaching the future of dentistry."

The Endodontic Educator Fellowship Awards were created to recognize the critical role that endodontic educators play in strengthening their specialty and to address the need for more endodontic specialists to teach in dental schools. Representatives from the Foundation's Board of Trustees and the AAE's Board of Directors worked together to develop the concept and guidelines in 2000, creating a program that was one of the first of its kind among the nation's dental specialty associations. Fourteen fellowships have been granted since the program began.

"The Foundation is dedicated to the continued health and prosperity of the specialty," said Dr. Simon.

AD



## 1<sup>st</sup> Congress of the European Society of Microscope Dentistry

18 - 20 September 2008

Amsterdam, The Netherlands  
NH Grand Hotel Krasnapolsky

"TO SEE OR NOT TO SEE"  
Hands-on workshops  
Masterclasses  
Plenary sessions  
Workshops introduction to the scope

[www.esmd2008.org](http://www.esmd2008.org)

<b>Masterclasses</b>		<b>Plenary sessions</b>
Micro Surgical Endodontics I	Marga Ree ( <i>The Netherlands</i> )	Cracks
Micro Surgical Endodontics II	Michiel de Cleen ( <i>The Netherlands</i> )	Endodontics
Restorative	Stephane Browet ( <i>Belgium</i> )	
<b>Hands-on workshops</b>		Ergonomics
Micro-examination	David Clark ( <i>USA</i> )	Restorative
Micro perio-surgery	Adriana McGregor ( <i>USA</i> )	Perio-surgery
Endodontics	Walter van Driel ( <i>The Netherlands</i> )	3D Imaging
Photography	Kasper Veenstra ( <i>The Netherlands</i> )	
Restorative	Glenn van As ( <i>Canada</i> )	Success and failure
	David Clark ( <i>USA</i> )	Photography
<b>Live demo and limited</b>		Micro endo-surgery
	Assad Mora ( <i>USA</i> )	Endo-restorative
	Tetsuya Hirata ( <i>Japan</i> )	Cone beam CT & endodontics
<b>Hands-on-workshop</b>		
<b>Introduction to the scope</b>	Wayne Remington ( <i>USA</i> )	
	Glenn van As ( <i>Canada</i> )	
	Thomas Clauder ( <i>Germany</i> )	






[www.esmd2008.org](http://www.esmd2008.org)