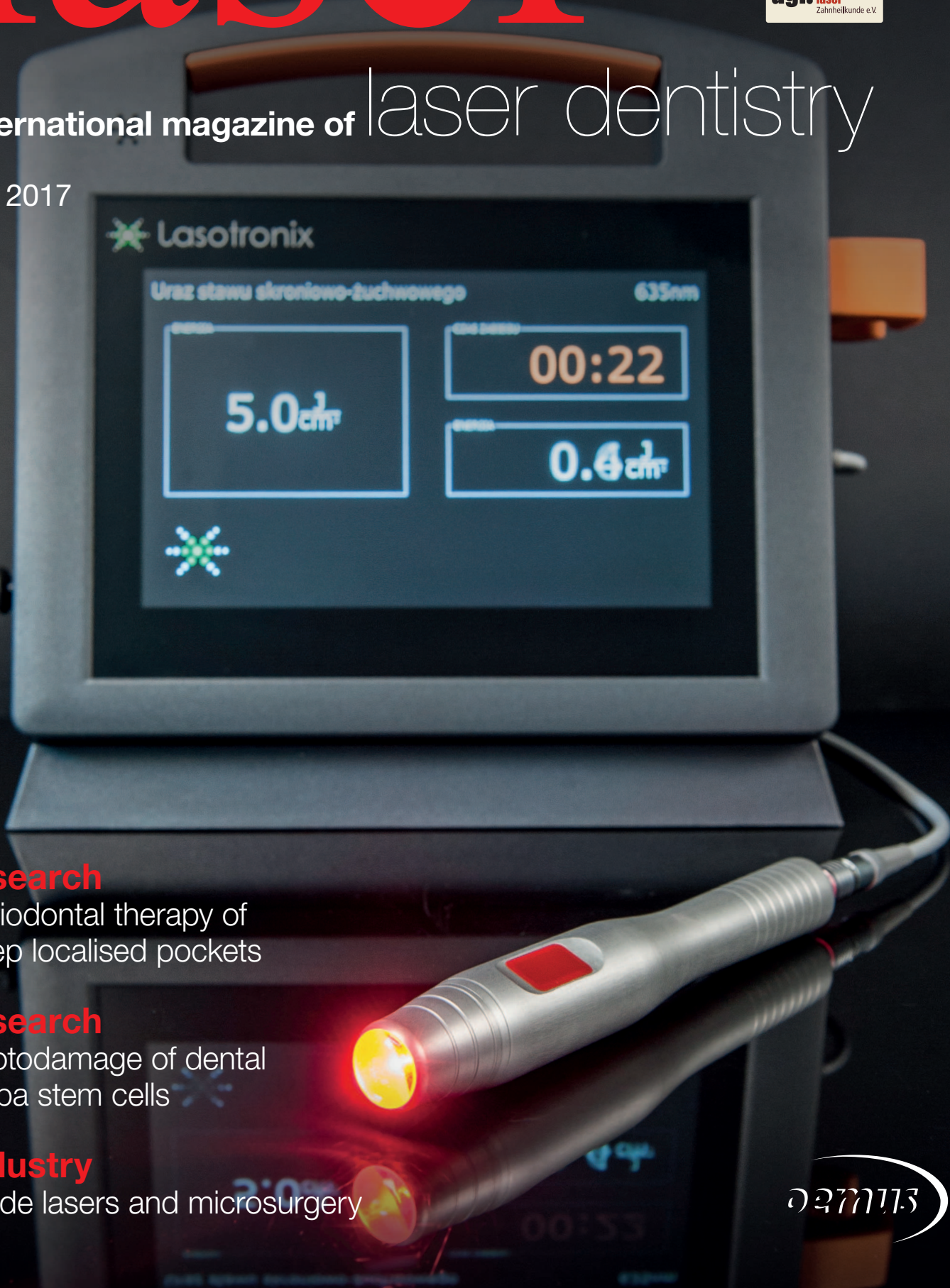

# laser



international magazine of laser dentistry

1 2017



## research

Periodontal therapy of deep localised pockets

## research

Photodamage of dental pulpa stem cells

## industry

Diode lasers and microsurgery



The universe at your fingertips.

# LightWalker

## The highest technology dental laser system

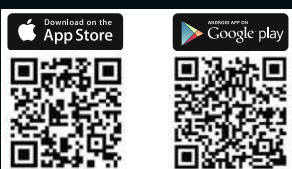
### Supreme clinical results:


- TwinLight® Perio Treatments
- TwinLight® Endo Treatments
- No-sutures soft-tissue surgery
- Patient-friendly conservative dentistry
- Pre-sets for over 40 applications

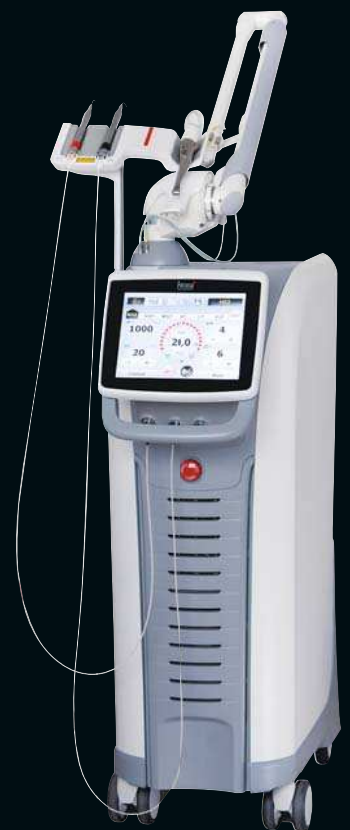### Unmatched simplicity of use:

- Balanced and weightless OPTOflex® arm
- Nd:YAG handpiece detection system
- Quantum Square Pulse technology for fast minimally invasive treatments
- X-Runner™ - the first digitally controlled Er:YAG dental laser handpiece

Visit Fotona's booth (Hall: 10, Plain: 2, Aisle: M, No: 050) to find out more about our latest high-performance, ASP-powered LightWalker laser systems and minimally invasive dental solutions, including the new SWEEPS endodontic solution.



 Fotona App



# Wavelength variation



Prof. Dr Norbert Gutknecht

Dear colleagues,  
Dear laser society members,

More and more companies offer laser systems with a variety of wavelengths for dental indications. This development gives rise to the hope that the insight in absorption, transmission, reflexion and dispersion in different tissues after irradiation with various wavelengths and the different effects on this tissues will increase. On the other hand we must now ask ourselves when different wavelengths should be applied alternatingly or at staggered intervals.

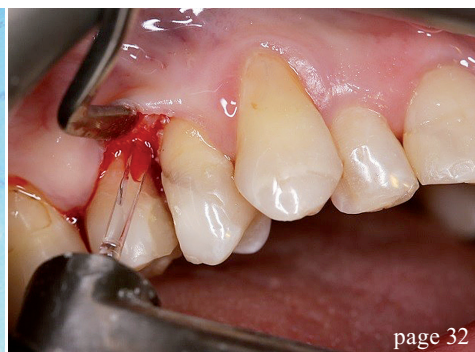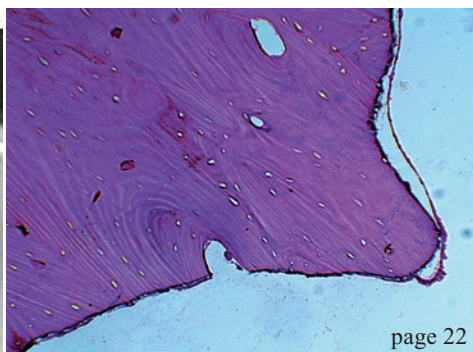
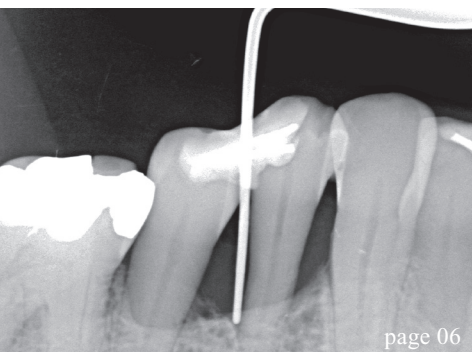
The upcoming IDS—International Dental Show certainly will present new and interesting combinations of laser wavelengths, hopefully featuring well-researched and differentiated evidence on their clinical applications. The larger the number of different laser wavelengths in the dental practice, the more will the probability of applying them more specifically in terms of individual indications increase. I am glad that this issue of **laser** international magazine of laser dentistry confronts its readers with an article on this topic.

I wish all of you who are going to attend IDS much fun in examining the new dental laser generation.

Yours,

A handwritten signature in black ink, appearing to read 'Norbert Gutknecht'. The signature is fluid and cursive, with a large initial 'N'.

Prof. Dr Norbert Gutknecht



## editorial

- 03 Wavelength **variation**  
Prof. Dr Norbert Gutknecht

## research

- 06 **Periodontal therapy** of deep localised pockets larger than 9 mm  
Dr Gottfried Gisler, MSc
- 18 **Photodamage of dental pulpa stem cells** during 700 fs laser exposure  
Prof. Dr Karsten König & Dr Anton Kasenbacher

## industry

- 22 **Histomorphological changes in human bone**  
Bistra Y. Blagova, Elena G. Poriazova, Petia F. Pechalova & Prof. Georgi T. Tomov
- 26 **Diode lasers and microsurgery**  
Dr Isabelle Nguyen
- 32 The application of **erbium laser** in dental **surgery**  
Dr Kinga Grzech-Lesniak
- 38 A **novel Er:YAG dental laser-in-handpiece** technology  
Georg Isbaner

## practice management

- 40 Successful **communication** in your **daily practice**  
Dr Anna Maria Yiannikos

## events

- 42 6<sup>th</sup> **Laser Dentistry Congress** of WFLD-ED  
Dr Dimitris Strakas

## news

- 44 **manufacturer news**

## DGL

- 47 **Wellenlängenvariation**  
Prof. Dr. Norbert Gutknecht
- 48 **news germany**

## about the publisher

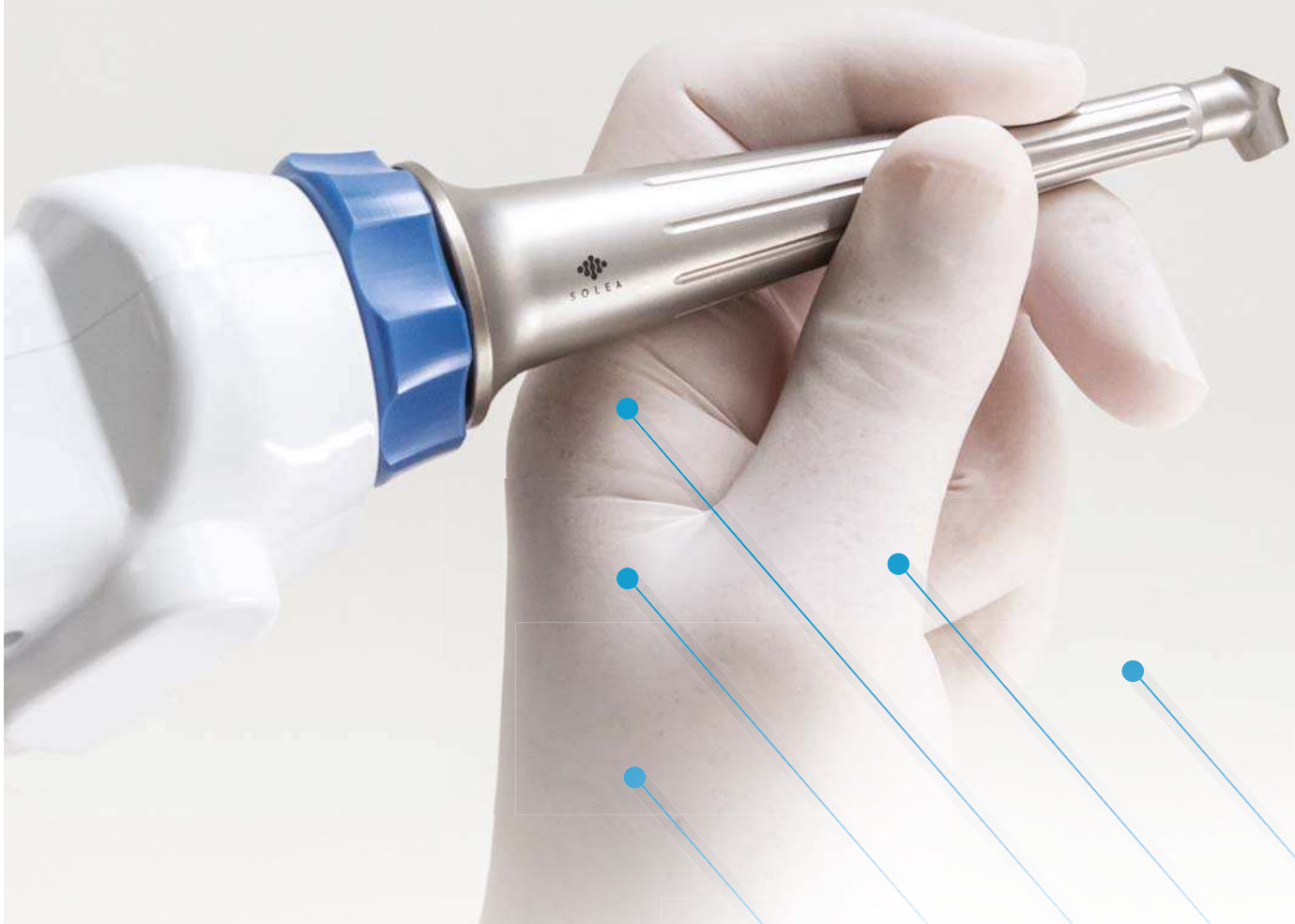- 50 Imprint



Cover image courtesy of LASOTRONIX  
[www.lasotronix.com](http://www.lasotronix.com)



# THE NEXT BIG BREAKTHROUGH IN LASERS IS HERE.



Solea® is making dentists' experience a whole lot easier. It's the first laser that can cut any tissue with a single-setting. Solea performs unlike any other laser for procedures that are reliably anesthesia-free, blood-free, suture-free and pain-free. Solea is changing what it means to go to the dentist.

SEE SOLEA FOR THE VERY FIRST TIME AT  
**THE IDS US PAVILION | HALL 2.2 BOOTH F-050**

To schedule your personal Solea hands-on session during IDS, please write us at:  
**[SOLEAIDS@CONVERGENTDENTAL.COM](mailto:SOLEAIDS@CONVERGENTDENTAL.COM)**



**CONVERGENTDENTAL**

# Periodontal therapy of deep localised pockets larger than 9 mm

## Adjunctive laser irradiation without antibiotics or open surgery

Author: Dr Gottfried Gisler, MSc, Switzerland

### 1. Introduction

The aim of this paper is to demonstrate that even "hopeless" teeth with very deep periodontal pockets of 10 mm and more pocket depth can be saved. Lasers as adjunctive therapy in periodontics have been described for a long time for the following reasons: Bactericidal effect of low-level laser application in photodynamic therapies<sup>1-4</sup> and decrease of immun-inflammatory mediators<sup>5</sup>, stimulation of wound healing with application of low-level lasers<sup>6-9</sup>, bactericidal effect<sup>10-12</sup> or better wound healing for lasers in the near infrared like diode lasers<sup>13</sup> or Nd:YAG lasers<sup>14,15</sup>,

calculus removing<sup>16,17</sup>, and bactericidal effect with lasers in the middle infrared<sup>18-20</sup> and stimulation of bone healing with Er:YAG lasers<sup>21</sup>.

To achieve the above-mentioned effects of laser irradiation, the laser energy must be absorbed in the specific chromophores or absorbers of the tissues. The graph by Meister et al.<sup>22</sup> in Fig. 1 gives a perfect overview about the different wavelengths and their chromophores applied in clinical situations. It can be seen that there is a high absorption in water for lasers in the mid-infrared like Er:YAG or Er,Cr:YSGG. A lower absorption was found for hydroxyapatite. The absorption constant of  $10^2/\text{cm}$  in hydroxyapatite can lead to misunderstandings of ablation in hydroxyapatite containing tissues like bone or dental hard tissues. If ablation in these tissues would occur by absorption in the secondary absorber for these wavelengths in the mid-infrared, the hydroxyapatite crystals would be strongly heated above the melting point and the generated heat would be transferred by conduction directly in the irradiated hard tissue.

Ablation of dental hard tissues and bone occurs by absorption in water for the wavelengths in the middle infrared. As can be seen in Fig. 1, the absorption curve shows a very high absorption in water at about  $10^4/\text{cm}$ . If water covers the irradiated surface during ablation, dental hard tissue and bone removal is achieved by explosive (water-mediated) ablation, so-called thermo-mechanical ablation.<sup>23</sup> In this process, light is absorbed by water molecules, rapidly heating a small volume. The vaporisation of water

Fig. 1: Light absorption constants  $\mu_A$  of biological materials.<sup>22</sup>

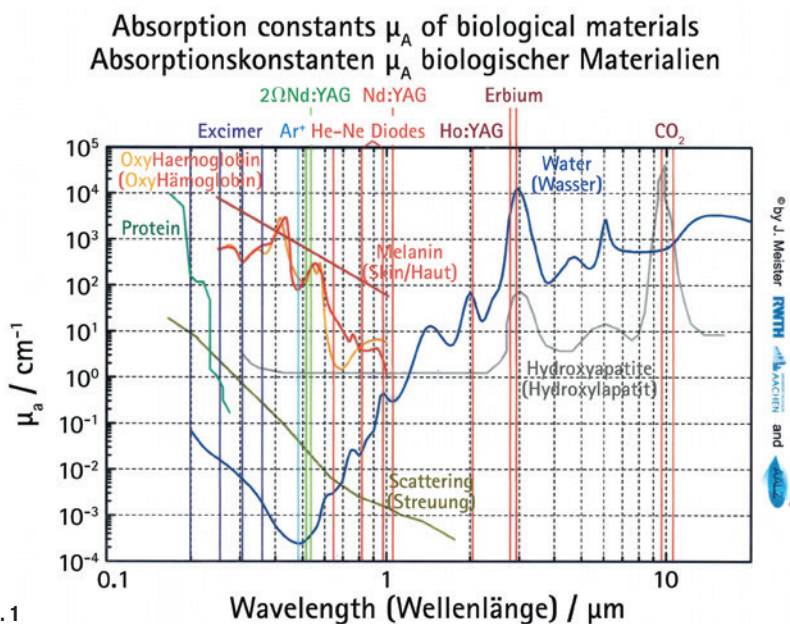
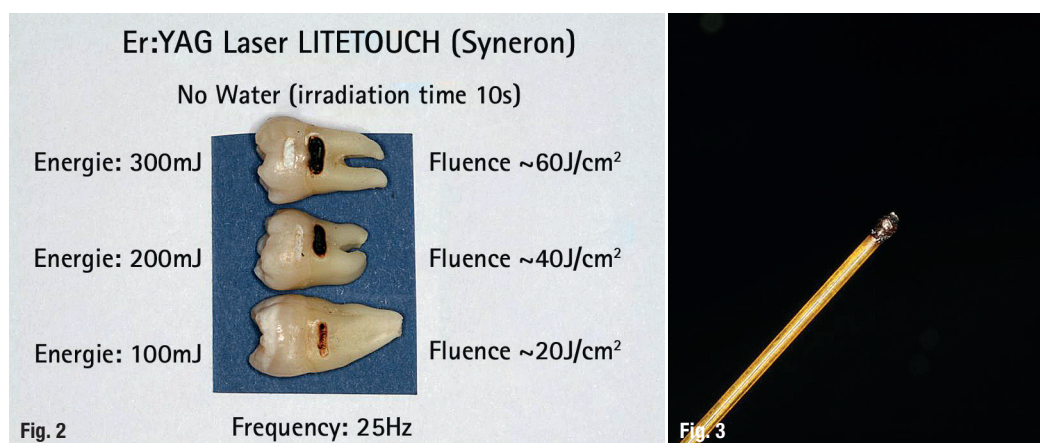


Fig. 1



**Fig. 2:** Irradiation effect by absorption of the Er:YAG laser energy in hydroxyapatite in dentine. After 10s of irradiation with no water at 25Hz, dentine will be carbonised even with an applied fluence of only 20J/cm<sup>2</sup>. A tooth irradiated for 10s with a fluence of ~60J/cm<sup>2</sup> becomes very hot, quite warm at ~40J/cm<sup>2</sup> and still warm at ~20J/cm<sup>2</sup>. In enamel there is less ablation but a strong heating.

**Fig. 3:** A "hot spot" at the fibre end of the diode laser is black burned tissue. Energies emitted with such a fibre end would bring the contrary desired therapeutic effect.

creates a strong subsurface pressure and leads to an explosive removal of the surrounding mineral.<sup>24,25</sup> The removal of hard tissue is done by micro-explosions far below the melting point of these tissues. If water does not cover the irradiated surface of bone or teeth, e.g. when the dentist's assistant sucks off the water spray during cavity preparation, the tissue water of the hard substances would be consumed by absorption very fast and the absorption takes place in the secondary absorber, the hydroxyapatite, which leads immediately to a strong overheating.<sup>26</sup> The clinical effect is carbonisation of the irradiated tissue (Fig. 2).

The chromophores that an Er:YAG or Er,Cr:YSGG laser in a periodontal pocket can identify are water or hydroxyapatite (Fig. 1). The laser user executing a closed curettage by such a laser has to avoid any absorption in hydroxyapatite. Therefore, the tissue water in the pocket must be sufficient to provide an absorption of the energy solely in water.

Calculus removal in a closed subgingival situation working with an Er:YAG laser must obey the same biophysical background. The water content of calculus<sup>27</sup> is similar to fresh dentin. Therefore the ablation threshold for both materials must be close together. If big masses of subgingival calculus should be removed only by an Er:YAG or Er,Cr:YSGG laser, working efficiently demands high energy densities. The risk to remove healthy subgingival dentin by a wrong angulation of the laser tip towards dentin or a too high energy (180mJ) then is very high.<sup>28</sup> In safety guidelines for laser removal of dental calculus<sup>29</sup> the Japanese society for laser dentistry recommends that the laser tip should be parallel<sup>30,31</sup> to the root surface and the applied laser energy be about 40mJ.

Er:YAG and Er,Cr:YSGG lasers are suitable tools for working in the subgingival periodontal area because of its biophysical background. Ablation of soft and hard subgingival deposits without any pathological thermal side effects is possible, bactericidal ef-

fects<sup>18-20</sup> with energy densities far below 10J/cm<sup>2</sup> are given, bone healing is stimulated<sup>21</sup>, and no discomfort for the patients after treatment is to be expected. The most important thing for closed working in very deep pockets of 10mm and more with these wavelengths is to avoid any absorption of the laser energy in hydroxyapatite. There are many authors<sup>32-35</sup> working in a closed subgingival setting with Er:YAG lasers and power settings of 160mJ, 10Hz and energy densities of 20J/cm<sup>2</sup> and more. But it is obvious that the higher the applied energies and the deeper the periodontal pockets are, the greater is the risk of causing damage in the hydroxyapatite-containing tissues like alveolar bone or root dentine because of absorption of the laser energy in the secondary absorber. To minimise this risk, we present seven cases working with the Er:YAG laser with energy densities close above the ablation threshold of bone and dentin.<sup>36</sup>

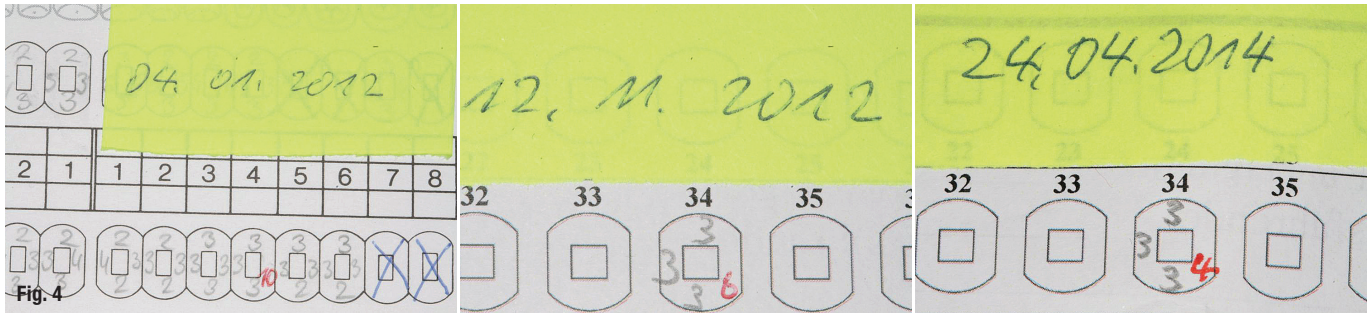
## 2. Material and Methods

Seven clinical cases, four of women and three of men aged between 48 and 74 years are presented. Eight periodontal pockets larger than 9mm were treated with pocket depths between 10 and 12mm. The tooth mobility degree (TM) of six teeth was 4. Not only was the horizontal mobility measured, but also the vertical mobility. One tooth 33 in case 4 had been already fixed by a crown to the neighbouring tooth and tooth 16 in case 5 had enough stability despite the 11mm deep pocket.

All patients had to pass a strict therapy protocol including:

- patient instruction for an adequate oral hygiene,
- evaluation and elimination of the pockets' cause,
- splinting the teeth except TM < 3
- conventional pocket therapy with scaling and root planing (SRP)
- laser irradiation

Laser irradiation includes three wavelengths of  $\lambda = 670\text{ nm}$ ,  $\lambda = 810\text{ nm}$ , and  $\lambda = 2,940\text{ nm}$ .



**Fig. 4:** Development of the clinical pocket depth. From the left: 4 January 2012, 12 November 2012 and 24 April 2014.

**2.1 The conventional treatment protocol**

The patient had to pass an oral hygiene phase prior to pocket treatment, followed by a first pocket treatment session, including:

- Splinting the tooth with wire and traditional or acrylic and glass fibre reinforced composites (ever-Stick®).
- Elimination of the pockets cause or causes, e.g.
  - endo/perio laesions → begin endodontic treatment,
  - occlusal traumata → eliminate pre-contacts or hyperbalances etc.,
  - food impaction (FI) → close the gap with reconstructive methods,
  - foreign bodies → remove them,
  - no attached gingiva → if periodontal treatment is successful → free gingival graft (FGG),
  - special pathogen bacteria like Aa → decontamination by laser light.
- SRP under local anaesthesia.

In up to three or four following sessions, the conventional treatment always consists of only ultrasonic cleaning of the treated pockets to remove any plaque formation without anaesthesia and finishing of the conservative therapies (endodontic treatment, fillings, occlusion, FGG, etc.).

The therapy of deep pockets greater than 9 mm demands at least three, oftentimes four laser applications in time intervals between four to ten days. During the whole treatment period, when common prophylactic actions in the treated area are impossible or contra productive, the patients have to rinse their mouth with 0.2% Chlorhexidine (CHX) solution. The healing of the periodontally treated area with correctly applied

laser therapy is almost painless for the patient, fast and without any uncomfortable side effects.

To understand why the local application of laser energy is able to replace antibiotics and to substitute augmentation procedures in many cases, it is indispensable to know the biophysical background of the therapeutic effects of the different laser wavelengths. Antibiotics must be applied only when the general health state demands antibiois and augmentation procedures are needed in aesthetically very sensitive areas.

**2.2 The laser treatment protocol**

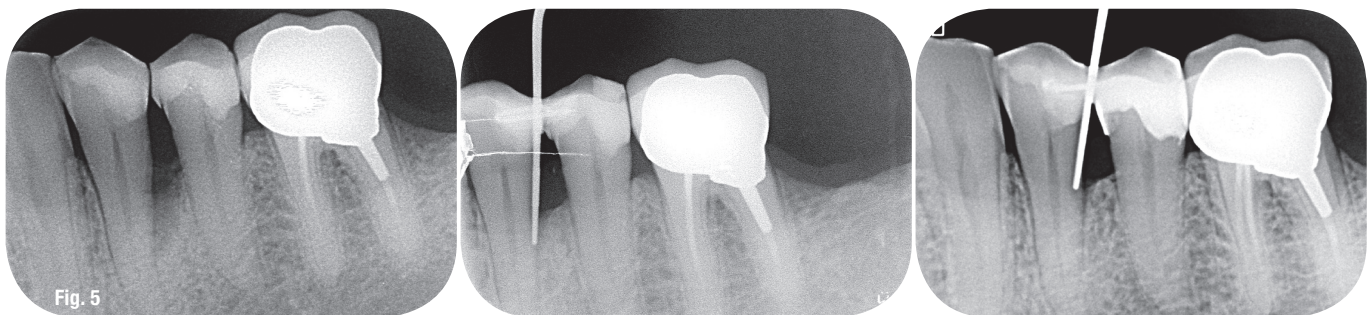
**2.2.1** The first laser treatment session follows directly after the conventional SRP under anaesthesia. The curettage is not done by conventional instruments, but by laser irradiation of an Er:YAG laser for two reasons:
 

- The laser in the middle infrared region stimulates bone growth factors.<sup>21</sup>
- The soft tissue is removed by the laser in a sterile way because of its ablation mechanism and disinfects the remaining soft and hard tissues.<sup>18</sup>

If we do a closed curettage of a very deep pocket of 10 mm and more pocket depth with an Er:YAG laser, it is impossible that during such irradiation the water spray gets inside of the deep pocket. The water spray has only a cooling effect from outside. Therefore, the tissue water in the pocket must be sufficient to provide an absorption of the energy solely in water. This can be safely achieved by special settings and a special technique of application. Our setting for closed pocket curettage with the Er:YAG Laser (LiteTouch, Syneron) are:

- fluence < 10 J/cm<sup>2</sup>
- energy on the device display: 50 mJ

**Fig. 5:** Radiological situation of bone regeneration. From the left: 4 January 2012, 12 November 2012 and 24 April 2014.





AVAILABLE  
NOW



Introducing

**Waterlase**  
*express*<sup>™</sup>

&

**Epic**  
*pro*<sup>™</sup>

The Smallest, Easiest and Most Cost-Effective Erbium Laser from BIOLASE yet!

Waterlase Express<sup>™</sup> is the **all-new, fifth-generation Er,Cr:YSGG laser** from BIOLASE that features powerful clinical animations included for each procedure. You can start performing REPAIR<sup>™</sup> Perio and Implant laser treatment — plus many other procedures with our smallest, most cost-effective Erbium laser yet.

Soft Tissue Management Redefined.

Epic Pro<sup>™</sup> is the **first premium diode laser** in dentistry and offers practical, clinical, and financial value to dental practices looking to redefine what it means to manage soft tissue.

EXPERIENCE THE **ALL-NEW**  
WATERLASE EXPRESS AND EPIC PRO AT IDS 2017!

**Hall 04.2, Stand L060 M061**

**BIOLASE**

biolase.com