

laser

international magazine of laser dentistry

I S L D



case report

The use of the Er:YAG laser in aesthetic dentistry

industry

Laser enucleation of a radicular cyst with the PIPS protocol

interview

On unifying the laser family



damus



M.Sc. Lasers in Dentistry

Specialist in dental laser therapies

Next Start: **23rd September 2019** | Aachen, Germany | 4 semesters

Aachen Dental Laser Center - AALZ
Pauwelsstraße 17 | 52074 Aachen | Germany
phone +49 241 47 57 13 10 | fax +49 241 47 57 13 29
info@aalz.de
www.aalz.de

RWTH International Academy
Kackertstraße 10 | 52072 Aachen | Germany
phone +49 241 80 23543 | fax +49 241 80 92525
info@academy.rwth-aachen.de
www.academy.rwth-aachen.de



Aachen Dental Laser Center

**INTERNATIONAL
ACADEMY**

**RWTH AACHEN
UNIVERSITY**

PROFESSIONAL EDUCATION PROGRAMMES

Your contact for more information: Leon Vanweersch • vanweersch@aalz.de - www.aalz.de

Prof. Dr Norbert Gutknecht

ISLD President and Scientific Chairman



Welcome to the European Capital of Culture

Dear friends and colleagues,

It is a great honour and a pleasure for me to invite you to our ISLD Congress in Plovdiv, Bulgaria, for an unforgettable experience of technology and culture going hand in hand to create an outstanding event. I am also very happy about the decision for DGL to join ISLD by executing their annual congress together with the ISLD in Plovdiv.

Plovdiv, established 4,000 years ago and, therefore, being the oldest city in Europe, celebrates this year its appointment as European Capital of Culture. There will be an array of attractive events all year around where people from all over Europe and other parts of the world will come to Plovdiv to enjoy participating in the celebrations and experiencing art works by many international artists. Against this backdrop, Plovdiv, the European Capital of Culture 2019, was a natural choice and unanimously selected as the best site to hold the 17th World Laser Congress of ISLD.

The International Society for Laser Dentistry (ISLD) was established in Japan in 1988. Thirty years later, the ISLD celebrated its Pearl Anniversary during the Laser Dentistry World Congress held in Aachen, Germany. The congress was a great success and more than 540 participants from 43 countries enjoyed a high level of scientific presentations, warm hospitality and a friendly atmosphere. It was, indeed, an unforgettable event and an ideal time for staging the revival of our prestigious Dental Laser Society.

Myself and many other colleagues representing numerous national dental laser societies were determined to

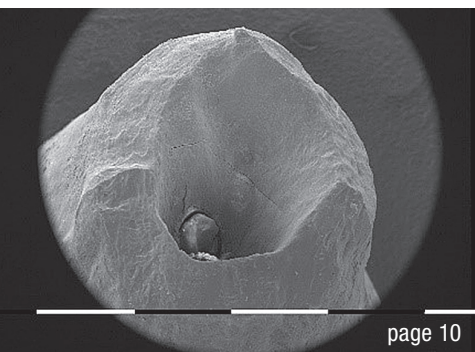
place ISLD as an outstanding scientific organisation in laser dentistry.

We feel very much encouraged to see more and more new membership applications. Colleagues from all over the world are eager to join ISLD and the number of national laser societies that choose to be part of our organisation is constantly growing. I believe that all of us, dental laser users worldwide, would like to see a bright future for Laser Dentistry. Your participation in our upcoming ISLD Congress, which will take place in Plovdiv, Bulgaria, 6–8 June 2019 is essential in strengthening ISLD and its main goal to enrich the knowledge of its members and to promote professional excellence in the use of lasers through science research and education.

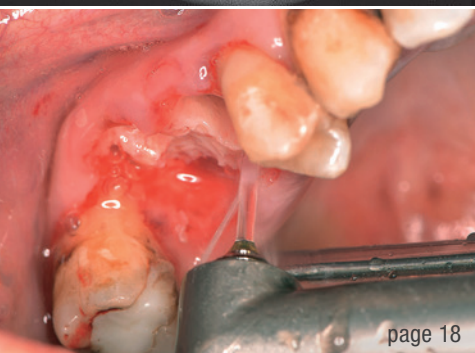
Prof. Georgi Tomov, our organising Chairman and his team, together with the Bulgarian Society for Laser Dentistry are already in full action and look forward to hosting us in their attractive city. I also look forward to seeing you joining us in a great celebration of science and art under the umbrella of ISLD, the leading World Laser Dentistry Organisation in beautiful Plovdiv. Welcome to Plovdiv in 2019.

Yours,

Prof. Dr Norbert Gutknecht



page 10




page 18



page 26

Cover image courtesy of Fotona d.o.o.
www.fotona.com



editorial

- Welcome** to the European **Capital of Culture** 03
Prof. Dr Norbert Gutknecht

case report

- Amalgam tattoo removal** with diode laser 06
Dr Maziar Mir, Prof. Norbert Gutknecht, Dr Masoud Mojahedi,
Dr Jan Tunér, Prof. Ramin Mosharraf, Sevda Noori & Dr Masoud Shabani
- Apicectomy** of an endodontically compromised **central incisor** 10
Drs Georgi T. Tomov & Mutlu S. Turkkan

- The use of the **Er:YAG** laser in **aesthetic dentistry** 14
Prof. Roly Kornblit

industry

- Laser enucleation of a **radicular cyst** with the **PIPS protocol** 18
Dr Betül Göfteci
- A simple **design improvement** of Waterlase iPlus® 22
Peter Hünnebeck, Dr Sophia Hünnebeck, Dr Roland Ventura

practice management

- Successful **communication** in your **daily practice** 24
Dr Anna Maria Yiannikos

interview

- On unifying the **laser family** 26

events

- Ceramic implants**—Game changer in **implant dentistry** 30
- Prophylaxis **works** and offers **future potential** 32
- Plovdiv to become European **Capital of Laser Dentistry** 33

news

- manufacturer **news** 36
- news** 38

about the publisher

- imprint 42

The universe at your fingertips.

● LightWalker

The highest technology dental laser system

Supreme clinical results:


- TwinLight® Perio Treatments
- TwinLight® Endo Treatments
- No-sutures soft-tissue surgery
- Patient-friendly conservative dentistry
- Pre-sets for over 40 applications

Unmatched simplicity of use:

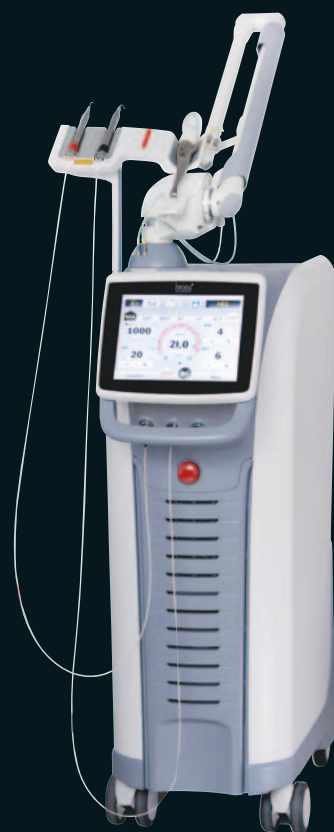- Balanced and weightless OPTOflex® arm
- Nd:YAG handpiece detection system
- Quantum Square Pulse technology for fast minimally invasive treatments
- X-Runner™ - the first digitally controlled Er:YAG dental laser handpiece

Visit Fotona's booth (Hall: 10, Plain: 2, Aisle: M, No: 050) to find out more about our latest high-performance, ASP-powered LightWalker laser systems and minimally invasive dental solutions.



 Fotona App

IDS
2019



Amalgam tattoo removal with diode laser

Dr Maziar Mir, Prof. Norbert Gutknecht, Dr Masoud Mojahedi, Germany; Dr Jan Tunér, Sweden; Prof. Ramin Mosharraf, Sevda Noori & Dr Masoud Shabani, Iran

Introduction

An amalgam tattoo belongs to the group of common pigmented lesions in the oral cavity. Such tattoos are created through emergence of amalgam particles into the damaged oral mucosa during placement of amalgam fillings or a discolouring of the soft tissue close to the amalgam filling over time. Clinically, amalgam tattoos appear as bluish-black or bluish-grey lesions on the oral mucosa, most commonly on the gingival surfaces, alveolar mucosa and buccal mucosa. The incidence of amalgam tattoos has been reported as up to 8 per cent of samples surveyed.^{1,2}

The clinical appearance of the lesion and the presence of radiopaque amalgam fragments in radiographs are enough to diagnose an amalgam tattoo. If no metallic fragments can be identified in a radiograph, a biopsy of the lesion is recommended to rule out melanocytic neoplasia. Unless for aesthetic reasons, treatment of an amalgam tattoo is not necessary.^{3,4} Owing to the severity of melanoma, clinicians must differentiate between benign lesions and serious lesions, most notably melanoma. Based on the pigment origin, a bluish-black or bluish-grey pigmented lesion may be classified as an endogenous or exogenous pigmented lesion. Based on the involved areas, such lesions are further differentiated into localised and diffuse pigmentations.

Localised bluish-black or bluish-grey pigmented lesions include:

1. pigmentation due to metals like amalgam, graphite, lead (in the oral cavity, amalgam tattoos usually occur near restorations);
2. melanotic macule (small in size, mostly occurs on lips, due to increase in melanin synthesis);
3. naevus (increased proliferation of melanocytes, usually innate/congenital);
4. malignant melanoma (dark, irregular borders, asymmetrical and rapid in growth); and
5. post-inflammatory pigmentation due to healing of lesions such as lichen planus, pemphigus and pemphigoid disease.

Diffuse pigmentations include:

1. physiological pigmentation (present from birth);
2. smoker's melanosis (due to history of smoking);
3. endocrine disorders like Addison's disease/Cushing's syndrome (based on systemic signs and symptoms);
4. HIV-associated melanosis (based on ELISA test for HIV); and
5. pigmentations associated with syndromes, such as McCune–Albright and Peutz–Jeghers (requires general examination for other associated features).

All of the above-mentioned lesions have to be considered in differential diagnosis when considering the treatment of such darkly pigmented areas in the oral cavity.⁵

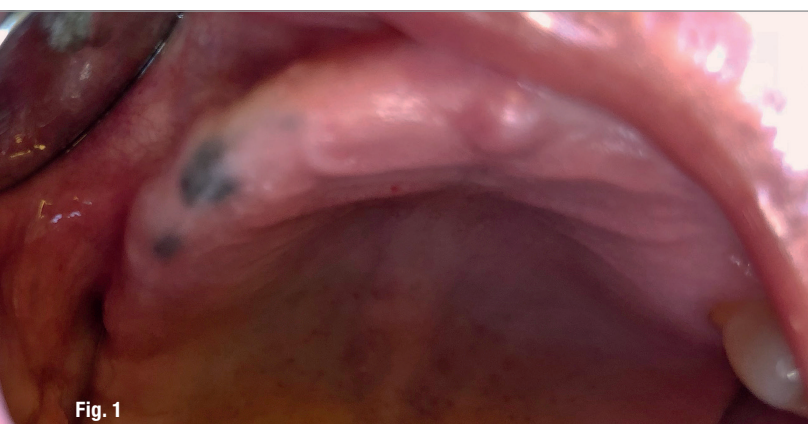


Fig. 1

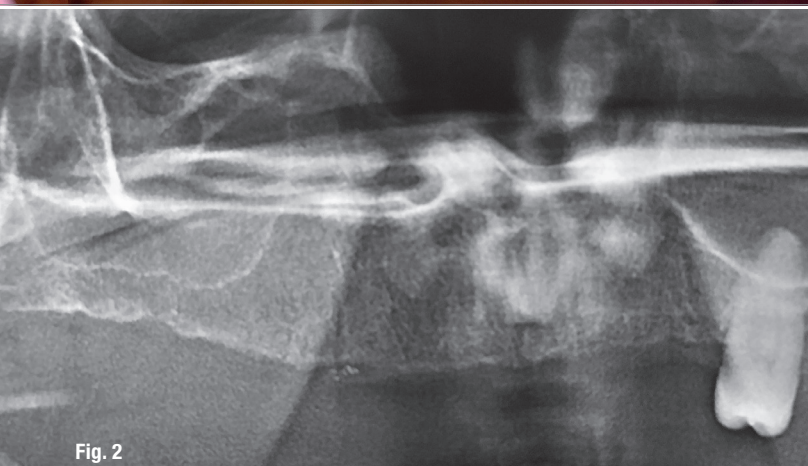

Fig. 2

Fig. 1: Clinical appearance of the amalgam tattoo at the alveolar ridge.

Fig. 2: Radiograph showing some amalgam particles at the lesion site.

Once amalgam tattoo diagnosis has been confirmed, treatment may be performed with a dental laser, surgical blade or placement of subepithelial connective tissue.^{6,7}

Case presentation

A 60-year-old female patient with a dark pigment at the edentulous alveolar ridge was referred for treatment of the lesion as a pre-prosthetic preparation procedure.

Medical history

The patient's medical history showed no systemic medical problems, no allergic reaction, no medications or recreational drugs and no history of past surgical procedures; thus, the patient did not need to be referred for medical consultation.

Dental history

Oral and maxillofacial examination of the patient revealed no temporomandibular

joint disorder or myofascial disturbances, and no functional or parafunctional habits, but poor oral hygiene and a fully edentulous maxilla.

Clinical findings

The clinical examination showed a dark pigmentation on the maxillary alveolar ridge that was firm and well demarcated and caused no pain (Fig. 1).

Radiographic examination

Radiographic examination revealed the appearance of radiopaque particles at the area of the dark pigmentation (Fig. 2).

Diagnosis

An amalgam tattoo lesion was thus diagnosed and removal by diode laser was decided on.

Amalgam tattoo removal with diode laser

After the patient had completed the consent form, the operation area was anaes-

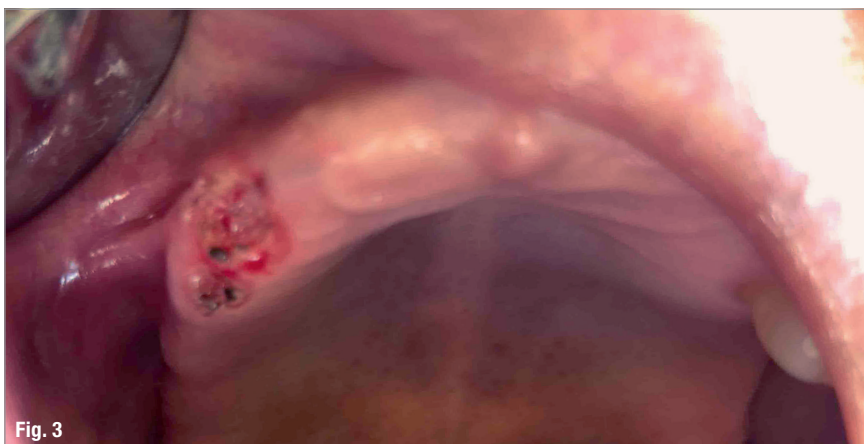


Fig. 3

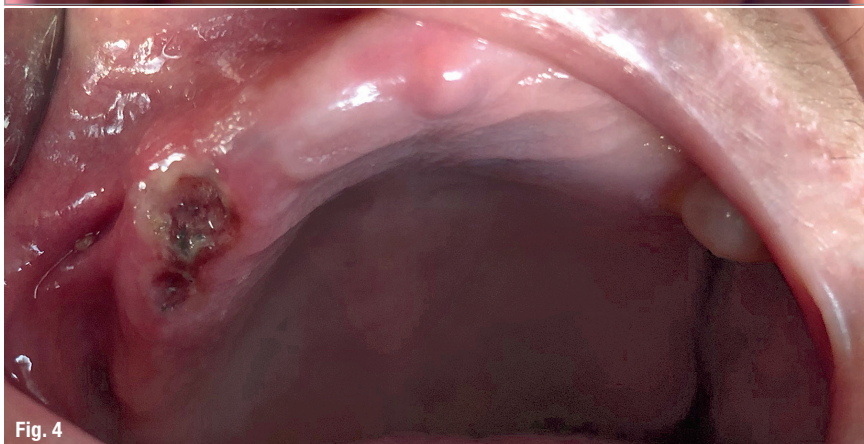


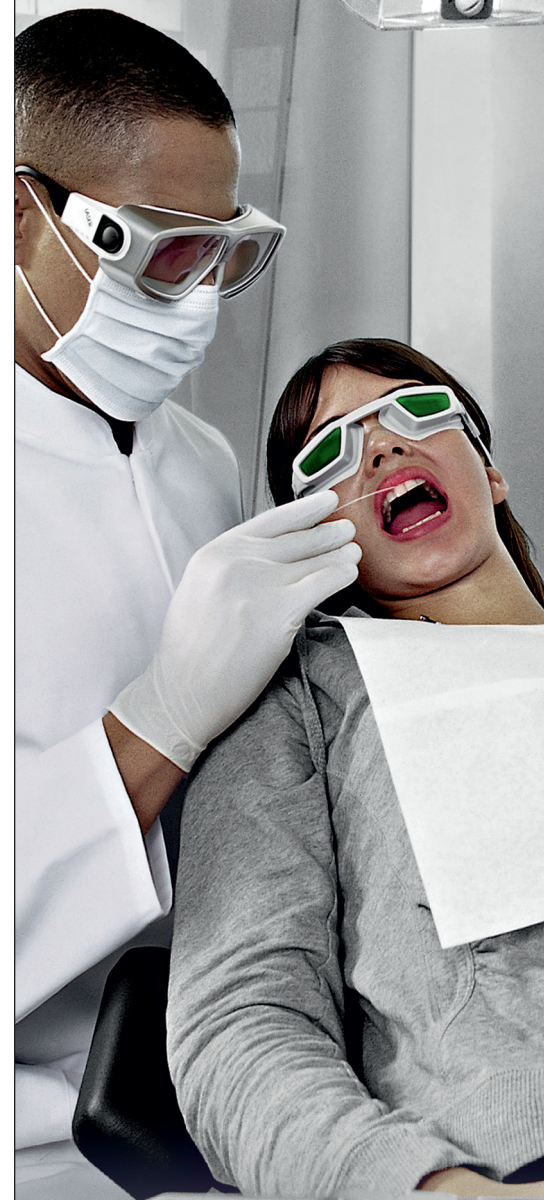
Fig. 4

Fig. 3: Situation immediately after amalgam tattoo removal. **Fig. 4:** Follow-up examination one day after amalgam tattoo removal.

laservision

shop online!

Dental Laser Protection



uvex-laservision.de

protecting people

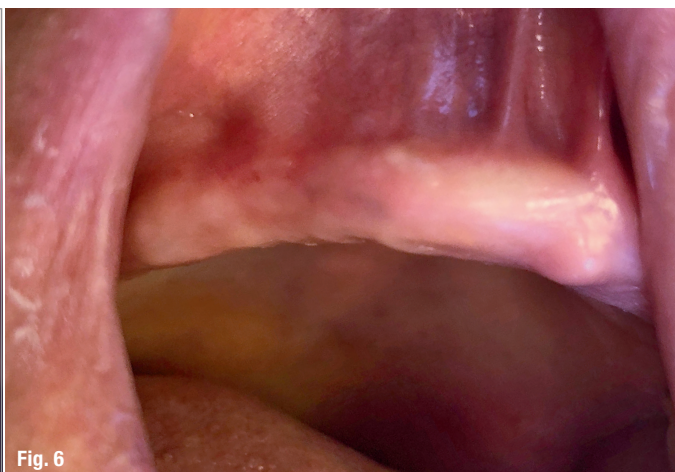
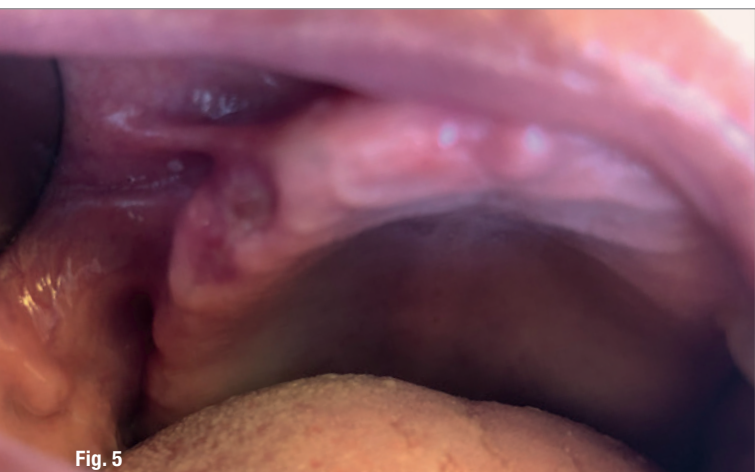
Fig. 5: Situation at the one-week follow-up. **Fig. 6:** One month after amalgam tattoo removal.

thetised through infiltration with 2 % lidocaine (1:80,000 adrenaline; 1.8ml; Darou Pakhsh Pharmaceutical).

In the next step, the controlled area was defined and laser warning signs were properly displayed to secure the operating room. After the eye protection of the patient, the patient's guardian and the assistant had been checked, the patient information (examination sheet and radiograph, consent form, etc.) was reviewed.

Mouth rinsing was done with a 0.2 % chlorhexidine oral rinse (Shahre Daru Laboratories) for about one minute. Subsequently, the amalgam tattoo was removed with a high-power diode laser (Gigaa Laser). The laser parameters applied for the amalgam tattoo removal were as follows: wavelength of 980 nm, power of 1.5W, fibre of 400 μ , initiated fibre, continuous wave and contact mode. The laser settings were registered in the patient documents.

Post-procedural education

The patient was advised on keeping the area clean, avoiding food and liquids that might have caused pain or irritation of the sensitive tissue, and taking over-the-counter analgesics as needed.

Final result

Excellent amalgam tattoo removal treatment was achieved with no bleeding, carbonisation or char. The patient did not experience any discomfort and was satisfied. The amalgam particles were removed after the soft-tissue removal (Fig. 3).

Follow-up

The first visit after treatment was scheduled for one day after the procedure (Fig. 4). The healing process was found to be as expected, with healing progressing well and without any swelling or pain. The next visit was planned for one week later (Fig. 5). Finally, at the one-

month follow-up, a successful treatment could be clinically observed (Fig. 6).

Discussion

Diode lasers are used extensively in many dental practices.⁸ Laser-tissue interaction with high-power diode lasers is based on photothermal effects.⁹ Q-switched alexandrite (755 nm), diode (980 nm) and Er,Cr:YSGG (2,780 nm) lasers have been used for amalgam removal.^{10–12}

In comparison with conventional excisional biopsy procedures (scalpel and suturing), laser-assisted amalgam tattoo removal can be performed very quickly, with no bleeding, little or no pain, less or no oedema, and a reduced or no need for analgesics. Owing to the closeness of the lesion to the alveolar bone and the prevention of heat transfer to the alveolar bone, this procedure is traditionally classified as an advanced laser procedure.

Conclusion

The application of a diode laser according to the laser protocol used in this case example proved to be a successful treatment choice for amalgam tattoo removal.

contact

Dr Masoud Shabani

Department of Community Dentistry
School of Dentistry
Ardabil University of Medical Sciences
Ardabil, Iran
m.shabani@arums.ac.ir

Author details



HEILEN MIT DER KRAFT DES LICHTS

LASER EINFACH, SICHER & SANFT

A.R.C.
LASER

Fotona
choose perfection

www.henryschein-dental.de



HENRY SCHEIN DENTAL – IHR PARTNER IN DER LASERZAHNHEILKUNDE

Wir bieten Ihnen ein breites und exklusives Sortiment marktführender Lasermodele verschiedener Hersteller an.

Unsere Laserspezialisten beraten Sie gern über die vielfältigen Möglichkeiten und das für Sie individuell am besten geeignete System.

Laser ist nicht gleich Laser und genau hier liegt bei uns der Unterschied:

Sie, Ihre Patienten und Ihre gemeinsamen Bedürfnisse stehen bei uns an erster Stelle.

Bei Henry Schein profitieren Sie vom Laserausbildungskonzept!

Von der Grundlagenvermittlung über hochqualifizierte Praxistrainings und Workshops zu allen Wellenlängen bis hin zu Laseranwendertreffen.

Unsere Laser-Spezialisten in Ihrer Nähe beraten Sie gerne.

FreeTel: 0800-1400044 oder FreeFax: 08000-404444

Erfolg verbindet.

 **HENRY SCHEIN®**
DENTAL