

IMPLANT TRIBUNE

The World's Dental Implant Newspaper · U.S. Edition

MARCH 2009

www.implant-tribune.com

VOL. 4, No. 3

Better horizontal ridge expansion

Using advanced minimal-invasive instruments and techniques allows for concomitant implant placement and regenerative procedures

By Liviu Steier & Gabriela Steier, U.K.

This 54-year old patient regularly attends our practice and takes part in our quarterly preventative program. His anamnesis contains no special entries. Figure 1 shows that the patient has lost tooth 12 as a result of a previously unsuccessful root canal treatment, followed by an unsuccessful apicotomy.

The prosthetic work has been in-situ for a long time and was performed alio loco. Secondary decay at the crown margins of tooth 11 created the need of prosthetic retreatment.

The different treatment options were explained in great detail to the patient, one of which was fixed restoration using implants. The patient decided on implantation in position 12, and was told that as a consequence of local infection, apicotomy and long-term tooth loss, the alveolar ridge has collapsed and guided bone regeneration would be needed to restore the optimum anatomical condition.

The existing porcelain fused to metal bridge (abutment teeth = 13 and 11, pontic = 12) was removed, decay eliminated and new adhesive core build-ups performed. Buccal infiltration anesthesia was given

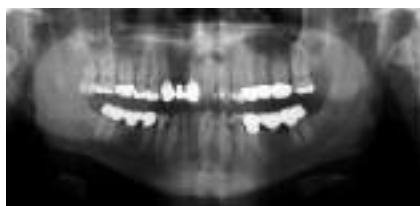

Fig. 1: Digital PAN before treatment.

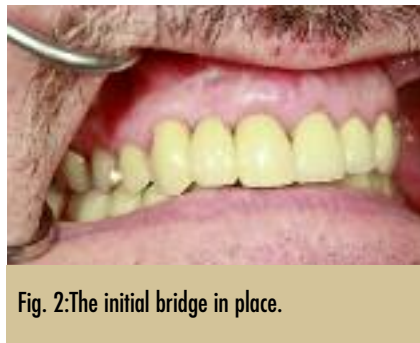


Fig. 2: The initial bridge in place.

and the patient was offered a new metallic, composite, veneered bridge.

A full gingival flap was raised, allowing the extensions of the bone resorption to be identified. It was obvious that implant placement without bone augmentation could not be performed. The two treat-

→ IT page 6

San Diego welcomes a 'New Wave' with AO



The Academy of Osseointegration Annual Meeting took place at the San Diego Convention Center from Feb. 26–28.

Group's annual meeting features innovations in implant therapy

By Robin Goodman, Group Editor

San Diego, California's second largest city, welcomed attendees to the Academy of Osseointegration's 24th Annual Meeting with its gentle Mediterranean climate and beckoned them outside during the breaks between lectures.

However, the exhibit hall proved to be quite a draw as well. After the boxed lunches distributed in the exhibit hall were consumed, the proximity of more than 120 booths made it difficult

to exit before stopping to get up close and personal with the items on display.

Thursday, Feb 26, the first day of the meeting, was filled with well-attended corporate forums from some of the biggest names in the business — BioHorizons, BIOMET 3i, Nobel Biocare, OsteoHealth, Piezosurgery, Straumann, Sybron Implant Solution and Zimmer Dental.

During the opening symposium, which featured music by a live three-piece jazz band while attendees took their seats, AO President Steven G. Lewis, DMD, started off a full afternoon of lively lectures that lasted until 5:15 p.m.

→ IT page 18

AD

Experience
EXCELLENCE
IN COSMETIC DENTISTRY 2009
www.aacd.com • 800.543.9220
25th ANNIVERSARY AACD SCIENTIFIC SESSION
Monday, April 27 - Friday, May 1, 2009 • HONOLULU, HAWAII

AMERICAN ACADEMY OF COSMETIC DENTISTRY
CELEBRATING 25 YEARS OF EXCELLENCE

Dental Tribune America
213 West 35th Street
Suite #801
New York, NY 10001

PRSR STD
U.S. Postage
PAID
Permit # 306
Mechanicsburg, PA

Composite shows significantly higher new bone regeneration

The key to success for dental implants lies in the volume and quality of the bone in the recipient. Because a scarce amount of bone is often a problem, guided bone regeneration is a well-established solution.

A study in the current issue of the *Journal of Oral Implantology* demonstrates complete bone regeneration of critical-size bone defects using a composite alloplastic graft of beta-tricalcium phosphate (β -TCP) in a calcium sulfate (CS) matrix without a membrane barrier.

Tricalcium phosphate (TCP), which is considered bioactive and biocompatible, is an alloplastic ceramic material that shows promise as a bone graft substitute. TCP cements have a slower resorption rate than bone, however, and are rather dense.

By adding a faster resorbing material, pores may be created, ensuring new bone tissue growing into the defect. CS is a material that can fill that need.

When CS is mixed with other

bone graft materials, the osteogenesis is accelerated, the study finds. Calcification is increased and the needed quantity of new bone is achieved in a shorter period of time.

In the study, two types of bone substitute were tested: Fortoss Resorb[®], a porous β -TCP synthetic graft, and Fortross Vital[®], a synthetic composite biomaterial based on a porous β -TCP in a matrix of CS.

Artificial defects were created on each iliac crest in four dogs. The experimental defects were treated in three groups: β -TCP alone (Fortoss Resorb), β -TCP in a CS matrix (Fortross Vital), and ungrafted to heal spontaneously.

After these defects were left to heal for four months, a significant difference was shown between the two β -TCP groups. The study concludes that the " β -TCP/CS combination demonstrated complete regeneration up to the cortex in all 10-mm specimens tested, while β -TCP alone did not succeed in regenerating these large-diameter defects."

The full text of the article, "Bone

Regeneration Using Beta-Tricalcium Phosphate in a Calcium Sulfate Matrix," is available at www.allenpress.com.

About Journal of Oral Implantology

The *Journal of Oral Implantology* distinguishes itself as the first and oldest journal in the world devoted exclusively to implant dentistry. The official publication of the American Academy of Implant Dentistry and of the American Academy of Implant Prosthodontics, the journal is dedicated to providing valuable information to general dentists, oral surgeons, prosthodontists, periodontists, scientists, clinicians, laboratory owners and technicians, manufacturers, and educators. Topics include implant basics, prosthetics, pharmaceuticals, the latest research in implantology, implant surgery, and advanced implant procedures. To learn more about the society, visit www.aaaid-joi.org.

(Source: *Journal of Oral Implantology*)

Nobel Biocare unveils results from largest U.S. consumer dental survey

Survey reveals almost 50 percent have missing teeth and few understand the health consequences

Nobel Biocare announced the results of the largest known consumer survey in dentistry at the 24th Annual Meeting of the Academy of Osseointegration in late February. The survey, which evaluated the responses of nearly 55,000 consumers, provides new insight into the prevalence of missing teeth in America and the general lack of understanding about the health consequences of missing teeth.

The survey revealed the emphasis consumers place on their smile when considering their overall appearance. The survey found that smile and appearance of teeth scored the highest (first and second, respectively) in

terms of importance to personal appearance — exceeding hair, clothes, eyes, facial features and physique. In fact, nearly 90 percent of respondents ranked their smile as the most important attribute and almost 87 percent ranked the appearance of teeth as the second most important feature.

"As dentists, we are very aware of the underlying health issues that can be associated with missing teeth. In this survey, we wanted to better understand how missing teeth affected patients on an emotional level and determine their awareness of the associated consequences," said Dr. Neil Park, vice president of professional relations, Nobel Biocare. "The results from this survey have provided us with a deeper understanding of the importance of a smile to people, and underscore the need for better consumer education highlighting the consequences of tooth loss and the available treatment options that can

increase satisfaction."

The survey revealed that nearly 50 percent of adults are missing at least one tooth. While most adults were aware of the visible consequences of missing teeth, including difficulty chewing food and impact to the appearance of a smile, there was limited awareness of the more serious health consequences, which can include bone loss that may lead to changes in the shape of the face and repositioning of existing teeth.

While there was a very strong correlation between prevalence of missing teeth among lower income households and among those with less educational achievement, the presence of missing teeth was still shown to have a remarkably high prevalence even among adult Americans with higher incomes.

For more information visit www.usdentalsurvey.com.

(Source: *Nobel Biocare*)

IMPLANT TRIBUNE

The World's Newspaper of Implantology - U.S. Edition

Publisher
Torsten Oemus
t.oemus@dtamerica.com

President
Peter Witteczek
p.witteczek@dtamerica.com

Chief Operating Officer
Eric Seid
e.seid@dtamerica.com

Group Editor
Robin Goodman
r.goodman@dtamerica.com

Editor in Chief
Sascha A. Jovanovic, DDS, MS
sahara@jovanoviconline.com

Managing Editor/Designer
Sierra J. Rendon
s.rendon@dtamerica.com

Managing Editor Endo Tribune
Fred Michmershuizen
f.michmershuizen@dtamerica.com

Managing Editor Ortho Tribune
Kristine Colker
k.colker@dtamerica.com

Account Manager
Humberto Estrada
h.estrada@dtamerica.com

Marketing Manager
Anna Wlodarczyk
a.wlodarczyk@dtamerica.com

Marketing & Sales Assistant
Lorrie Young
l.young@dtamerica.com

C.E. Manager
Julia Wehkamp
j.wehkamp@dtamerica.com

Design Support
Yodit Tesfaye
y.tesfaye@dtamerica.com

Dental Tribune America, LLC
215 West 55th Street, Suite 801
New York, NY 10001
Phone: (212) 244-7181, Fax: (212) 244-7185



Published by Dental Tribune America

© 2009, Dental Tribune International GmbH. All rights reserved.

Dental Tribune makes every effort to report clinical information and manufacturer's product news accurately, but cannot assume responsibility for the validity of product claims, or for typographical errors. The publishers also do not assume responsibility for product names or claims, or statements made by advertisers. Opinions expressed by authors are their own and may not reflect those of Dental Tribune International.

Editorial Advisory Board

Dr. Sascha Jovanovic, Editor in Chief

Dr. Bernard Touati

Dr. J.T. Krauser

Dr. Andre Saadoun

Dr. Gary Henkel

Dr. Doug Deporter

Dr. Michael Norton

Dr. Ken Serota

Dr. Axel Zoellner

Dr. Glen Liddelow

Dr. Marius Steigmann

IT Corrections

Implant Tribune strives to maintain the utmost accuracy in its news and clinical reports. If you find a factual error or content that requires clarification, please report the details to Managing Editor Sierra Rendon at s.rendon@dtamerica.com.

Tell us what you think!

Do you have general comments or criticism you would like to share? Is there a particular topic you would like to see more articles about? Let us know by e-mailing us at feedback@dtamerica.com. If you would like to make any change to your subscription (name, address or to opt out) please send us an e-mail at database@dtamerica.com and be sure to include which publication you are referring to. Also, please note that subscription changes can take up to six weeks to process.



SURGICAL SUPPLY CO., INC.

A POWER TRIO

FOR ALL YOUR GRAFTING NEEDS



Power-up your
in-office performance
with an ACE seminar!

ADVANCED TISSUE GRAFTING

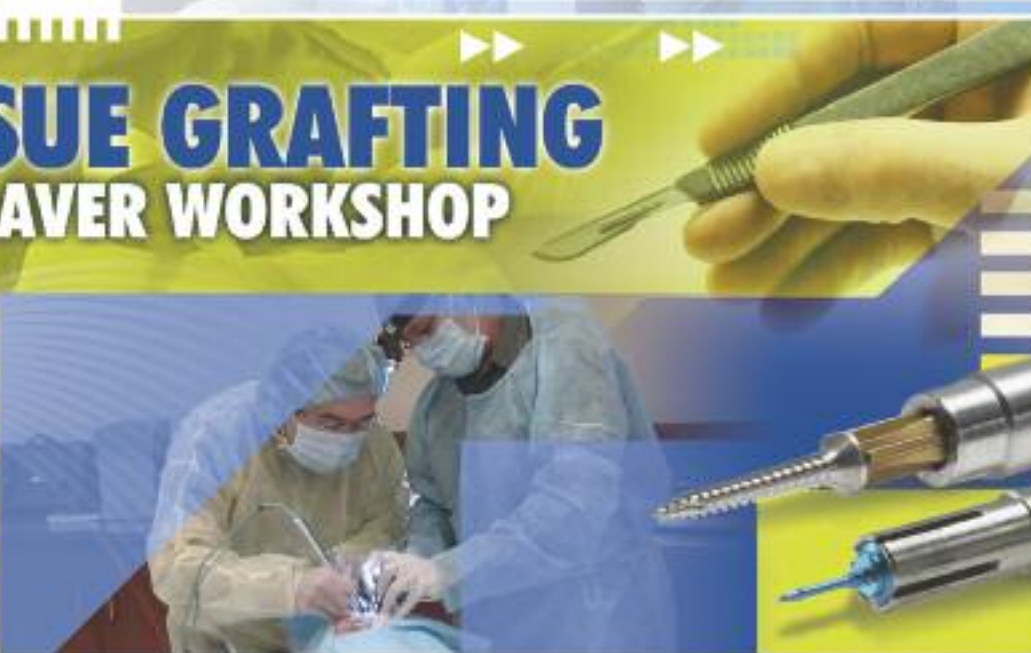2-DAY HANDS-ON CADAVER WORKSHOP

ORLANDO, FL
April 25-26, 2009

Featured Speaker:
Aron Genshor, PhD, DOS, FRCD(C), FAD

Course Location:
Walt Disney World Swan and Dolphin

Course Registration:
www.acesurgical.com/cadaver.html



800.441.3100

www.acesurgical.com

ACE Surgical Supply Company, Inc.
1034 Pearl Street, Brockton, MA 02301

Go green for healthy teeth, gums

New study suggests antioxidants in green tea may help reduce periodontal disease

With origins dating back more than 4,000 years ago, green tea has long been a popular beverage in Asian culture, and is increasingly gaining popularity in the United States. And while ancient Chinese and Japanese medicine believed green tea consumption could cure disease and heal wounds, recent scientific studies are beginning to establish the potential health benefits of drinking green tea, especially in weight loss, heart health and cancer prevention.

A study recently published in the *Journal of Periodontology*, the official publication of the American Academy of Periodontology (AAP), uncovered yet another benefit of green tea consumption.

Researchers found that routine intake of green tea may also help promote healthy teeth and gums. The study analyzed the periodontal health of 940 men, and found that those who regularly drank green tea had superior periodontal health than subjects who consumed less green tea.

"It has been long speculated that green tea possesses a host of health benefits," said study author Dr. Yoshi-

hiro Shimazaki of Kyushu University in Fukuoka, Japan. "And since many of us enjoy green tea on a regular basis, my colleagues and I were eager to investigate the impact of green tea consumption on periodontal health, especially considering the escalating emphasis on the connection between periodontal health and overall health."

Male participants aged 49 through 59 were examined on three indicators of periodontal disease: periodontal pocket depth (PD), clinical attachment loss (CAL) of gum tissue, and bleeding on probing (BOP) of the gum tissue.

Researchers observed that for every one cup of green tea consumed per day, there was a decrease in all three indicators, therefore signifying a lower instance of periodontal disease in those subjects who regularly drank green tea.

Green tea's ability to help reduce symptoms of periodontal disease may be due to the presence of the antioxidant catechin.

Previous research has demonstrated antioxidants' ability to reduce

inflammation in the body, and the indicators of periodontal disease measured in this study, PD, CAL and BOP, suggest the existence of an inflammatory response to periodontal bacteria in the mouth.

By interfering with the body's inflammatory response to periodontal bacteria, green tea may actually help promote periodontal health, and ward off further disease. Periodontal disease is a chronic inflammatory disease that affects the gums and bone supporting the teeth, and has been associated with the progression of other diseases such as cardiovascular disease and diabetes.

"Periodontists believe that maintaining healthy gums is absolutely critical to maintaining a healthy body," said Dr. David Cochran, DDS, PhD, president of the AAP and chairman of the Department of Periodontics at the University of Texas Health Science Center at San Antonio. "That is why it is so important to find simple ways to boost periodontal health, such as regularly drinking green tea — something already known to possess certain health-related benefits."



About the Journal of Oral Implantology

The *Journal of Oral Implantology* distinguishes itself as the first and oldest journal in the world devoted exclusively to implant dentistry. The official publication of the American Academy of Implant Dentistry and of the American Academy of Implant Prosthodontics, the journal is dedicated to providing valuable information to general dentists, oral surgeons, prosthodontists, periodontists, scientists, clinicians, laboratory owners and technicians, manufacturers, and educators. Topics include implant basics, prosthetics, pharmaceuticals, the latest research in implantology, implant surgery, and advanced implant procedures. To learn more about the society, visit www.aaaid-joi.org.

(Source: *Journal of Oral Implantology*)

AD

Always in control

SimPlant[®] CompatAbility

- Accurate and predictable implant treatment
- Cost-effective and highly profitable
- User-friendly
- Compatible with all implant brands and scanners

simple • compatible • unique

SimPlant[®] SurgGuide[®] Immediate Smile[®]

Materialise
Dental

www.materialisedental.com

First interventional CT scanner for dental implants in the U.S.

While 3-D CT scanners are starting to be used for dental implant planning, they are usually only available before the procedure. An innovative surgeon, Dr. Michel Matouk has devised a new protocol to improve precision by obtaining CT scans during surgical procedures, when they are most needed. This allows improved computer-planned and computer-guided implant surgery, therefore providing less invasive and more accurate placement of cosmetic dental implants.

When Peter S. was told his front tooth needed extraction, he hoped he could find a way to get immediate implant replacement under general anesthesia. "When Dr. Matouk discussed the possibility of CT scanning during the procedure to improve precision, I knew this would give the best result," he said. The scan revealed an adequate bony volume for implant placement at the exact site needed after the extraction, while he was still sedated. The implant was then placed uneventfully.

Matouk, a dental implant and maxillofacial surgeon, has been working on precision surgical navigation for years. His efforts just culminated in the development of computer-aided implantation using intra-operative CT scans. This new technology is currently limited to a few major neurosurgical academic centers and has not been applied to any dental surgery offices in the

United States. It provides real-time tracking of surgical results. The technology uses a cone beam CT (CBCT), an alternative to conventional CT, which provides three-dimensional radiographic imaging, on-site, while reducing radiation 90 percent compared to hospital-based computer-assisted tomography (CT). High-end dental implant centers are starting to offer CBCT to improve planning before the placing of dental implants. However, surgery is a fluid process and sometimes plans have to be modified; at that point, the surgeon is working "blindly." The final result can then only be evaluated after the case is finished.

One to two millimeters, however, can mean the difference between success and failure in cosmetic dental implant surgery. It is for these complex situations that Matouk, a dually licensed physician and dentist, saw the need for interventional CBCT. He researched the different CBCT systems available and chose the one with the most field of vision and least radiation, and then proceeded to modify it to allow for intra-operative interventional use. As soon as he used it, he realized the new doors that this technology opens. And while surgical procedures have not changed, now the accuracy of the final result can be confirmed prior to the end of the case.

(Source: *South Florida Dental Implant & Facial Surgery Center*)

Instant Gratification for Denture Patients

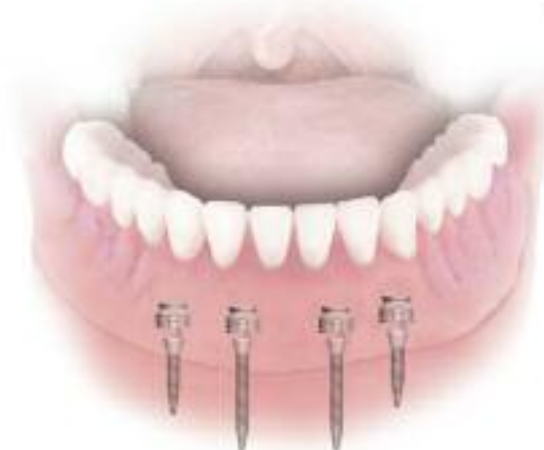

IMTEC MDI Minimally Invasive Implant System

IMTEC's Sendax MDI[®] Implant System offers a revolutionary one-hour, one-stage solution for long-term denture stabilization. This immediate loading, minimally invasive system utilizes a patented, flapless placement protocol and works with the patient's existing denture. The versatile MDI implant family includes the 1.8 and 2.1mm implants for dense bone and the 2.4 and 2.9mm implants for softer bone.



2.1mm Collared O-Ball



Celara Denture System

Proven and Profitable Technique



- Create New Dentures Quickly and Easily
- Predictable Results, Fewer Appointments, More Profitability, Increased Patient Satisfaction
- Improve Communication with your Laboratory
- 80+ Certified Celara Labs in the US

Order your Celara Training System for only \$99.00, a savings of \$70.00!
Kit includes Instructional DVD, Manual and Poster

Promo Code DT9099

Train Now!

IMTEC MDI Certification Seminar Schedule

April 18 - Atlantic City, NJ
 April 18 - Tacoma, WA
 April 24 - Keiss Kraft - Omaha, NE
 April 25 - New Orleans, LA
 May 2 - Knoxville, TN
 May 2 - St. Paul, MN
 May 8 - ADL Lab - Louisville, KY
 May 13 - da Vinci Dental - West Hills, CA
 May 15 - Sundance Dental - Scottsdale, AZ
 May 16 - Denver, CO
 May 29 - Sherer Dental Lab - Rock Hill, SC

MDI University Training

University of Oklahoma - April 25 & 26
 Oklahoma City, OK

Call 866-946-1374 for your free MDI Technique CD or visit www.imtec.com/implants

← **IT** page 1

ment options available were:

1) Vertical and horizontal bone augmentation with a healing time of at least five months and an implant placement with an additional surgery.

2) Horizontal ridge widening with immediate implant placement and bone grafting. Of course, there were advantages and disadvantages of each treatment option.

Advantages of bone augmentation and implant placement in two stages:

- Direct full control of bone augmentation procedure.
- Predictable bony support at implant placement time.
- Risk-free implant placement.

Disadvantages of bone augmentation and implant placement in two stages:

- Treatment delay by healing time of at least five months.
- Two surgical procedures needed.

Advantages of bone augmentation and implant placement at the same time:

- Single surgical procedure.
- Reduced healing time.

Disadvantages of bone augmentation and implant placement at the same time:

- Bone management knowledge skills for the surgeon requested.
- Additional technical equipment required.

Meisinger offers a so-called Split Control instrument kit it described as a “[...] minimally invasive alternative to osteotomes. Bone spreading and bone condensing with special screw-like instruments (spreaders) achieve a controlled and standardized dilation of horizontally resorbed bone and a gentle densification of cancellous bone.”

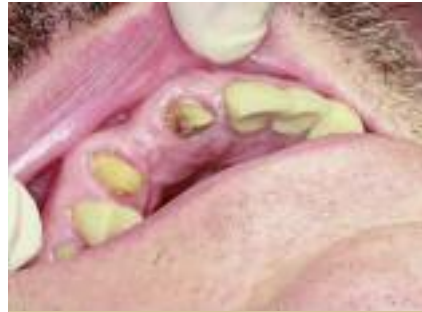

Fig. 3: Direct view of the horizontal bone resorption after removal of the temporary restoration.

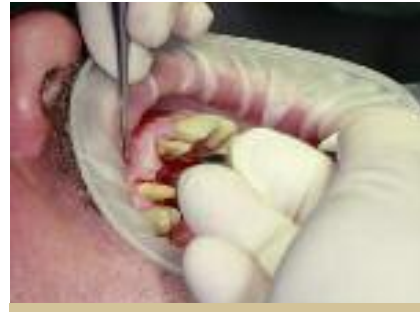

Fig. 4: Primary incision line is placed in the sulci of the adjacent teeth using a 15 C scalpel blade.

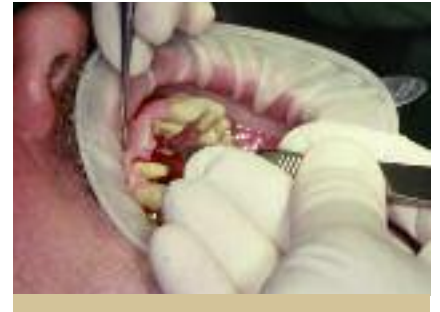

Fig. 5: Second incision: a crestal incision line lightly deviated toward the palatal complements the sulcular incisions.

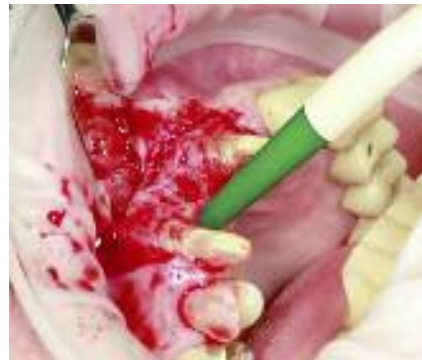

Fig. 6: Full gingival flap isolation.



Fig. 7: Split Control Kit by Meisinger.



Fig. 8: The spreaders are screwed into the bone with a hand ratchet.

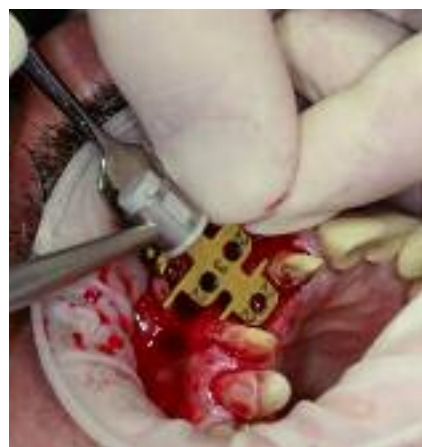

Fig. 9: Implant guide in place (Innovative Implant Technology).

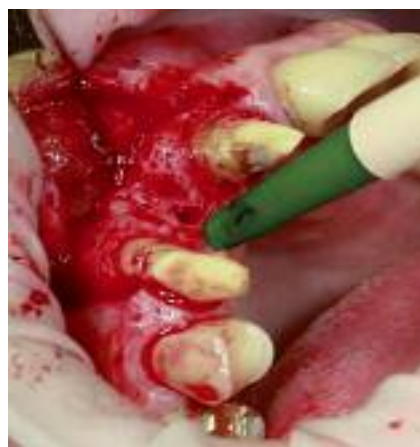

Fig. 10: Direct view of the implant alveola as performed by the manual spreaders.

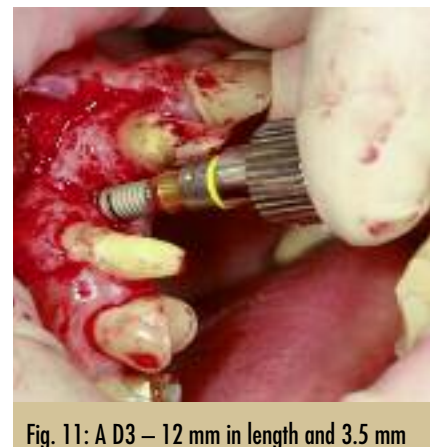

Fig. 11: A D3 – 12 mm in length and 3.5 mm diameter Biohorizons implant (external hexlock) is manually fixated and then rotary screwed into a torque of 32 N/cm2.

The Split Control Kit by Meisinger (www.bone-management.com) contains different sized screws, built similarly to a Hed-

→ **IT** page 8

AD

The Ultimate in Patient Comfort

Crescent Headrest, Backrest, Knee Support and Bodyrest
 Bring your patients comfort with memory foam cushions for their neck, back and entire body. The Knee Rest will provide your patients with pressure relief in the lower back and hips.

Available in Gray, Beige and Teal

Your Complete Source for Patient Comfort!

Crescent Osteo Headrest
 The Osteo Pillow will gently cushion the head and neck and offer support to the patient who has difficulty bringing their head to a reclined position.

Crescent Child Booster Seat
 The Crescent Child Booster Seat is the ultimate seat to have in your practice to assist in the positioning of children in the dental chair.

www.crescentproducts.com/dental.htm


To Order Call Toll-Free: (800) 989-8085

The Final Piece Of The Aesthetic Puzzle

Introducing The Encode® Zirconia Abutment

Clinicians can now provide beautiful, all-ceramic restorations with BIOMET 3i's New Encode Zirconia Abutment.

- **Zirconia Provides Strength And Aesthetics In The Anterior Zone**
- **Robocast Technology Eliminates Implant-Level Impressions And Associated Component Inventory**
- **Working Above The Gingiva Helps To Preserve Soft Tissue**



Zirconia

To find out how you can provide your patients with beautiful, all ceramic restorations, contact your BIOMET 3i Representative today.



Call Your BIOMET 3i Representative Today.
In the USA: 1-800-342-5454 • Outside the USA: +1-561-776-6700
or visit us online at www.biomet3i.com

Please Note: Not all products are available outside the U.S. Please contact your local BIOMET 3i Sales Representative for availability.

Encode is a registered trademark of BIOMET 3i LLC. BIOMET is a registered trademark and BIOMET 3i and design are trademarks of BIOMET, Inc. ©2009 BIOMET 3i LLC. All rights reserved.

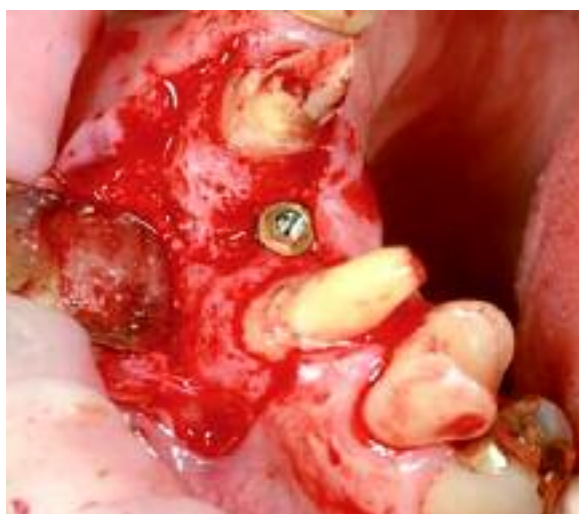

Fig. 12: Direct view of the Biohorizons implant. The neck of the implant is seated exactly at the crest of the bone level.

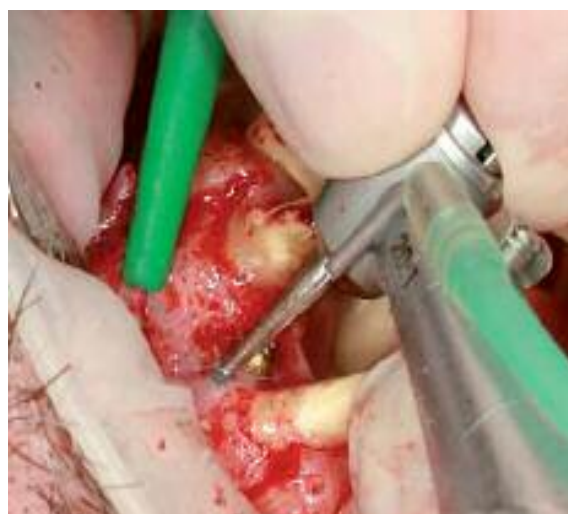

Fig. 13: To improve the local blood perfusion, small and superficial bony defects were added to the regeneration area.

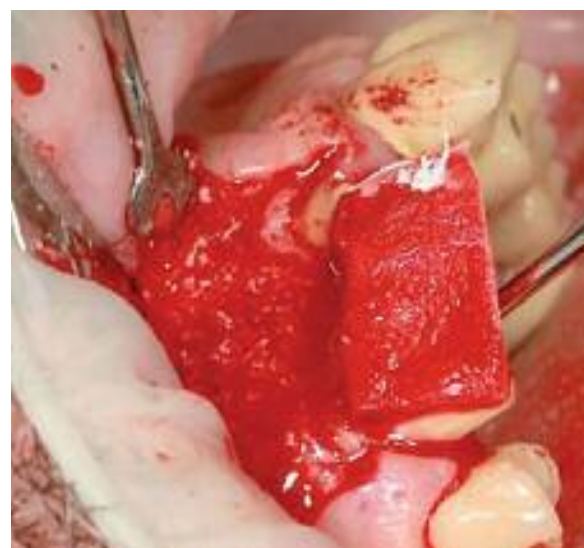


Fig. 14: Bio-Oss® Spongiosa small granules in place.

AD

Case Acceptance Frustrations?

Who Else Wants Predictable Case Acceptance in the Emerging New Dental Economy?



Who is this Implant Dentist and why is he telling the harsh truth about the secrets to case acceptance in YOUR practice?

Follow Implant Clinician,
Have You Experienced ANY of the Following "Dirty Dozen" Case Acceptance Frustrations?

1. Not knowing what to present with cases (problems, solutions, photos, technology, models, etc.) to get to yes?
2. Patients not "owning" their problems / "valuing" oral health?
3. Patients not having the financial ability to accept complete care or patients having "sticker shock"?
4. Presenting to patients who are not ready for treatment?
5. Difficulty getting acceptance on really large cases and more optimal costly treatment plans?
6. New patients not willing to accept more complete care?
7. Time investment issues (to work-up case, diagnose, prepare for presentation)?
8. Counseling patients who aren't ready emotionally or financially?
9. Patients always settling for least costly care?
10. Patients feeling overwhelmed by treatment plans and options?
11. Difficulty gaining patient trust?
12. Not knowing how to follow-up or when?

If you said **yes** to one or more of the above, there's good news. James has put together a System that **eliminates every one of the 12 frustrations**. A successful implant clinician whose cases average over **\$38K per patient**. **Dr. James McAnally** has taught dentists in over 40 countries and 6 continents how to **supersize and systematize their case acceptance (sales) process for complex case patients (implants & reconstructions)**. At any time, only 5 dozen Elite dentists, each investing \$15K-\$25K per year, are allowed entry into his top level Programs for their marketing and case acceptance success.

For doctors fed-up with the "dirty dozen" case acceptance frustrations and who are ready for a solution by a **real 21st century clinician**, his trademarked **Maximum Case Acceptance System™** is being made available to you via a one of a kind Program that **doesn't require travel or attending live seminars**.

This **Introductory DVD** to the Maximum Case Acceptance System™ is the first step for you to gain predictable case acceptance for large elective cases. On it, James reveals the dark underbelly of the major MYTHS circulating in dentistry related to case acceptance and "sales" for implant dentists. You'll be pleased to find that **none** of the solutions for case acceptance with big elective cases requires the use of high-pressure sales techniques, memorizing a bunch of "sales closes," making any major changes in your clinical procedures, or spending time creating ineffective model of "sedating" patients.

The Intro. DVD will immediately improve your current case acceptance by revealing two dentist behavioral patterns that if ignored automatically reduce acceptance and success, the 3 dirty little secrets that labs, supply houses, CE courses, and equipment manufacturers are hiding from you, why credentials, CE, logic, and "sales closes" aren't critical to case acceptance, the biggest clinical opportunity that exists in every market and the one capability used to harvest it, why "big ticket" items like dental implants and reconstructive dentistry require a systematic sales process, ways to eliminate all competitors and finally get the fees you deserve and how "obviate or die" is a critical concept for practice success in the new dental economy emerging outside your front door.

Like it or not, the new dental economy forming around your practice is allowing only those implant dentists with access to the powerful concepts in the Maximum Case Acceptance System™ to maximize their cases going to treatment, help more patients with serious problems, remain free of insurance constraints and experience high levels of **PROFIT**. If you're too "professional" to apply the science of persuasion to help patients needing your advanced skills, you'll **Dare James**. But if you're ready for a fresh, frank voice encouraging and empowering you to get more return on your efforts and to get the inside's truth on what "sells" **major dental implant treatment plans**, you'll be thrilled to have discovered him.

Every month over 26,000 dentists worldwide devour his writings. The most successful dentists take his concepts and elevate their success to even higher levels. As a trusted management, marketing and sales advisor to the most **successful Elite Dentists**, James commands \$14,997 for his one day practice

makover sessions. **HELL DARE YOU** to think differently and more creatively about your case acceptance possibilities **AND PRESENT THE TOUGH-MINDED, PRAGMATIC STRATEGIES NECESSARY** to put more of your skills to full use helping more patients. *Take advantage of this special offer and get the DVD that reveals what's behind the "dirty dozen" frustrations preventing predictable case acceptance for you. Don't let your competitors get to it before you. Take your first step for success in the new dental economy and let the DVD start putting into place your Maximum Case Acceptance System™ today!*

NEW Case Acceptance System Just for Implant Dentists

Order Dr. McAnally's Introduction to the Maximum Case Acceptance System™ DVD for \$197 (61% off the full price of \$497.00) by April 30th and get \$283.95 in FREE Marketing and Case Acceptance Tools!



~~\$497~~ **\$197 (61% off!)**



~~\$25.00~~ **FREE!!**

Intro. to Maximum Case Acceptance Program™ DVD Special Offer Deadline April 30th, 2009



~~\$29.95~~ **FREE!!**



YES! James, I want to get started on the road to better case acceptance on ALL my cases big and small. Send Me the Intro. to the Maximum Case Acceptance System™ DVD for only \$197 +S/H (61% off the \$497.00 regular price) plus My FREE Marketing and Case Acceptance Boosters—The FREE Book & 2 FREE Months of the Gold Elite Docs Strategies™ Letter; All Written Just for Implant Dentists Like Me with Advanced Skills. I Understand My Investment is Tax Deductible and Fully Guaranteed!

**Reserve Today at:
BigCaseMarketing.com/it3
Or Call
888-267-0216**

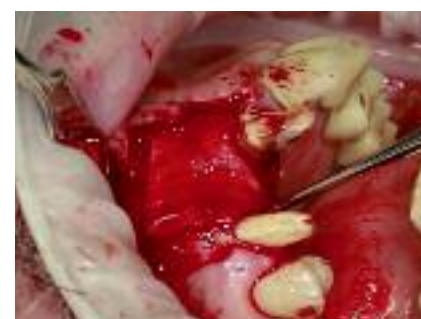

Fig. 15: Direct view of the augmented area and the BioGide membrane still reflected. The excellent blood perfusion from the bone is visible.

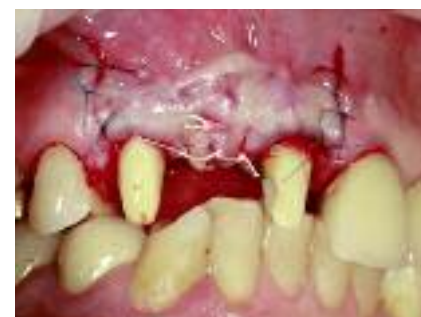

Fig. 16: Flap sutured in place.

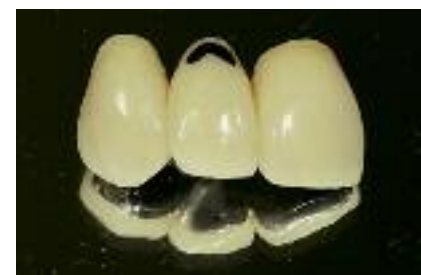

Fig. 17: The pontic of the temporary restoration appeared overextended due to the three-dimensional augmentation. The needed reduction was marked.

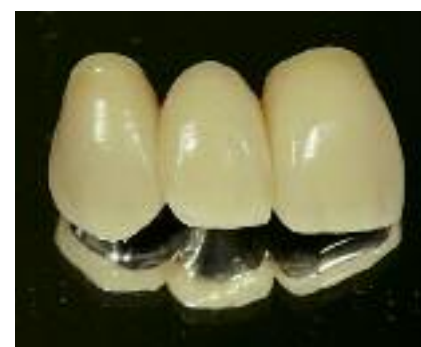

Fig. 18: Temporary restoration after resizing.

← **IT** page 8

ström file, but reversed. Initial small-sized drills are offered within the kit intended for use as markers and access instruments, and to be followed by the spreaders in increasing dimensions.

The implant guiding system (by Innovative Implant Technology) was used to two-dimensionally position the primary marker drill. To begin with, an 010 followed by an 018 pilot drill was used, complemented by an expansion burr in the size of a 025 burr. The bony spreading was performed using the following spreaders: 027, 029, 031, 033.

As a next step, the guided bone regeneration was performed. To augment the buccal resorption, Bio-Oss Spongiosa small granules, 0.25 mm (Geistlich Biomaterials), were used and covered with Geistlich Bio-Gide resorbable bilayer membrane 25 x 25 mm both soaked in wound blood.

With the membrane covering the augmentation material, additional fixation of the membrane was avoided because of the available fixation and immobilization using the soft tissue.

The flap was sutured in place crestally using GoreTex suture because of its mechanical perform-

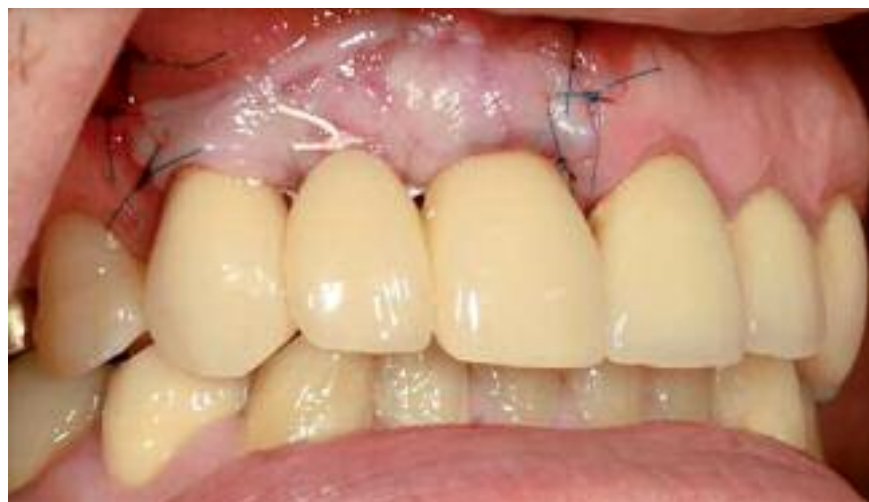

Fig. 19: The temporary was recemented in place avoiding pressure in the augmented area.

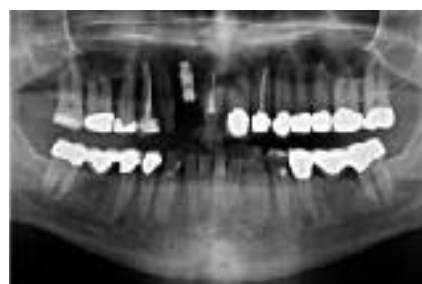

Fig. 20: The correct three-dimensional position of the BioHorizons implant was confirmed with an X-ray.

ance. The lateral-releasing incisions were closed using 6x0 Prolene

suture material.

Conclusion

The buccal bone plate can resorb to a severe degree as a result of tooth loss. Conventional implantologic reconstructive therapy supposed until recently a two-stage approach: guided bone regeneration followed by a five-month healing time and a second surgery for fixture installment.

Using advanced minimal-invasive instruments for extremely thin-ridge expansion allows for concomitant implant placement and regenerative procedures.

IT About the author



Dr. Liviu Steier is a GDC-registered specialist in endodontics, professor at the University of Florence Dental School and professor of the Tufts School of Dental Medicine. He also maintains a private practice, MS Dentistry at 20 Wimpole St., London W1G 8GF, www.msdentistry.co.uk. Dr. Steier is also the current president of the British Academy of Oral Bone Grafting and offers bone management courses together with Dr. Siavash Mirfendereski, also of MS Dentistry. He can be contacted at lsteier@gmail.com.

AD

Benex® - Control Professional
 Root Extraction Systems developed with Dr. Sytle

Art.-No. BE001230001

- Safe and simple extraction of roots
- Maximal protection of the tooth socket
- Possibility of drilling even if minute root fragments or foreign bodies are present in the root
- Possibility of drilling independently of anatomic root canal

Meisinger GERMANY / USA

Meisinger USA, L.L.C.
 7442 South Tucson Way • Suite 130 • Centennial • Colorado 80112 • USA
 Tel.: +1 (303) 268-5400 • Fax: +1 (303) 268-5407 • E-Mail: info@meisingerusa.com
www.meisingerusa.com • www.bone-management.com • www.occlusalrouter.com