

# laser

international magazine of laser dentistry

1 2014

5 years  
of Fotona laser innovations

Fotona  
Globe Selection

| **research**

Use of lasers in periodontal bone defects

| **case report**

Er:YAG laser and composite resin ablation

| **industry report**

Erbium lasers in pediatric dentistry

dentis



# Bio-Emulation™ Colloquium

The Santorini Experience - June 21-22, 2014, Greece

## Mentors



Pascal Maigne



Michel Maigne



Francesco Mangani



Francesca Valletti



Gaetano Calorini

## Emulators



Panos Bazos



Gianfranco Pollano



Javier Tapia Guadix



Leandro Pereira



Jason Smithson



Claudio Pisacane



Stephane Browet



Gil Tinet



David Gerdolle



Sascha Hein



Lucas Zago Naves



Andrea Fabiani



Giancarlo Pongione

## Registration information:

June 21-22, 2014, Greece

The Venue will be held at the Petros M. Nomikos Conference Centre, Fira.

Colloquium fee: **€ 799**

Tel: **+49 341 48474 302** / email: **request@tribunecme.com**

# Welcome to Paris 2014



Prof. Dr. Norbert Gutknecht  
Editor-in-Chief

Dear reader,


First of all, I would like to wish all our friends and DGL members a happy, healthy and successful 2014! I am sure many of you already have fixed dates and venues on their schedules, which are hopefully both obligatory and relaxing. I assume that you, being an active reader of **laser** international magazine of laser dentistry, are not only interested in new technologies and application concepts, but you also wish to participate in direct discussions with speakers and users at our WFLD (World Federation for Laser Dentistry) Congress on 2–4 July in Paris.

Scientists, practitioners and postgraduate students from all parts of the world will meet in Paris to exchange their latest findings and opinions as well as controversial problems. It will be your decision whether you let yourselves be charmed by either the various wavelengths or Paris' irresistible flair.

It is my special pleasure to welcome you all in the name of the WFLD board and the Paris organizational team to this year's most exclusive laser event.

Looking forward to meeting you in Paris

You're sincerely,

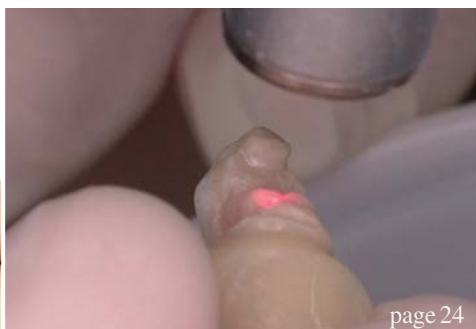

Prof. Dr. Norbert Gutknecht





page 18



page 24



page 30

## editorial

- 03 **Welcome to Paris 2014**  
| Prof. Dr Norbert Gutknecht

## research

- 06 **Use of lasers in periodontal bone defects**  
| Prof. Dr Aslan Yasar Gokbuget *et al.*
- 10 **Mucoccele of the lip treated by using 980 nm diode laser**  
| Dr Merita Bardhoshi *et al.*
- 18 **Diclofenac, dexamethasone or laser phototherapy?**  
| Jan Tunér

## case report

- 14 **Pain reduction of recurrent aphthous stomatitis**  
| Dr Maziar Mir *et al.*
- 24 **Er:YAG laser and composite resin ablation**  
| Carlo Fornaini

## industry report

- 30 **Erbium lasers in pediatric dentistry**  
| Giovanni Olivi *et al.*

## economy

- 34 **Gain power at your laser clinics!**  
| Dr Anna Maria Yannikos

## meetings

- 37 **International events 2014**

## science

- 38 **ISMI: A new Society for Implantology**

## interview

- 40 **LaserCUSING: Laser melting with metals**
- 44 **“Technology has allowed my work to evolve enormously”**  
| An interview with Dr Carlo Fornaini, president-elect of the World Federation for Laser Dentistry

## news

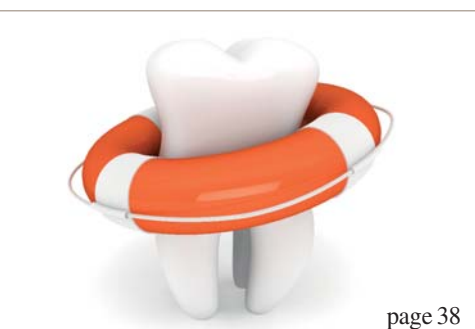- 46 **News**

## about the publisher


- 50 | imprint



Cover image courtesy of Fotona,  
[www.fotona.com](http://www.fotona.com)



page 38



page 40



page 46

Fotona<sup>®</sup>  
choose perfection



The first digitally controlled  
dental laser handpiece

## X-Runner<sup>™</sup>

- instantly adjustable spot size and shape
- precise coverage of large areas
- lightweight, ergonomic design
- for Fotona LightWalker AT laser systems

50 years  
of Fotona laser innovations



The universe at your fingertips.

• LightWalker<sup>®</sup>

# Use of lasers in periodontal bone defects

## A case report with six years follow-up

**Authors\_** Prof. Dr Aslan Ya ar Gokbuget & Necla Asli Kocak, Turkey

### \_Introduction

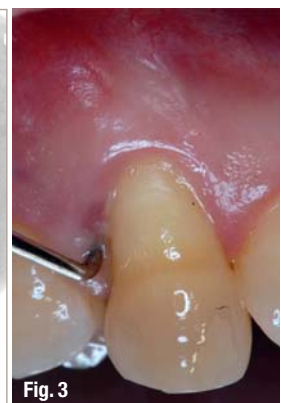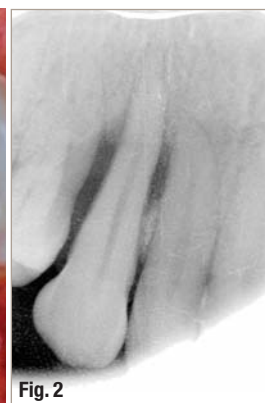
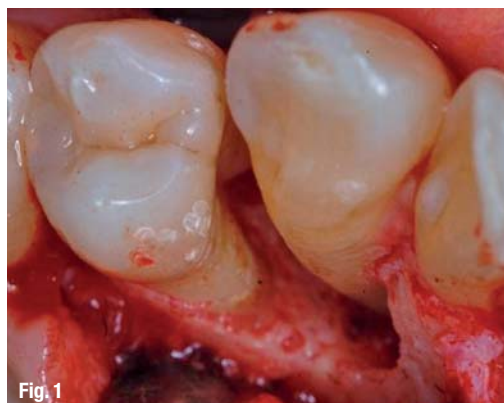The use of lasers in periodontal treatment has been well documented over the past ten years. Lasers can be used for initial periodontal therapy and surgical procedures. When used in deep periodontal pockets with associated bone defects, not only does laser remove the diseased granulation tissue and associated bacteria, but it also promotes osteoclast and osteoblast activity, often resulting in bone regrowth. This usage becomes more complicated because the periodontium consists of both hard and soft tissues. The many lasers available, such as CO<sub>2</sub>, Nd:YAG and diode lasers, can be used in periodontics because of their excellent ablation and haemostatic characteristics.

Chronic periodontitis is initiated by microbial plaque, which accumulates on the tooth surface at the gingival margin and induces an inflammatory reaction. The inflammatory response in patients with chronic periodontitis results in destruction of the periodontal tissues. With a constant bacterial challenge, the periodontal tissues are continuously exposed to specific bacterial components that have

the ability to alter many local cell functions. The function of the inflammatory process is to protect the host and limit the effect of the biofilm. Some tissue destruction occurs as part of this process. Extent and severity of damage vary among individuals and over time, and may involve attachment loss. This variation in disease expression is the result of the interaction of host genetics and environmental and microbial factors.

A major goal of periodontal therapy is to achieve a biocompatible root surface through the removal of bacterial biofilms and smear layer. Ultrasonic scalers and hand instrumentation are the most commonly used procedures for root debridement in periodontal therapy. To achieve more efficient subgingival instrumentation at deeper probing depths (PDs), the tips of scalers have evolved to smaller diameters and longer working lengths. Clinical studies reported similar results when comparing ultrasonic scalers and manual instrumentation for root debridement, even though manual instrumentation requires more time and physical effort. Mechanical root debridement results in a smear layer containing bacteria, bacterial endotoxins, and contami-

**Fig. 1** Bone defect.  
**Fig. 2** First radiographic examination.  
**Fig. 3** Probing.



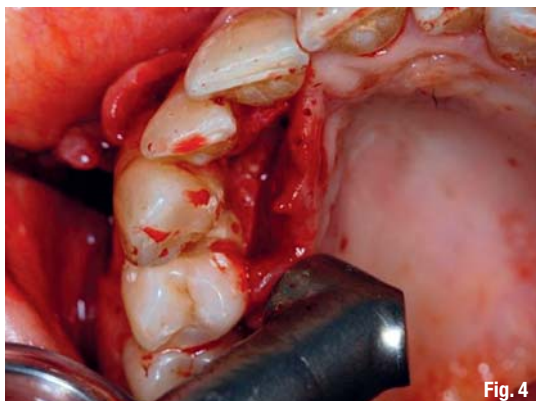


Fig. 4

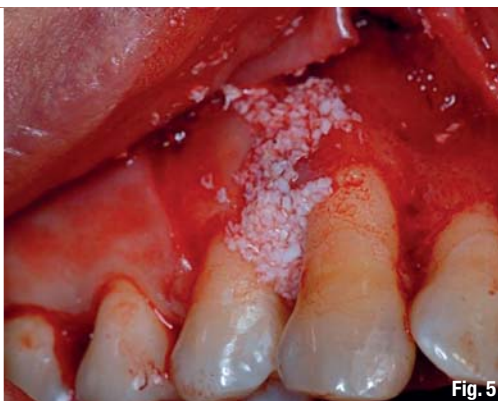

Fig. 5

Fig. 4\_Surgery.

Fig. 5\_Augmentation.

nated root cementum. Furthermore, it does not remove plaque and calculus completely from inter-radicular septa or root concavities. Individually or collectively, these factors are likely to hamper the periodontal healing process. A significant disadvantage of ultrasonic scalers, for the patient and the clinician, is the formation of a contaminated aerosol. Dentistry has changed tremendously over the past decade to the benefit of both the clinician and the patient. One technology that has become increasingly utilized in clinical dentistry is that of the laser. Laser is an acronym for Light Amplification by Stimulated Emission of Radiation. Laser is a device that utilizes the natural oscillations of atoms or molecules between energy levels for generating coherent electromagnetic radiation usually in the ultraviolet, visible, or infrared regions of the spectrum. It is a device that produces high intensity of a single wavelength and can be focused into a small spot. Initially introduced as an alternative to the traditional halogen curing light, the laser now has become the instrument of choice, in many applications, for both periodontal and restorative care. Because of their many advantages, lasers are indicated for a wide variety of procedures.

Presently, various laser systems have been used and in recent years, laser radiation has been suggested as an alternative instrumentation modality for the treatment of chronic periodontitis. *In vitro* studies reported effective results for Nd:YAG laser root debridement. When used at low-energy densities with a water-spray surface coolant, the Nd:YAG laser provides a homogeneous and smooth root surface topography. In addition, laser is effective at removing dental calculus and smear layer and exhibits bactericidal effects without inflicting any significant thermal damage to the root surface. Several clinical studies compared traditional instrumentation to the Nd:YAG laser for treatment of periodontal disease. However, laser usage for such purposes remains controversial, probably because of insufficient evidence that any specific wavelength of laser is superior to traditional instrumentation. The lack

of evidence supporting laser usage results from poorly designed studies and the lack of continuity of design between studies, e.g., wide variations in laser parameters, energy densities, experimental designs, and the lack of proper controls in many studies.

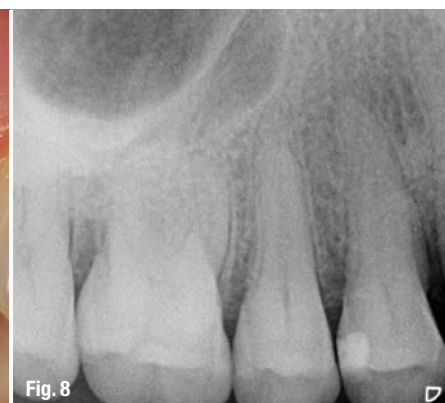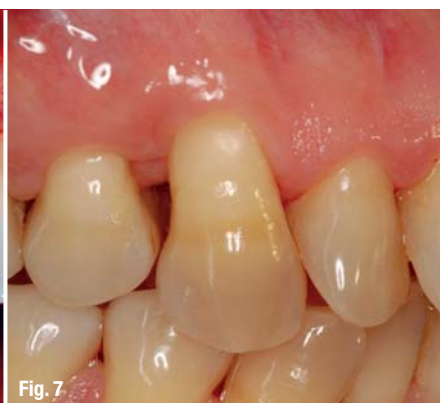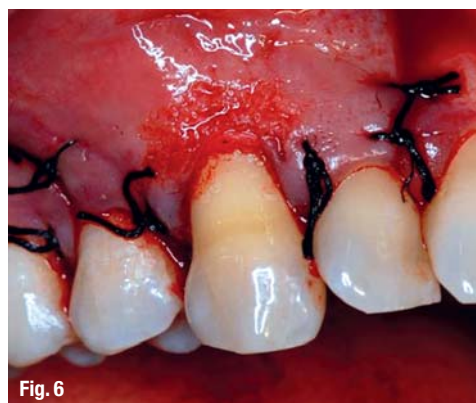### Advantages and disadvantages

Advantages of laser treatment are greater haemostasis, bactericidal effect, and minimal wound contraction. Compared with the use of a conventional scalpel, lasers can cut, ablate and reshape the oral soft tissue more easily, with no or minimal bleeding and little pain as well as no or only a few sutures. The use of lasers also has disadvantages that require precautions to be taken during clinical application. Laser irradiation can interact with tissues even in the noncontact mode, which means that laser beams may reach the patients eyes and other tissues surrounding the target in the oral cavity. Clinicians should be careful to prevent inadvertent irradiation to these tissues, especially to the eyes. Protective eyewear specific for the wavelength of the laser in use must be worn by the patient, operator, and assistant. Laser beams can be reflected by shiny surfaces of metal dental instruments, causing irradiation to other tissues, which should be avoided by using wet gauze packs over the area surrounding the target. However, previous laser systems have strong thermal side effects, leading to melting, cracking, and carbonization of hard tissues.

### Clinical presentation and case management

A 44-year-old female patient presented at our private clinic PGG for treatment of the periodontal problems at the right maxillary molar site (Fig. 1). Upon review of her medical history she was otherwise healthy. She had previously been treated for chronic periodontitis with a non-surgical approach. Then radiographic examination was made (Fig. 2). It revealed a combined marginal and vertical radiolucency. On clinical examination, deep probing depths





**Fig. 6**\_Suturing.

**Fig. 7**\_ Six years after radiation.

**Fig. 8**\_Radiograph six years after radiation.

were isolated (Fig. 3). No clinically detectable mobility of the teeth was present. One day prior to surgery, the patient was given 2,000 mg of amoxicillin and following surgery put on a regimen of amoxicillin (1,000 mg tid) for five days post-op. A crestal incision is scalloped around the teeth necks to eliminate the internal epithelium and granulation tissue from the pocket (Fig. 4). A mucoperiosteal flap is raised to expose the teeth, and bone tissue and granulation tissue are eliminated from the bone defect with Nd:YAG laser with 300  $\mu$ m tip, VSP, 1.5 Hz, 10 W power setting was used and Er:YAG laser with power settings of VSP, 120 mJ, 10 Hz with water and air flushing was used for teeth surface detoxification. Due to defect morphology we used a combined technique with enamel matrix derivative (Emdogain). Then, xenogenous bone grafts (Bio-Oss®) were compacted into the defect (Fig. 5). A Bio-Gide® barrier was placed over the defect and was extended both buccally and lingually.

The buccal and lingual flaps were released and tension-free primary closure was achieved with 4-0 silk sutures (Fig. 6). The patient was instructed to continue antibiotics as prescribed and to rinse with the 0.12% chlorhexidine gluconate bid for 30 sec twice a day. Finally, a strict maintenance and oral hygiene protocol were established. The area healed uneventfully after six months. Periapical radiographs were taken throughout the healing process to evaluate the mineralization of the graft over time, bone formation within the bony defect was evident. Radiographically it appeared that there was increased mineralization of the bone surrounding the teeth. The patient was again examined every year. Six years after treatment (Fig. 7), a new radiograph (Fig. 8) was taken which demonstrated complete resolution of the bony defect surrounding the teeth.

### Discussion

As technology advances into dentistry, whether it is laser or another exciting venue, the options available to clinicians will continue to increase. Al-

though the use of lasers in dentistry is relatively new, the future looks very bright. In summary, laser treatment is expected to serve as an alternative or adjunctive to conventional mechanical periodontal treatment. Currently, among the different types of lasers available, Nd:YAG, Er:YAG and Er,Cr:YSGG laser possess characteristics suitable for dental treatment, due to their dual ability to ablate soft and hard tissues with minimal damage. In addition, the bactericidal effect of laser with elimination of lipopolysaccharide, its ability to remove bacterial plaque and calculus, an irradiation effect limited to an ultra-thin layer of tissue, faster bone and soft tissue repair make it a promising tool for periodontal treatment including scaling and root surface debridement. The decision to use a laser should be based on the proven benefits of haemostasis, a dry field, reduced surgical time and the general experience of less postoperative swelling.

### Conclusion

Although no definitive conclusion can be drawn from a single case report, the guided bone regeneration combined laser technique described in this case report effectively eliminated teeth associated three-wall bony defect and deep pocket. Under the conditions of the present case, it may be concluded that the Nd:YAG and Er:YAG laser combination can be safely and effectively utilized for degranulation and implant surface debridement in the surgical treatment of periodontal infection.

#### contact

#### laser

#### **Prof. Dr Aslan Y. Gokbuget**

PGG Dental Clinic  
Tevkikiye Casddesi Kismet Apt. 133 d.8  
34365 Nisantasi  
Istanbul, Turkey

Tel.: +90 212 2480317  
Fax: +90 212 2475118





# Master of Science (M.Sc.) in Lasers in Dentistry

Batch: EN2014 - Fulltime (new) or Module based

**Next Start: 15 September 2014**

**Aachen, Germany**

**4 semesters**

## Become part of the International Dental Elite

- Create new economic potential for your practice
- Two year career-accompanying postgraduate programme at the University of Excellence RWTH Aachen
- Combination of lectures, skill training sessions, live ops, tutorials, and practical workshops
- Internationally accepted and accredited by the German Government, the European Union, the Washington Accord and the Bologna Process
- Science-based and practice-orientated on highest national and international level
- Increased patient satisfaction: minimal contact reduced vibration and pain



**RWTH INTERNATIONAL  
ACADEMY  
AACHEN UNIVERSITY**

RWTH International Academy  
Kackertstraße 10 | 52072 Aachen | Germany  
phone +49 241 80 23543 | fax +49 241 80 92525  
info@academy.rwth-aachen.de  
www.academy.rwth-aachen.de

**PROFESSIONAL EDUCATION PROGRAMMES**

**AALZ**

**Aachen Dental Laser Center**

AALZ GmbH  
Pauwelsstraße 17 | 52074 Aachen | Germany  
phone +49 241 47 57 13 10 | fax +49 241 47 57 13 29  
info@aalz.de  
www.aalz.de