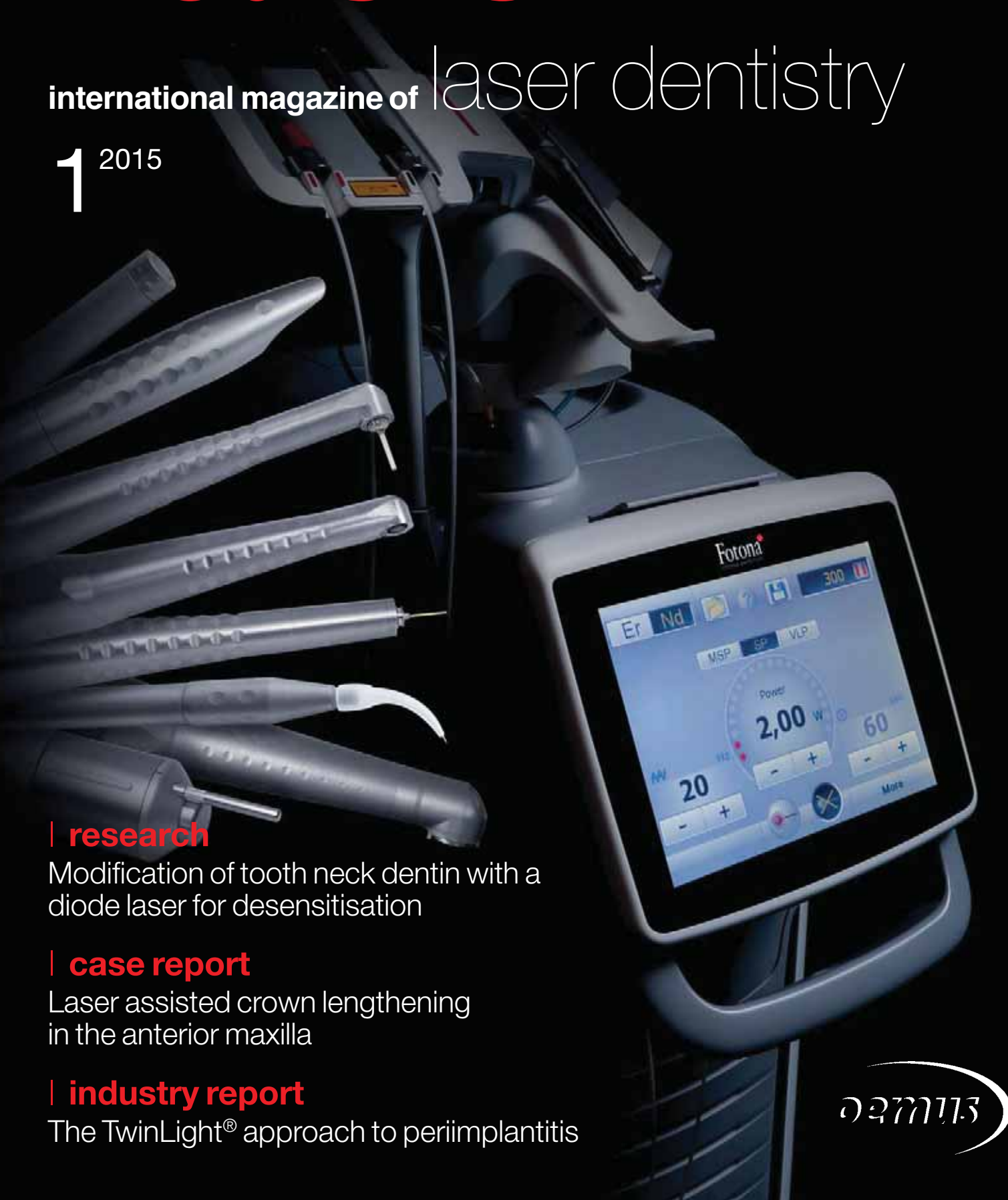

# laser



international magazine of laser dentistry

1 2015



| **research**

Modification of tooth neck dentin with a diode laser for desensitisation

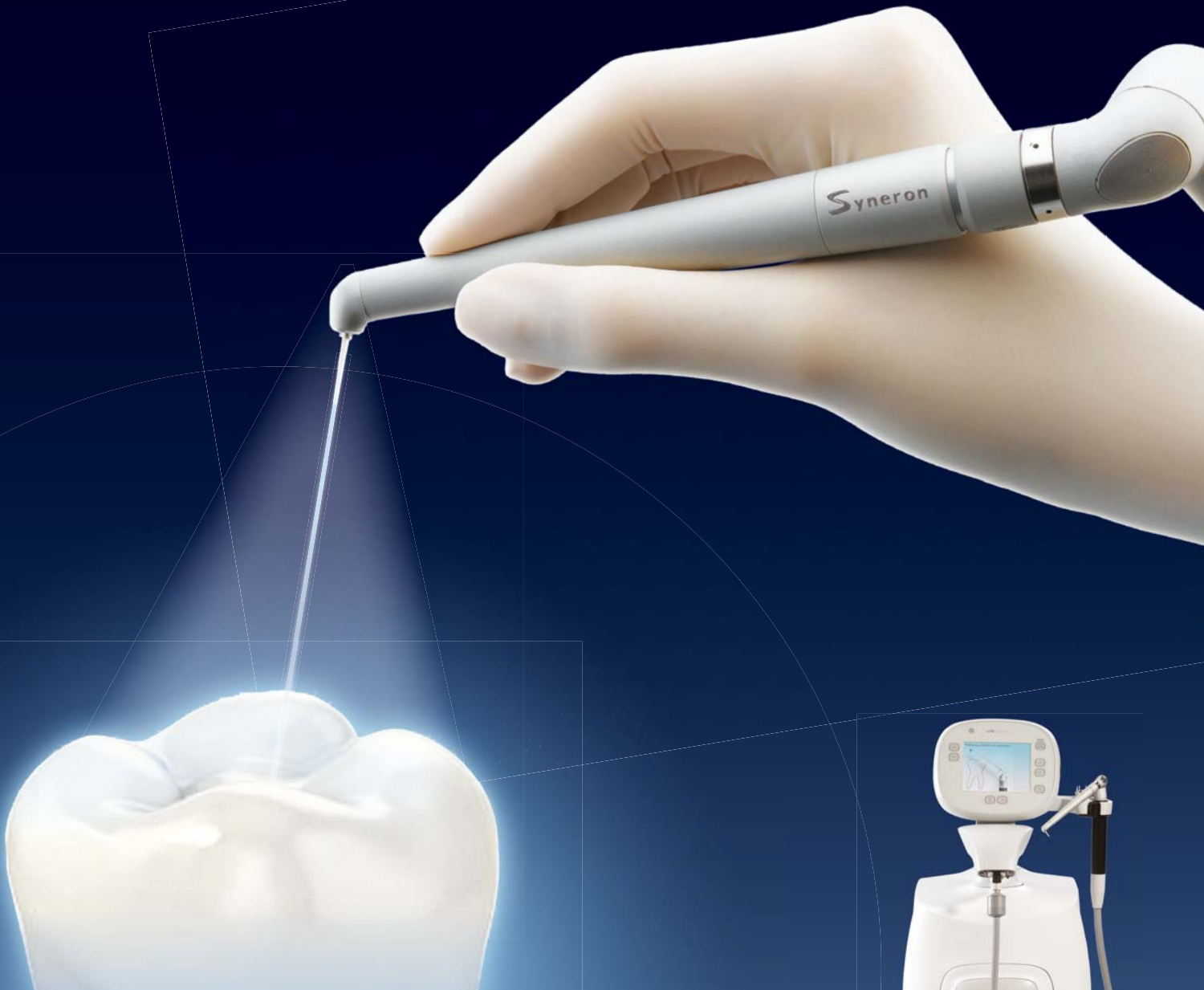| **case report**

Laser assisted crown lengthening in the anterior maxilla

| **industry report**

The TwinLight® approach to periimplantitis

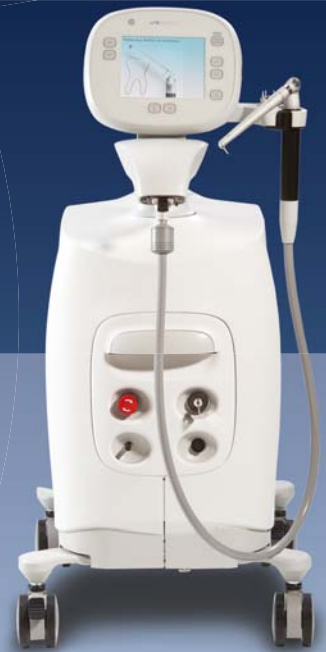



# LITETOUCH<sup>TM</sup>

## Er:YAG Laser-in-Handpiece

Dentists' Choice for Hard & Soft Tissue Procedures



To learn more about our innovative technology solutions,  
contact: [dental@syneron.com](mailto:dental@syneron.com), [www.synerondental.com](http://www.synerondental.com)



# Let's try again!



Prof. Dr Norbert Gutknecht  
Editor-in-Chief

Dear reader,

First of all, I would like to wish you a happy, healthy and blessed New Year 2015.

The prevalence of antimicrobial resistance is increasing and has been a topic of much debate recently. The results associated with this are not yet known, but are certainly more severe than described in the official media. High concentrations of antibiotic residues are ingested not only via food (meat in particular) but also owing to careless patient prescriptions. As a responsible and future-oriented practitioner, one should seriously consider relevant antibiotic alternatives.

With most laser systems used in today's dentistry, it has become possible to reduce the administration of antibiotics or even omit them entirely. This is an option particularly in periodontology, peri-implantitis therapy, endodontics and several areas of oral surgery. As scientific studies have demonstrated, bacterial reduction with laser devices is so efficient that post-operative healing is both faster and longer lasting. Based on this knowledge, we should aim for more intensive integration of laser technology in the different fields of dentistry.

Numerous congresses organised by our scientific laser society, as well as specialist continuing education events, dealing with the above-mentioned topic offer you opportunities to deepen your knowledge in this area. Announcements of these events will be published in our respective journals.

With this in mind, I am looking forward to welcoming you to one of our congresses or continuing education events.

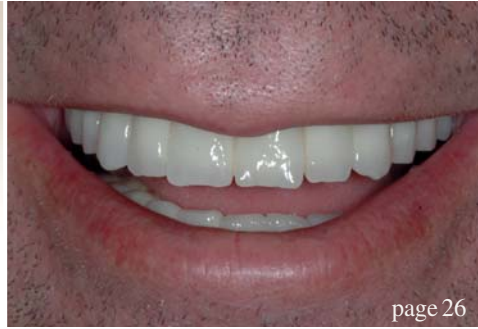Best regards,

A handwritten signature in black ink, appearing to read 'Norbert Gutknecht'. The signature is fluid and cursive, written on a light-colored background.

Prof. Norbert Gutknecht  
Editor-in-Chief



page 6



page 26



page 32

| editorial

03 Let's try again!  
| Prof. Dr Norbert Gutknecht

| research

06 Modification of tooth neck dentin with a diode laser for desensitisation  
| Dr Ute Ulrike Botzenhart

| case report

16 Laser assisted crown lengthening in the anterior maxilla  
| Ana Minovska *et al.*

20 Gingival plastic with diode laser—A case report  
| Ioannis Papadimitriou *et al.*

| industry report

26 The TwinLight® approach to peri-implantitis  
| Dr Ilay Maden *et al.*

| practice management

32 Gain power at your laser clinics!  
Physical evidence and place  
| Dr Anna Maria Yiannikos

34 Clinical governance—A system for better health care  
| Dr Kashif Hafeez

| interview

36 Lasers are becoming increasingly prevalent in dentistry  
| Dental Tribune International

| meetings

38 IDS 2015: new exhibitor record and increased exhibition space

| news

30 Manufacturer News international

42 News international

| DGL

45 Auf ein Neues!  
| Prof. Dr. Norbert Gutknecht

46 Manufacturer News germany


48 News germany

| about the publisher

50 | imprint



Cover image courtesy of Fotona, [www.fotona.com](http://www.fotona.com)



page 36

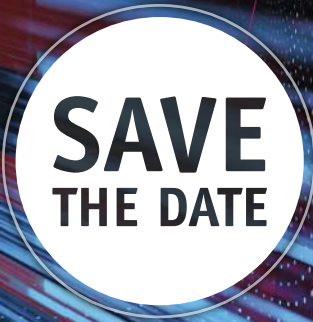

page 38



page 42





November 27–28, 2015  
Berlin, Germany  
Hotel Palace

# 24<sup>th</sup> Annual Meeting of the DGL

## LASER START UP 2015



[www.dgl-jahrestagung.de](http://www.dgl-jahrestagung.de)



[www.startup-laser.de](http://www.startup-laser.de)



### Fax Reply

+49 341 48474-290

I would like to receive further information on the

- 24<sup>th</sup> Annual Congress of the DGL e.V.     LASER START UP 2015

on November 27–28, 2015 in Berlin, Germany.

Name & email address

Practice Stamp

laser 1/15

# Modification of tooth neck dentin with a diode laser for desensitisation

Author\_Dr Ute Ulrike Botzenhart, Germany

“Cervical dentin hypersensitivity is a common phenomenon of discomfort, which affects an increasing number of young adults.”



[PICTURE: ©VLADIMIR GJORGIEV]

Cervical dentin hypersensitivity is a common phenomenon and affects an increasing number of young adults. Today, more than 30% of the adult population in industrialised nations is affected, but the number of unreported cases is presumably much higher and treatment demand is increasing.<sup>1</sup> Patients who are affected report intense and sharp pain of short duration during eating or dental hygiene, for example, that cannot be ascribed to any other form of dental defect or disease.<sup>2</sup> Dentine hypersensitivity is associated with exposure of dentine at the cemento-enamel junction and can be explained by the combined effect of several aetiological factors, such as erosion, abrasion and attrition

with erosion as the main factor.<sup>3,4</sup> Other factors, like microbiological invasion of exposed dentinal tubules with accompanying inflammation of pulpal tissue, functional overload, traumatic toothbrushing and whitening of vital teeth, also appear to be involved.<sup>5,6</sup>

To date, the commonly accepted theory of pain transmission is still Brännström's hydrodynamic theory.<sup>7</sup> It states that chemical, mechanical, osmotic and thermal stimuli induce fluid flow in exposed dentinal tubules, activation of mechanoreceptors at the pulp-dentine border and finally activation of pain fibres. The structure of the dentinal surface is

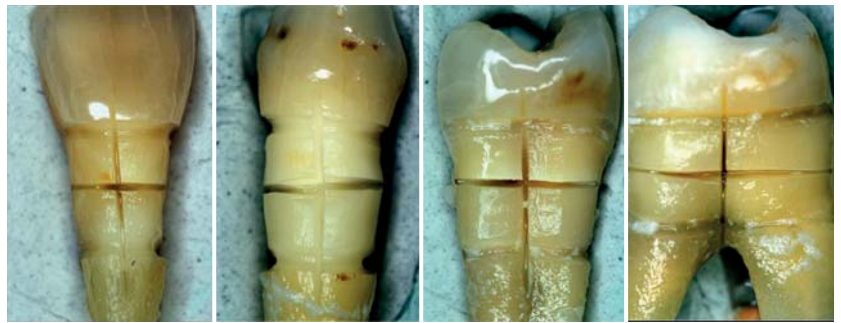

an important factor of this mechanism.<sup>8</sup> Examination of tooth necks under a scanning electron microscope (SEM) has shown that affected teeth had eight times as many exposed tubules with a diameter twice the size compared with non-sensitive dentine.<sup>8</sup> By demonstrating that the density of sensitive nerve fibres is correlated to pain intensity of a sensitive tooth,<sup>9</sup> it is also assumed that, in addition to the hydrodynamic theory, other mechanisms, such as nerve stimulation, could be involved. Thus, inflammation mediators could make nerve endings more sensitive to mild stimuli, which could induce pain.<sup>10</sup> Nevertheless, the precise physiological mechanisms underlying dentine hypersensitivity are not clearly understood yet,<sup>11, 12</sup> and despite intensive research, constant improvement of therapy methods and active substances, reports still show that there is difficulty controlling this painful condition.<sup>11</sup>

Laser treatment of dentine hypersensitivity alone or in combination with conventional treatments is a new promising option for rapid and durable pain relief.<sup>13</sup> Depending on the laser type and energy settings used, the actual reported effects of laser desensitisation are morphological alteration of the dentinal structure, for example a closure of the dentinal tubules by melting and resolidification of the dentinal structure; laser dehydration with protein deposition or deposition of insoluble salts in the dentinal tubules; as well as bio-stimulation, for example nerve analgesia, induction of sclerosis and secondary dentine formation; and placebo effects. Recently, great effort has also been made to integrate tooth structure-like components into the tooth surface with the help of laser radiation.<sup>11, 14-17</sup>

However, on account of the high temperature increase, these methods are not suitable for clinical application<sup>11, 16</sup> and too little is known about the long-term morphological and clinical effects of laser application to recommend the therapy.

The aim of our study was to examine the effects of a diode laser with a wavelength of 809 nm in the treatment of dentine hypersensitivity in terms of morphological changes. The ability of this type of laser to close open dentinal tubules, its suitability as a method for dentinal sealing, as well as the induction of recognisable morphological side-effects in the dentinal structure using this laser, were tested *in vitro*. Furthermore, the effect of laser-fluoride application was compared with single treatment options, and the acid resistance of the tested treatment modalities (fluorides, laser, and laser-fluoride treatment) was evaluated by the method of pH-cycling.



## Material and methods

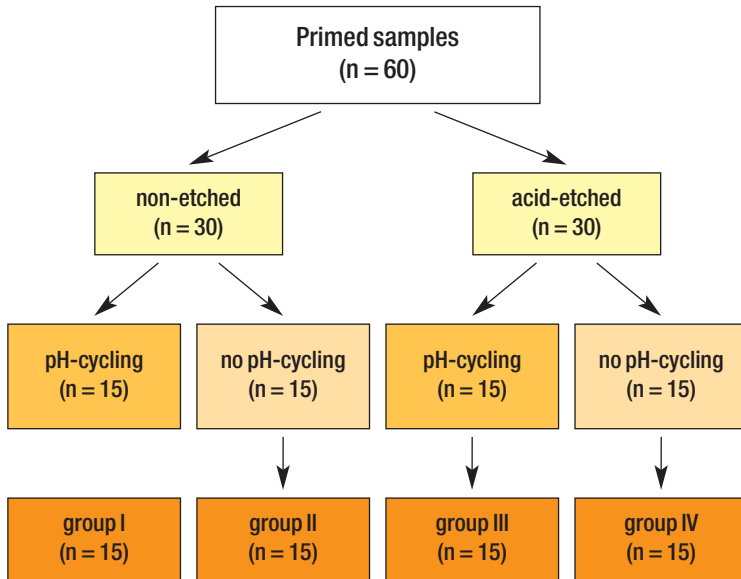
The samples used were extracted human teeth drawn from a pool of extracted teeth collected for dental research at the University Bonn, Dental Clinic once informed consent had been obtained. Surgical treatment was not linked to research in any way. All experiments were *in vitro*; hence, there were no potential risk factors to human health.

Immediately after extraction, the teeth were stored in a sodium chloride solution (0.9% NaCl, Delta-Pharma) with 0.01‰ sodium acid added and kept refrigerated at 5 °C to prevent the teeth drying out and to minimise bacterial and chemical decomposition. Teeth without carious lesions at the tooth neck and root surface ( $n = 60$ ) were divided into four groups of 15 teeth by random selection. Every test group had the same number of incisors, canines, premolars and molars from the maxillae and mandible (four maxillary incisors, one maxillary canine, two maxillary premolars, two maxillary molars, one mandibular canine, three mandibular molars and two mandibular third molars). The incisors of the mandibular arch were exchanged for third molars because the small root surface did not allow preparation of a quadrangle. The experimental surface was located at the vestibular, mesial or distal side of the root surface. Four quadrants were marked in the cervical area (Fig. 1).

Enamel and root cementum were completely removed with diamond burs under water-cooling (INTRAmatic LUX 24, KaVo) by one operator to simulate hypersensitive dentine. With removal of a 1 mm layer, we assumed that all dentinal tubules had been totally exposed. The sample surface was smoothed with a Gracey curette (#7-8; Thico-dent) and divided into quadrangles with a diamond separating disc (0.5 mm thick) under water-cooling (INTRAmatic 10 C, KaVo; Fig.1).

Groups 3 and 4 underwent a pretreatment (acid etching with 50% citric acid for 2 minutes, rinsing with distilled water for 30 seconds) to remove the smear layer created by preparation.

**Fig. 1** Samples of (a) Incisor, (b) Canini, (c) Premolar and (d) Molar after quadrangle preparation in the tooth neck area.



**Fig. 2** Flow chart to illustrate group assignment with the help of test procedure.

The test groups were as follows (Fig. 2): Groups 1 and 2 with smear layer and Groups 3 and 4 with removal of the smear layer. Quadrant 1 of each sample underwent laser application. Quadrant 2 underwent laser application followed by fluoridation. Quadrant 3 underwent fluoridation exclusively. Quadrant 4 was left untreated as a control.

The diode laser used had a wavelength of 809 nm (ORA-Laser 01 I.S.T., ORALIA). The parameters were chosen according to Gutknecht et al.,<sup>18</sup> who used an Nd:YAG laser for cervical desensitisation, because the action mechanism of both laser types is approximately similar.<sup>19</sup> The laser parameters were 1 W, 10 Hz and 60 seconds in contact mode with a 400 µm fibre in an overlapping flap. The surface of each quadrant was approximately 3–5 mm<sup>2</sup>. Owing to the penetration depth of the laser radiation used, an absorber (Contactin CO) was also used in 50% of the samples. For fluoridation, we used Bifluorid 12 (VOCO), which was left to react for 1 minute and afterwards rinsed with water spray.

**Tab.1** Results of statistical analysis of the histological examination of group I (with smear layer, with pH-cycling) and group III (without smear layer, with pH-cycling); p = 0.05.

After the treatment, all teeth of Groups 1 and 3 underwent pH-cycling for ten days according to Ten Cate et al.<sup>20</sup> as a post-treatment to simulate the conditions of the oral cavity. The teeth subsequently underwent histological and SEM examination.

	Mann-Whitney-U-Test (laser with absorber – laser without absorber)	Friedmann-Test
group I	p > 0.05	p < 0.05
group III	p > 0.05	p > 0.05

*SEM examination*

Six samples from each group (n = 6), three with and three without absorber application prior to laser treatment, were prepared for SEM examination. We used the replica technique to evaluate morphological changes and to make it possible to perform histological examination of the samples afterwards. For the replica technique, we took impressions of the samples with a light-body silicone (PRESIDENT PLUS JET light body, Coltène AG), allowed them to dry for four weeks and cast them in epoxy resin (Stycast 1266, Part A + B, T-E-Klebetchnik). The resin samples were attached to a table for SEM examination, sputter coated with a thin layer of platinum (15 W and 22 mA for 70 seconds) and mounted on the specimen stub with a conductive bridge using a special adhesive for SEM examination (Leit-C nach Görke, Neubauer Chemikalien) to ensure electrical grounding.

The observation of the samples was performed under high vacuum and in direct mode at an angle of 40 degrees, an accelerating voltage of 10 kV and 3 A, and at a magnification of 2,000x.

*Histological examination*

All samples (n = 60) were prepared for histological examination by formalin fixation (4%, pH of 6.9), followed by dehydration in alcohol of progressive concentrations, embedding in Technovit 7200 VLC (Heraeus Kulzer), cutting, grinding (EXAKT grinding unit), fixation to an object plate (Technovit 4000VLC, Heraeus Kulzer) and burnishing to a thickness of 20–30 µm each, so that every preparation contained two quadrants of each sample. The sections were dyed with toluidine blue according to Donath et al.<sup>21</sup> and analysed with the DIALUX 20 EB (LEITZ) light microscope at a magnification of 25x. Four samples had to be excluded afterwards because of artificial alterations or incomplete removal of the enamel or root dentine, which could only be detected with light microscopy. Therefore, 56 samples with four quadrants each were examined histologically.

*Statistical analysis*

For histological examination, we used non-parametric tests (Mann-Whitney test, Friedman test and Wilcoxon signed-rank test). The various morphological effects we found under SEM examination were first analysed qualitatively by one operator and then analysed using the chi-square test. For all statistical analyses, we used SPSS (IBM Software) and the significance level was p = 0.05.

**\_Results**

*Histological examination*

In the histological examination, major structural changes in the dentine were not observed, regard-



less of the treatment modality we used. After laser irradiation, no carbonisation, cracks or other side-effects could be detected.

In Groups 2 and 4 (without pH-cycling), no structural effects were observed, whereas changes of different width indicated by staining were recorded in Groups 1 and 3 (with pH-cycling). These patterns were measured at three points and the average value was calculated (Fig. 3). With the help of a measuring scale, the width of these patterns was converted into micrometres. There was no statistically significant difference between the effect of the laser with or without absorber application in Groups 1 and 3 (Mann-Whitney test,  $p > 0.05$ ; Table 1). In Group 3 (without a smear layer), no statistically significant differences between the different surface treatments and the width of the pattern were observed (Friedman test,  $p > 0.05$ ; Table 1), whereas statistically significant differences in Group 1 (with a smear layer) in the width of the pattern were found (Friedman test,  $p < 0.05$ ; Table 1) after fluoridation and after laser irradiation (Wilcoxon signed-rank test,  $p < 0.05$ ; Mann-Whitney test,  $p < 0.05$ ; Table 2). After fluoridation, the average width of these patterns was approximately 43  $\mu\text{m}$  compared with 60  $\mu\text{m}$  after laser irradiation.

#### SEM examination

Under SEM examination, ultrastructural changes in the dentinal structure were observed. Six different structural and morphological markers were recorded:

1. Wide-open tubules (Fig. 4a)
2. Partly occluded or narrowed tubules (Fig. 4b)
3. Surfaces with impressions of tubule orifices (Fig. 4c)
4. Smooth and unstructured surfaces (Fig. 4d)
5. Surfaces with superficial precipitation (Fig. 4e)
6. Melted surfaces (Fig. 4f).

In a few cases, cracks and superficial pellets were observed, but the results were not predictable. After qualitative analysis of these structural changes, statistical analysis was performed using the chi-square test ( $p = 0.05$  significance level).

No statistically significant differences between laser application in Groups 1–4 with or without absorber application (chi-square test,  $p > 0.05$ ) and in Groups 1, 2, 3 and 4 with and without absorber application prior to laser treatment combined (chi-square test,  $p > 0.05$ ) were observed (Table 3).

AD

# Join the largest educational network in dentistry!



Register for  
**FREE!**

- education everywhere and anytime
- live and interactive webinars
- more than 500 archived courses
- a focused discussion forum
- free membership
- no travel costs
- no time away from the practice
- interaction with colleagues and experts across the globe
- a growing database of scientific articles and case reports
- ADA CERP-recognized credit administration

[www.DTStudyClub.com](http://www.DTStudyClub.com)

