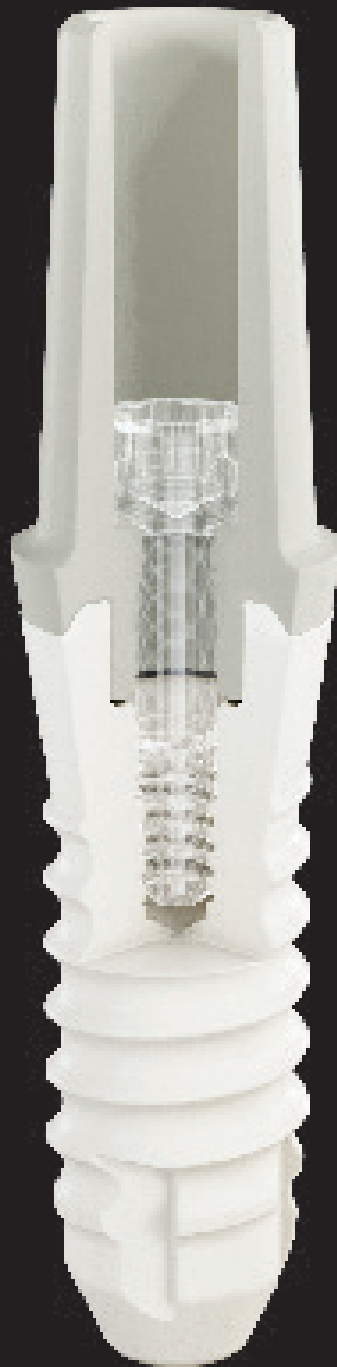


# ceramic implants

international magazine of ceramic implant technology



## case report

Tooth replacement with one-piece zirconia implants

## industry

Ceramics come of age

## interview

Metal out—Ceramics in!



Straumann® PURE Ceramic Implant System  
Discover natural PURE white.  
Love your smile.

Two-piece design  
available soon



**OUTSTANDING  
ESTHETICS**

Favorable soft  
tissue attachment,  
high-end esthetic  
restorations



**PROVEN  
QUALITY**

High performance  
zirconia ceramic,  
100% proof tested



**EXCEPTIONAL  
SURFACE**

ZLA® surface with  
revolutionary  
osseointegration  
features



**METAL-FREE**

A metal-free  
alternative to  
titanium implants



**INNOVATIVE**

A new system that  
helps you expand  
your patient pool



Contact your local Straumann representative now or visit  
[www.straumann.com/pure](http://www.straumann.com/pure)

**Georg Isbaner**

Editorial Manager



# Ceramic implants—We need to talk!

The number of initiatives surrounding ceramic implants has increased significantly lately. New expert associations dealing solely with this subject are taking the stage. In Europe alone, three major congresses on ceramic implantology will take place this year. And in the US, the IAOCI and its cooperation partners are also quite active.

It therefore seems fair to say: there is a lot to talk about, when it comes to ceramic implants.

The fact that there is a strong need for communication is reflected in this issue of *ceramic implants—international magazine of ceramic implant technology*: Never before have we received so many specialist articles and information as for this issue. And never before did we print so many pages—and still were not able to take everything into account.

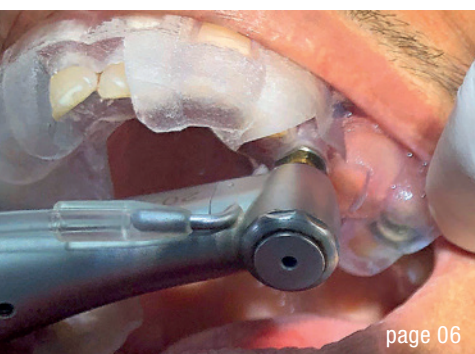
During IDS 2019 in Cologne, we've had the opportunity to talk to numerous ceramics specialists. For a start, we spoke to Ric Donaca, CEO and Head of Development of the Germany-based manufacturer Argon Medical, about his new ceramic implant system, which is made with a synthetic content, giving the material the elasticity that is necessary to deal with high loading forces (pages 42

and 43). An interview with Frank Hemm, Head of Marketing & Education at Straumann, and Rubino Di Girolamo, CEO of Z-Systems, about the new partnership between the two companies (pages 44–46) was equally informative as a conversation with Philip Bolleter (Head of the Technical Department at Dentalpoint) and Adrian Hunn (Head of Marketing and Sales at Dentalpoint) about the overall market situation and the digital workflow for ceramic implants (pages 40 and 41). Last but not least, we've quizzed Dr Jens Tartsch about future research tasks ceramic implantology has yet to address. Founded in 2018, his expert association is also dedicated to fostering this still rather young field of oral implantology.

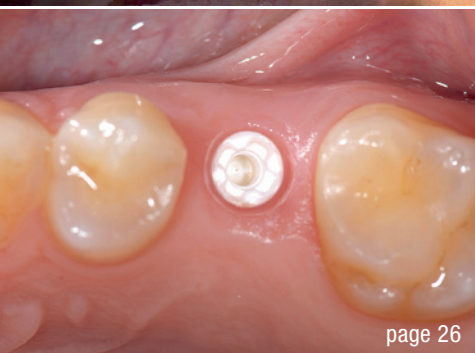
Ultimately, however, this issue is a platform for those who are in direct therapeutic contact with patients: implantologists and prosthodontists who specialise in ceramic implant restorations. The most experienced and globally renowned clinicians share insights into their exceptional work with patients—without them, none of this would be possible.

I hope you enjoy the read.

Yours, Georg Isbaner



page 06

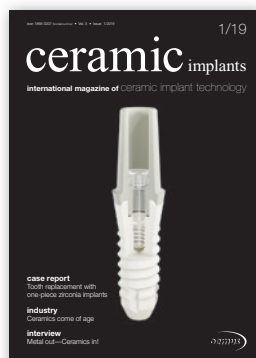


page 26



page 44

Cover image courtesy of  
CAMLOG Biotechnologies GmbH  
[www.camlog.com](http://www.camlog.com)



## editorial

Ceramic implants—We need to talk! 03  
Georg Isbaner

## case report

Zirconia implants and digital workflow: A case report 06  
Drs Saurabh Gupta & Sammy Noumbissi

Tooth replacement with one-piece zirconia implants 10  
Dr Paul S. Petrunaro

Single-tooth restoration in the aesthetic zone 16  
Dr med. dent. Franz-Jochen Mellinghoff

Rehabilitation of an edentulous mandible 20  
Prof. Ziv Mazor

The key to lasting aesthetics 22  
Dr Robert Bauder

Single-tooth restoration with an all-ceramic implant solution 26  
Prof. Dr med. dent. Michael Gahlert

## industry

Ceramics come of age 28  
Prof. Stefan Holst

Staying ahead of the competition 32  
Luc Trevisan

## interview

Metal out—Ceramics in! 40

Harnessing the advantages of ceramics 42

On complementing each other 44

Ceramic implantology—At eye level with titanium 48

## events

Ceramic implants—Game changer in implant dentistry 52

1<sup>st</sup> EACim congress to take place in June 54

New frontiers in metal-free implant dentistry 55

## news

manufacturer news 34

news 56

## about the publisher

imprint 58



CERAMIC EXCELLENCE

CERALOG<sup>®</sup>  
SYSTEM

# INNOVATIVE



**Sophisticated two-piece construction with innovative abutment solution, ceramic-specific design and high-tech 'Ceramic Injection Molding' manufacturing process – that is CERAMIC EXCELLENCE.**

- Dual surface texture: Osseointegration and soft tissue attachment
- Two-piece design, screw-retained reversible prosthetic solutions
- Ceramic-specific design with Hexalobe connection
- Innovative PEKK abutment with stress shield reduction
- Ivory colored for highly esthetic restorations
- 100 % quality control

CERAMIC-SPECIFIC  
DESIGN WITH  
HEXALOBE  
CONNECTION



Become a  
CERAMIC EXCELLENCE  
partner now  
[www.camlog.com/en/implant-systems/ceralog](http://www.camlog.com/en/implant-systems/ceralog)



a perfect fit™

camlog

# Zirconia implants and digital workflow: A case report

Drs Saurabh Gupta, India & Sammy Noubissi, USA

## Introduction

Advancements made in the dental zirconia industry have given rise to new and alternative treatment options for implantology. When compared with other ceramic oxides, zirconia exhibits outstanding biochemical properties. Since its introduction to dentistry, it has been utilised as a material suitable for fixed dental prosthesis, ceramic crowns, metal-free implant abutments and prosthetic frameworks. Zirconia is highly suitable for dental implants owing to its tooth-like colour, structure, material properties and biological response. Additionally, human studies indicate minimised adhesion of bacteria to zirconia compared with titanium. Zirconia also exhibits fewer inflammatory cells within the peri-implant soft tissue.

A recently conducted systematic review showed a 95 per cent survival rate of one- and two-piece zirconia implants after one year of successful functioning.<sup>1</sup> According to this article, the marginal bone loss and survival values of

one- and two-piece zirconia implants after a year is acceptable. Also, it must be highlighted that there is a lack of data specifying the performance of zirconia implants in long-term studies, and thus, it has become increasingly important to further research these implants and to obtain more data. In the following, a clinical case is depicted in which a maxillary premolar is replaced using a one-piece ceramic implant following a digital workflow from treatment planning to prosthetic rehabilitation.

## Initial situation

A 44-year-old patient attended the scheduled dental maintenance appointment complaining of a fractured tooth (Fig. 1), which had been treated endodontically and restored with a crown five years prior. The patient was a non-smoker and had an otherwise unremarkable medical history. Clinical assessments revealed little pain during percussion. A periapical radiograph confirmed the clinical findings and revealed the fracture line to be at the

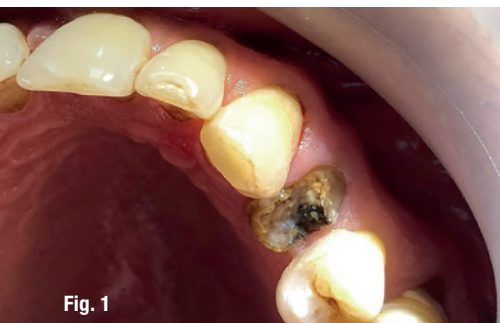

Fig. 1

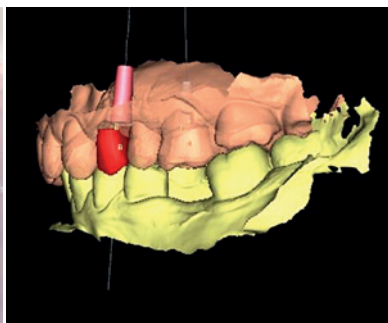


Fig. 2

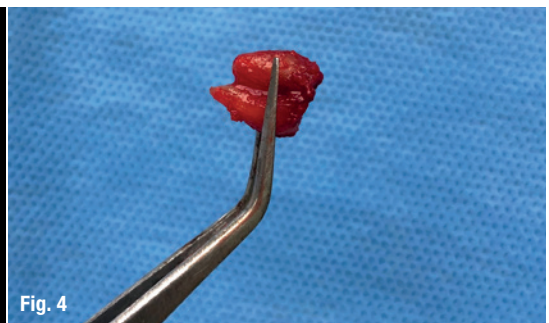


Fig. 4

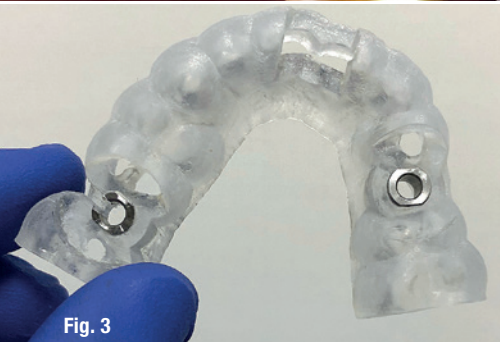

Fig. 3

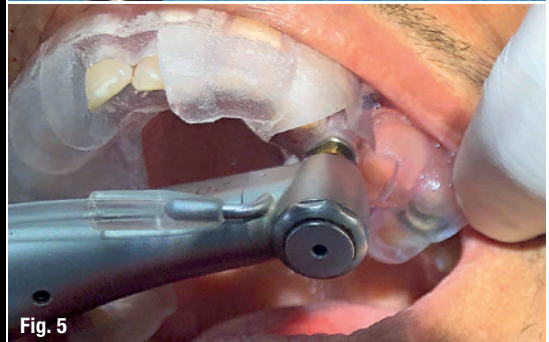
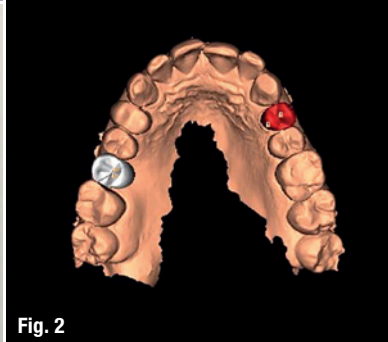



Fig. 5

**Fig. 1:** Initial clinical situation. **Fig. 2:** Digital pre-planning of the surgery. **Fig. 3:** The final surgical guide. **Fig. 4:** The extracted tooth #24. **Fig. 5:** During the guided surgery treatment.



# The unique Tissue Level Implant with Zirconia Collar



Aesthetic gingival area

Zirconia collar

Gingival integration & Osseointegration

Bone area

Pure Titanium body

## Z1<sup>®</sup> Implant Giving you confidence in implantology.

### Proven Technology

- ✓ 98.6%\* success rate
- ✓ Pure Titanium and Y-TZP Zirconia
- ✓ Suitable for all prosthetic solutions

### Proven clinical outcomes for patient safety

- ✓ Anti-bacterial shield
- ✓ Ideal in fresh extraction sockets
- ✓ Immediate aesthetic result

### Proven economics for a profitable implant practice

- ✓ Reduced chairtime
- ✓ Practice development
- ✓ Patient satisfaction

### Proven surgical protocols for a simplified workflow

- ✓ Only 1 surgery
- ✓ No healing abutment
- ✓ Visibility of the connection



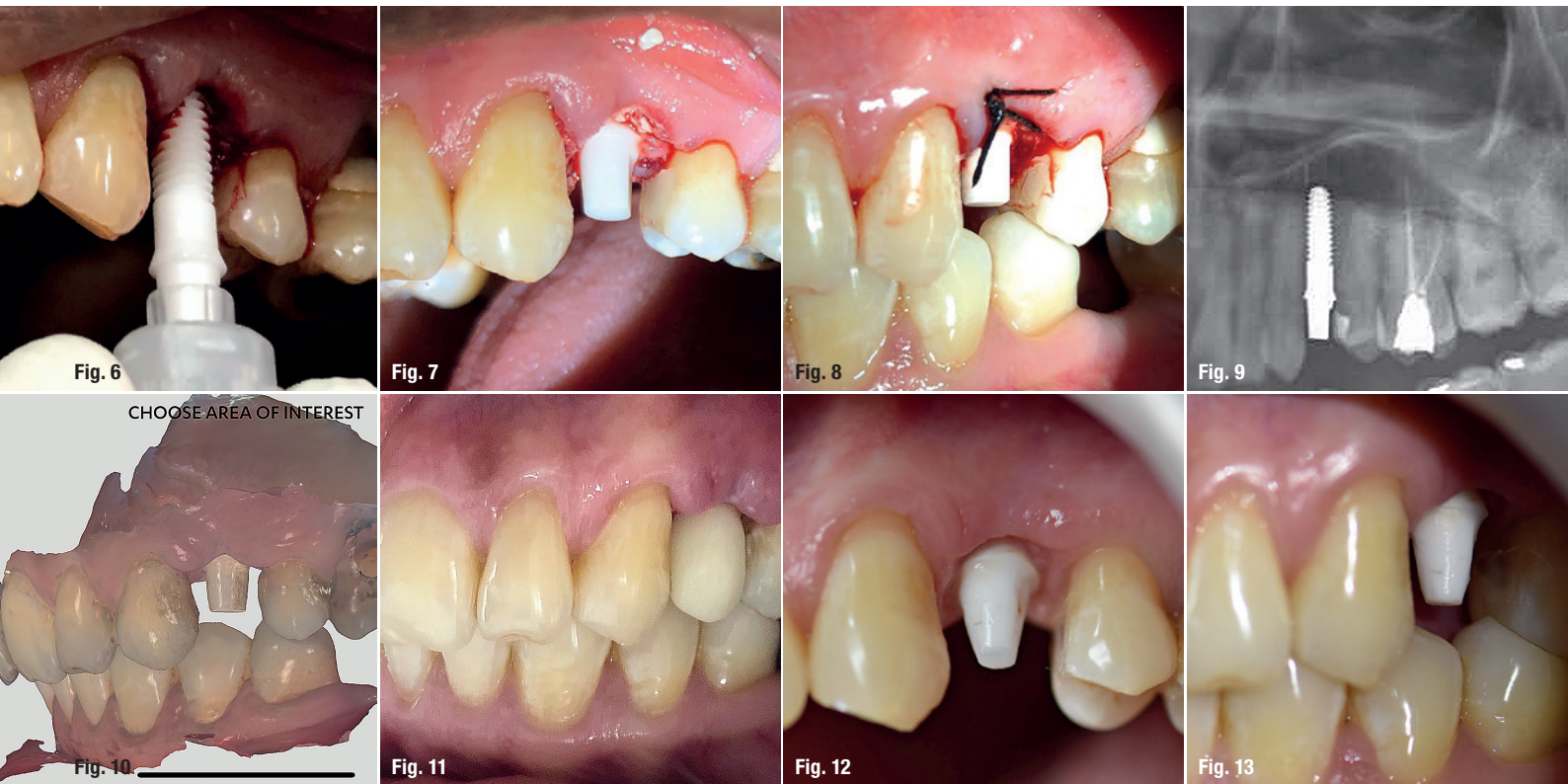Find us online  
[www.tbr.dental](http://www.tbr.dental)



Unique, like your smile

\*Z1 implants are medical devices of class IIb manufactured by SIRONI IMPLANT S.p.A. Information on latest clinical data of the Sironi Implantology program based on 15,534 patients with Z1 implants from 01/2011 to 01/2016.





**Fig. 6:** Placement of the implant. **Fig. 7:** Bone grafting material placed around the implant body. **Fig. 8:** The horizontal mattress suture. **Fig. 9:** Radiograph taken immediately after surgery. **Fig. 10:** The optical scan after surgery. **Fig. 11:** The provisional restoration. **Figs. 12 & 13:** Tooth preparation.

cervical margin of tooth #24. A horizontal root fracture was diagnosed and the patient agreed to his tooth being replaced with a metal-free ceramic implant.

### Digital planning

A digital design software programme was used for designing the surgical guide and for implant planning. CBCT scans were combined with an open-format surface in the planning software for gaining a comprehensive clinical insight (Fig. 2). The benefits of prosthetic-based implant planning for achieving optimal function and aesthetics were considered while accounting for the current clinical situation, including bone density, soft-tissue type and anatomy, and projected prosthesis. A customised surgical guide was designed based on the planned position of the implant (Fig. 3). The provisional restoration was digitally designed and fabricated by the laboratory technician for immediate restoration.

### Surgical procedure

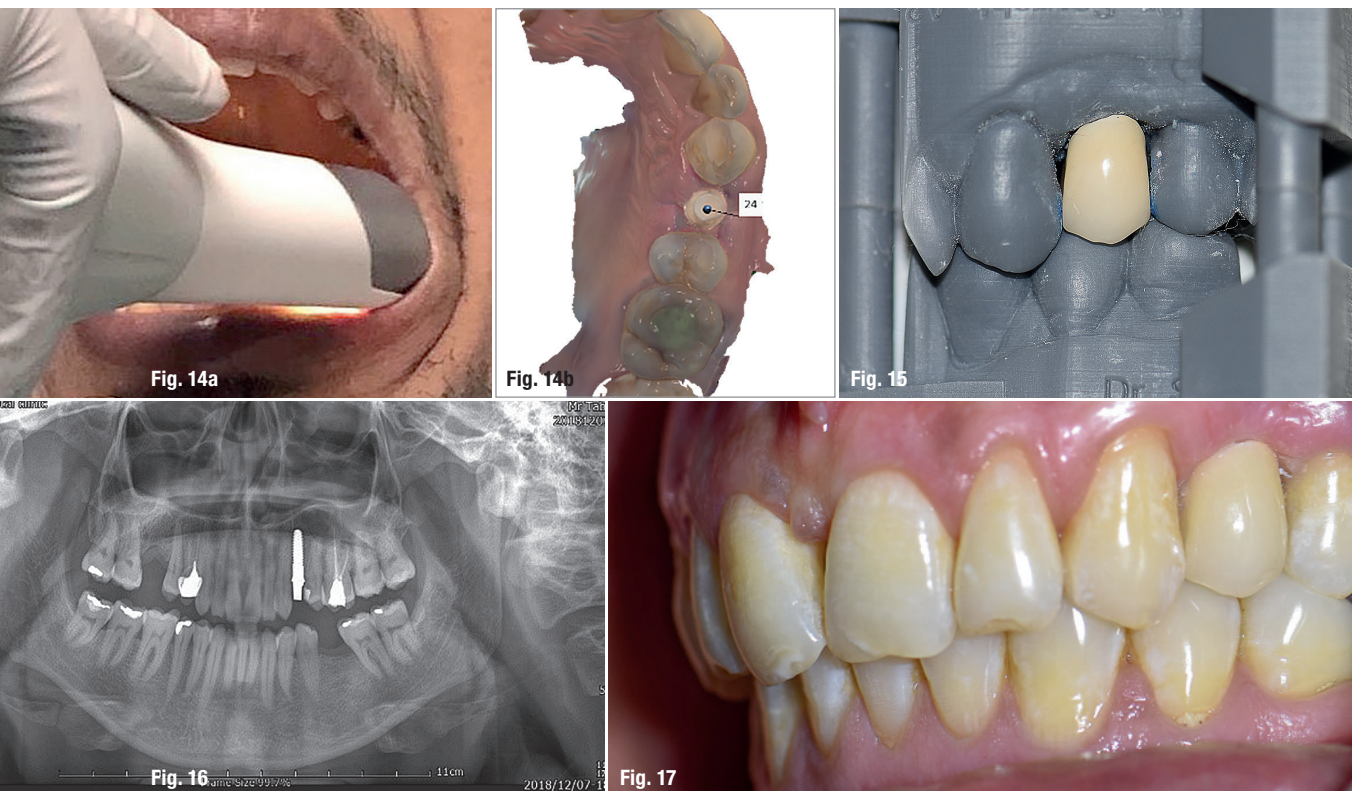
On the day of surgery, a pre-surgical dose of 600mg of ibuprofen and 750mg of amoxicillin was administered to the patient. Atraumatic extraction was carried out to remove the root tip (Fig. 4). The manufacturer's instructions were followed for placing the conventional surgical guide and preparing the implant bed. Implant indicators were used for

preparing and maintaining an accurate vertical position for placing the monotype zirconia implant. A ZiBone zirconia implant (COHO Biomedical Technology) with a diameter of 4.0mm, a body length of 11.5mm and an abutment height of 4.0mm was surgically placed by means of guided surgery without the need for a flap (Fig. 6). After being placed at a torque of 35Ncm, the implant showed good primary stability. The minor buccal bone defect was corrected using bone cement (Augma Biomaterials) to enhance the vestibular ridge contour and to give the crown a natural appearance (Fig. 7). A horizontal mattress silk suture was placed for closure (Fig. 8). Also, the acrylic provisional restoration fabricated prior to the surgery using the implant design software was inserted immediately after the surgical procedure (Figs. 9–13). A chlorhexidine mouthrinse, an anti-inflammatory and antibiotics were prescribed. The suture was removed seven days after the implant placement.

### Prosthetic phase

The osseointegration was successful and it was planned to restore the implant using a zirconia crown after four months. The abutment portion was prepared using Magic Touch burs (Strauss & Co.), and an intraoral optical scan (TRIOS 3 Wireless, 3Shape) was taken of the abutment portion of the monobloc zirconia implant (Figs. 14 & 15). Self-adhesive resin cement (3M ESPE) was used after cleaning and air-drying the zirconia surfaces. Excess





**Fig. 14a:** Intraoral scanning. **Fig. 14b:** Optical scan for final restoration. **Fig. 15:** The final crown. **Fig. 16:** Radiograph taken four months after surgery. **Fig. 17:** Situation one year after surgery.

cement was removed carefully using dental floss after cementation of the final crown.

Control and maintenance appointments were scheduled six months and one year after placement of the implant (Figs. 16 & 17). The implant crown was still functional and no technical complications were observed at either appointment. The soft tissue surrounding the implant with respect to site #24 was quite healthy. A periapical radiograph was taken at the one-year follow-up. Bone remodelling around the implant was normal and the level of bone surrounding the border had fully stabilised. The patient was satisfied with the treatment outcome, in terms of both aesthetics and function.

### Conclusion

No technical or biological complications were recorded after one year of implant functioning. Thus, the use of a zirconia implant in this case turned out to be a suitable alternative to a titanium implant. The soft tissue surrounding the implant was stable and exhibited outstanding biocompatibility. The vertical implant position is an important factor for success of such implants, as the soft-tissue collar of the implant needs to be apically positioned at a depth that allows for soft-tissue apposition and attachment up to the restorative platform. For such a one-piece implant, the process of restoration requires cementation,

which bears the risk of excess cement being retained subgingivally, leading to complications ranging from bone loss to implant failure.



### contact



**Dr Saurabh Gupta, BDS MDS**

Oral and Maxillofacial Surgeon, India Board of Director, IAOCI, USA  
saurabh@iaoci.com



**Dr Sammy Noubissi, DDS, MS, PA**

IAOCI President  
801 Wayne Avenue Suite #G200  
Silver Spring MD 20910, USA  
sammy@iaoci.com

