



Stop losing money
Two proven ways
to grow your practice

▶Page 9



Do more in 3-D
New version of imaging
software adds features

▶Page 12



Fun for all ages
New product brings
gaming to the office

▶Page 14



The Las Vegas Strip. (Photo/Provided by stock.xchng)

What happens in Vegas

... could change your practice for the better

By Kristine Colker, Managing Editor

If you are not yet headed to Las Vegas from Sept. 16-18 for the first OrthoVOICE orthodontic meeting, there is still time to get in on the action.

→OT page 3

Miniscrews: a focal point in practice

Part 4 of 6: More clinical examples

By Dr. Björn Ludwig, Dr. Bettina Glasl, Dr. Thomas Lietz and Prof. Jörg A. Lisson

The straightening of mesially tipped (second) molars in a full dentition represents a therapeutic

challenge. The treatment is further complicated if the tooth is not only tipped but also partly impacted.

The presence of a non-erupted third molar does not simplify the process (Fig. 1a). When planning the required appliance, it is important to consider whether it is necessary, for example, to reshape the entire dental arch (Figs. 1a-d) or just upright the tipped tooth.

If miniscrews with bracket heads are used, it is possible to employ a special NiTi uprighting spring (such as the Memory Titanol spring, FORESTADENT).

A standard multi-bracket appliance can be used to reshape the dental arch.

→OT page 4

AD

Dental Tribune America
213 West 35th Street
Suite #801
New York, NY 10001

PRSR STD
U.S. Postage
PAID
Permit # 306
Mechanicsburg, PA

**MOTIVATE
CHALLENGE
CONNECT**

September 16-18, 2010

ph planet hollywood
RESORT & CASINO • LAS VEGAS

For a new generation of orthodontists who are passionately making their mark on our profession!
REGISTER TODAY AT: www.orthoVOICE.com

What does it mean to be scholarly?

By Dennis J. Tartakow, DMD, MEd, PhD,
Editor in Chief



Quoting Nathan Pusey's "The Age of the Scholar" (1965), "We live in a time of such rapid change and growth of knowledge that only he who is in a fundamental sense a scholar — that is, a person who continues to learn and inquire — can hope to keep pace, let alone play the role of guide" (Howe, 2003, p. 19).

Dr. Pusey's quote is almost 50 years old but is as important, if not more important, today as it was then. The concepts and principles for which his words stand for also apply to the goals and direction set forth by our orthodontic training programs.

To be scholarly and erudite requires a fundamental understanding of ethics or moral philosophy, which addresses questions about morality, justice and virtue.

These concepts are clearly not (a) a matter of following one's feelings, (b) identified with religion, (c) the same as following the law or (d) the same as doing whatever society accepts.

Most individuals accept standards that are, in fact, ethical. However, societal standards of behavior can deviate from what is ethical; an entire society can become ethically corrupt.

With these thoughts under the

microscope, ethics must satisfy two concepts or principles:

- Ethics must refer to right and wrong — standards that prescribe what humans should do in terms of rights, obligations, fairness, specific virtues or benefits to society, such as standards that (a) impose the reasonable obligations of values that include enjoining virtues of honesty, compassion and loyalty; and (b) relate to rights, such as the right to life, freedom from injury and privacy. Consistent, well-founded reasoning supports these ethical standards.
- Ethics must refer to the study and development of moral standards — feelings, laws and social norms that deviate from what is considered to be ethical. It is necessary to continually examine one's standards to ensure they are well founded and reasonable. It also means the continuous effort of studying our own moral beliefs and conduct, striving to ensure that we and the institutions we help to shape live up to standards that are reasonable and solidly based.

According to Webster's Online Dictionary (2010), there are many other applied definitions, explanations and descriptions of scholarly communication. In general, scholarly communication is an umbrella term illustrating the process of academics, intellectuals and researchers publishing and contributing their findings to the wider academic community and beyond.

It is simply the creation and dissemination of knowledge related to research, education and erudite endeavors.

There has been widespread belief that the dissemination of scholarship in the traditional system has reached a state of crisis in recent years, which has also been referred to as the publishing crisis (UConn Libraries Spring Forum, 2008).

Such concepts must be encouraged and promoted as goals and

directions for all students in colleges and universities.

Our orthodontic residents in undergraduate, postgraduate or continuing education must also be encouraged to seek these principles of scholarship to maintain quality guidelines and to improve the standards of orthodontic education. **OT**

References

1. Pusey, N. (1965). The Age of the scholar. In R. Howe (Ed.), The quotable teacher (p. 19). The Lyons Press: Guilford Connecticut.
2. UConn Libraries Spring Forum. (2008). Scholarly Communication Crisis. Retrieved from: www.lib.uconn.edu/about/publications/scholarlycommunication.html#Whatis.
3. Webster's Online Dictionary. (2010). Scholarly communication. Retrieved from: www.websters-online-dictionary.org/definitions/Scholarly+communication?cx=partner-pub-0939450753529744%3Av0qd01-tdlq&cof=FORID%3A9&ie=UTF-8&q=Scholarly+communication&sa=Search#906.

OT Corrections

"Miniscews: a focal point in practice," on Page 1 of the June/July issue of Ortho Tribune, was Part 3 in a series of 6.

Ortho Tribune strives to maintain the utmost accuracy in its news and clinical reports. If you find a factual error or content that requires clarification, please report the details to Managing Editor Kristine Colker at k.colker@dental-tribune.com.




Image courtesy of Dr. Earl Broker.

Member Publication
AADE
American Association
of Dental Editors

ORTHO TRIBUNE
The World's Orthodontic Newspaper - U.S. Edition

Publisher & Chairman
Torsten Oemus, t.oemus@dental-tribune.com

Vice President Global Sales
Peter Witteczek
p.witteczek@dental-tribune.com

Chief Operating Officer
Eric Seid, e.seid@dental-tribune.com

Group Editor & Designer
Robin Goodman
r.goodman@dental-tribune.com

Editor in Chief Ortho Tribune
Prof. Dennis Tartakow
d.tartakow@dental-tribune.com

International Editor Ortho Tribune
Dr. Reiner Oemus
r.oemus@dental-tribune.com

Managing Editor/Designer Ortho Tribune & Show Dailies
Kristine Colker, k.colker@dental-tribune.com

Managing Editor/Designer Implant, Lab & Endo Tribunes
Sierra Rendon, s.rendon@dental-tribune.com

Online Editor
Fred Michmershuizen
f.michmershuizen@dental-tribune.com

Product & Account Manager
Humberto Estrada
h.estrada@dental-tribune.com

Product & Account Manager
Mark Eisen, m.eisen@dental-tribune.com

Product & Account Manager
Gregg Willinger
g.willinger@dental-tribune.com

Marketing Manager
Anna Wlodarczyk
a.wlodarczyk@dental-tribune.com

Marketing & Sales Assistant
Lorrie Young, l.young@dental-tribune.com

C.E. Manager
Julia Wehkamp
j.wehkamp@dental-tribune.com

Dental Tribune America, LLC
213 West 35th Street, Suite 801
New York, NY 10001
Phone: (212) 244-7181, Fax: (212) 244-7185



Published by Dental Tribune America

© 2010, Dental Tribune International
All rights reserved.

Dental Tribune makes every effort to report clinical information and manufacturer's product news accurately, but cannot assume responsibility for the validity of product claims, or for typographical errors. The publishers also do not assume responsibility for product names or claims, or statements made by advertisers. Opinions expressed by authors are their own and may not reflect those of Dental Tribune International.

OT Editorial Advisory Board

Jay Bowman, DMD, MSD
(Journalism & Education)

Robert Boyd, DDS, MEd
(Periodontics & Education)

Earl Broker, DDS
(T.M.D. & Orofacial Pain)

Tarek El-Baily, BDS, MS, MS, PhD
(Research, Bioengineering & Education)

Donald Giddon, DMD, PhD
(Psychology & Education)

Donald Machen, DMD, MSD, MD, JD, MBA
(Medicine, Law & Business)

James Mah, DDS, MSc, MRCD, DMSc
(Craniofacial Imaging & Education)

Richard Masella, DMD (Education)

Malcolm Meister, DDS, MSM, JD
(Law & Education)

Harold Middleberg, DDS
(Practice Management)

Elliott Moskowitz, DDS, MSD
(Journalism & Education)

James Mulick, DDS, MSD
(Craniofacial Research & Education)

Ravindra Nanda, BDS, MDS, PhD
(Biomechanics & Education)

Edward O'Neil, MD (Internal Medicine)

Donald Picard, DDS, MS (Accounting)

Howard Sacks, DMD (Orthodontics)

Glenn Sameshima, DDS, PhD
(Research & Education)

Daniel Sarya, DDS, MPH (Public Health)

Keith Sherwood, DDS (Oral Surgery)

James Souers, DDS (Orthodontics)

Gregg Tartakow, DMD (Orthodontics)
& Ortho Tribune Associate Editor

**Tell us
what
you
think!**

Do you have general comments or criticism you would like to share? Is there a particular topic you would like to see more articles about? Let us know by e-mailing us at feedback@dental-tribune.com. If you would like to make any change to your subscription (name, address or to opt out) please send us an e-mail at database@dental-tribune.com and be sure to include which publication you are referring to. Also, please note that subscription changes can take up to six weeks to process.

← OT page 1

The three-day event is shaping up to be different from most other conventions out there, including giving attendees more time in the exhibit hall without having to worry about conflicting educational sessions, a new generation of speakers who haven't yet shared their stories with meeting attendees and a simple way to have dinner at some great restaurants and meet some new friends.

"I've been to several orthodontic meetings around the world and seen the different ways people have presented academic programs," said Dr. Clarke Stevens, the man behind OrthoVOICE. "European meetings often have more people involved than the regular list of speakers. We thought it would be interesting and creative to invite different types of people."

Some of these people include Dr. Scott Law, a practicing orthodontist in Killeen, Texas, who just finished his residency in 2009. He will speak on "Hit the Ground Running While Training for a Marathon — Know When to Pass the Baton and Win the Relay."

It also includes Dr. Jennifer J. Garza, who started her career as an orthodontic assistant and now has her own paperless practice and is a biologic orthodontist. She will share how her experiences have shaped the philosophies she is determined to uphold in her practice.

Each day of the meeting, there will be sessions for orthodontists and sessions for staff, with two to three tracks going at the same time. However, attendees aren't limited by their job descriptions — if an orthodontist wants to attend a staff-focused presentation or vice versa, he or she is more than welcome to do so.

Another idea taken from European meetings, Stevens said, will be a more creative use of exhibit hall space. Not only will attendees have one-hour breaks to explore the exhibits, but vendors are encouraged to have entertainment or themes in their booths. One exhibitor, Stevens said, is considering offering a coffee bar in the morning with pastries.

Of course, a meeting is never complete without an array of social activities, and OrthoVOICE has plenty of those. A cocktail party kicks off the first night with entertainment, while a cocktail party the second night is more of a wine-and-cheese affair.

Two unique events are the breakfast roundtable and Dinner With Strangers. For breakfast, every table will have a moderator and a topic, from how one conducts a new patient exam to how one closes spaces where there's been an extraction. Orthodontists and staff are encouraged to pick a topic they want to discuss and spend their meal sharing information with others.

For Dinner With Strangers, attendees will find a list in their reg-

istration materials of various restaurants around Las Vegas where OrthoVOICE has made reservations for eight to 10 people.

Attendees will pick a restaurant they would like to go to and will then show up for dinner with other attendees who they haven't yet met.

"Sometimes I go to a meeting alone, and I wonder where I'm going to eat," Stevens said. "But this way, you can go to a great restaurant and have a great evening with some new friends."

Stevens said he likes that OrthoVOICE is being held in Las Vegas and plans to keep it there every fall.

"Vegas is a great place to have a meeting because it's sort of an entertainment capital, and people love to come there," he said.

OT OrthoVOICE registration & information

When

Sept. 16–18. Check-in begins at 2 p.m. Thursday. The opening party will be held that night at 6 p.m. Breakfast roundtables begin at 7 a.m. on both Friday and Saturday.

Where

Planet Hollywood Hotel and Casino, 3667 Las Vegas Blvd. South, Las Vegas, 89109

Registration

To register for OrthoVOICE, go online to www.orthovoice.com. Orthodontists and staff members are \$250 each and residents are \$200. To make reservations at Planet Hollywood, call (877) 244-9474.

Registration includes admission to all lectures during the event, admission into the opening party Thursday and the cocktail party Friday and food/beverage service at four breaks daily on Friday and Saturday.

"It's also nice to have stability and have a meeting in one place every year, so if someone can't

make it to the AAO one year, they know they will have this nice alternative." OT

AD

Go beyond just treating malocclusion

Malocclusion
New techniques
Poor oral habits
Soft tissue dysfunction
Compliance
Financial gain

With the high demand from parents for early treatment, it is vital to arm yourself with the most cost effective treatment.

TAKE YOUR PRACTICE TO THE NEXT LEVEL
The majority of children from six years of age will show signs of malocclusion. In many cases, the underlying causes are never addressed. Just treating malocclusion with either a fixed or functional appliance does not address these problems.
Myofunctional Research Co. (MRC) has spent the last 20 years educating Doctors; teaching them how to go beyond the treatment goal of just straightening teeth. Myofunctional treatment with MRC's appliances adds another dimension into dental and facial development.
Once educated, most parents and their children would prefer this approach - less braces, better facial development and a stable result without retainers.

MRC has a comprehensive range of myofunctional appliances, designed to treat the real causes of malocclusion. By attending an **MRC Educational Program**, you can learn how to effectively incorporate these appliances into your practice, delivering the best results for your patients, while maximising your financial gain.

NEW: MRC training facility now in Southern California.

MYOFUNCTIONAL RESEARCH CO.
www.myoresearch.com
a BETTER way

Next course **1st to 2nd October 2010**
MRC Training Facility, California

Book now **1866 550 4696** (limited seats)
More info www.myoresearch.com/courses

1134 OTTRIB 08/10

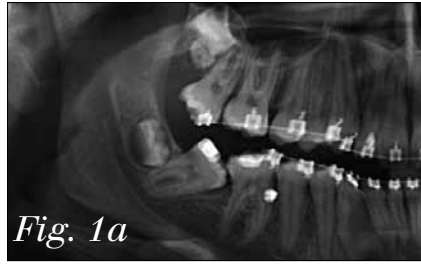


Fig. 1a

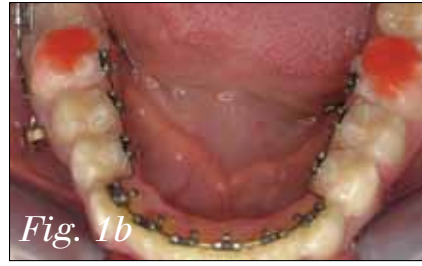

Fig. 1b

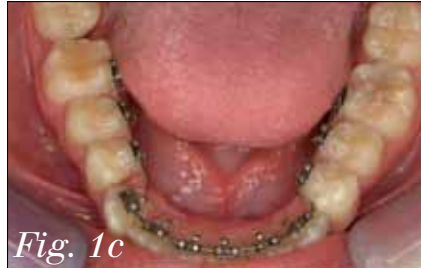

Fig. 1c

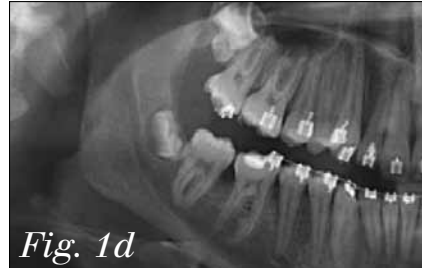


Fig. 1d

Figs. 1c, 1d: Status after five months without reactivation of the arch section.

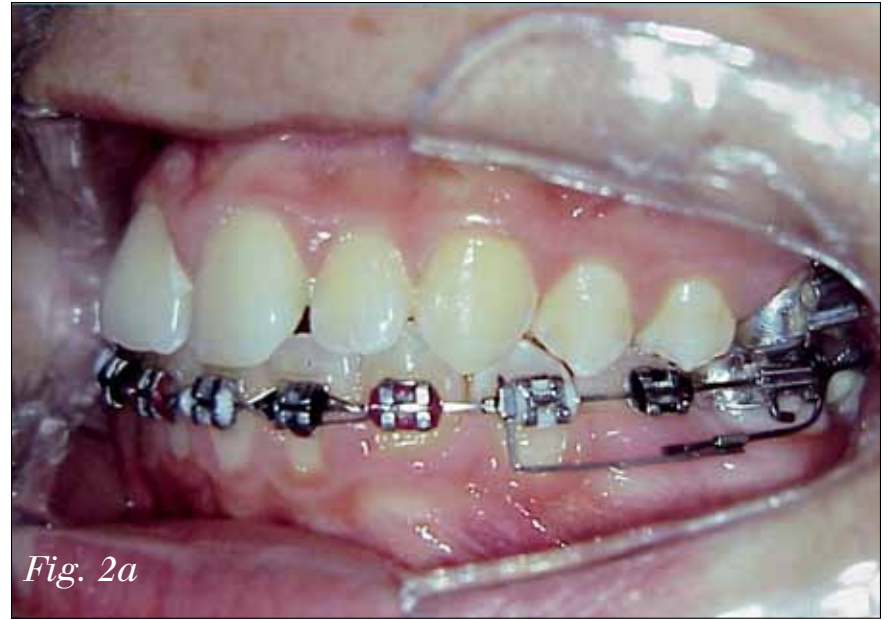

Fig. 2a

Fig. 2: The uprighting spring fixed to the main arch not only affects the molars, but also causes displacement of the premolars (loss of anchorage).

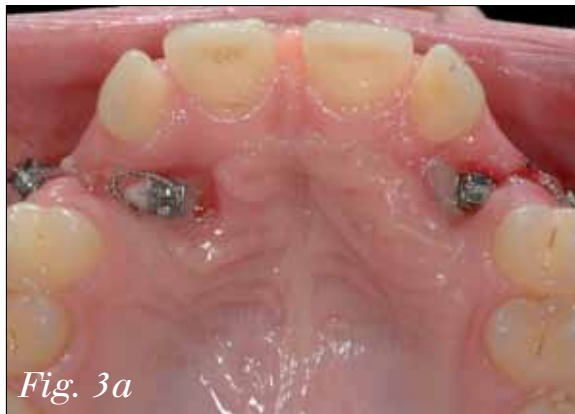

Fig. 3a

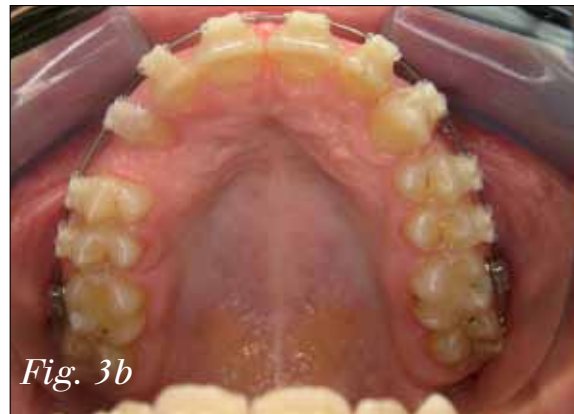

Fig. 3b

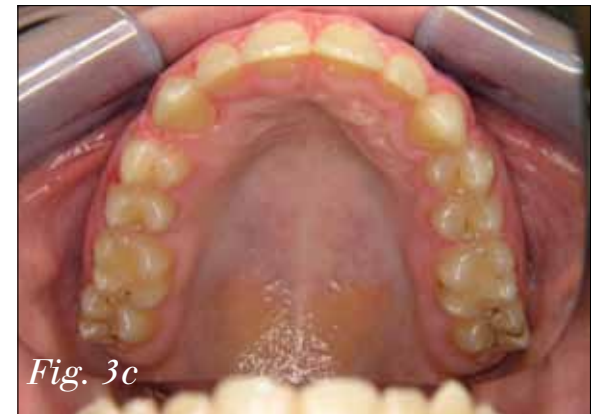

Fig. 3c

Figs. 3a–c: The alignment of a displaced canine using a miniscrew. After the canines have been exposed, they are attached to a bracket by means of a miniscrew (a). After removal of the screw, the dental arch can be reshaped using a conventional technique (b, c).

← OT page 1

At the same time, a second force element can be applied with the aid of a miniscrew and an uprighting spring (Figs. 1b–d). This avoids the loss of anchorage that inevitably occurs when only an uprighting spring is fixed to the multi-bracket appliance (Fig. 2).

The straightening of an individual tooth may become necessary for periodontological, prosthetic or orthodontic reasons. This is a very simple procedure if a miniscrew and uprighting spring are used and the appliance remains invisible to the observer. The tooth need only be fitted with an appropriate attachment system that makes it possible to fix this to the uprighting spring.

Depending on how the spring is set, it is even possible to achieve intrusion or extrusion of the tooth. This form of treatment is inexpensive for the patient and the orthodontist will find it highly effective.

Alignment of retinated teeth

The alignment of retained or displaced teeth, particularly in the case of canines, is one of the most common forms of surgical intervention in the field of orthodontic techniques. Numerous appliances are available — rubber bands, springs, orthodontic chains — that are effective to a greater or lesser extent.

All these mechanisms have the

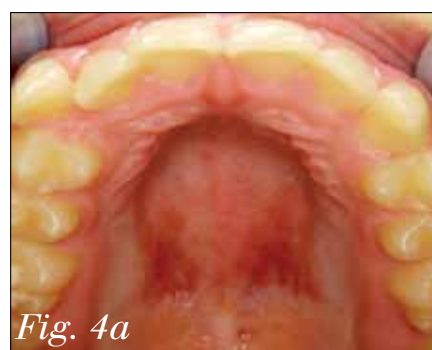

Fig. 4a

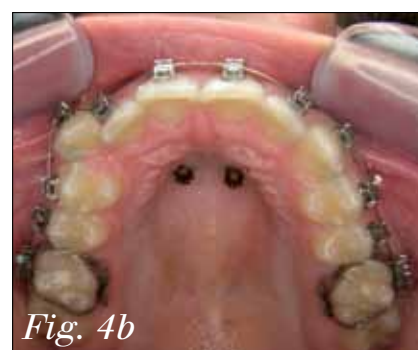

Fig. 4b

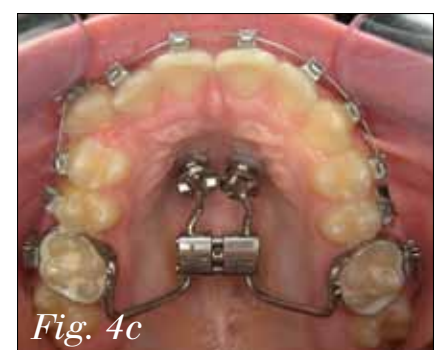

Fig. 4c

Figs. 4a–c: Obtaining additional transverse space by means of 'hybrid RPE.' The initial diagnosis is an asymmetrical narrow jaw with insufficient space for tooth 13 (a). After fixture of the brackets, two miniscrews (OrthoEasy) were inserted during the same session (b). The hybrid RPE appliance was attached to the miniscrews and molar bands using laboratory abutments (FORESTADENT; c).

same underlying problem: the neighboring teeth must be used — directly or indirectly — to provide an anchorage so that the required traction forces can be applied.

Ideally, the neighboring teeth will offer the greater resistance so that only the retained tooth moves. Realistically, however, both components tend to move toward each other.

In the worst-case scenario, only the group providing anchorage is displaced from its original position. This can occur if there is ankylosis of the retained tooth, something that is difficult to evaluate during initial examination.

If an attempt is made to move an ankylosed canine toward insufficient dental anchorage, the result will be the worst-case scenario. This can lead to an open bite in the region of the anterior teeth and premolars.

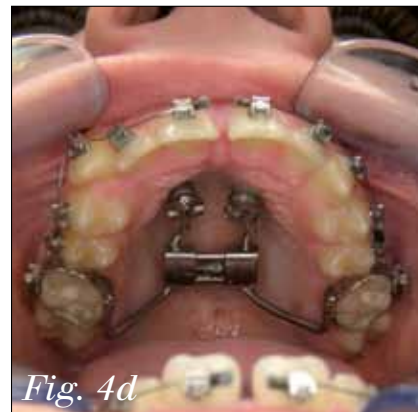

Fig. 4d

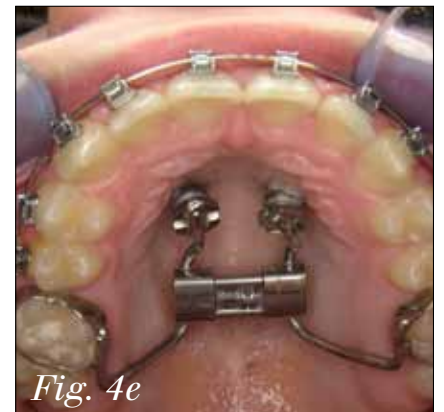

Fig. 4e

Figs. 4d, 4e: The diastema shows the effect of the appliance after 10 days' use (d). Status after transverse expansion and concurrent reshaping of the dental arch (e).

Miniscrews provide the definitive form of anchorage for the alignment of displaced teeth (Figs. 3a–c). If sufficient space is available, brackets will not be needed in the initial phase of treatment.

Skeletal adjustments: palatine suture expansion

Rapid palatal expansion (RPE) is one of the most effective and

→ OT page 6



TenBrook

self-ligating system.

Something to *smile* about!



Mesial/distal cut-outs create increased inter-bracket span to fully express the wire

Chamfered mesial and distal slot openings prevent kinking and permanent sets in wire

Door rotates and locks into both open and closed positions

Hooks available on 3's, 4's & 5's

Smooth, round edges for patient comfort

Slot is both passive & active with four point torque control in larger dimension wires

One piece base/bracket design for optimum pad-to-tooth fit and bond strength

Compound contour/torque-in-base

Call Now **866.752.0065** or Visit www.orthoclassic.com

Find us on



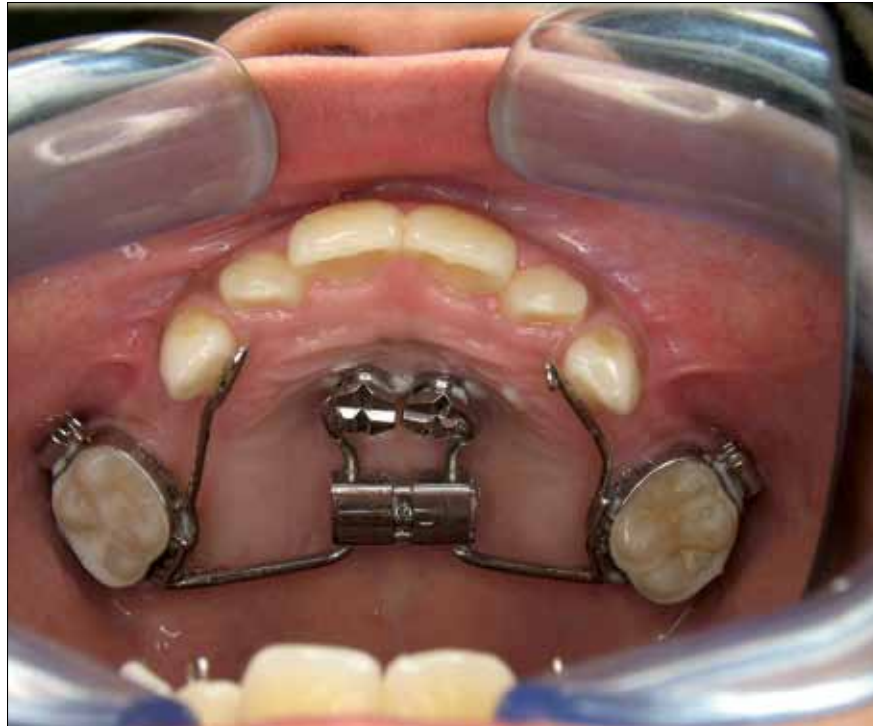

Fig. 5: The hybrid RPE appliance with adjuvant anterior hooks for the attachment of a Delaire mask.

← 01 page 4

stable methods of acquiring more transverse space in the upper jaw. The targeted screw rate should be in the range of 0.2 to 0.6 mm/day.

As a rule, the appliance is fixed by means of bands to the molars and premolars. The desired transverse width can generally be achieved within 10 to 20 days. Thereafter, a three-month stabilization phase should be observed, in order to allow ossification of the ruptured palatine suture.

The standard anchorage technique — with dental support only — has several disadvantages. The most significant is the risk of tipping the anchor teeth.

Many appliances have been described that distribute the force over more than one tooth. A further problem is apparent here: as it is necessary to leave the appliance in place for a longer period after the active phase, it is only possible to com-

mence further corrective treatment for teeth in the anterior region.

It is possible to overcome these problems by using the hybrid RPE (Figs. 4–6).

Bands are employed as usual in the molar region. In the anterior region, the RPE appliance is fixed using two miniscrews. These should be placed on a notional transverse line connecting the canine/premolar contact points paramedially.

Distraction is achieved using the same method as in standard techniques.

There are several advantages to hybrid RPE. Preparation of the apparatus is much simpler and cheaper, whilst the dental arch, including the premolars, is accessible for additional tooth correction measures.

Class II corrections

In the case of patients with Class II malocclusion who have completed or are near completing their growth

→ 01 page 8

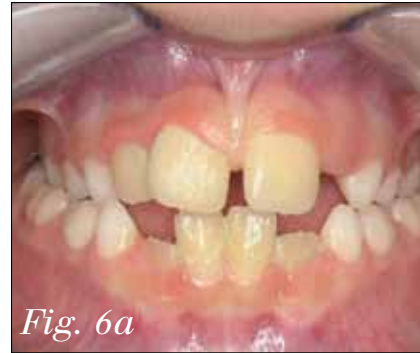

Fig. 6a

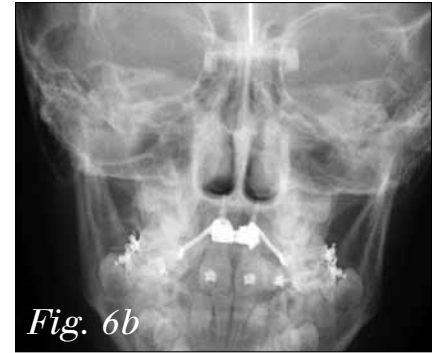

Fig. 6b

Figs. 6a, 6b: Bilateral cross-bite in a 7-year-old boy (a). X-ray of the hybrid RPE appliance in situ (b).

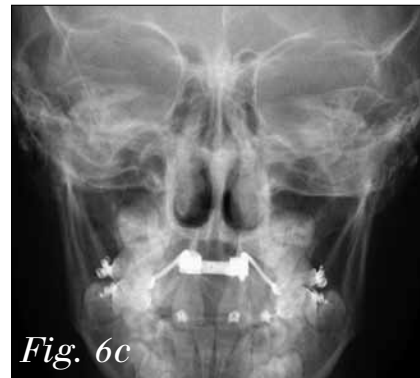


Fig. 6c

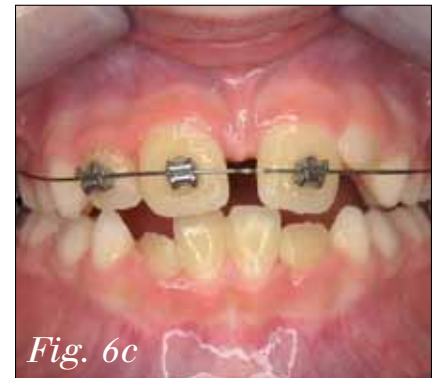

Fig. 6c

Fig. 6c, 6d: Status after 10 days' use: cross-bite has disappeared and vertical bite has remained stable (c, d).

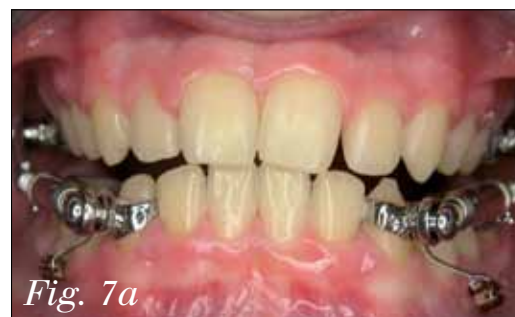

Fig. 7a

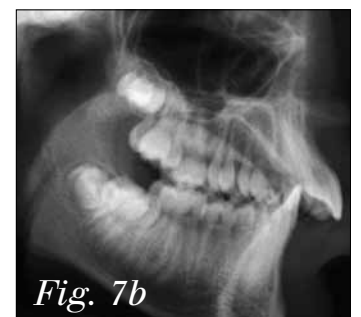

Fig. 7b

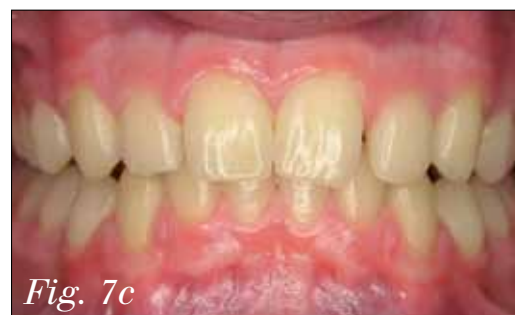

Fig. 7c

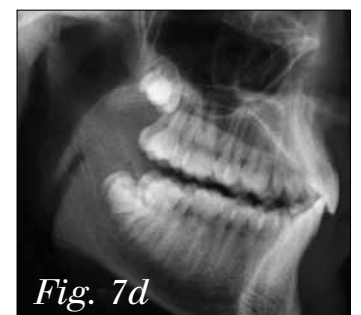


Fig. 7d

Figs. 7a–d: Anchorage of the canine using a miniscrew avoids protrusion of the anterior teeth when using a fixed Class II correction appliance (here: Williams appliance, FORESTADENT).

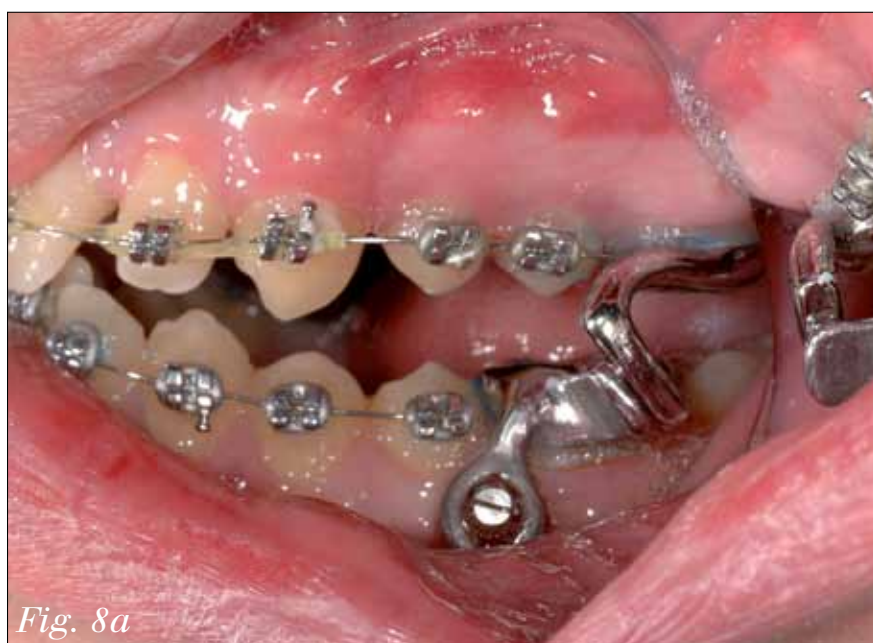

Fig. 8a

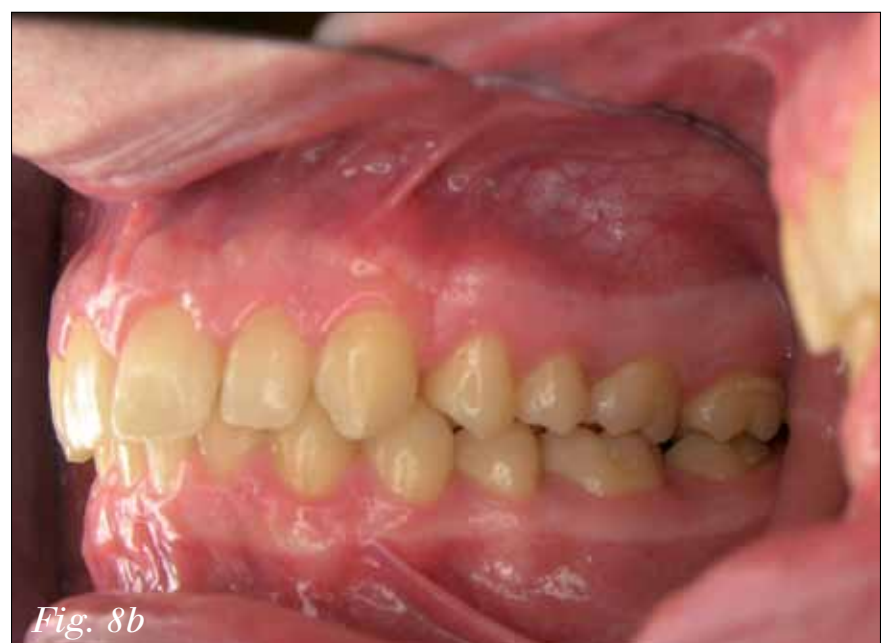

Fig. 8b

Figs. 8a, 8b: The miniscrew stabilizes the position of the molars to which the Kinzinger FMA is attached. This counteracts any protrusion of the premolars and anterior teeth (a). Class I dental status on completion of treatment (b).

4 Keys to Orthodontic Success

Unlock your potential with our all new webinar series!

What is a Webinar?

A webinar is a seminar that is transmitted over the Web. Participants will be able to ask Scarlett questions and get answers in real time. Scarlett will be able to conduct polls, and show results as well as ask questions. Participants will receive course materials by e-mail prior to the seminar and will be able to view Scarlett's PowerPoint slides during the seminar. Webinars offer exceptional convenience and are very cost-effective, eliminating travel expenses all together.



Mastering The New Patient Exam

- How to Increase Case Acceptance
- Educating and Motivating the New Patient
- Creating a Successful "Will Call Back System"
- Having an Effective "Recall System"
- The New Patient Exam as a Team Approach
- Presenting Fees
- The Importance of the Initial Phone Call

Top Notch Management

- The Hiring Process
- Employee Appraisals
- Addressing Collection Policies
- Effective Communication
- Creating and Managing Budgets
- The Importance of Delegation
- Motivating Staff
- Morning Meetings
- Staff Benefits

Effective Marketing That Works

- Creating a Yearly Marketing Game Plan
- Determining a Marketing Budget
- Assigning a Marketing Coordinator
- Understanding the Market Trends
- Internal Marketing
- External Marketing
- Community Marketing
- Media/Direct Marketing
- Staff Marketing

Building A Successful Schedule

- Building a Schedule for the Growth of a Practice
- The Build for Growth Formula
- Scheduling Doctor Time
- Assigning Columns and the Benefits
- Emergency Appointments and How to Handle Them
- Building Production into the Schedule
- Scheduling Deband Days
- The Importance of Morning Meeting

For dates and registration, visit

www.orthoconsulting.com

or call 858-435-2149

How to Join

Three easy steps to joining our webinars

1. Register for the webinar you desire
2. Receive your password and link to log in
3. On the date and time of webinar click the link provided and enter you password

Tuition

\$249 per computer and webinar. Includes course materials sent via email and one month of post-meeting email support.

About Scarlett

Scarlett Thomas is an orthodontic practice consultant who has been in the orthodontic field for over 23 years, specializing in case acceptance, team building, office management and marketing. As a speaker and practice consultant, Scarlett has an exceptional talent to inform, motivate and excite!

After implementation of her concepts into your practice, Scarlett invites you to experience not only tremendous growth and increased income but a well organized practice.



← OT page 6

phase, simple techniques for the forward positioning of the lower jaw are usually ineffective.

Following a thorough initial examination and diagnosis, there are three possible therapeutic approaches: camouflage, fixed Class II correctional appliances (Herbst splint, Sabbagh Universal Spring, FMA, Jasper Jumper, etc.) or orthognathic surgery.

The patient must be informed of the advantages and disadvantages of each approach.

All fixed Class II correctional appliances — irrespective of whether these use the Herbst splint or canted plane principle — have the same problem and the same undesirable side effects. There is a risk of protrusion of the lower frontal teeth and/or distalization of the upper molars.

By means of passive stabilization with the aid of two miniscrews (Figs. 7, 8), these effects can be readily avoided.

Orthognathic surgery

After surgical intervention to relocate or reposition the jaw (for orthodontic or traumatological reasons), it is important to maintain a stable correlation between the bone fragments and the jaw in the postoperative phase.

This promotes healing and prevents relapse.

The occlusion appliance is fixed intraorally, using intermaxillary elastic or wire ligatures, depending on the situation. It is essential to use the appropriate fixing options, whether this is a splint (Schuchardt splint) or a multi-bracket appliance.

Where these are really only needed in one jaw or jaw section, the question arises of whether, in the era of the miniscrew, it is necessary to involve the other jaw in the stabilization of the surgical effect.

If miniscrews are used in the opposing jaw (Fig. 9), the same effect is achieved — but with considerably less restriction from the point of view of the patient.

Pre-prosthetics

It is the aim of pre-prosthetic orthodontics to position the teeth optimally for the subsequent prosthesis. This can include intrusion, uprighting and the opening or closing of gaps amongst other techniques.

As this series and many other publications have already shown, miniscrews are particularly useful in this context. Miniscrews can also be used as anchoring elements for a provisional prosthesis.

Where teeth are missing (particularly the second canines, Fig. 10a) and the growth phase is not yet completed, the fitting of an intermediate prosthesis is problematic.

As an alternative, particularly where additional anchorage is required, miniscrews can be used. A longer screw (8 or 10 mm) can be inserted in the center of the dental ridge (Fig. 10b).

There should be at least 1 mm of bone to the mesial and distal sides of the miniscrew.

The hole for the insertion of a miniscrew (1.6 mm) should thus be at least 2.6 mm. A provisional crown can then be mounted onto the head of the miniscrew. If necessary, a bracket can be fixed to this crown (Fig. 10c).

Outlook

The clinical use of miniscrews supports a wide range of tasks. Dental repositioning that was previously deemed impossible becomes achievable, whilst possible repositioning techniques are improved and supported.

In order to achieve this, miniscrews alone are not sufficient; an appropriate range of equipment is also necessary.

Several suppliers of miniscrews offer, in addition to screws and insertion tools, a number of devices that facilitate the use of miniscrews. The fifth part of this series will focus on the wide range of useful auxiliaries that are available. OT

(Editorial note: A complete list of references is available from the publisher. This article first appeared in Dental Tribune Asia Pacific, Vol. 7, No. 5, 2009. The next edition of Ortho Tribune will feature "Part V — Therapeutic auxiliary elements." All photos were provided by the authors.)

OT Contact

Dr. Björn Ludwig
Am Bahnhof 54
56841 Traben-Trarbach
Germany
Phone: +49 (654) 181-8381
Fax: +49 (654) 181-8394
E-mail:
bludwig@kieferorthopaedie-mosel.de

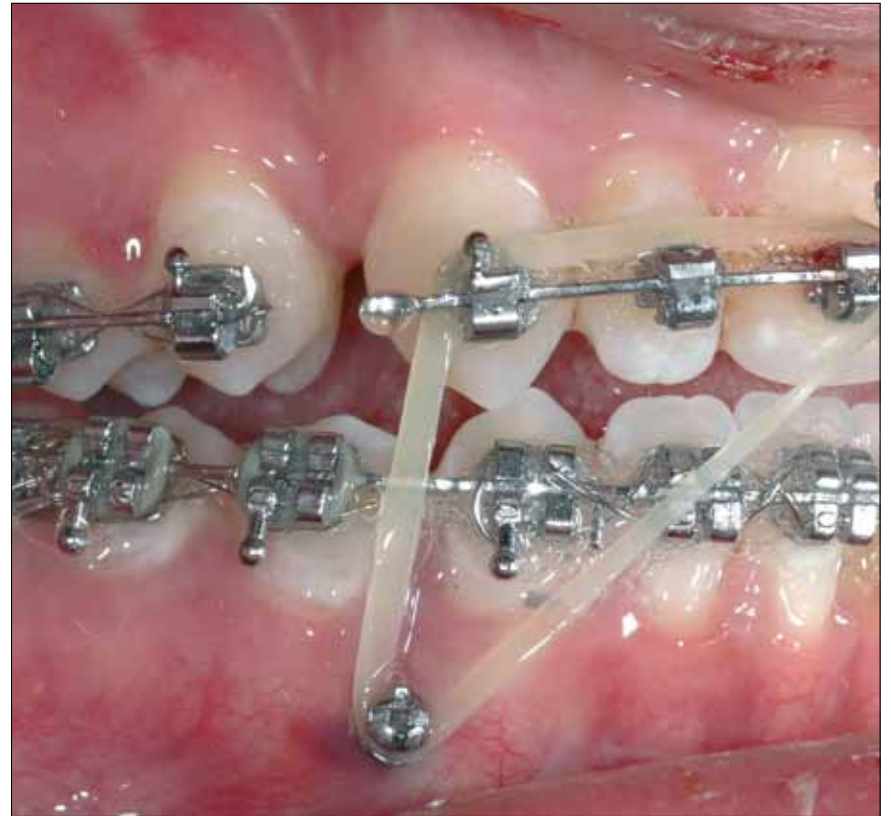

Fig. 9: The use of miniscrews to attach intermaxillary rubber traction bands means that no other attachments to the teeth are necessary.

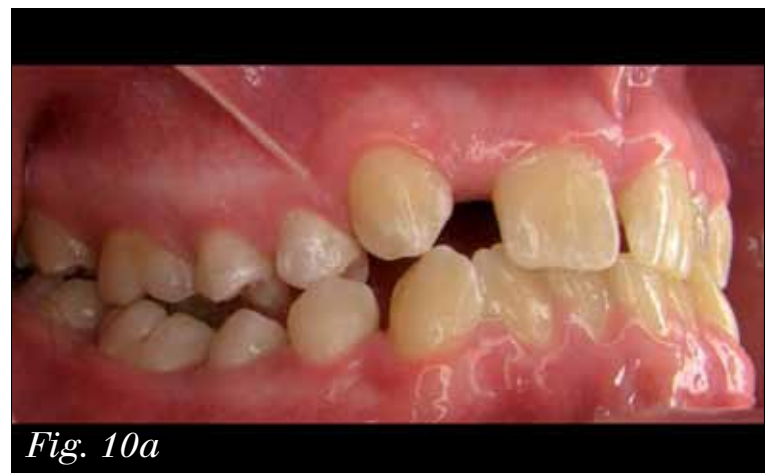

Fig. 10a

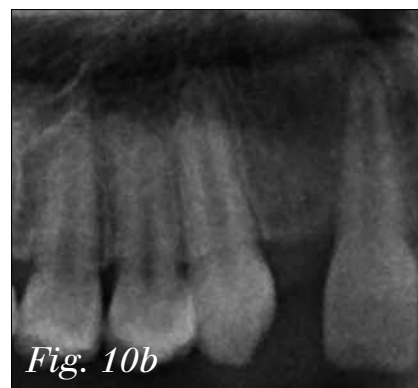


Fig. 10b

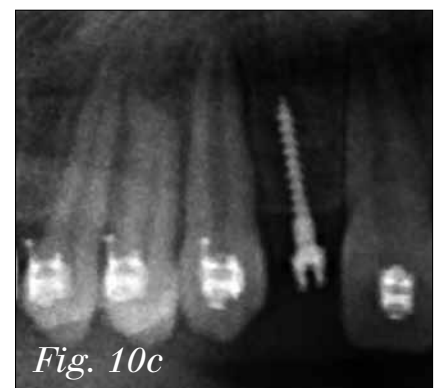


Fig. 10c

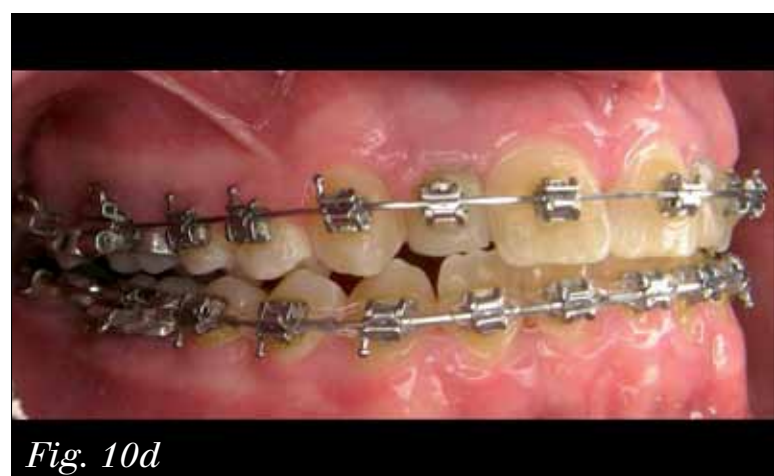

Fig. 10d

Figs. 10a–d: Missing tooth #12 is to be replaced by an implant-based crown. The initial phase of treatment involves widening the gap (a). The head of the vertically inserted OrthoEasy screw (b,c) is used to anchor a provisional crown (including bracket), which serves to widen the gap further (d).

**Send
us your
case
study!**

Have an interesting ortho case you would like to share with your peers? To have your case study considered for publication in Ortho Tribune, send your 800- to 1,200-word case study and up to 12 high-resolution photos to Managing Editor Kristine Colker at k.colker@dental-tribune.com. Authors will be notified of publication and have an opportunity to review the designed case study prior to final publication. Cases will be published pending editor approval and space availability.

Proven strategies for ortho growth

By Roger P. Levin, DDS

Declines in ortho production are still a reality for many orthodontists across the country. Research from a first quarter ADA 2010 survey shows 44 percent of orthodontists reporting lower net income, 37 percent reporting lower gross billings and 41 percent with lower numbers of new patients.

These results should come as no surprise to orthodontists.

From the patients' perspective, orthodontics is increasingly viewed as a commodity. Competition increases every day. Recent advances, such as Invisalign®, have increased competition even more. There is no evidence to suggest this scenario will change anytime soon.

Yet, despite all of these potential obstacles, Levin Group ortho practices continue to grow by:

- Encouraging patient referrals through superior customer service,
- Turning occasional referring dentists into frequent referring dentists.

What is superior customer service?

The ortho practice needs to make

certain it provides truly excellent customer service to ensure patients or parents would find it odd to even consider going elsewhere when another family member needs ortho treatment.

“WOWing” your patients requires having the right systems in place. To do so, you should follow these steps:

- Establish operating procedures for customer service that every patient will experience.
- Survey your patients regularly to determine their satisfaction levels.
- Ask your referring dentists how they view customer service in your practice.
- Develop a system to handle any patient/parent concerns or complaints quickly and in a manner that achieves total patient satisfaction.

How do occasional referrers become frequent referrers?

Every ortho practice has one or two top referrers who contribute the bulk of referrals. However, if you lose one of these referring dentists, an extraordinary amount of revenue — possibly hundreds of thousands of dollars over time — could be lost.

Diversifying your referral sources begins by:

- Determining who refers
- Analyzing how many patients each of them refers
- Customizing marketing strategies to effectively get GPs to refer more patients
- Subsequently tracking each strategy for effectiveness and then making adjustments as needed

An effective referral marketing program will foster better relationships, generate more referrals and subsequently reduce or reverse the noticeable declines many orthodontists have experienced.

Conclusion

Now is not the time to adopt diminished expectations. Remember that ortho practices have incredible potential. By upgrading your customer service and referral marketing systems, ortho practices can grow exponentially.

To jumpstart practice growth, experience Dr. Roger Levin's next Total Ortho Success™ Seminar from Oct. 28–29 in Orlando. Ortho Tribune readers are entitled to receive a 20 percent courtesy. To receive this, call

OT About the author



Dr. Roger P. Levin is chairman and chief executive officer of Levin Group, the leading orthodontic practice management firm. Levin Group provides Total Ortho Success™, the premier comprehensive consulting solution for lifetime success to orthodontists in the United States and around the world. Levin Group may be reached at (888) 973-0000 and customerservice@levingroup.com.

(888) 973-0000 and mention “Ortho Tribune” or e-mail customerservice@levingroup.com with “Ortho Tribune Courtesy” in the subject line. OT

AD



ANNUAL DENTAL TRIBUNE STUDY CLUB
SYMPOSIA AT THE GNYDM
NOVEMBER 28 – DECEMBER 1, 2010, 10:00 AM DAILY



For the third year in a row, the DTSC hosts its annual CE Symposia at the GNYDM, offering four days of focused lectures in various areas of dentistry.

REGISTER NOW: WWW.GNYDM.COM

FREE ENTRANCE
EARN 20 C.E. CREDITS
20h CE

28 NOV

10:00 - 11:00 Dr. Howard Glazer, DDS, FAGD
BEAUTIFIL: GO WITH THE FLOW

11:20 - 12:20 Dr. John Flucke, DDS
LIGHT CURED ADHESIVE DENTISTRY - SCIENCE AND SUBSTANCE

1:20 - 2:20 Dr. Martin Goldstein, DMD
A SIMPLIFIED APPROACH TO MULTI-LAYER DIRECT COMPOSITE BONDING

2:40 - 3:40 Dr. Marius Steigmann, DMD
MY FIRST ESTHETIC IMPLANT CASE - WHY, HOW, & WHEN?

4:00 - 5:00 Dr. Louis Malcmacher, DDS, MAGD
TOTAL FACIAL ESTHETICS FOR EVERY DENTAL PRACTICE

29 NOV

10:00 - 11:00 Mrs. Noel Brandon-Kelsch
ECO-FRIENDLY INFECTION CONTROL-UNDERSTANDING THE BALANCE

11:20 - 12:20 Dr. Derek Fine, DMD
CONE BEAM - AWARENESS IN THREE DIMENSIONS

1:20 - 2:20 Various Speakers
OPTIMIZING YOUR PRACTICE WITH 3D CONE-BEAM TECHNOLOGY

2:40 - 3:40 Dr. Daniel McEwen, DDS
HIGH RESOLUTION CONE BEAM WITH PREXION 3D

4:00 - 5:00 Dr. Maria Ryan, DDS, PhD
DETECTING CORONARY HEART THROUGH PERIODONTITIS AND PERIIMPLANTITIS

30 NOV

10:00 - 11:00 Dr. Fotinos Panagakos
DENTIN HYPERSENSITIVITY - NEW MANAGEMENT APPROACHES

11:20 - 12:20 Dr. Jay Reznick, DMD, MD
3D IMAGING AND CT-GUIDED DENTAL IMPLANT SURGERY

1:20 - 2:20 Dr. Dov Almog, DMD
INTRODUCTION TO CONE BEAM CT (CBCT), ESPECIALLY AS IT PERTAINS TO PREVENTION OF FAILURES IN ORAL IMPLANTOLOGY

2:30 - 3:30 Dr. Maria Ryan, DDS, PhD
DETECTING CORONARY HEART THROUGH PERIODONTITIS AND PERIIMPLANTITIS

4:00 - 5:00 Dr. Dwayne Karateew, DDS
CONTEMPORARY CONCEPTS IN TOOTH RELACEMENT: PARADIGM SHIFT

1 DEC

10:00 - 11:00 Mr. Al Dube
MERCURY AMALGAM WASTE AND OSHA AND REGULATORY ISSUES AFFECTING DENTISTS

11:20 - 12:20 Dr. Glenn van As
AN INTRODUCTION TO DIODE LASERS: TOP 10 PROCEDURES YOU CAN DO WITH YOUR DIODE LASER

1:00 - 4:30 Various Speakers
REVOLUTIONARY IMPLANT DESIGN UNVEILED

PLEASE SEE FURTHER PROGRAM AND SPEAKER DETAILS UNDER WWW.DTSTUDYCLUB.COM/GNYDM

