

	<b>IMPLANT TRIBUNE</b> The World's Implant Newspaper · U.S. Edition	<b>LAB TRIBUNE</b> The World's Dental Lab Newspaper · U.S. Edition
<b>Composite solutions</b> Composites for posterior teeth are something many tend to avoid. <a href="#">▶ page 6A</a>	<b>AO scrapbook</b> Check out scenes from the Academy of Osseointegration meeting. <a href="#">▶ page 1B</a>	<b>Comparing systems</b> Clinical laboratory evaluation looks at CAD/CAM equipment. <a href="#">▶ page 1C</a>

## New pathogen contributes to ECC

Researchers at The Forsyth Institute have made a significant discovery about the nature of childhood dental disease. The scientific studies led by Anne Tanner, BDS, PhD, identified a new pathogen connected to severe early childhood caries.

This bacterium, *Scardovia wiggsiae*, was present in the mouths of children with severe early childhood caries (ECC) when other known pathogens such as *Streptococcus mutans* were not detected. This research may offer the potential to intervene and halt the progression of disease.

Early childhood caries is the most common chronic infectious disease of childhood in the United States. Severe ECC can destroy primary teeth, cause painful abscesses and is the major reason for hospital visits for young children. This condition disproportionately affects disadvantaged socio-economic groups.

This research, which will be published in the April issue of the Journal of Clinical Microbiology, provides new insight on the microbiota of severe ECC. Dental caries is caused by an interaction between bacteria, host susceptibility and a carbohydrate diet that contains high amounts of sugar.

Tanner published an updated evaluation of the diet associated with severe ECC in collaboration with Dr. Carole Palmer at Tufts University in the Journal of Dental Research in 2010.

The bacterial species *S. mutans*



Early childhood caries, ECC, is the most common chronic infectious disease of childhood in the United States. (Photo/Sonyae, www.dreamstime.com)

is widely recognized as the primary pathogen in early childhood caries. However, it is also present in people without disease and is not detected in all cases of childhood caries. This suggests that other species such as *S. wiggsiae* are also disease-causing pathogens.

"In my work, I have seen the tremendous public health impact of severe early childhood caries," said Tanner, a senior member of staff in the department of molecular genetics at The Forsyth Institute. "Understanding the causes of severe dental decay in young children is the first step in identifying an effective cure."

### Summary of study

Severe early childhood caries, while strongly associated with *S. mutans*

[→ DT](#) page 2A

## Dentistry in a 'capital' way



There is plenty of opportunity to increase your dental knowledge in Washington, D.C., as the Nation's Capital Dental Meeting gets under way on March 31 and runs through April 2. We've got a few hints about the meeting as well as some off-the-beaten-path options when you want to step out of the convention center. (Photo/KC Photo, www.dreamstime.com)

[→ See page 4A](#)

## Ancient teeth raise new questions

By Gail Glover, Binghamton University

Eight small teeth found in an Israeli cave raise big questions about the earliest existence of humans and where we may have originated, Binghamton University anthropologist Rolf Quam says.

Quam is part of an international team of researchers, led by Israel Hershovitz of Tel Aviv University, that has examined the dental dis-

covery and recently published joint findings in the American Journal of Physical Anthropology.

Excavated at Qesem cave, a prehistoric site near Rosh Haain in central Israel that was uncovered in 2000, the teeth are similar in size and shape to those of modern man, *Homo sapiens*, which have been found at other sites in Israel, such as

[→ DT](#) page 5A

Dental Tribune America  
116 West 23rd Street  
Suite #500  
New York, N.Y. 10011

PRSRRT STD  
U.S. Postage  
PAID  
Permit #764  
South Florida, FL

**IT'S GREAT TO BE ON TOP ...**



**89% fillers by weight:**

- Outstanding wear resistance
- Enhanced color stability

**30-50% less resin compared to classic hybrid and pseudo nano composites:**

- Low shrinkage of only 1.6 vol.%
- Non-sticky
- Prolonged working time under ambient light

**Designer Nano particles:**

- Excellent polishability and polish retention
- Tooth-like modulus of elasticity
- Tooth-like thermal expansion and flexural strength

**... WITH THE MOST TOOTH-LIKE COMPOSITE EVER!**

REF 2646 Trial Kit 8 X 0.25 Caps (2 X A1, 2 X A2, 2 X A3, 2 X A3.25)  
1 X 1g GrandISO Heavy Flow syringe A2, 1 X Diamo Polisher

**TRY GRANDISO NOW FOR JUST \$58**

**GrandISO**  
89% filled universal Nano Hybrid Composite  
The Combination of handling, esthetics and performance.

**VOCO**  
THE DENTALISTS

Call 1-888-658-2584 · www.vocoamerica.com

AD

# BMP improves implant success

By Paula Hinely, Georgia Health Sciences University

Using a bone-creating protein to augment the maxillary sinus could improve dental implant success, according to Georgia Health Sciences University (GHSU) researchers.

Dental implants won't work if the bone in which they are anchored is too thin. Bone-thinning is a common cause and consequence following tooth loss.

The currently favored solution is to supplement the area with bone grafts to stabilize the implant base. But that technique is problematic "primarily because it involves additional surgeries to harvest the bone," said Dr. Ulf M.E. Wikesjö, interim associate dean for research and enterprise in the GHSU College of Dental Medicine.


In animal studies, he and his team at the GHSU Laboratory for Applied Periodontal and Craniofacial Regeneration found that when implanting bone morphogenetic

protein (BMP) in the sinus, more new bone will form within four weeks than using conventional bone grafting at the same site.

"We found that BMP induced superior bone quality over that following bone grafts, which improves the chances for successful implants," Wikesjö said. "BMP is phenomenal, because it's a true, off-the-shelf product with ease of use that can produce real results, and it could be the new gold standard for this procedure."

According to the American Association of Oral and Maxillofacial Surgeons, 69 percent of adults ages 35-44 have lost at least one tooth due to decay, disease or trauma, and 26 percent of adults have lost all permanent teeth by age 74.

Before dental implants were available, the only options for replacing these missing teeth were dentures and dental bridges, both of which could lead to further bone loss. Implants provide patients with numerous benefits, including improved oral health, appearance,



Dr. Ulf M.E. Wikesjö, interim associate dean for research and enterprise in the Georgia Health Sciences University College of Dental Medicine (Photo/Georgia Health Sciences University)

speech, convenience, durability and the ability to eat.

The findings of his team's pilot study were presented at the Academy of Osseointegration annual meeting in Washington, D.C. Wikesjö's GHSU co-investigators include Drs. Jaebum Lee, Cristiano Susin, Nancy Rodriguez and Jamie de Stefano. [DT](#)

← [DT](#) page 1A

using selective detection methods (culture, PCR), has also been associated with other bacteria using molecular cloning approaches. The aim of this study was to evaluate the microbiota of severe ECC using anaerobic culture.

The microbial composition of dental plaque from 42 severe ECC children was compared with that of caries-free children. Bacterial samples were cultured anaerobically on blood and acid (pH 5) agars. Isolates were purified and partial sequences for the 16S rRNA gene were obtained from 5,608 isolates.

Sequence-based analysis of the 16S rRNA isolate libraries from blood and acid agars of severe ECC and caries-free children had more than 90 percent population coverage with greater diversity in the blood isolate library. Isolate sequences were

compared with taxa sequences in the Human Oral Microbiome Database (HOMD) and 198 HOMD taxa were identified, including 45 previously uncultivated taxa, 29 extended HOMD taxa and 45 potential novel groups.

The major species associated with severe ECC included *S. mutans*, *S. wiggsiae*, *Veillonella parvula*, *Streptococcus cristatus* and *Actinomyces gerencseriae*. *S. wiggsiae* was significantly associated in children with severe ECC in the presence and absence of *S. mutans*.

Tanner and her team conclude that anaerobic culture detected as wide a diversity of species in ECC as observed using cloning approaches.

Culture coupled with 16S rRNA identification identified more than 74 isolates for human oral taxa without previously cultivated representatives. The major caries-associated species were *S. mutans* and *S. wiggsiae*, the

latter of which is a candidate as a newly recognized caries pathogen.

This study was conducted with collaborators at the Goldman School of Dental Medicine, Boston University and Tufts University School of Dental Medicine, and with Dr. Floyd Dewhirst and resources of the HOMD at The Forsyth Institute.

The HOMD links several types of information on oral microbes to a consistent naming system. The HOMD contains descriptions of the microbes, their metabolism and their ability to cause disease along with information on their DNA and proteins, as well as to the scientific literature. [DT](#)

## References

- A. C. R. Tanner, J. M. J. Mathney, R. L. Kent, N. I. Chalmers, C. V. Hughes, C. Y. Loo, N. Pradhan, E. Kanasi, J. Hwang, M. A. Dahlan, E. Papadopoulou, F. E. Dewhirst. Cultivable Anaerobic Microbiota of Severe Early Childhood Caries. *Journal of Clinical Microbiology*, 2011; DOI: 10.1128/JCM.02427-10.
- C. A. Palmer, R. Kent, C. Y. Loo, C. V. Hughes, E. Stutius, N. Pradhan, M. Dahlan, E. Kanasi, S. S. Arevalo Vasquez, A. C. R. Tanner. Diet and Caries-associated Bacteria in Severe Early Childhood Caries. *Journal of Dental Research*, 2010; 89 (11): 1224 DOI: 10.1177/0022034510376543.

(Source: The Forsyth Institute)

## DENTAL TRIBUNE

The World's Dental Newspaper - US Edition

### Publisher & Chairman

Torsten Oemus  
t.oemus@dental-tribune.com

### Chief Operating Officer

Eric Seid  
e.seid@dental-tribune.com

### Group Editor & Designer

Robin Goodman  
r.goodman@dental-tribune.com

### Editor in Chief Dental Tribune

Dr. David L. Hoexter  
d.hoexter@dental-tribune.com

### Managing Editor/Designer

Implant, Endo & Lab Tribunes  
Sierra Rendon  
s.rendon@dental-tribune.com

### Managing Editor/Designer

Ortho Tribune & Show Dailies  
Kristine Colker  
k.colker@dental-tribune.com

### Online Editor

Fred Michmershuizen  
f.michmershuizen@dental-tribune.com

### Product & Account Manager

Mark Eisen  
m.eisen@dental-tribune.com

### Marketing Manager

Anna Wlodarczyk  
a.wlodarczyk@dental-tribune.com

### Sales & Marketing Assistant

Lorrie Young  
l.young@dental-tribune.com

### C.E. Manager

Julia E. Wehkamp  
j.wehkamp@dental-tribune.com

### C.E. International Sales Manager

Christiane Ferret  
c.ferret@dtstudyclub.com

Dental Tribune America, LLC  
116 West 25rd Street, Suite 500  
New York, NY 10011  
Tel.: (212) 244-7181  
Fax: (212) 244-7185

Published by Dental Tribune America  
© 2011 Dental Tribune America, LLC  
All rights reserved.

Dental Tribune strives to maintain the utmost accuracy in its news and clinical reports. If you find a factual error or content that requires clarification, please contact Group Editor Robin Goodman at r.goodman@dental-tribune.com.

Dental Tribune cannot assume responsibility for the validity of product claims or for typographical errors. The publisher also does not assume responsibility for product names or statements made by advertisers. Opinions expressed by authors are their own and may not reflect those of Dental Tribune America.

## Editorial Board

Dr. Joel Berg  
Dr. L. Stephen Buchanan  
Dr. Arnaldo Castellucci  
Dr. Gordon Christensen  
Dr. Rella Christensen  
Dr. William Dickerson  
Hugh Doherty  
Dr. James Doundoulakis  
Dr. David Garber  
Dr. Fay Goldstep  
Dr. Howard Glazer  
Dr. Harold Heymann  
Dr. Karl Leinfelder  
Dr. Roger Levin  
Dr. Carl E. Misch  
Dr. Dan Nathanson  
Dr. Chester Redhead  
Dr. Irwin Smigel  
Dr. Jon Suzuki  
Dr. Dennis Tartakow  
Dr. Dan Ward

## Tell us what you think!

Do you have general comments or criticism you would like to share? Is there a particular topic you would like to see more articles about? Let us know by e-mailing us at [feedback@dental-tribune.com](mailto:feedback@dental-tribune.com). If you would like to make any change to your subscription (name, address or to opt out) please send us an e-mail at [database@dental-tribune.com](mailto:database@dental-tribune.com) and be sure to include which publication you are referring to. Also, please note that subscription changes can take up to 6 weeks to process.

← DT page 1A

Oafzeh and Skhul — but they're a lot older than any previously discovered remains.

"The Qesem teeth come from a time period between 200,000 and 400,000 years ago when human remains from the Middle East are very scarce," Quam says. "We have numerous remains of Neanderthals and *Homo sapiens* from more recent times, that is around 60,000 to 150,000 years ago, but fossils from earlier time periods are rare. So these teeth are providing us with some new information about who the earlier occupants of this region were as well as their potential evolutionary relationships with the later fossils from this same region."

The teeth also present new evidence as to where modern man might have originated. Anthropologists believe that modern humans and Neanderthals shared a common ancestor who lived in Africa more than 700,000 years ago. Some of the descendants of this common ancestor migrated to Europe and developed into Neanderthals. Another group stayed in Africa and evolved into *Homo sapiens*, later migrating out of the continent.

If the remains from Qesem can be linked directly to the *Homo sapiens* species, it could mean that modern man either originated in what is now Israel or may have migrated from Africa far earlier than is now thought.

Quam says the verdict is still out as to which species is represented by these eight teeth, which poses a challenge for any kind of positive identification.

"While a few of the teeth come from the same individual, most of them are isolated specimens," Quam says. "We know for sure that we're dealing with six individuals of differing ages. Two of the teeth are actually deciduous or 'milk' teeth, which means that these individuals were young children. But the problem is that all the teeth are separate so it's been really hard to determine which species we're dealing with."

Quam says that rather than rely on individual features, anthropologists use a combination of characteristics to get an accurate reading on species type. For instance, Neanderthals have relatively large incisors and distinctive molars and premolars, whereas *Homo sapiens'* teeth are smaller with incisors that are straighter along the "lip" side of the face. Sometimes the differences are subtle, but it's these small changes that make having a number of teeth from the same individual that much more important.

Even though Quam and his colleagues don't know for sure which species the teeth belong to, these dental records still tell them a lot about the past.

"Teeth are evolutionarily very conservative structures," Quam says. "And so any differences in their features can provide us with all sorts of interesting information about an

individual. It can tell us what they ate, what their growth and development patterns looked like as well as what their general health was like during their lifetime. They can also tell us about the evolutionary relationships between species, all of which adds to our knowledge of who we are and where we came from."

Excavation continues at the Qesem site under the direction of Avi Gopher and Ran Barkai of Tel Aviv University. The archaeological material already recovered includes abundant stone tools and animal remains, all of which are providing researchers with a picture of daily life and hunting practices of the site's former inhabitants.

"This is a very exciting time for archeological discovery," Quam



Assistant Professor Rolf Quam (above) from the department of anthropology at Binghamton University. At left, a picture of the archaeological dig in Israel. (Photos/ Provided by Binghamton University)

says. "Our hope is that the continuing excavation at the site will result in the discovery of more complex remains, which would help us pinpoint exactly which species we are dealing with."

Quam continues to be in touch with the on-site archeologists and hopes to collaborate in the project if more complete human remains are recovered. ■

AD

**FINALLY, AN INJECTABLE HYBRID RESTORATIVE FOR ALL INDICATIONS**

## BEAUTIFIL Flow Plus

- Indicated in classes I, II, III, IV & V
- Physical properties rival hybrids
- Stackable & sculptable; stays put
- Self-polishing "leveling-effect"
- High radiopacity, beyond enamel

BEAUTIFIL Flow Plus is the next step in the evolution of restorative materials, combining the delivery of a flowable and the strength, durability, and aesthetics equal to or better than leading hybrid composites.

Visit [www.shofu.com](http://www.shofu.com) or call 800.827.4638




**TRIAL OFFER \$99.95**  
**A \$160.00 VALUE!**  
 Order now [www.shofu.com](http://www.shofu.com)  
 Enter code: DTRFP2-11

**F00**  
Zero Flow

Stackable



**F03**  
Low Flow

Self-leveling



Shofu Dental Corporation • San Marcos, CA

# Nation's Capital Meeting

There will be plenty of educational choices at the Washington D.C. Convention center during the Nation's Capital Dental Meeting, including registered clinics, participation clinics and capsule clinics throughout the three days of the event, March 31-April 2.

There are similar offerings on each day as a part of the dental assistant, hygienist and office manager tracks.

Furthermore, Judy Bendit, RDH, and Patti DiGangi, RDH, will lead a three-day hygiene mastery program, titled Creating A Flight Plan. The program days begin at 8 a.m. and run until

4:30 p.m. and every letter in the words Flight Plan stands for one of the topics to be covered in the course.

You may register online for the meeting itself and the hygiene program at [www.dcdental.org](http://www.dcdental.org). On the website, you'll also find assistance when it comes to planning your visit to the Washington metropolitan area.

If you own a smart phone, you can augment your visit to the meeting by downloading the Core-Apps "Follow Me" program. You'll then have the complete on-site program, as well as the option to sign up for real-time

meeting alerts. In addition, you may use the program to not only locate exhibitors using an interactive floor plan, but also to communicate with exhibitors as well.

The Core Apps Follow Me program is a part of the District of Columbia Dental Society's effort to go green. There is an option on the printed registration for you to indicate that you will use the digital program and do not require a printed one.

## Special events

On March 31, there will be wine and

cheese available during the President's Reception in honor of Dr Patrick Grogan, president of the District of Columbia Dental Society in the reception area of Exhibit Hall A. The event, which is from 4:30 to 6 p.m., only requires a badge for admittance.

In addition, from 10 a.m. to 5:30 p.m. every day, you won't want to miss the Wall of Wine in Exhibit Hall A. Paying \$25 will allow you to pull a bottle of wine from the wall, some of which are valued at \$500. Even if you don't get one of the most expensive bottles, you'll still walk away with a bottle of wine that is worth \$25.

All proceeds from the Wall of Wine will benefit the D.C. Dental Society Foundation in its efforts to promote oral health to the local community. The "pulling" of wine bottles from the wall will occur from 11:15 a.m. to 1:30 p.m. every day, so even if you are unable to participate, it might be fun to watch the pulls take place.

## Washington D.C.'s wilder side

If you are looking for things to do outside the convention center that are a little bit off the beaten path, we have a few suggestions.

*National Museum of Crime & Punishment; 575 7th St. NW; (202) 621-5550; [www.crimemuseum.org](http://www.crimemuseum.org)*

Fancy a stroll through a shooting gallery? Alternatively, perhaps attempting to crack open a safe is more your style? Maybe a little computer hacking seems worth a try? Well you can do all this and more at this unique museum. You can even place your hands and head through the pillory and get your picture taken.


*National Museum of Health and Medicine; 6900 Georgia Ave.; (202) 781-2200; [www.nlmh.washingtondc.museum/index.html](http://www.nlmh.washingtondc.museum/index.html)*

Visit this museum before it closes on April 3, which is when it will be moved to Silver Springs, Md. Although it has a rotating collection of exhibits, some of the permanent exhibits are unique as well. For example, it is one of a small number of museums in the United States that actually collects and exhibits human remains.

Thus, the Anatomical Collection includes: anatomical and pathological skeletal specimens; fluid-preserved gross anatomical and pathological specimens; medical research collections that include slides, tissue blocks and documentary materials; as well as miscellaneous materials.

Current exhibits include: Abraham Lincoln, the Final Casualty of the War; Trauma Bay II, Balad, Iraq; Resolved: Advances in Forensic Identification of U.S. War Dead; Battlefield Surgery 101: From the Civil War to Vietnam; To Bind up the Nation's Wounds: Medicine During the Civil War. [D](#)

AD




Take Your Restorations  
to a Whole New Level

## ATTEND

# LVI Smile Design II

The Ultimate Solution for Complex,  
Comprehensive Cases



## Up on Lithium Disilicate?

No? It's a breakthrough material  
bound to increase revenue and the quality of dental restorations.



You can learn about Lithium Disilicate from a leading  
dental technician - **Jurgen Seger** - and take your  
restorations to a whole new level.

**LVI Smile Design II - The Ultimate Solution for Complex,  
Comprehensive Cases**

This course will provide information on the fabrication of multiple preps scenarios that the technician faces daily. Emphasis will be on the perfectly balanced smile design, even when different substructures, thicknesses and materials are used. Solutions on implant constructions, bridges, single crowns, veneers and material selection will be discussed and presented. Areas such as digital photography, technique and skill will be addressed in order to provide a thorough understanding of comprehensive case treatment planning.  
Visit [www.lviglobal.com](http://www.lviglobal.com) for complete instructor and course information.

**June 5-7, 2011 | \$3,695**

FOR MORE INFORMATION AND TO  
REGISTER VISIT  
**WWW.LVIGLOBAL.COM OR**  
**CALL 888.584.3237**

**Recommended Private Education Course**

Academy of General Dentistry  
Approved PACE Program Provider  
PACE  
FAGDMAGD Credit  
6/1/2007 to 5/31/2011

**ADA C-ERP** | Continuing Education Recognition Program  
LVI Global is an ADA CERP Recognized Provider. ADA CERP is a service of the American Dental Association to assist dental professionals in identifying quality providers of continuing dental education. ADA CERP does not approve or endorse individual courses or instructors, nor does it imply acceptance of credit hours by boards of dentistry. LVI Global designates this activity for 25 continuing education credits.

*Jurgen Seger*

# 5<sup>TH</sup> ANNUAL AMERICAN DENTAL IMPLANT ASSOCIATION



# MIAMI

## *Symposium*

The American Dental Implant Association is an organization that encourages collaboration and communication among dental implant professionals. It supports education and research to improve implant techniques and products as well as increase public awareness concerning the benefits of implant dentistry.

This symposium will allow you the opportunity to hear from numerous experienced lecturers on the advancements and cutting edge techniques in implant dentistry of today and the chance to network, exchange information and socialize with colleagues and friends from around the country and the world.



**SEPTEMBER 9-10, 2011**  
**HYATT REGENCY MIAMI**

### FEATURED SPEAKERS



Katya Archambault



Charles Babbush



Sergio Belmonte



Donald Callan



Renzo Casellini



Len Conner



Arun K. Garg



Jack Hahn



William D. Nordquist



Alfred Seban

This event fills up fast, so be sure to reserve your spot soon!

**305-944-9636**

# Nanohybrid composite solutions that patients love

By Bruce LeBlanc, DDS

I graduated from dental school in 1977. At that time, adhesive dental options were just beginning to emerge. Caulk Nuvafil was the first light-cured material in my memory that made an impact in the United States. For the first time in my practice, I was able to create solutions for my patients that minimized the amount of tooth structure to be removed.

Around 1982, Dr. Buddy Mopper pioneered creating artistic durable restorations with direct composites. Meanwhile, Dr. John Kanca made valuable contributions in the understanding of etching and applying bonding agents. The maximizing of durable bond strengths combined with the development of composite resins that mimic teeth in color and strength fueled the explosion of minimally invasive techniques that

we benefit from today.

Options that were not initially possible became routine and preferred. Today, direct composite dentistry remains the most sought after service that I offer in my practice. Patients are drawn to the idea of minimally invasive lifelike restorations that rebuild the strength of the teeth.

Composite resin materials continue to evolve. Adding smaller nanoparticles to strong hybrid formulations improved polishing and handling, and created a new class of hybrids. For the last six years, nanohybrids have been my go-to composite material with my favored brands being Kerr's Premise and Herculite Ultra as well as Cosmedent's Nano.

These materials do not slump, allowing final sculpting to be accomplished with ease. Over the six years I have used them, breakage is not a factor and a higher-retained polish

than hybrids means a more natural looking restoration that retains less plaque, improving longevity and appearance.

With ideal color opacity and blending, I am able to produce restorations that excite my patients, often with only one shade. These materials draw on surrounding tooth color to blend seamlessly. Patients love the material's tooth mimicking appearance.

Observing successful direct composite patient recalls for more than 30 years has allowed me to confidently offer composite restorative options ranging from small edges to full coverage. It is my conviction based on clinical observations that when we use these nanohybrid resin materials in combination with higher performance bonding agents that seal both the enamel and dentin, the result is a restoration that maximizes longevity, minimizes

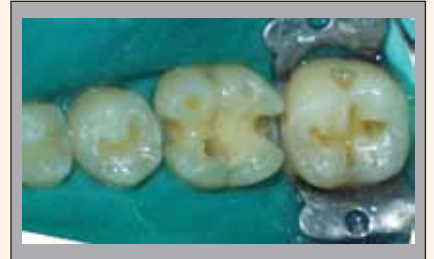

Fig. 1

tooth removal, strengthens the tooth and creates a natural appearance.

However, there is still some reluctance within the profession to implement composite dentistry to restore posterior teeth. Many clinicians express concerns over discolored margins, premature fractures and sensitivity. I would like to address those issues by sharing cases that display why I am enthusiastic about the options I can create for my

AD

MARK YOUR CALENDAR!

**June 9-11, 2011** Orlando, Florida  
Gaylord Palms Resort and Convention Center

## DENTISTRY

### GATEWAY TO GOOD HEALTH



**PLAQUE BUILD-UP**

**DIABETES**

**HYPERTENSION**

**OBESITY**

Emerging science shows the strong connection between oral health and our overall quality of life. This slate of speakers presents innovations and modern techniques to help you lead your patients to good health through exceptional dental care.

Dr. Nassar Barghi  
Dr. Harold Crossley  
Ms. Renee' C. Graham  
Ms. Shirley Gutkowski  
Dr. Randy F. Huffines  
Dr. Gregory M. Lutke  
Dr. Jay Malmquist  
Dr. David L. Meinz  
Dr. Greg L. Psaltis

Dr. Timothy T. Wheeler  
Dr. David T. Wong  
Dr. Raymond A. Yukna  
**and many more!**

FNDC2011

THE OFFICIAL MEETING OF  
THE FLORIDA DENTAL ASSOCIATION

www.floridadentalconvention.com

patients with these materials.

### Case No. 1

The patient is a college student. Radiographic evidence showed lesions were present on the proximals and occlusals of teeth #18, #19 and #20. Minimally invasive direct composite restorations were chosen to maximize tooth retention and longevity.

Proper isolation of the area is essential to prevent contamination of the bonding process and was accomplished with a rubber dam. Decay and defective tooth structure were removed (Fig. 1). My preference for bonding agents remains the rinse-etch systems that maximize enamel etching and cleansing of the entire tooth. In my opinion, proper isolation, cleaning and etching are key building blocks to bonding performance.

In this case, a multi-bottle fourth-generation etch/rinse bonding system was used. Proper application as per manufacturer's instructions and evaporation of the acetone/alcohol component in the primer ensures maximum adhesion and should routinely result in no postoperative sensitivity.

In my opinion, adhesive bonding should solve tooth sensitivity, not cause it. Matrix systems that ensure proper proximal sealing and contour are essential. Kerr Premise nanohybrid composite tooth replacement material was added in layers and properly cured. My favored curing light systems are Kerr Demi and Ultradent's Valo LED lights.

Curing was completed, followed by shaping, polishing and resealing the margins. The post-treatment photo that I have chosen at five years post-op exemplifies why I have confidence in long-term success (Fig. 2). This result is routinely expected with the products and techniques that we use and illustrates that composite resin restorations can be placed with confidence in posterior teeth.

Patients love the natural look and feel as well as the comfort that comes when properly sealing teeth with resin bonding agents and direct composite restorations.

### Case No. 2

Having shown the success of case No. 1, which demonstrates my expected long-term performance of direct composite restorations, I will now show and discuss the replacement of a posterior composite resin that had premature failure. I will offer my observations of what I think may have happened to cause premature failure.

The patient was referred to us with a restoration in her upper left first molar that she said was three to four years old. She was having quite a bit of sensitivity

Photos of her preop condition (Fig. 3) show a large composite restoration that was leaking and failing. Notice that the margins are not sealed and deteriorating along the enamel. I believe that either contamination of the tooth and/or using a bonding agent that did not properly

etch the enamel resulted in a restoration that did not properly seal the tooth.

When we removed the restoration, a large chunk easily flaked out, indicating that adhesion was not present (Fig. 4). Notice the severe decay under the composite and the layer of glass ionomer that had been placed to prevent leakage, decay and sensitivity. Further removal of unsound tooth left minimal tooth remaining for restoration (Fig. 5).

At this point, I would ask you to consider, what options should be considered to solve the problem we faced? I felt I had three options to offer the patient.

One choice was to do a root canal and crown build up from within the tooth and do a crown overlay. I considered that to be a good treatment, but cost compared to the potential longevity for the patient did not make it worth the risk.

Secondly, I considered tooth removal, placement of an implant and a crown as a viable option that was more likely to succeed long term than the endo crown option. The cost to complete this was not appealing.

The third option, our eventual choice, was a direct composite restoration. The only matrix system that I have used successfully for this extreme tooth condition to surround the tooth and seal at the gingival while staying in place is the Greater Curve matrix band retained in a tofflemire holder. Its bell shape encourages a tight gingival seal and retention as it is tightened.

We completed the technique with an etch/rinse multi-bottle bonding agent. This remains my gold standard for bonding because it optimizes cleaning and etching of the tooth for the most predictable seal and bond. For this case we used Cosmedent Nano as our composite.

The result (Fig. 6) is two weeks post treatment and shows a retained polish with a toothlike appearance and complete sealing of the tooth. This treatment choice was delivered at approximately one-third the cost of a crown and root canal and one-fifth the cost of an implant and crown.

The patient returned for follow up evaluation totally comfortable and excited about the results. If and when it should fail, my advised treatment would then be an implant/crown combination.

In closing, nanohybrid composite technology represents years of refinement and development that have created products that offer maximum versatility and value for the dentist to create a multitude of exciting options that patients love. Although following proper protocol is imperative for success, it is not any more difficult than most other procedures we perform in dentistry.

In the end, there is no procedure I do for my patients on a daily basis that creates more excitement and perceived value than an adhesively bonded nanohybrid composite. My

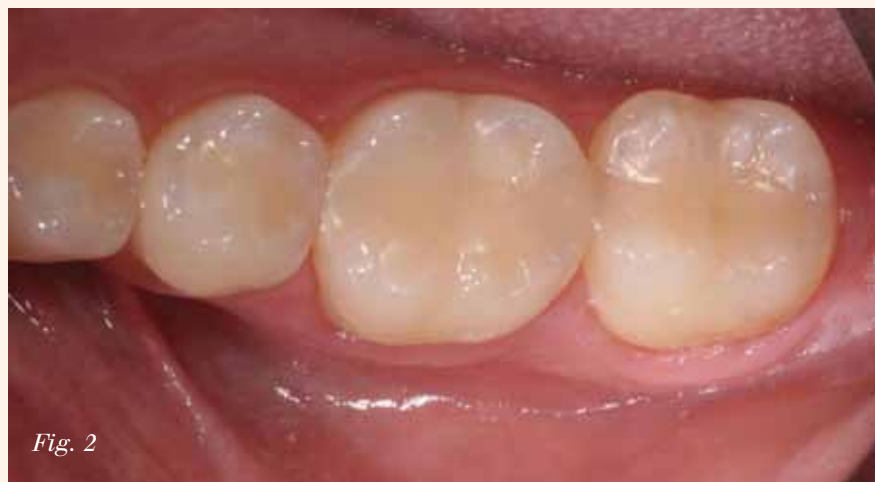

Fig. 2

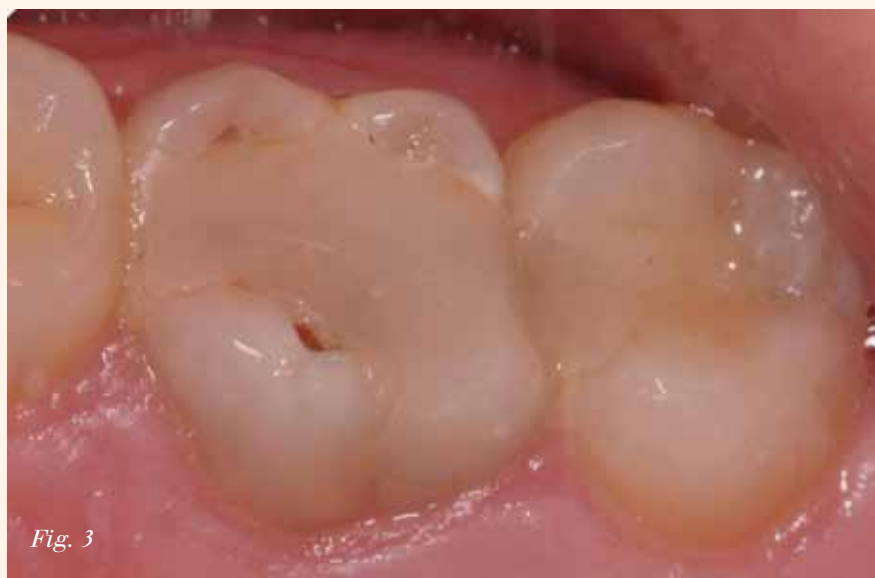

Fig. 3

AD

No Pre-Registration Fee

2011  
87<sup>th</sup> Annual Session

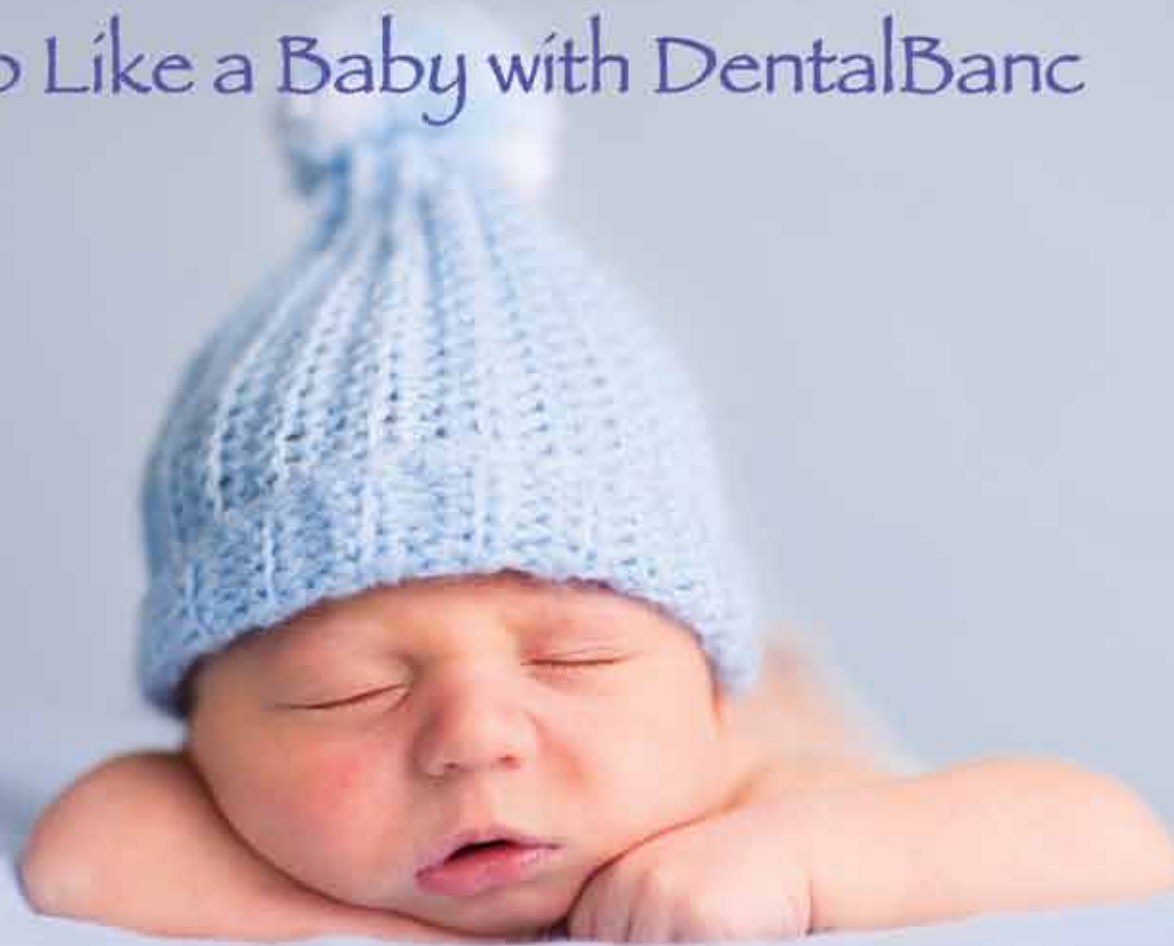Greater New York  
Dental Meeting™

Scientific Meeting:  
Friday, November 25 -  
Wednesday, November 30

Exhibits:  
Sunday, November 27 -  
Wednesday, November 30

The Largest Dental Meeting/Exhibition/Congress in the United States

# Sleep Like a Baby with DentalBanc



## Rest Easy with Our Suite of Payment Management Products

- Identify Risk with Credit Analysis and Payment Plan Recommendations
- Get Paid On Time with ACH Draft and Credit Card Payment Options
- Decrease Staff Work Load with Complete Management of Your Accounts
- Reduce Charged Off Accounts with Credit Bureau Reporting and Collection Services
  - A Great Alternative to 3rd Party Financing
  - eSignature Now Available

Call 888-758-0584 for more information or visit [www.dentalbanc.com](http://www.dentalbanc.com).



DentalBanc



PROFESSIONAL PAYMENT MANAGEMENT



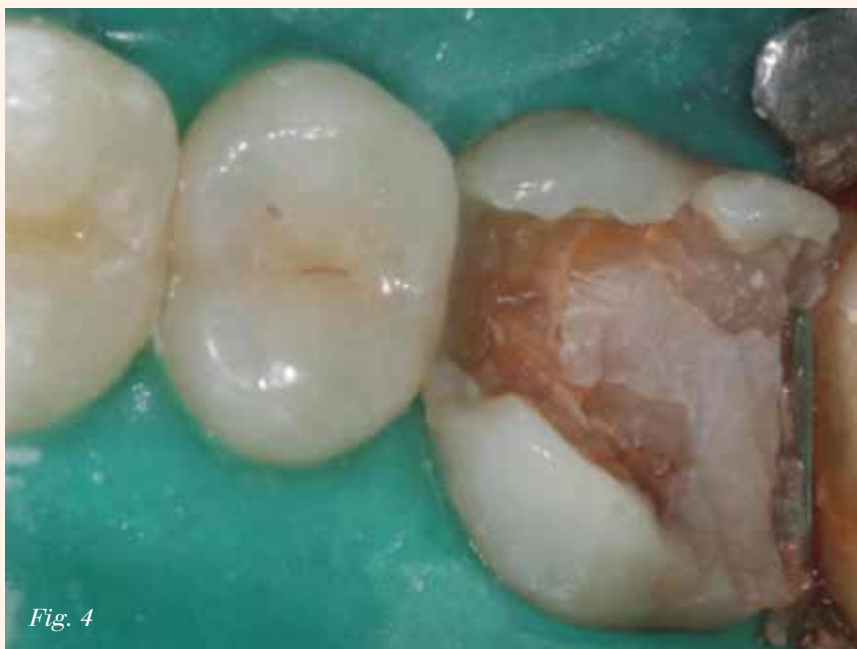

Fig. 4

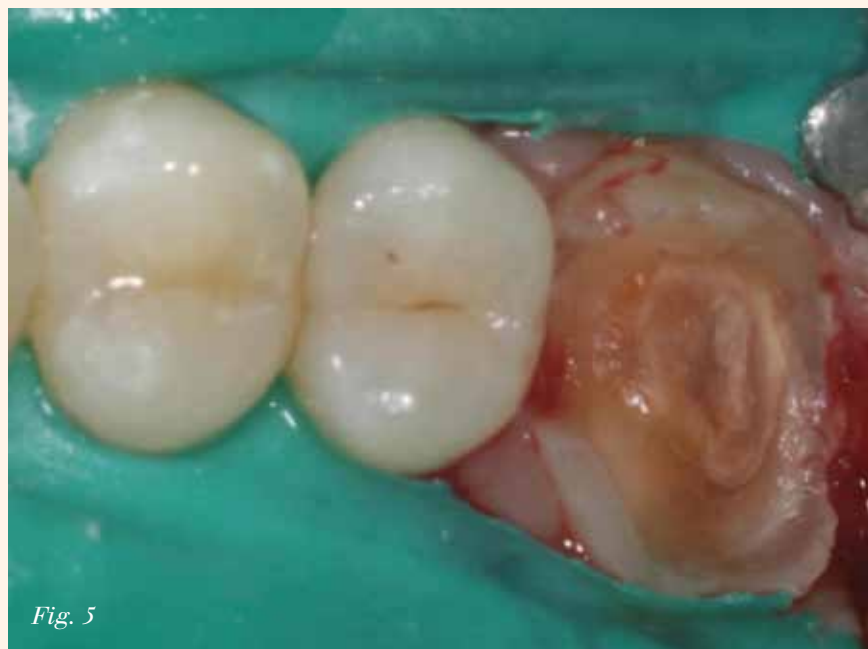

Fig. 5

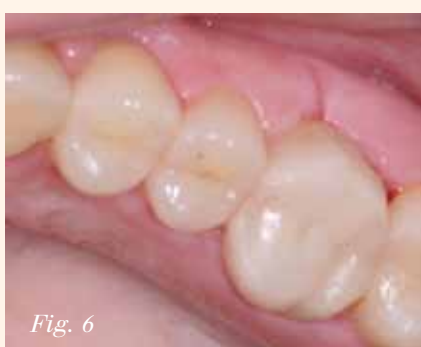

Fig. 6

← DT page 7A

hope is that this will encourage those who may be reluctant to provide this service to explore and enjoy its possibilities. Happy bonding! DT

About the author



Dr. Bruce J. LeBlanc provides seminars nationally on adhesive dental techniques. His practice offers adhesive and cosmetic solutions that minimize tooth removal. He is a product consultant to dental manufacturers and has published internationally on his adhesive technique. He is course director and presenter for “Mastering Posterior Esthetics” at LSU School of Dentistry as well as presenter for the LSU Cosmetic Continuum. He is also the president of the F. Harold Wirth Foundation established at LSU School of Dentistry to enhance the dentist-patient relationship and the enjoyment of practicing dentistry. LeBlanc may be reached via e-mail at [bjleb@cox.net](mailto:bjleb@cox.net).

AD



[EMS-SWISSQUALITY.COM](http://EMS-SWISSQUALITY.COM)

# THE NEW PIEZON

## PIEZON MASTER 700 – THE ORIGINAL PIEZON METHOD IN THE LEAD WITH INTELLIGENT i.PIEZON TECHNOLOGY




> A new brochure – everything about the Original Piezon Method and the new Piezon Master 700

**NO PAIN** for the patient – what the inventor of the Original Piezon Method had in mind when he developed the new Piezon Master 700.

The result is a treatment which irritates neither teeth nor gingiva – and which delivers extra smooth tooth surfaces without abrading the oral epithelium.

It is a symbiosis of intelligent technology and unequalled precision. A perfect match between the Original Piezon LED handpieces and the i.Piezon module for instrument movements perfectly aligned with the tooth. An incomparable fit when used with EMS Swiss Instruments made of ultrafine biocompatible surgical steel.

With its modern touch panel, the new Piezon Master 700 sets new standards for ease of operation and hygiene. Everyone benefits, all feel good – patient, practitioner, the whole practice.

For more information > [welcome@ems-ch.com](mailto:welcome@ems-ch.com)

