

DENTAL TRIBUNE

—The World's Dental Newspaper • Middle East & Africa Edition—

PUBLISHED IN DUBAI

MARCH 2008

No. 2 Vol. 6



Dental School Is Not Business School

► Page 4



TM Disorders: Diagnostic Classification of Temporomandibular Disorders

► Page 6



Hitting first base four key areas for new practice owners

► Page 14

Doctors rally to offer free care for refugees

RAMZI BARNOUTI is a quiet knight for asylum seekers in Sydney, organising free medical care which they cannot afford and the Federal Government does not offer.

The Iraqi specialist has gathered a small team of pro bono doctors to provide GP, specialist and dental services for between 80 and

100 families on the Red Cross Asylum Seeker Program who do not meet government benefits criteria. He wants drug companies and laboratories to come on board too.

Dr Barnouti, 70, a retired urologist who migrated in December 2005 but was unable to practise here, approached the Red Cross in 2006 and they developed the pro

bono scheme together. "I chose refugees because these are people who need help very much," he said.

"I said 'just call doctors and they will agree, anywhere in the world, 99 per cent will say yes'."

→ [DT](#) page 2

Yogurt May Chase Away Bad Breath

If you've tried mints, mouthwash and toothpaste but your breath still offends, maybe you should skip the oral hygiene aisle. Next time, try the dairy case.

In a small study, Japanese researchers have found that eating traditional, sugarless yogurt reduces the malodorous compounds that cause bad breath. It also cuts down on plaque and gingivitis, they discovered.

The study, funded in part by a major Japanese yogurt maker, was presented March 10 at the International Association for Dental Research annual meeting, in Baltimore.

Halitosis, or bad breath, is caused by anaerobic bacteria that breed on the back of the tongue, producing volatile sulfur compounds. One of those compounds, hydrogen sulfide, is the stuff that causes your breath to smell like rotten eggs.

Lead author Kenichi Hojo and colleagues from Tsurumi University in Yokohama, Japan, decided to investigate yogurt because of its effects in preventing

gastrointestinal problems and research indicating that regular yogurt consumption reduces the risk of dental decay.

"We are thinking that yogurt must be good for oral health, also," said study co-author Nobuko Maeda, a professor of microbiology at the university.

Researchers recruited 24 volunteers. Each person received identical instructions for oral hygiene, diet and medication intake. In the initial phase of the study, participants were asked not to consume yogurt or products containing streptococci and lactobacilli, such as cheese and

→ [DT](#) page 2

Tooth troubles could raise dementia risk

Fewer teeth in old age linked to mental woes, study finds

Tooth loss and mouth illnesses may boost the risk of dementia later in life, U.S. research shows.

Of participants "who did not have dementia at the first examination (of annual exams over a 12-year period), those with few teeth -- zero to nine -- had an increased

risk of developing dementia during the study, compared with those who had 10 or more teeth. The team offered several possible reasons for this association, including periodontal disease, early-life nutritional deficiencies, and infections or chronic diseases that may result simultaneously in tooth loss and brain damage.

Further research is needed to confirm whether there is a direct link between tooth loss and increased risk of dementia, the researchers said.

"It is not clear from our findings whether the association is causal or casual," they wrote. [DT](#)

UAE requires dentists to hire nurses

Private sector dentists in the UAE without a technician or a nurse will be barred from renewing their licence under a new policy set by the Ministry of Health, reported Khaleej Times. Dr Ibrahim Ali Al Qadi, Director of the Private Medical Practice Department at the MoH, said dentists have until April 30, 2008. [DT](#)

AD

PROMEDICA

Highest quality made in Germany

- high quality glass ionomer cements
- first class composites
- innovative compomers
- modern bonding systems
- materials for long-term prophylaxis
- temporary solutions
- bleaching products...

All our products convince by

- excellent physical properties
- perfect aesthetical results



Light-curing temporary filling material

- fast to place, easy to remove
- no risk of damaging the preparation



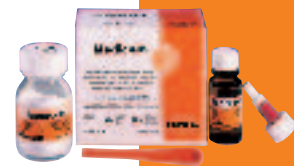Glass ionomer filling cement

- perfect packable consistency
- excellent durable aesthetics
- also available as handmix version



Light-curing universal one-component bonding

- now in practical and hygienic Single Dose
- fast and easy application without spilling



Glass ionomer luting cement

- very low film thickness
- perfect occlusal accuracy



Glass ceramic micro-hybrid composite

- highly resistant long-lasting restorations
- perfectly invisible fillings

PROMEDICA

PROMEDICA Dental Material GmbH

Tel. +49 43 21 / 54173 · Fax +49 43 21 / 51908

Internet: <http://www.promedica.de> · eMail: info@promedica.de

Popular Energy Drinks Cause Tooth Erosion

For more than 10 years, energy drinks in the United States have been on the rise, promising consumers more "oomph" in their day. In fact, it is estimated that the energy drink market will hit \$10 billion by 2010. While that may be great news for energy drink companies, it could mean a different story for the oral health of consumers who sometimes rely daily on these drinks for that extra boost.

Previous scientific research findings have helped to warn consumers that the pH (potential of hydrogen) levels in beverages such as soda could lead to tooth erosion, the breakdown of tooth structure caused by the effect of acid on the teeth that leads to decay. The studies revealed that, whether diet or regular, ice tea or root beer, the acidity level in popular beverages that consumers drink every day contributes to the erosion of enamel.

However, in a recent study that appears in the November/December 2007 issue of General Dentistry, the Academy of General Dentistry's (AGD) clinical, peer reviewed journal, the pH level of soft drinks isn't the only factor that causes dental erosion. A beverage's "buffering capacity," or the ability to neutralize acid, plays a significant

role in the cause of dental erosion.

The study examined the acidity levels of five popular beverages on the market. The results proved that popular "high energy" and sports drinks had the highest mean buffering capacity, resulting in the strongest potential for erosion of enamel.

According to the study, the popularity of energy drinks is on the rise, especially among adolescents and young adults. Their permanent teeth are more susceptible to attack from the acids found in soft drinks, due to the

porous quality of their immature tooth enamel. As a result, there is high potential for erosion among this age demographic to increase.

In fact, Raymond Martin, DDS, MAGD, AGD spokesperson, says he treats more patients in their teens to 20s for tooth erosion. "They drink a great deal more sodas, sports drinks, and energy drinks," he says. "The results, if not treated early and if extensive, can lead to very severe dental issues that would require full mouth rehabilitation to correct," says Dr. Martin. [DT](#)



Health and physical awareness at Dubai Women's College

Dubai Women's College organized a three-day program focusing on health and physical awareness issues through which students, faculty members, and staff participated in a variety of sports and attended workshops and lectures.

The program included Sports Days organized by the Health and Fitness Department at DWC for the students to experience a variety of sport and recreational activities in order to help them develop their teamwork and sportsmanship skills.

For three consecutive days, DWC's community participated in four tournaments and eighteen different sports activities each day.

All DWC students participated in a fun run and tug of war events were organized at the beginning and end of the sports days.

Sports offered during the program included Basketball. Tennis, Bocce, Croquet, Volleyball, Table Tennis, Darts/Chess, Soc-

cer, Yoga, Badminton, Mini Golf, Aerobics, indoor Rock Climbing, Swimming, and others.

Several students received medals for winning in the fun run, tug of war, and all tournaments.

DWC strategically integrates sports and activities within its academic curriculum and offers health and fitness activities in order to promote exercise, healthy lifestyle, and wellbeing among its students.

'Students' were able to undertake a wider variety of team or individual sports and recreational pursuits compared to last year. We start with our students from the very basic sports skills since the majority of them have had limited experience to participate in sports and motor skills before.

It is very important for us to make them not only understand, but also feel the significance of exercise in their lives and that is why we organized a wide range of activities so they can select the sport they are most interested in practicing,' noted Suzanne

Trease, Chair of the Health and Fitness Department at DWC.

Several lectures on health issues were also introduced to the students including a skin test by a consultant from Medical Delta Co., a dermatologist consultation from Kaya Skin Clinic, premarital screening counseling, personal Hygiene and Women and sports, and free dental problem consultation. [DT](#)

← [DT](#) page 1

He found his team through the Yellow Pages, sending out 500 letters asking for volunteers to treat asylum seekers unable to obtain medical benefits.

Twenty doctors - GPs and specialists - replied. He sent 600 letters to dentists, and heard back from 16.

"I met a family who have been like this [without access to free medical care] for the last seven years," he said.

Yet Dr Barnouti is not shocked. "When you are there [in Iraq] and see the '91 war you think being seven years here without medical care is nothing. I have seen much worse things."

He was in the United Arab Emirates during the 2003 bombardment of Baghdad.

Dr Dawood Haddad, 47, who practises in Fairfield, was one of the first GPs to sign up for the scheme. "A lot of my patients come from refugee countries," he said. "I know how much suffering they have been through.

"I don't want them to have more suffering by depriving them of very basic health needs. Taking one patient out of 50 without charging is no big deal."

← [DT](#) page 1

pickled vegetables. During the second phase, they consumed 90 grams of yogurt, or a little more than 3 ounces, twice a day for six weeks.

Researchers collected samples from the participants' saliva and tongue coatings, and measured volatile sulfide compound concentrations in the air of people's mouths. Those measures showed that, at six weeks, hydrogen sulfide levels decreased in 80 percent of volunteers who had bad breath. "So we thought two yogurts per day did work for improving (bad breath)," Maeda said.

In addition, plaque and gingivitis was significantly reduced in people with bad breath after the yogurt-intake phase of the study, compared with the initial phase when they did not consume yogurt. However, the authors said there were no noteworthy differences in the number of oral bacteria in the mouths

He has one or two pro bono families on his books at any time.

Nicole Cunningham, the Red Cross's refugee services co-ordinator, said the value of the program was in making health care accessible.

"I am focused on early intervention rather than crisis intervention," she said. "I have met asylum seekers with very advanced stages of cancer and wondered what if we had treated them earlier."

Ms Cunningham said the Red Cross program provided \$140 a month to asylum seekers who did not qualify for government assistance.

She said the most common reason they did not qualify was that they had not applied for asylum within 45 days of arriving in Australia.

Dr Barnouti is getting out the Yellow Pages again, this time to write to pharmaceutical, radiology and pathology companies, because after diagnosis, the patients are unable to pay for the prescription or tests.

"Drug companies will spend \$10,000 on one lunch for doctors, to show them new products," Dr Barnouti said. "They can afford to help."

Dr Haddad backed the campaign. Most of the things needed, such as antibiotics, were not sophisticated, he said. [DT](#)

of people before and after eating yogurt.

Bruce J. Paster, senior staff member in the department of molecular genetics at The Forsythe Institute in Boston, suggested the authors may not have looked for all the bacteria that were present. "Typically, the bacterial microbiota and their end products are the culprits for the bad breath," he said.

"In theory," he added, "their hypotheses may be valid. For example, the odor-causing species may have been replaced by some 'good' species in the yogurt."

Research participants consumed yogurt made especially for the study, Maeda said. As with other yogurts, the starter culture consisted of a combination of Streptococcus thermophilus and Lactobacillus bulgaricus. What differed was the strain of bacteria they used, she said.

The yogurt maker that helped fund the study hopes to make its product commercially available this fall, she added. [DT](#)



DENTAL TRIBUNE
The World's Dental Newspaper - Middle East & Africa Edition

President/CEO *Yasir Allawi*
y.allawi@dental-tribune.ae

Managing editor *Amani Ebrahim*
amani@dental-tribune.ae

Marketing manager *Suzanne Nadir*
suzanne@dental-tribune.ae

Production manager *Husain Alvi*
husain.alvi@dental-tribune.ae

P.O. Box 4475, Dubai, United Arab Emirates,
Tel. +9714-2282928, Fax: +9714-2241024
E-mail: info@dental-tribune.ae

Published by Venus Advertising
in licence of Dental Tribune International GmbH

© 2008, Dental Tribune International GmbH. All rights reserved.

Dental Tribune makes every effort to report clinical information and manufacturer's product news accurately, but cannot assume responsibility for the validity of product claims, or for typographical errors. The publishers also do not assume responsibility for product names or claims, or statements made by advertisers. Opinions expressed by authors are their own and may not reflect those of Dental Tribune International.

Editorial Board

Dr. Abdel Salam Al Askary, Implantology, Egypt
Dr. Talal Al-Harbi, Orthodontist, Qatar
Dr. Mohammed H. Al Jishi, Bahrain

Dr. Abdullah Al-Shammary, Restorative Dentistry, KSA
Dr. Baha Burhan, Maxillo-Facial, UAE
Dr. Mohammad Mohsen Khobyari, Prosthodontics, Iran
Prof. Hussain F. Al Huwaizi, Endodontics, Iraq

Medications Plus Dental Materials May Equal Infection for Diabetic Patients

People who live with diabetes on a daily basis are usually instructed to eat right, maintain regular physical activity, and if necessary, take medication. What many may not know is that these medications that help control healthy insulin levels

may lead to unexpected events at the dentist's office. According to a study in the November/December 2007 issue of General Dentistry, the AGD's clinical, peer-reviewed journal, diabetic patients especially need to communicate special

needs to their dentists. This is due to harmful interactions that could occur because of the materials and medications used at dental appointments.

According to the study, more than 194 million people world-

wide have diabetes, and health officials estimate that this figure will double or triple in less than 20 years. "It is imperative that diabetic patients inform their dentist of their needs in order to anticipate medication interactions and physical reactions to

treatment," says Lee Shackelford, DDS, FAGD, spokesperson for the AGD. "The doctor must know if the patient is taking insulin, and has taken their daily dose of insulin, in order to anticipate the length of the appointment." **DT**

Teen teeth bleaching

Girls and boys alike, from elementary to high school, are bleaching their teeth.

"Kids are under a lot of pressure, as adults are, to look good, to have white teeth," says Dentist Dr. David Carroll.

"White teeth just pretty much make everyone seem more attractive. Even if you have straight teeth and they're yellow they're still not that nice," says Patient Taryn Barg.

Don't be blinded by the white. Dentists warn that children's teeth aren't fully developed. Bleaching can make them overly translucent and trigger tooth and gum sensitivity.

"If I ate certain food it would just kind of tingle and it didn't feel too good," says Barg.

"There could be extreme tooth sensitivity if it's used improperly, if it's kept on the teeth for too long, and if the directions are not followed closely," says Carroll.

That should be a red flag to parents who may not know their child is using a tooth whitener.

"If the child all of a sudden can't drink cold water or can't eat ice cream for some reason that might be an indication that they have started using some of these products," says Carroll.

To avoid problems, kids who want whiter teeth should see a dentist before starting the bleaching process.

"Get a thorough examination, find out why, what is the cause of discoloration of the teeth. There's nothing wrong with over the counter methods if they're done in cooperation with the dentist and if they're supervised by an adult," says Carroll.

Taryn admits she's addicted

"You just like glow kind of, just makes everything about you look nicer," she says. **DT**



If it isn't **clean**, it can't be **sterilised**!
Hydrim and **Statim**, your perfect partners
 in the sterilisation process

Now you can eliminate the risk of hand washing instruments

Authorities now recommend that instruments cannot effectively be sterilised unless they have first been cleaned in a mechanical washer. Across Europe guidelines are under review to reflect this advice.

That's why effective sterilisation begins with the Hydrim® C51wd or M2 instrument washer. After a pre-wash to remove virtually all proteins, two independent, high pressure sprays clean the instrument load from above and below, removing virtually all organic debris. Independent tests show an efficacy of 99.9 – 100 per cent. The Hydrim washers perfectly prepare instruments for sterilisation in as little as 19 minutes, and eliminate the risk of washing instruments by hand.

**Washed and
sterilised in
27 minutes**

Following the Hydrim wash cycle, the instrument basket can immediately be transferred into an S class Statim® autoclave cassette for the fastest sterilisation cycle available. Most instruments, including handpieces can now be sterilised between patients in a Statim 2000 S in only 8 minutes. The fast Statim S cycle process fully complies with the latest European standard EN13060.

The compact Hydrim C51wd and Statim units are designed for benchtop use and are the perfect partnership for the central sterilisation area even in the smallest practice. The floor standing Hydrim M2 can process about 100 instrument sets in a 10 hour day and is ideal for the larger, busy practice.

For further information about SciCan products please contact:

Sub Sahara and Africa – Eric Bernard on **+27 11 486 1622**
 or email **ebernard@global.co.za**

Middle East – Ashraf Suleiman on **+20 12 326 7870** or
 email **asuleiman@scican.com** or visit our website at **www.scican.com**

SciCan
 A HIGHER STANDARD

Dental School Is Not Business School

Are graduates of dental school ready for the reality of practicing dentistry? Four out of 5 dentists don't think so, according to a survey by The Wealthy Dentist, citing a lack of business savvy and little knowledge of dental practice management.

Many feel that dental school must also fill the role of business school. "Dental school needs really good business courses to help students get started in practice, even if they are going into an employment situation," opined a Tennessee dentist.

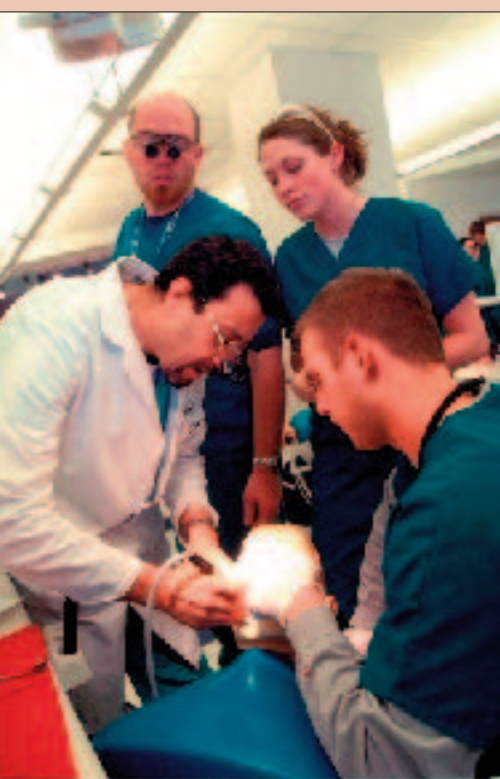Of course, some feel that dental schools provide an excellent education. "Dental school has tried to address issues of practice management, dental insurance issues, and advanced restorative techniques including implants and periodontal surgery," said a Pennsylvania periodontist.

One Michigan dentist reported being disappointed by his young associates. "I have gone through a few associates. I have a high-tech, high-end practice, and I try to show them all the tricks. They are not only clueless, but they don't even try - poor confidence level out of school. They want to make the money

but they don't want to work the hours or try to learn the communication and practical skills that today's public demands... I think that in the future I'm going to charge a training fee!"

"Dental schools might be great, but they're notoriously bad at addressing business

issues," said Jim Du Molin, dental management consultant and founder of The Wealthy Dentist. "Students learn lots of science and very little about practice management. But how can graduates expect to practice dentistry if they can't run a dental practice?" [DT](#)



But is business training really within the scope of dental school? "Today's graduates are not prepared to start a business, but neither were we. Business sense is hard to get in a classroom setting," observed a North Carolina dentist. "It's like preparing for parenting; how do you know when you're ready?"

Though dental technology has advanced rapidly, it's not clear that dental education has followed. "It has not changed enough in at least the last 25 years. Clinically, dental students have just enough knowledge and experience to provide basic care and hopefully will understand that they need to continue to learn and develop their capabilities," wrote an Illinois dentist. "There should be some basic business requirement in the pre-dental education, but I don't see that there is room in dental school to cover this (running a business) in any but the most cursory way."

Doing well in dental school is no guarantee that a student will become a good clinician. "Dental school prepares you for your board exams, not the real world of dentistry," commented a New Jersey dentist. "Academically graduates are over-prepared, and clinically they tend to be under-prepared," agreed a general dentist from Missouri.

OUR TECHNOLOGY – YOUR KNOW-HOW

FKG RaCe NiTi Instruments & SafetyMemoDisc

CANAL TREATMENT IN CONTINUOUS ROTATION. SAFE, SIMPLE AND EFFICIENT!



NON-CUTTING SAFETY TIP

- Perfect control of the instrument
- Steers clear of lateral canals




ALTERNATING CUTTING EDGES

- No threading, nor blocking effect
- Lowest operation torque & reduced working time



SHARP CUTTING EDGES

- Improved efficiency
- Better debris evacuation




EXCLUSIVE ELECTRO-CHEMICAL TREATMENT

- Better resistance to torsion and metal fatigue
- Facilitates cleaning and sterilisation

COMPATIBILITY

Our instruments are suitable for all micro-motors and controller systems



TO COUNT NUMBER OF USES

- SafetyMemoDisc & 8 removable petals
- Curvature gauge & decrement table

FKG
FKG DENTAIRE
Swiss Dental Products



FKG document's ref. - 99.7AA.10.01C.AN

For more information and orders please contact Lunatus Marketing & Consultancy FZCO, Tel: +971 4 340 5991/3 or Email: dental@lunatus-me.com

Dental videos featured on YouTube

Dr Gordon from the US uses popular video sharing website to help patients conquer their fear of the dentist

Claudia Salwiczek
DTI

LEIPZIG: For some patients, a visit to the dentist is a terrifying prospect. It is something they try to avoid under all circumstances. Responsible for this reaction is a gland in the brain called the amygdale, researchers found. At times of perceived potential danger, this almond shaped gland begins to set off a series of reactions that provide the host with the ability to enact a potentially life-saving flight response. Statistics from international studies about the prevalence of dental fear in patients show that 5–15 per cent of the population worldwide are experiencing this extreme fear of the dentist, despite the fact that untreated cavities or chronically infected gums and teeth can seriously affect a person's overall medical status.

Nowadays, specialised dental fear clinics use both psychologists and dentists to help people learn to manage and decrease their fear of dental treatment. The goal of these clinics is to provide individuals with the fear management skills necessary to receive regular dental care with a minimum of fear or anxiety. US dentist Dr Jerry Gordon uses similar strategies. After completing his educational career at Rutgers University and the University of Medicine and Dentistry in New Jersey (UMDNJ) and a general practice residency at The Mount Sinai Medical Center in New York, he meanwhile



Dr Jerry Gordon

runs his own private practice in Bensalem, a 60,000 people township in Pennsylvania.

While conventional anxiety treatment options are standard in his day-to-day practice, Dr Gordon has started to put informative video content on his Web site www.dentalcomfortzone.com in 2006 and on YouTube the following year. The extremely popular video sharing Web site, acquired by Google for US\$1.65 billion in 2006, allows millions of users to upload, view and share video clips worldwide. Dr Gordon's range of videos, produced by Swamp Queen Productions, a local production company, includes topics like painless dentistry and dental fears, as well as clinical videos on root canal, extractions and other procedures like air abrasion or cosmetics. In his opinion, a good Web site can be the deciding factor in whether the patient ultimately

calls the office. "It has been exciting for me to share what I do with people in my own area and around the world," he told Dental Tribune in an exclusive interview.

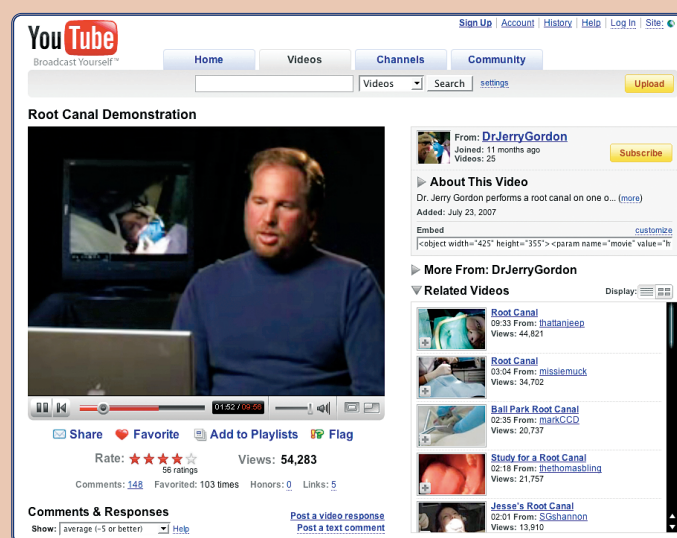With the rise and popularity of reality television shows like *Dr 90210*, *The Swan* or *Extreme Makeover*, people are more open to seeing clinical content in a realistic way. "Not every fearful patient will benefit from watching my clinical videos, but some will. This technique is well known in behavioural psychology, and is called systematic desensitization or graduated exposure therapy,"

Dr Gordon's video marketing has triggered a lot of feedback. Articles about him and his approach were featured in *The New York Times*, the *International Herald Tribune* and the *Boston Globe*. "One patient even travelled from New York City to my office (about 100 miles) for a root canal because she had read about me in *The New York Times* and then watched the video on YouTube."

Reactions from colleagues were mixed. "I got a few dentists, especially some endodontists, that nipped the video a bit. Fellow dentists asked me

After having seen the videos on YouTube, several dentists have also contacted him about other important causes he is working on, like the treatment of retired American Football Players. "Having videos on YouTube can considerably broaden the scope of people who know about your practice, and what you are doing in your community. It is my hope that people can overcome their fear of dentists and dentistry, if only in small part, by watching some of my videos."

Gordon plans to further extend his video marketing in the future. Excerpts of his testimo-

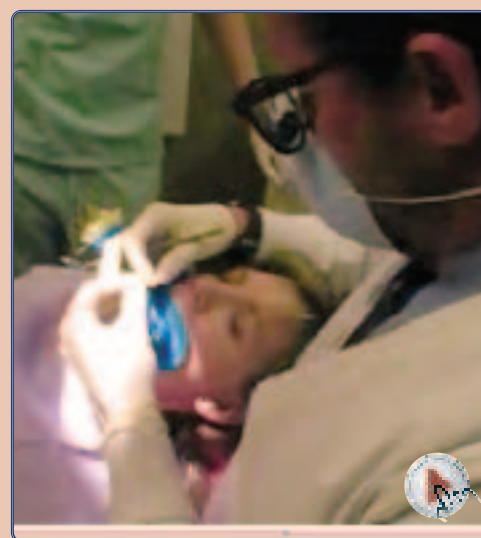


Dr Gordon demonstrates dental procedure on www.youtube.com.

Gordon explains. "When fearful or phobic people watch the video and see instruments and different dental procedures, they can become more familiar and less threatened by the dental environment."

for some tips and liked my technique, so I guess that eases it out. The most gratifying feedback is by apprehensive people who are in need of a root canal and are helped by the video," Gordon states.

nials and clinical videos will be used for TV commercials and radio spots. "We have the capability to have our videos available for news or special interest segments if the need arises," he concludes. **DT**



Arthritis and your Teeth

Having arthritis makes caring for your teeth difficult, but common dental procedures may make matters worse. According to an article in the January/February issue of *Arthritis Today*, recent studies show an increased risk of developing one arthritis-related condition and suffering a serious complication of another.

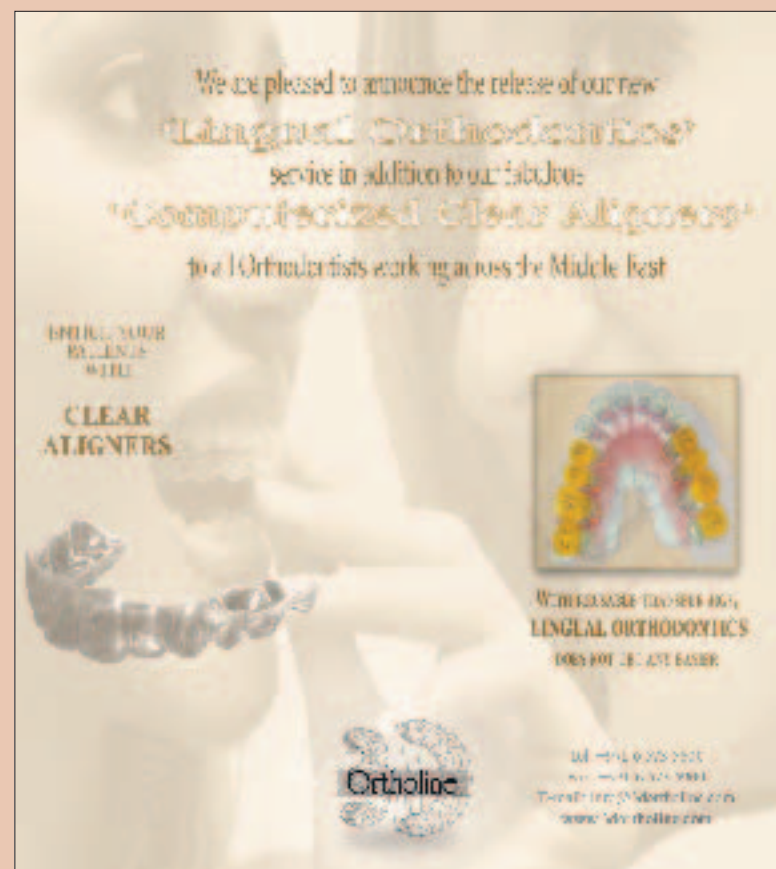Studies found that dental X-rays can trigger Sjogren's syndrome. Sjogren's syndrome is an inflammatory autoimmune disease that causes dryness, especially of the eyes and mouth. In addition to dryness, Sjogren's syndrome can cause problems in other parts of the body including joints, the lungs, kidneys, liver, nerves, thyroid gland and skin. Studies show fewer cases of Sjogren's syndrome in less-developed countries where dental X-rays are uncommon and the disease is not present at all in the



least developed countries. Researchers in the Oklahoma Research Foundation say it raises questions about a link between X-rays and Sjogren's syndrome.

Studies have now shown that the use of bisphosphonates, such as Fosamox or Actonel, for osteoporosis, along with invasive dental work, such as a tooth extraction, may lead to an increased risk of an uncommon but serious complication of osteonecrosis of

the jaw. Osteonecrosis is the break down and eventual collapse of bone resulting from the loss of blood supply to bone tissue. Symptoms may include pain, swelling or infection of the gums or jaw, gums that are not healing, loose teeth, numbness or a feeling of heaviness of the jaw, drainage and exposed bone. Researchers are not sure exactly how bisphosphonates contribute to osteonecrosis of the jaw. **DT**



AD



TM Disorders: Diagnostic Classification of Temporomandibular Disorders

(Part 2 of 3)¹ *Ulises A. Guzman & Henry A. Gremillion, USA*

The head, face, masticatory system, and cervical region are common sites in which pain is experienced. Many conditions present with similar signs and characteristic patterns that may lead to diagnostic confusion and ultimately misdirected care. Defined, validated classification systems relating to the multiplicity of painful entities can simplify and enhance diagnostic outcomes. Due to the rapid advances in our knowledge regarding pain mechanisms and pathways, classification systems must be ever evolving, not rigid. Presently an ideal system related to masticatory system disorders does not exist.

One set of diagnostic criteria will not satisfy all circumstances to which it might be applied. More importantly, many classifications systems were developed for the purpose of enhancing the formation of study populations for clinical research endeavors and are not absolutely applicable to every clinical case presentation.

For example, the inclusion criteria for a clinical trial might require the presence of all criteria for a specific disease, while a clinical diagnosis might require the presence of only a few. These criteria are meant only to provide clinical guidance for diagnosis. Final diagnostic decisions must be based on the clinical judgment of the health care professional. This article will provide the reader with a review of the most accepted diagnostic classification system related to temporomandibular disorder (TMD).

It is generally recognized that two basic categories of TMD exist, extracapsular (myogenous) and intracapsular (arthrogenous). The majority of TMDs are extracapsular in nature; however, it is not uncommon for these two basic categories to co-exist.

Masticatory muscle-related conditions are found to be the most common subgroup of TMD.^{1,2}

The current understanding of the complexity and the dynamic relationship between the masticatory and cervical musculature enables the practitioner to better assess the condition(s) possible etiology(ies). The individual variations and demands placed on the system, as well as normal function while awake or sleep, are true

considerations in our patient evaluation.

Myofascial pain is a regional pain, usually dull and achy with the presence of localized tenderness in firm bands of muscle, tendons and/or fascia that reproduce pain when palpated and may produce a characteristic pattern of regional referred pain and/or autonomic symptoms on provocation.^{3,4} Patients may complain of muscle stiffness, acute malocclusion, ear

and protective splinting (co-contraction).⁸ Although there is significant evidence that these conditions exist, there are few reliable clinical characteristics that can be used to distinguish them from each other.

Myofibrotic contracture refers to the painless shortening of a muscle. Previous terms used include chronic trismus, muscle fibrosis and muscle scarring. It is a chronic resistance to a passive stretch as a re-

sult of fibrosis of the supporting tendons, ligaments or muscle fibers themselves. The patient usually does not complain of pain unless the muscle is extended beyond its functional length. There are two basic subcategories: myostatic (reversible condition) and myofibrotic (irreversible condition). Clinical characteristics include a limited range of motion, unyielding firmness on passive stretch and a history of trauma

tissue, and in this case arising in or involving the TM joint. Neoplasms can be categorized as benign, malignant or metastatic from a distant site. Approximately 1% of malignant neoplasia metastasize to the jaws.^{9,10} Squamous cell carcinomas of the head and neck region, nasopharyngeal tumors, neoplasm arising from the parotid gland (adenoid cystic carcinoma) and mucoepidermoid carcinomas have been reported to extend to the TMJ region resulting in pain and alteration of normal function.^{11,12} Dysfunction is not usually caused by neoplasm.¹³

Primary tumors known to have involved the condyle include osteoma, benign osteoblastoma¹⁴, chondroma and chondrosarcoma, benign giant cell tumor, ossifying fibroma, fibrous dysplasia and myxoma.¹⁵ Malignant neoplasm have been reported originating from the temporomandibular joint space (fibrosarcoma, synovial sarcoma).^{16,17,18}

Congenital or developmental disorders of the cranial bones and mandible includes aplasia (agenesis), hypoplasia, hyperplasia and neoplasia. Lesions and disorders of the jaws can be either odontogenic or non-odontogenic in origin and generalized or metastatic in nature. Most congenital or devel-

opmental disorders primarily cause problems with esthetics or function and are rarely accompanied by orofacial pain unless associated with Neoplasia (eg, osteomyelitis, multiple myeloma, Paget's disease). Complete agenesis is extremely rare.¹⁹

Hyperplasia is the overdevelopment of the cranial bones or the mandible. This can be developmental or acquired. Hyperplasia can occur as a localized enlargement, such as in condylar hyperplasia or coronoid hyperplasia, or as an overdevelopment of the entire mandible or side of the face. Fibrous dysplasia is a form of hyperplasia due to a benign, slow growing swelling of the mandible and/or maxilla. It is characterized by the presence of fibrous connective tissue.

The disease occurs in children and young adults and becomes inactive when they reach skeletal maturity. Radiographically the lesion may appear from an opaque ground-glass to a lucent appearance, depending on the ratio of fibrous tissue to bone. Clinically, usually there is no displacement of teeth and the cortical bone and occlusion remain intact.

Disc derangement disorders are an abnormal arrangement of intra-capsular joint parts causing interference with the structural relation during mandibular condyle translation with mouth opening and closing. In the TM joint this alteration can relate to the elongation, tear or rupture of the capsule or ligaments causing a disruption in the disc position or morphology. The subclassification of disc displacement represents a disc-condyle misalignment and is subdivided into disc displacement with reduction or disc displacement without reduction.²¹⁻²⁵

Disc displacement with reduction is characterized by the "temporary" alteration or interference of the disc-condyle structural relationship during mandibular translation resulting in an opening joint sound, for example clicking or popping. A reciprocal closing noise is usually of less magnitude and is thought to be produced by the displacement once again of the disc (to its original position) in usually an anterior or antero-medial position.²⁴

It has been theorized that the momentary misalignment of the disc is due to articular surface irregularities, disc-articular surface adherence, synovial fluid degradation and disc/condyle incoordination as a result of abnormal muscle activity or disc deformation.

“Presently an ideal system related to masticatory system disorders does not exist.”

symptoms, tinnitus, vertigo, toothache, tension-type headache and masticatory muscles involvement. The most common differential diagnoses to consider includes osteoarthritis, myositis, myalgia, neoplasia and fibromyalgia.

Myositis is inflammation of a muscle due to local causes such as infection or injury. Pain is usually acute and in a localized area with localized tenderness over the entire region of the muscle. The inflammation can occur also in the tendinous attachment of the muscle, "tendonitis or tendomyositis". Increased pain with mandibular activity with alteration in function due to inflammation or pain. Swelling, tissue reddening and an increase in temperature over the entire muscle can be noticed. The most common differential diagnoses to consider includes myositis, local myalgia-unclassified and myofascial pain.

Myospasm is an involuntary, sudden, continuous (fasciculation) tonic contraction of the muscle. Previously used terms are trismus, "cramp". A muscle in spasm is acutely shortened. The patient experiences acute pain, a limited range of motion and often acute malocclusion. EMG studies verify sustained muscle contraction even at rest.⁵ The most common differential diagnoses to consider includes myositis, local myalgia-unclassified and neoplasia.

Local Myalgia-Unclassified This category includes muscle pain secondary to ischemia⁶, bruxism⁷, fatigue, metabolic alterations, delayed onset muscle soreness, autonomic effects

sult of fibrosis of the supporting tendons, ligaments or muscle fibers themselves. The patient usually does not complain of pain unless the muscle is extended beyond its functional length. There are two basic subcategories: myostatic (reversible condition) and myofibrotic (irreversible condition). Clinical characteristics include a limited range of motion, unyielding firmness on passive stretch and a history of trauma

“...two basic categories of TMD exist, extracapsular (myogenous) and intracapsular (arthrogenous).”

or infection is usually reported by the patient. The most common differential diagnoses to consider includes TMJ ankylosis and coronoid hypertrophy.

Masticatory muscle neoplasia can be benign or malignant and may be associated with pain or not. Neoplasia is defined as a new, abnormal or uncontrolled growth of muscle tissue (eg, myxoma). Confirmation must be obtained by biopsy and imaging.

Congenital or developmental disorders Most congenital or developmental disorders are not associated with orofacial pain. They can be categorized as agenesis, hypoplasia, hyperplasia and neoplasia.

Neoplasia, a new, often uncontrolled growth of abnormal

¹ Part 1 appeared in *Dental Tribune Middle East*, No. 9 Vol. 5, September 2007.

Although the concept of natural progression has been suggested, there is currently no convincing evidence that TMJ clicking typically progresses to locking and degeneration or that arthritic changes must develop^{25,26}, probably demonstrating a normal physiological response.^{27,28,29}

Diagnostic criteria include: reproducible joint noise usually at variable position (opening, closing), soft-tissue imaging confirms a displaced disk that improves its position during jaw opening and hard tissue imaging will demonstrate absence of extensive degenerative bone changes. Pain may be precipitated by joint movement and deviation during movement coinciding with a click.

Disc displacement without reduction, or “closed-lock”, is described as an altered or misaligned disc-condyle structural relationship that is maintained during mandibular translation. It is characterized by a lack of joint noise and limited jaw motion (opening <35 mm), mandibular deflection to the affected side (if not bilateral), soft-tissue imaging reveals disc displaced without reduction and hard-tissue imaging reveals no extensive osteoarthritic changes.

Patient may experience pain precipitated by forced mouth opening. A history of clicking that ceased with the occurrence of locking, ipsilateral hyperocclusion (during acute stage) and occasionally hard-tissue imaging can reveal moderate osteoarthritic changes. Studies on the progression of the disease have demonstrated very few reducing displaced disc cases progressing to a non-reducing stage, but almost all the non-reducing displaced disc cases developed structural bone changes.⁵⁰

Joint dislocation, or “open-lock”, is characterized by the condyle and usually the disc position anterior to the articular eminence and unable to return to a closed position without a specific manipulation. Elevator muscles activity and/or a true hyperextension of the disc-condyle complex may be responsible for the patient’s difficulty in returning to a normal position. A temporary dislocation that can be reduced by the patient is referred to as subluxation. Patient usually reports a history of excessive range of motion (hypermobility) that is not painful, but pain can occur at the time of dislocation with mild residual pain after the episode. Radiographic evidence reveals the condyle well beyond the eminence. The most common differential diagnosis to consider is fracture.

Inflammatory conditions can occur as localized synovitis, capsulitis or retrodiscal tissues of the temporomandibular joint that can be due to infection, an immunologic condition secondary to articular degenera-

tion or trauma. Clinically it is difficult and may be impossible to differentiate between these. Diagnostic criteria must include localized TM joint pain exacerbated by function, especially with superior or posterior joint loading on palpation. No evidence of extensive osteoarthritic changes with hard-tissue imaging. Additional clinical findings may exist, such as localized pain at rest, limited range of motion secondary to pain, fluctuating swelling (due to effusion) causing a decrease in the ability to occlude on ipsilateral posterior side and ear pain.

The most common differential diagnoses include: osteoarthritis, polyarthritis, ear infection, neoplasia, generalized systemic polyarthritic condition, rheumatoid arthritis, juvenile rheumatoid arthritis (Still’s disease), spondyloarthropathies (ankylosing spondylitis, psoriatic arthritis, infectious arthritis, Reiter’s syndrome), crystal-induced disease (gout, hyperuricemia), and autoimmune disease and other mixed connective tissue diseases (lupus erythematosus, scleroderma, Sjögren’s Syndrome). Polyarthritides are characterized by pain during acute and subacute stages, possible crepitus, limited range of motion secondary to pain and/or degeneration and bilateral radiographic evidence of structural bony changes.⁵¹ The complexity of the disease mandates serology studies and management by a rheumatologist. Bilateral resorption of condylar structures can result in an anterior open bite.

Osteoarthritis is considered a non-inflammatory arthritic condition that is commonly found in synovial joints. Osteoarthritis is classified according to the etiology of the condition. It is divided into a primary and secondary non-inflammatory arthritic condition.⁵² The recognition of secondary osteoarthritis is clinically significant because it may represent the first stage of treatment.

Osteoarthritis (primary) is a degenerative non-inflammatory condition of the joint characterized by deterioration and abrasion of the articular tissue and concomitant remodeling of the underlying subchondral bone due to overload on the remodeling mechanism.^{35–36} Osteoarthritis is categorized as primary on the absence of identifiable etiologic factors.³⁷

Clinical characteristics include: pain with function, point tenderness with palpation, limited range of motion with deviation to the affected side on opening and crepitus or multiple joint noises. Radiographically, evidence of structural bony changes (subchondral sclerosis, osteophytic formation, erosion). Pain and dysfunction can vary depending on the degree of inflammation and morphologic changes. Studies suggest that the course of the disease usually progresses favorably; allowing remodeling and adapta-

tion. Treatment must be rendered on a case specific basis depending upon the degree of pain and dysfunction.³⁸ The most common differential diagnoses to consider: inflammation, polyarthritis, neoplasia.

Osteoarthritis (secondary) is a degenerative condition of the joint characterized by deterioration and abrasion of the articular tissue and the concomitant remodeling of the underlying subchondral bone due to a prior event or disease that overload the remodeling mechanism. Clinical characteristics include: a clearly documented disease or event associated with osteoarthritis, pain with function, point tenderness on palpation, limited range of mandibular motion with deviation to the affected side on opening and crepitus or multiple joint sounds. Potential etiological factors include direct trauma to the TM joint (traumatic arthritis), local TMJ infection or history of active systemic arthritis (eg, rheumatoid arthritis).

Ankylosis is clinically characterized by the restriction of a mandibular movement with deviation to the affected side on opening and is usually not associated with pain.⁴⁰ Fibrous adhesions occur mainly in the superior compartment of the TM joint, affecting the translation movement of the affected condyle. Adhesions can occur secondary to joint inflammation resulting from trauma or systemic conditions such as polyarthrotic disease. Bony ankylosis can lead to a complete immobilization of the TM joint. Clinically, evidence of bone proliferation is appreciated radiographically. Patient demonstrates deviation to the affected side and significant limited movement to the contralateral side.

Fracture is direct trauma to the mandible and may result in fracture to the condylar process. All related components of the masticatory system—soft tissue, disc, capsule, synovium, retrodiscal tissue, ligaments, and/or articular surface—may also be affected. Condylar fractures are usually unilateral and may occur in the condylar neck or in the capsule (intra- or extracapsular) with or without displacement. Location of the fracture and degree of the fracture will determine the direction of displacement. A displacement anterior-medial-inferior usually results due to the action of the lateral pterygoid muscle. Clinical characteristics include: associated trauma, preauricular pain and swelling (synovitis, capsulitis), limited opening, and if the condylar fragment is displaced, occlusal changes and deviation to the affected side. The development of adhesions and osteoarthritis are common findings implicated in condylar fractures.^{39, 40} [B]

Literature

1. Dworkin, S.F., Huggins, K.H., Le Resche, L., et al. Epidemiology of signs and symptoms in temporomandibular disorders: clini-

cal signs in cases and control. JADA, 1990; 120:273–81.

- Schiffman, E., Friction, J.R., Haley, D., et al. The prevalence and treatment needs of subjects with temporomandibular disorders. JADA, 1990; 120:295–304.
- Friction, J.R., Myofascial pain syndrome: Characteristics and epidemiology. In: Friction, J.R., Awad EA (eds). Advances in Pain Research and Therapies, vol 17. Myofascial pain and Fibromyalgia. New York: Raven, 1990:107–127.
- Friction, J., Kroening R, Haley D, et al. Myofascial Pain syndrome of the head and neck: A review of clinical characteristics of 168 patients. Oral Surg Oral Med Oral Pathol 1982;60:615–23.
- Layzer RB. Diagnostic implication of clinical fasciculations and cramps. In: Rowland LP (ed). Human Motor Diseases. New York: Raven, 1982:23–27.
- Sahlin K, Eldstrom L, Sigholm H, et al. Effects of lactic acid accumulation and ATP decrease on muscle tension and relaxation. Am J Physiol 1981;240:C121–C126.
- Dao TTT, Lund JP, Lavinge GJ. Comparison of pain and quality of life in bruxers and patients with Myofascial pain of the masticatory muscles. J Orofacial Pain 1994; 8:350–356.
- Tveteras K, Kristensen S. The etiology and pathogenesis of trismus. Clin Otolaryngol 1986;11:583–7.
- Aniceto GS, Penin AG, de la Meta Pages R, et al. Tumors metastatic to the mandible. Analysis of nine cases and review of the literature. J Oral Maxillofac Surg 1990;48: 246–251.
- Bavitz JB, Chewning LC. Malignant disease as temporomandibular joint dysfunction: Review of the literature and report of case. J Am Dent Assoc 1990;120: 163–166.
- Sharav Y, Feinsod M. Nasopharyngeal tumor initially manifested as Myofascial pain dysfunction syndrome. Oral Surg Oral Med Oral Pathol 1977;44:54–77.
- Malins TJ, Farrow A. Facial pain due to occult parotid adenoid cystic carcinoma. J Oral Maxillofac Surg 1991;49:1127–1129.
- Trumpy IG, Lyberg T. Temporomandibular joint dysfunction and facial pain caused by neoplasms: Report of three cases. Oral Surg Oral Med Oral Pathol 1993;76: 149–152.
- Svensson D, Isacson G. Benign osteoblastoma associated with an aneurysmal bone cyst of the mandibular ramus and condyle. Oral Surg Oral Med Oral Pathol 1993;76:433–436.
- Nitzan DW, Marmary Y, Hasson O, et al. Chondrosarcoma arising in the temporomandibular joint: A case report and literature review. J Oral Maxillofac Surg 1993; 51:312–315.
- White RD, Makar J, Steckler RM. Synovial sarcoma of the temporomandibular joint. J Oral Maxillofac Surg 1992;50:1227–1230.
- Mendoca-Cardad JJ, Schwartz HC. Synovial chondromatosis of the temporomandibular joint: Arthroscopic diagnosis and treatment of a case. J Oral Maxillofac Surg 1994;56:624–625.
- Quinn PD, Stanton DC, Foote JW. Synovial chondromatosis with cranial extension. Oral Surg Oral Med Oral Pathol 1992;73:398–402.
- Brecht K, Johnson CM. Complete mandibular agenesis. Report of a case. Arch Otolaryngol 1985; 111:132–134.
- Behrents RG, Mc Namara JA, Avery JK. Prenatal mandibulofacial dysostosis (Treacher-Collins syndrome). Cleft Palate J 1977;14: 13–34.
- Farrar WB. Differentiation of temporomandibular joint dysfunction to simplify treatment. J Prosthet Dent 1972;28:629–36.
- Dolwick MF. Diagnosis and etiology of internal derangements of the temporomandibular joint.

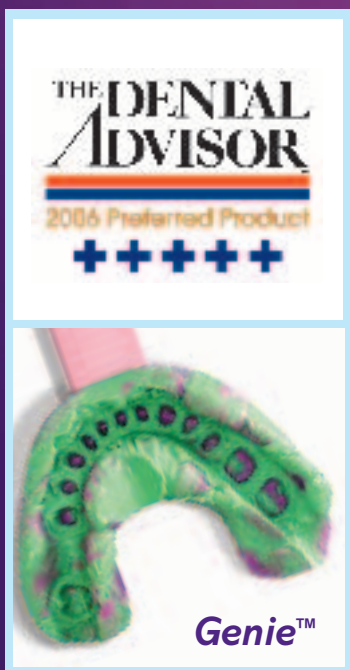In Laskin D, Greenfield W, Gale E, et al, editors. The President’s Conference on the examination, diagnosis and management of temporomandibular joint disorders. Chicago: Am Dent Assoc 1983:112–7.

- Hansson TL. Temporomandibular joint anatomical findings relevant to the clinician. In Clark GT, Solberg WK, editors. Perspectives in temporomandibular disorders. Chicago: Quintessence Publishing Co, 1987:45–57.
- Isberg-Holm AM, Westesson P. Movement of the disc and condyle in temporomandibular joints with clicking: An arthrographic and cineradiographic study on autopsy specimens. Acta Odontol Scand 1982;40:151–164.
- Nikerson JW, Boering G. Natural course of osteoarthritis as it relates to internal derangement of the temporomandibular joint. Oral Maxillofac Surg Clin North Am 1989;1:1–19.
- de Bont, LF, Dijkgraaf LC, Stenga B. Epidemiology and natural progression of articular temporomandibular disorders. Oral Surg Oral Med Oral Pathol Oral Radiol Endod 1997;83(1):72–76.
- Scapino RP. The posterior attachment: Its structure, function and appearance in TMJ imaging studies. Part I. J Craniomand Disord Facial Oral Pain 1991;5:85–95.
- Scapino RP. The posterior attachment: Its structure, function and appearance in TMJ imaging studies. Part II. J Craniomand Disord Facial Oral Pain 1991;5:155–166.
- Scapino RP. Histopathology associated with malposition of the human temporomandibular joint disc. Oral Surg Oral Med Oral Pathol 1983;55:382–397.
- de Leeuw R, Boering G, Stegenga B, de Bont LG. Clinical signs of TMJ, Osteoarthritis and Internal derangement 30 years after non surgical treatment. J Orofacial Pain 1994;8:18–24.
- Altman RD. Criteria for classification of clinical osteoarthritis. J Rheumatol 1991;18(suppl27): 10–12.
- Holmlund AB, Gynther G, Reinhold FP. Rheumatoid arthritis and disc derangement of the temporomandibular joint: a comparison study. Oral Surg Oral Med Oral Pathol 1993;73:273–277.
- De Bont LGM, Boering G, Liem RSB, et al. Osteoarthritis of the temporomandibular joint: A light microscopic and scanning electron microscopic study of the articular cartilage of the mandibular condyle. J Oral Maxillofac Surg 1985;43:481–488.
- Kopp S. Clinical findings in temporomandibular joint osteoarthritis. Scand J Dent Res 1977; 85:434–443
- Bland JH, Stulberg SD. Osteoarthritis: Pathologist and clinical patterns. In: Keeley WM, et al (eds). Textbook of Rheumatology, 2nd ed. Philadelphia: Saunders, 1985.
- Stegenga B, de Bont LGM, Boering G, et al. Tissue responses to degenerative changes in the temporomandibular joint: A review. J Oral Maxillofac Surg 1991; 49:1079–1088.
- Brandt KD, Slemenda CW. Osteoarthritis: Epidemiology, pathology and pathogenesis. In: Schumacher HR (ed). Primer on the rheumatic diseases, 10th ed. Atlanta: Arthritis Foundation, 1993:184–188.
- Rasmussen OC. Clinical findings during the course of temporomandibular arthropathy. Scand J Dent Res 1981;89:283–288.
- Block MS, Provenzano J, Neary JP. Complications of mandibular fractures. Oral Maxillofac Surg Clin North Am 1990;2:525–550
- Bell WE. Temporomandibular Disorders. Classification, Diagnosis, Management, 3rd ed. Chicago: Year Book, 1990:166–176.

It's the impression

below the surface that makes the difference.

Genie's™ superior flow... for incredible impressions, every time.



To capture the very best impressions, it's critical that your impression material exhibits superior "flow" – the ability to capture all details, including those past the prepared margin. Flow is the single most important feature of your impression material, because the better the flow, the better you'll capture important details.

For flow that stands above the rest, choose Genie™. An independent study confirms it: when compared to leading brands of impression material, Genie™ proved to have superior flow.* Isn't it time you got the best performance at a great price?

* Study available upon request.

To order Genie™, contact your dental supply dealer or visit www.sultanhealthcare.com.

Sultan Healthcare
www.sultanhealthcare.com

If you like Genie™, you'll love these Sultan products...



Silgimix™ Alginate Replacement Impression Material

Quicker, better impressions—without the mess. It's the dust-free alternative to alginate materials.



Genie™ Bite

A bite registration that sets, rock hard, in 60 or 90 seconds. Comes in easy-to-use automix cartridges.



3-Way™ Disposable Impression Trays

Single use—ideal for accurate impressions, counter impressions and bite registrations.



Genie™ Magic Mix

Genie is available in 380 ml cartridges for automix machines. Get 5% more material than foil bag systems.



Google rivals Microsoft with new personal medical record service

Reuters

ORLANDO: Google has unveiled a new plan for patients who want to gain control of their medical records. At the 2008 Annual Conference of the Healthcare Information and Management Systems Society in Florida, USA, Chief Executive Eric Schmidt said that his company has signed deals with leading US hospitals and medical companies, such as Aetna Inc and Walmart Stores Inc pharmacies, to help them securely share sensitive health data.

introduced HealthVault, a hub to collect, store and share personal medical information on the internet.

While medical providers are covered by US privacy laws, there is little in the way of estab-

lished privacy, security and data usage standards for electronic personal health records. Google said it is prepared to resist fishing expeditions by lawyers seeking to subpoena personal medical records stored on Google Health. Last year, it went to court

to defeat an effort by the US Justice Department to request some Google search records. "We've taken a pretty aggressive position in a pro-consumer way in the US, but I do want to assure you we are subject to US law," Schmidt said. [D1](#)

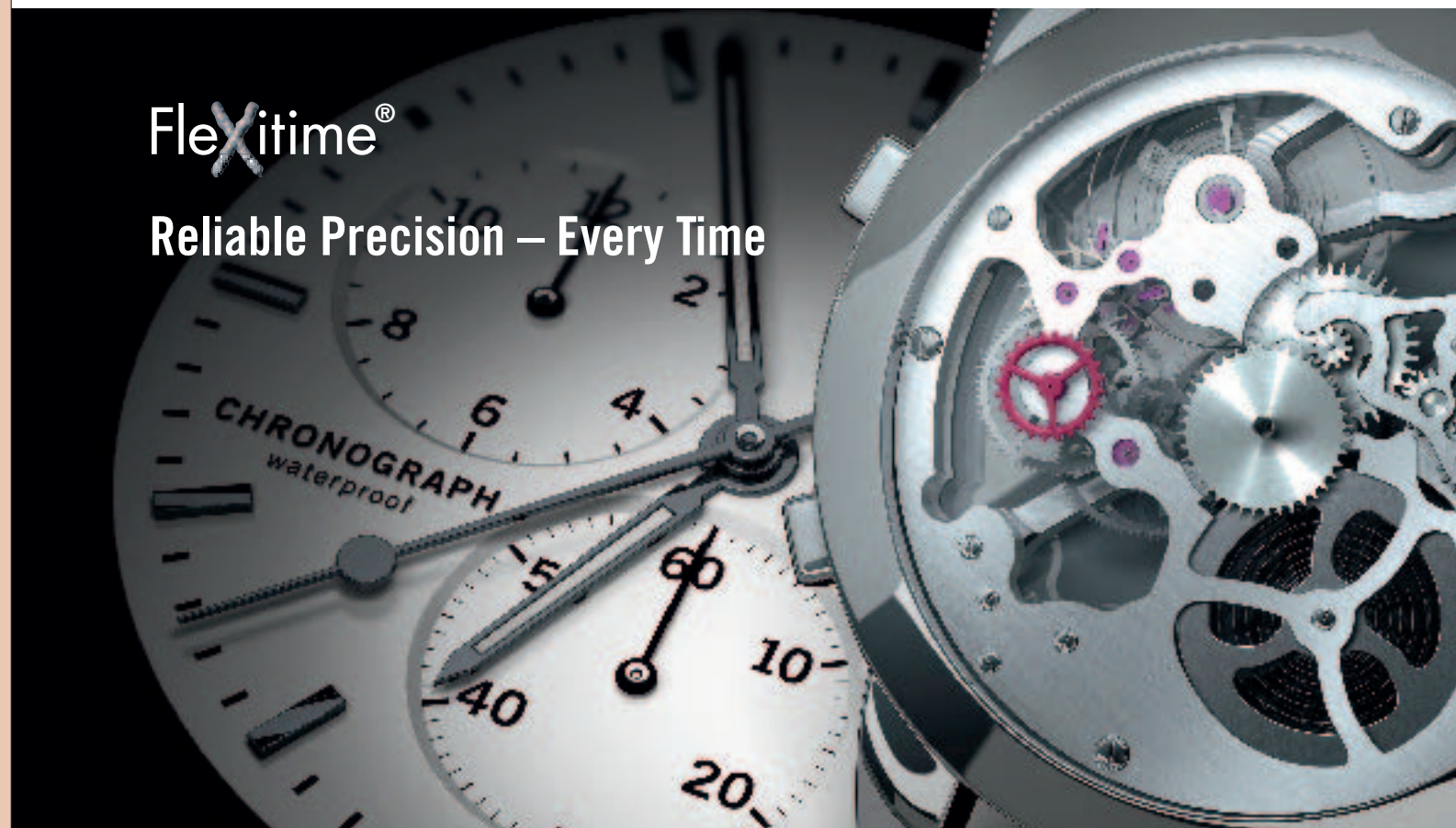


AD

Heraeus

Flexitime®

Reliable Precision – Every Time



CEO Eric Schmidt introduced Google's new personal medical record service at the HIMSS in Florida, Photo: Oscar-Einzig

Schmidt said it would likely be a few months before Google Health is offered widely. The password-protected web service will store health records on Google computers, with a medical services directory that lets users import doctors' records, drug history and test results. Google aims to foster sharing of information between these services, but keep control in patients' hands, allowing them to schedule appointments or refill prescriptions. Schmidt said that his company has no plan to sell ads on the new service and aims to make money indirectly when users search for other medical information.

Earlier this year, Google announced it will team up with a leading academic medical research clinic, Cleveland Clinic, to test a data exchange that puts patients in charge of records. Many other companies—such as IBM, Oracle Corp and Siemens—have already worked on such digitization and Google's biggest rival, Microsoft, has recently in-

Flexitime®

- Precision and accuracy
- Easy, robust and safe processing
- Flexible working time combined with always short intraoral setting time
- 7 years market experience, clinically proven
- Multiple times awarded quality

New!

Flexitime® Dynamix® Putty

- True Putty consistency automatically mixed
- Balanced hardness
- Low stickiness
- Convenient cutting



Flexitime® – the VPS precision impression material for reliable precision – every time.

Heraeus Kulzer GmbH

Mid-East & N. Africa

United Arab Emirates

Export Manager: Dia Marwan · P.O. Box 5527 Dubai · Phone +971(0)4 2828558 · Fax +971(0)4 2828508

e-mail: heraeus@emirates.net.ae · www.heraeus-kulzer.com

