

implants

international magazine of oral implantology



case report

Guided maxillary arch implant restoration

Peri-implantitis: Can it be treated without surgery?

interview

The quest for safe and sterile implants



Neodent® Grand Morse®

Greatness is an achievement.



GRAND ESTHETICS

Delivers Immediate natural-looking esthetics.



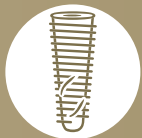GRAND SIMPLICITY

Ease of use at its best.



GRAND RELIABILITY

Stable and strong foundation designed for long term success.



GRAND STABILITY

Designed for predictable immediate treatments in bones I, II, III and IV.



Discover all Neodent® Grand Morse® benefits, scan the QR code or access: neodent.com/gm-pr



Celebrating is a choice

Neodent® is celebrating its 30th anniversary! Over time, millions of smiles have been created in partnership with professionals worldwide.



Dr Rolf Vollmer
First Vice President
and Treasurer of DGZI



Looking ahead in 2023

Dear colleagues and friends,

The past few years have presented significant challenges for the dental community, particularly with the pandemic and the shift to virtual events. However, despite these challenges, the demand for dental implants continues to grow, reflecting their value as a solution for missing teeth. This growth has led to an increased focus on research and development in the field, and new techniques and technologies are being developed all the time. This is a testament to the dedication and innovation of the professionals in our discipline.

I am especially looking forward to the upcoming International Dental Show in Cologne in Germany. This event, the world's largest trade fair for the dental industry, offers an unparalleled opportunity for us to come together as a community, meet old friends and partners, and explore the latest innovations in dentistry. I would like to invite you to visit the German Association of Dental Implantology (DGZI) in Hall 11.2 at Booth S010/T011. Our members will be in attendance, ready to share their experiences and insights with you. At the DGZI, we have a strong commitment to advancing research in implantology. Our society is dedicated to fostering and promoting ongoing research in order to improve patient outcomes and advance our understanding of this complex and dynamic area of dentistry. This includes exploring new materials, surgical techniques and ways to optimise the integration of implants with the surrounding tissue.

Although there is still some time to go, I would also like to use this as an opportunity to announce the DGZI congress in Hamburg in Germany on 6 and 7 October. This international event is a great chance for implantologists to come together and share their experiences, insights and perspectives on the latest advancements in our field. I encourage all of you to attend and contribute to the discussions, as we work together to further the progress of implantology.

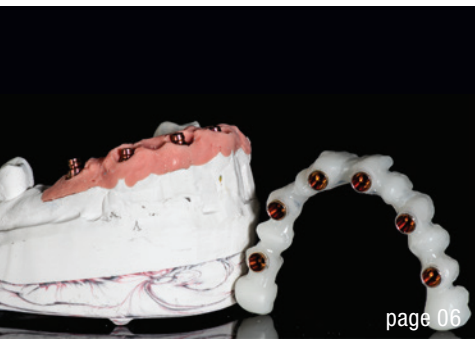In conclusion, I am proud to be a part of this community and to work alongside so many dedicated and talented professionals. I look forward to continuing to support the growth and development in implantology and to the opportunities for learning and networking that lie ahead.

Yours,

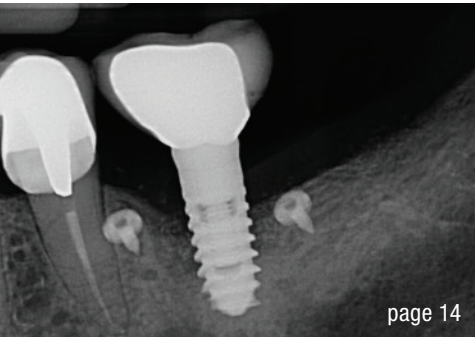
A handwritten signature in black ink, appearing to read 'Dr Rolf Vollmer'.

Dr Rolf Vollmer

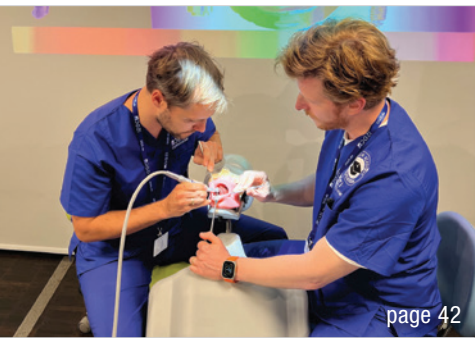First Vice President and Treasurer of DGZI



page 06



page 14



page 42

Cover image courtesy of bredent medical, www.bredent-group.com



Background: © STILLFX/Shutterstock.com

editorial

Looking ahead in 2023 03
Dr Rolf Vollmer

case report

Guided maxillary arch implant restoration: Language and cross-border collaboration are no barrier with hybrid workflow 06
Dr Florian Obădan & Jorge Reyes Minguillán

Peri-implantitis: Can it be treated without surgery? 14
Prof. Hady Haririan

Dual-wavelength **laser treatment** of osteotomy site to increase the **success rate** of implant placement 20
Dr Sean Chiu

Immediate implant placement and bone grafting of a maxillary central incisor: **A seven-year follow-up** 26
Prof. Su Yucheng

Screw-retained restoration of maxillary first premolar 30
Dr Anthony Bendkowski

interview

The quest for **safe** and **sterile** implants 34
Dr Dirk Duddeck

Acting against the **silo effect** 36
Dr Tiziano Testori

industry

Neodent celebrates **30 years** of history 38

news

manufacturer news 40

news 48

events

High-tech in a unique setting 42

about the publisher

imprint 50



**IMPLANT
SOLUTIONS
WORLD
SUMMIT**

ATHENS 2023

**Athens, Greece
June 8-10, 2023**

Where history, future
and science meet

Are you passionate about implant dentistry?

**Are you committed to science, innovation
and education?**

**Do you want to provide your patients with
optimized treatment solutions?**

Then join Dentsply Sirona, the world-leading expert
in implant dentistry, for an exclusive, state-of-the-art
congress in Athens, Greece, on June 8-10, 2023.

At Implant Solutions World Summit, you'll discover
cutting-edge science, the latest innovations in digital
dentistry, bone regeneration, and optimized implant
treatment solutions for your patients—and enjoy the
company of world-renowned speakers, colleagues
and friends from around the world.



dentsplysirona.com/worldsummit

[#ImplantSolutionsWorldSummit](https://twitter.com/ImplantSolutionsWorldSummit)

Follow Dentsply Sirona for
the latest in implant dentistry



dentsplysirona.com/implants

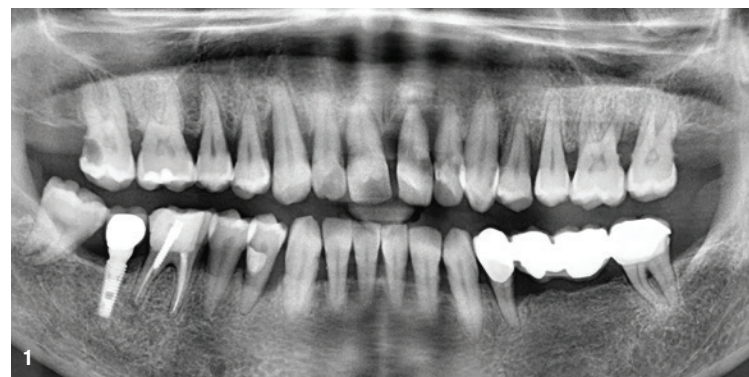 **Dentsply
Sirona**

**Implant
Solutions**

Guided maxillary arch implant restoration: Language and cross-border collaboration are no barrier with hybrid workflow

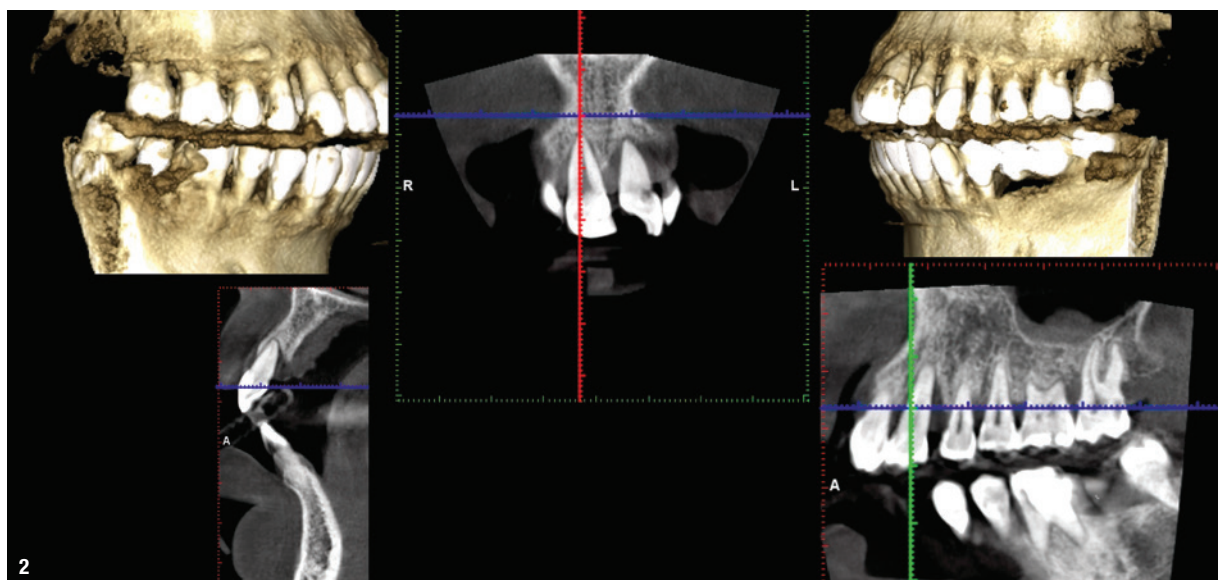
Dr Florian Obădan & Jorge Reyes Minguillán, Romania & Spain

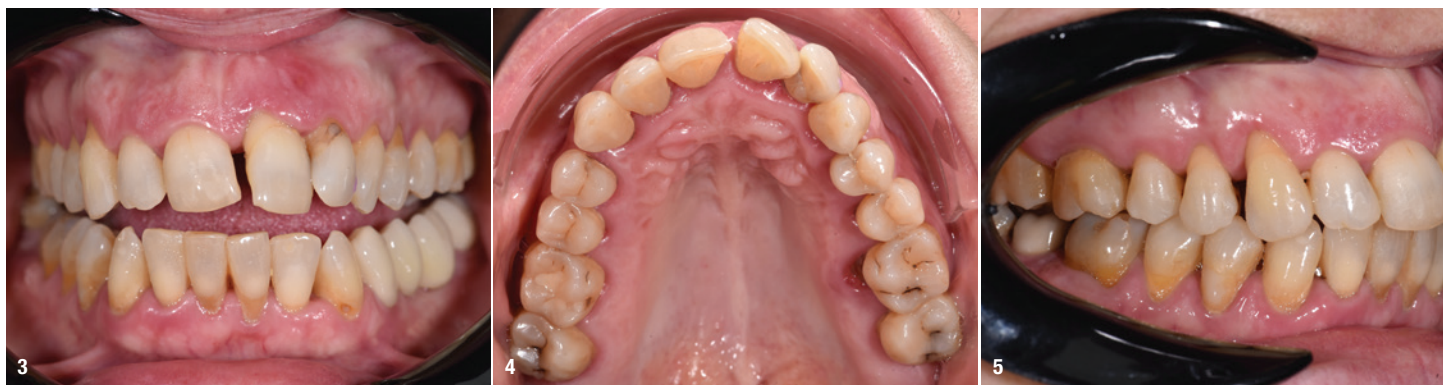The rehabilitation of a failing maxillary dentition requires comprehensive planning and appropriate tools to execute a treatment which will meet the patient's expectations and accomplish the biological principles for long-term successful restoration. Nowadays, digital workflows aid clinicians in achieving this accuracy with holistic treatment planning. Digitisation in implant dentistry has ensured that the dental technician and the clinician are in sync at every step of planning and execution, as the exchange of data between them can be done remotely with the click of a button. Guided implant placement ascertains the precise transfer of the virtually planned implant positions to the surgical site. This pre-planned implant positioning facilitates immediate loading, as the provisional prosthesis can be milled and kept ready prior to the surgery, requiring only minor relining and adjustments after the surgery. Guided implant placement with immediate loading not only restores function, aesthetics and the patient's confidence instantly, but also has high patient ac-



ceptability owing to the minimised surgical trauma, post-operative discomfort and reduced treatment duration.

The following case report showcases the planning and execution of the SKY fast & fixed full-arch protocol (trent





medical) with synchronisation of a complete digital workflow between a dental technician in Spain and a clinician in Romania who do not speak a common language.

Case presentation

A middle-aged woman presented to the dentist's clinic in Alexandria in Romania with a mobile central incisor, seeking a long-term highly aesthetic solution. A full-mouth clinical assessment and radiographic examination with a dental panoramic tomogram and CBCT scan (Figs. 1 & 2) were carried out. Based on the severity, complexity of management and extent of distribution, a diagnosis of generalised severe periodontitis with potential loss of dentition was made, and the patient was advised to undergo total extraction of the maxillary teeth (other than the terminal molars) and immediate placement of implants and their immediate loading using the SKY fast & fixed treatment protocol.¹⁻⁴

Preoperative phase

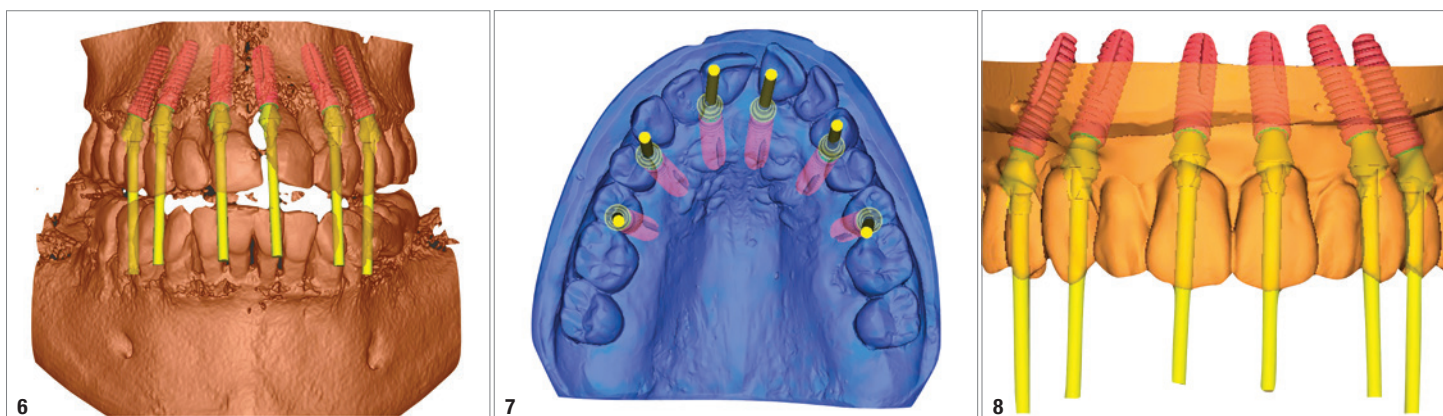
High-resolution intra-oral images and profile pictures were taken (Figs. 3–5). Preliminary impressions were made with irreversible hydrocolloid (alginate), as there was a possibility of tooth loss (owing to severe tooth mobility) with the use of silicone-based materials for impression taking. The resulting models were scanned using the

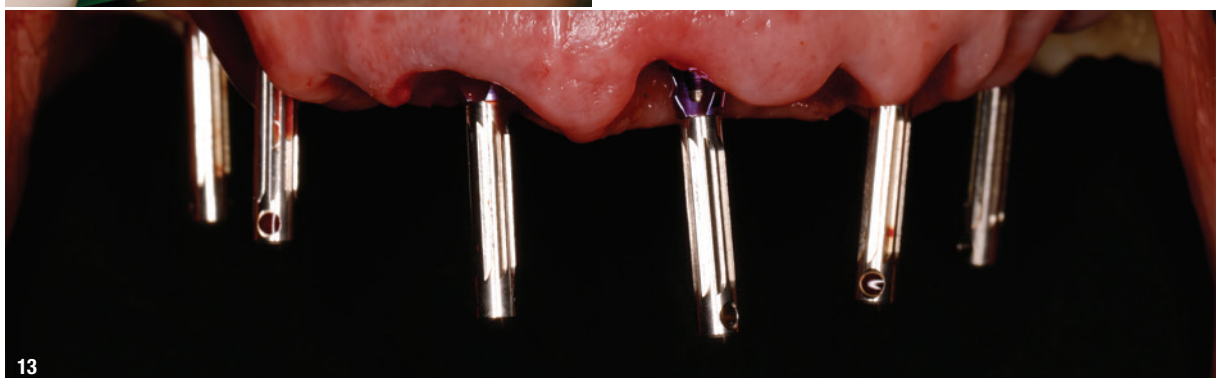
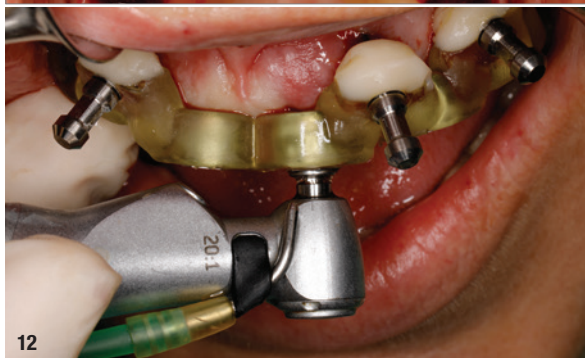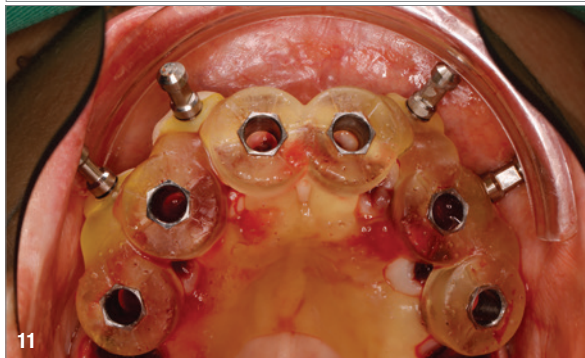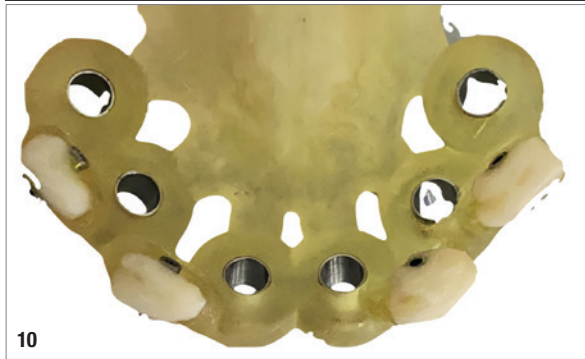
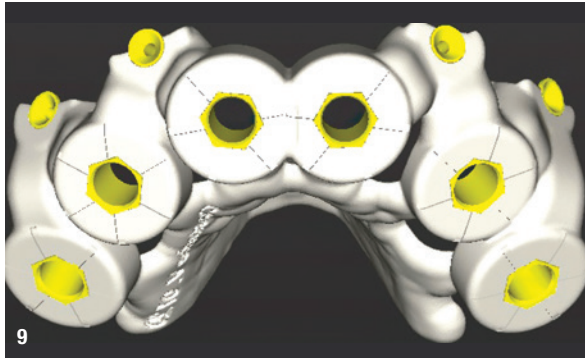
laboratory 3D scanner, and the STL files, radiographs and images were transferred to the dental technician in Madrid in Spain.

The dental technician used exocad for the digital mock-up and e-mailed it to the clinic. The CAD was printed (the model without the teeth, the model with the new tooth set-up and the teeth detached from the model) using a 3D printer. The STL files were used for planning the ideal prosthetic positions of the implants (six 4 × 14 mm copaSKY implants, bredent medical). CoDiagnostiX (Dental Wings) was used for planning the implant positions, as well as the appropriate abutments (Figs. 6–8). The surgical guide was fabricated based on the virtually planned ideal positions of the six implants (Figs. 9 & 10). The provisional prosthesis was designed in Madrid by the dental technician, but milled and kept ready prior to surgery in Romania.

Surgical phase

The procedure was done under local anaesthesia with articaine with 1:100,000 adrenaline. Atraumatic extraction of all the maxillary teeth except the terminal second molars (as they served as a vertical stop for maintaining occlusal height) was done, and the extraction sockets were thoroughly curetted to remove the granulation tissue. After mechanical debridement, to ensure complete disinfection of the site, antimicrobial photodynamic therapy was per-



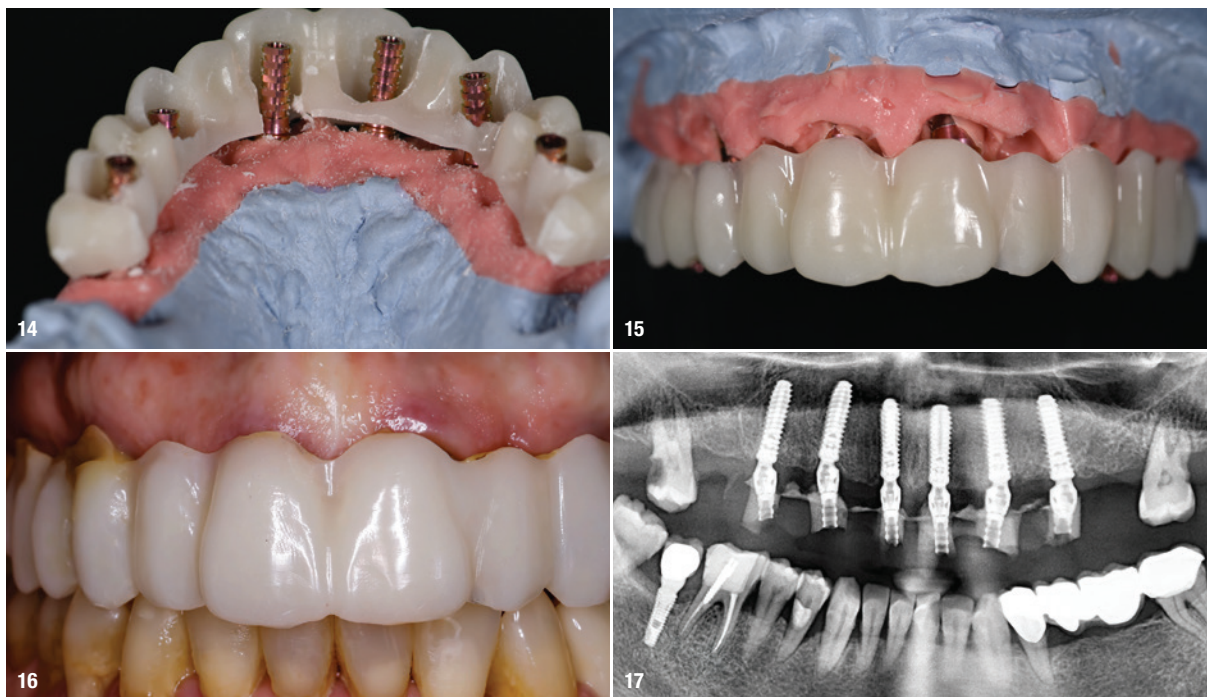


formed. A blue photosensitiser (methylene blue) was applied inside each socket and left in situ for 60 seconds to stain the bacteria. After rinsing off of the liquid, each socket was then exposed to the diode laser for 1 minute. This ensures focused antibacterial action by destruction of the bacteria in the biofilm by singlet oxygen molecules. The procedure was completely flapless to minimise surgical trauma, and it facilitated seamless seating of the surgical guide. The surgical guide was stabilised intra-orally with four fixation pins placed buccally (Fig. 11). The surgical kit was used for fully shaft-guided implant placement, which is more convenient than the sleeve-in-sleeve and spoon systems. It is based on the principle of maximum safety when reaching the drilling depth and angulation by guiding the drills through the high-precision drill sleeve (Fig. 12). Sequential drilling was done, and primary stability of more than 40Ncm was obtained for all six implants, facilitating predictable immediate loading. Titanium abutments were installed on all six implants, and a closed-tray impression was taken (Fig. 13). The milled provisional prosthesis was placed on the quickly poured model to make the holes in the prosthesis to facilitate intra-oral relining with Qu-Resin and Qu-Connector (bredent medical) to ensure a passive fit of the screw-retained prosthesis (Figs. 14 & 15). The titanium copings were picked up in the provisional prosthesis after relining, finished and polished extra-orally, and inserted on to the implants to a torque of 18Ncm (Figs. 16 & 17). The provisional prosthesis was kept out of all eccentric contact, and light centric contacts were maintained. Biomechanical principles were applied by preventing cantilevers which could weaken and fracture the provisional prosthesis.

The patient was instructed to avoid hard food, and oral hygiene instructions were reinforced. She was extremely satisfied with her new smile and regained her confidence.

Prosthetic phase

The patient was recalled after eight months for the final prosthetic phase. Intra-oral scans were taken for fabrication of the final prosthesis (Fig. 18), the intention being to



plan, start and finish the case completely digitally. This, however, was not possible because there was a mismatch in fitting the components which the laboratory had milled for verification on the printed models. The decision was made to go the analogue route.

Titanium copings were inserted, and after confirmation of proper seating with a panoramic radiograph, intra-oral splinting of the copings was done to ensure accurate impression taking. Putty and light-bodied wash impressions were taken, carefully packed and sent to Madrid for fabrication of the final prosthesis (Figs. 19a & b).

After obtaining the master model, the dental technician made the design of the framework, milled it in PMMA and sent it to the clinic. The provisional prosthesis, having a passive fit, because it was fixed intra-orally, was used as a verification key for the master model. Because there was a passive fit, the framework was cemented on to the pre-fabricated copings with DTK-Adhesive (bredent medical) on the model by the dental technician (Figs. 20 & 21).

The solution for the long-term restoration was determined based on the inter-arch distance and passivity of fit, as well as protection of the implants. The choice of material for the definitive prosthesis framework was laser-sintered titanium with composite build-up teeth (Figs. 22–24). The laser-sintered titanium, being produced with an additive method, did not have undercut areas, and it was fabricated by the dental technician in Spain.

Canine-guided occlusion was established without difficulty. Function and aesthetics were restored satisfactorily

for the patient, and the final outcome was extremely gratifying for the surgical and prosthetic team (Figs. 25 & 26).

Discussion

Chronic generalised periodontitis can result in insidious loss of periodontal attachment, tooth mobility and poor prognosis of teeth. The SKY fast & fixed treatment protocol aims for immediate restoration of function and aesthetics for management of failing dentition. A recent study by Slutzkey et al. concluded that, if the prerequisites for immediate loading, such as high primary stability of $\geq 30\text{Ncm}$, splinting of the implants via a provisional prosthesis and the use of bone-level implants with a sand-blasted and acid-etched surface, are fulfilled, then full-arch fixed restorations supported by a combination of axial and tilted implants can be a viable treatment option to rehabilitate the terminal dentition of patients suffering from severe generalised periodontitis.⁵

