

implants

international magazine of oral implantology



case report

Delayed immediate implant placement and direct soft-tissue management


interview

On remaining vigilant

events

Dental implant quality under scrutiny

You never forget
your first *fixo*



Fixo: the first single-piece implant
for immediate loading,
easily usable even in guided surgery.

discover more



oxyimplant.com

Dr Georg Bach

President of the DGZI



Dental **implantology** in times of crisis

Implantology has been a crucial factor in dental healthcare and continues to be so—even in these challenging times of the coronavirus. Patients in Germany and other countries have been receiving reliable dental care over the past months with regard to all oral and surgical matters, which naturally includes implantology. The fact that implantology is a stable and reliable pillar of dental healthcare in crises like the current one does not seem self-evident at first glance, but it underscores the importance that this special discipline enjoys among the population today. Implantology must not be considered optional; rather is it integral to the basic therapy spectrum of dentistry and cannot be sidelined if circumstances get dire. This is not least due to the many years of dental training and continuing education in implant surgery and prosthetics, as well as the continuous development of first-rate products and services from our trade and industry partners.

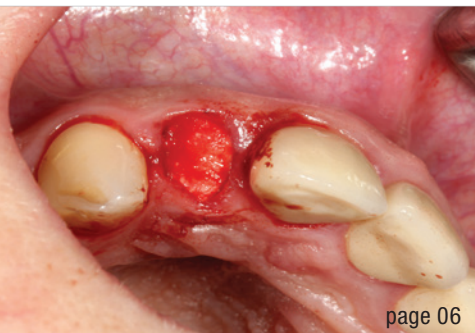
In light of this, it is quite evident that the Future Congress of the German Association of Dental Implantology (DGZI) remains indispensable. The 50-year anniversary of DGZI was initially planned to be celebrated last year in the German city of Bremen, the association's founding city. However, owing to the COVID-19 pandemic-related restrictions imposed by the federal government at that time, the congress had to be postponed. The cancelled congress will now be held on 1 and 2 October 2021 in Cologne in Germany with a programme that remains unchanged in terms of its high degree of versatility and interactivity and its first-rate character. In addition to the informative dental exhibition, the Future Podium will commence on Friday with a lecture of my own on triumphs and tragedies in implantology, which will be followed by lectures by Prof. Shahram Ghanaati on the use of autologous blood concentrates in implantology and oral surgery and Prof. Katja Nelson on digitalisation in implantology

(from freehand to guided surgery), and a subsequent joint panel discussion. Thereafter, the streaming of a live surgery conducted by Dr Jan Klenke demonstrating periodontal recession coverage using an acellular dermal matrix and a tutorial by Prof. Daniel Grubeanu on elevated immediate restoration concepts will follow. The subsequent three sessions of more than 20 table clinics (45 minutes each) will allow for direct peer–peer exchange on different treatment approaches, concepts and products within the context of implantology and peri-implantitis therapy. The digital poster presentation will kick off on Friday as well, and the winners will be awarded the next day. Saturday will be dedicated to the transfer of academic knowledge through lectures by internationally renowned speakers. We are honoured to have been able to attract, among others, the presidents of numerous leading expert societies as speakers for this part of the programme. You will find the complete Future Congress programme at www.dgzi-jahreskongress.de.

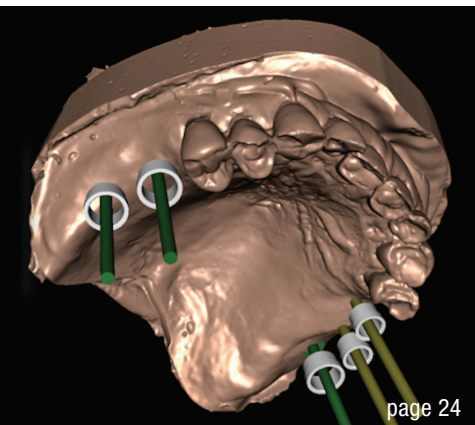
We are looking forward to finally seeing you in person again! With this in mind, I wish you a beautiful, successful and harmonious late summer and an exciting time reading this new issue of **implants—international magazine of oral implantology**.

Yours,

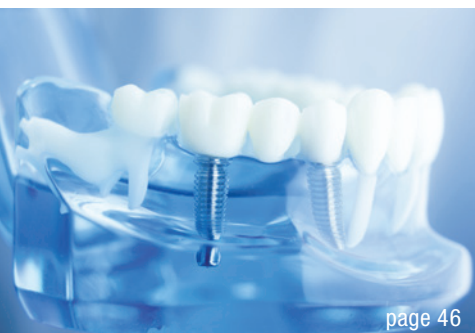Dr Georg Bach



page 06



page 24



page 46

Cover image courtesy of
TBR Dental / www.tbr.dental



editorial

Dental **implantology** in times of crisis 03
Dr Georg Bach

case report

Delayed **immediate** implant placement and direct **soft-tissue** management 06
Dr Haki Tekyatan

Restorative simplicity for a challenging case with limited space 14
Dr Fernando Rojas-Vizcaya & Jose de San Jose Gonzalez

Immediate fixed **full-arch** rehabilitation of periodontitis patients 16
Prof. João Caramês

Graft volumetric changes of **collagenated** xenograft 24
Dr Livio Lo Faro, Dr Francesco Giachi Carù & Prof. Tiziano Testori

Dental lasers against **peri-implantitis** 34
Dr Bradley Labrecque

Successful **rehabilitation** of an anterior tooth 36
Dr Dr Branislav Fatori & Dr Inge Schmitz

interview

On remaining **vigilant** 38
An interview wiith Julien Benhamou

obituary

The inventor of the Bicon system has passed away 40

news

manufacturer news 42

news 48

events

Dental implant quality **under scrutiny** 46
Dr Dirk U. Duddeck

about the publisher

imprint 50

FLEX YOUR MUSCLES

OUR SHORTCUT TO IMMEDIACY:
CONELOG® PROGRESSIVE-LINE FLEX



PROSTHETIC SIMPLICITY AND CLEVER TRAY

- Consequently prosthetically oriented implant system
- Small tray with all instruments you need for implant placement
- Washtray function: validated for reprocessing
- Implant design for high stability in soft bone [1,2]

EXPERIENCE THE PROGRESSIVE EFFECT.



video animation

CURIOUS? PHONE +49 7044 9445 239

sales@camlog.com

www.camlog.com

References

- [1] Conserva E. Initial stability after placement of a new buttress threaded implant. A case series study. *implants*. 2019(3):24-28.
- [2] Ruppin J. One-year clinical experience with Progressive-Line implants. *EDI journal*. 2020(4):54-63.

camlog

 biohorizons
camlog

Delayed **immediate** implant placement and direct **soft-tissue** management

Dr Haki Tekyatan, Germany

In the case of implant planning, the preservation of soft tissue and bone is essential for functional and aesthetic long-term success. There are now various different techniques and materials available. The timing of implant insertion and soft-tissue shaping play a crucial role, as do the measures taken in advance of the planned therapy. A targeted strategy can generate favourable conditions before implant placement. In this context, the use of bone grafting materials in combination with intravenously collected autologous platelet concentrates (I-PRF and A-PRF) has become increasingly important in recent years. With this “biologisation” of specially developed bone grafting materials for alveolar management, stable preservation of the extraction socket and the bone can be expected while promoting wound healing. The greatest loss of bone and, as a result, soft tissue occurs in the first 12 months after tooth extraction. In the literature, loss rates of up to 60% are reported.³ In this regard, Tan et al. were able to show in a systematic review that six months after extraction there is a horizontal bone loss of 29–63% and a vertical bone loss of 11–22%. The transverse bone loss was found to be higher than the vertical bone loss.¹² This was also confirmed by Araujo and Lindhe in their animal studies. They found that the greatest changes to the alveolar process in the area of the buccal wall occurred within three to six months after tooth extraction.² In implant dentistry, these are limiting factors in daily practice. However, it is crucial to have sufficient hard and soft tissue both in quantity and in quality to achieve the goals of implant therapy.⁵

Preventive interventions can aid in counteracting bone loss and resorptive processes in order to preserve hard and soft tissue.⁷ In this regard, alveolar stabilisation is a method performed during or after tooth extraction to minimise external resorption of the alveolar process, preserve bone, and promote and support bone formation within the extraction socket.⁶ Various terms are used for this in the literature, such as alveolar ridge preservation (for three- or two-walled defects), socket preservation (for circularly intact alveoli), socket seal technique and alveolar preservation. The aim of these methods is to fill the fresh extraction socket with a bone grafting material and to achieve stabilisation of the alveolar walls.⁹ In this regard, the use of bone substitute materials biologised

with platelet-rich plasma (I-PRF and A-PRF) is described in the literature as a successful means to preserve bone and soft tissue and to support the healing process.^{8,11} In the following case report, socket preservation with CERASORB® Foam (curasan) and I-PRF (IntraSpin®, Bio-Horizons Camlog), obtained according to the Low Speed Centrifugation Concept (LSCC) of Prof. Shahram Ghanaati, was performed after extraction of tooth #12.¹⁵ Similar cases were reported by Palm et al. and Al-Nawas et al. in the past.^{13,14} The implant was positioned and inserted six weeks later on the basis of external planning (DEDICAM, CAMLOG) and using a surgical guide with depth stop (CAMLOG Guide System®). An intra-oral scan (Medit i500®, Kulzer) was performed intra-operatively, and the first surgical phase concluded with submerged healing. During this period, a new type of healing abutment was fabricated entirely from PEEK material. After a healing period of three months, this PEEK healing abutment was used directly after implant exposure in order to shape the peri-implant soft tissue optimally and atraumatically in a few treatment steps. Finally, the prosthetic restoration was realised with a ceramic-veneered CAD/CAM-fabricated crown.

Case report

A healthy 55-year-old female patient presented to the practice with an unsalvageable tooth #12. Clinically, the oral situation was unremarkable. The patient reported that the crown was loose and that it rotated slightly. She also reported pain on biting. The radiographic evaluation revealed that the tooth had been endodontically treated and restored with a metal post. Dislocation of the post and core with the crown and a deep fracture were detected, and the patient was informed accordingly (Figs. 1 & 2). A few days later, tooth #12 was extracted gently and atraumatically with the aim of preserving the alveolar walls as far as possible. Special periostomes and instruments (KLACK set®, Geistlich Biomaterials) were used for this purpose (Figs. 3 & 4). Since an implant restoration was planned in this case, it was decided in advance, and together with the patient, that appropriate measures for bone preservation should be taken. The condition of the alveolus after extraction is an important criterion for deciding which treatment protocol should be used, that is,

Our dental implants have
an outstanding survival rate

98%

With maintained marginal
bone after 5 years

0.3 mm



Stronger
than ever.
Thanks to
science.

After 30 years of research and more than 1,000 scientific publications, we can confidently say that Astra Tech Implant System® EV delivers life-long function and natural esthetics.

Thanks to science, our implants have an outstanding survival rate and a marginal bone maintenance far better than the industry standard.

If you are looking for endless possibilities and superior outcomes, this is the only system you need. Today and tomorrow.

Follow Dentsply Sirona Implants
for the latest in implant dentistry



dentsplysirona.com/implants



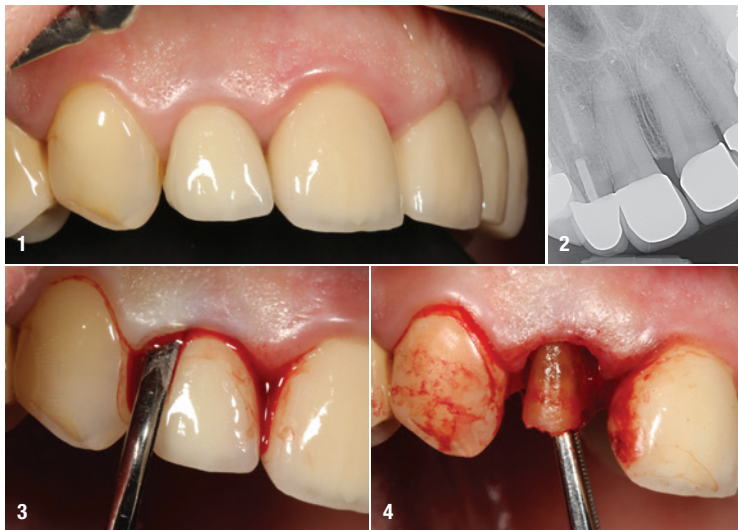

Fig. 1: Initial clinical situation of tooth #12. **Fig. 2:** Radiograph of tooth #12 showing failed endodontic treatment with the dislocated post restoration and deep complicated fracture. **Fig. 3:** Gentle detachment of marginal gingiva and periodontal ligament fibres using periostomes. **Fig. 4:** Atraumatic extraction of the tooth and the fractured fragment.

which bone grafting material with which resorptive properties should be used and when the implants should be placed. In the case described here, the alveolar bone could be preserved in all directions. The decision was made in favour of delayed immediate implant placement and the use of a bone regeneration material that is rapidly

resorbed and quickly incorporated into the autogenous bone.

Socket preservation was performed with a β -tricalcium phosphate collagen matrix (CERASORB Foam), which was biologised in advance with I-PRF (platelet-rich fibrin concentrate; Fig. 5). In its hydrated, biologised state, the collagen matrix can be excellently shaped and adapted to the alveolar walls under as little compression as possible (Figs. 6 & 7). The augmentation site was covered crestally and sealed with a compressed A-PRF plug (Fig. 8). The site was then stabilised by means of cross-suturing (Fig. 9). Tight covering using the socket seal approach and a tissue punch was not necessary in this context. The gap was temporarily restored with an interim prosthesis, which was designed as a pontic in order to shape the soft tissue (Fig. 10). Lastly, a control radiograph was taken, and the optimal defect filling and almost structurally identical distribution of the matrix could be noted on the radiograph (Fig. 11). After the treatment, irritation-free, stable and, above all, pain-free healing was observed. As a result, planning for implant placement by means of CBCT (Orthophos XG 3D, Dentsply Sirona) could be carried out after only three weeks (Figs. 12 & 13). To achieve optimal 3D axial positioning of the implant in the vertical, mesiodistal and orovestibular directions, the CBCT/DICOM data sets were sent to an external planning centre (DEDICAM) via a secure channel and a surgical guide (CAMLOG® Guide, SMOP®, Swissmeda) was fabricated (Figs. 14 & 15).

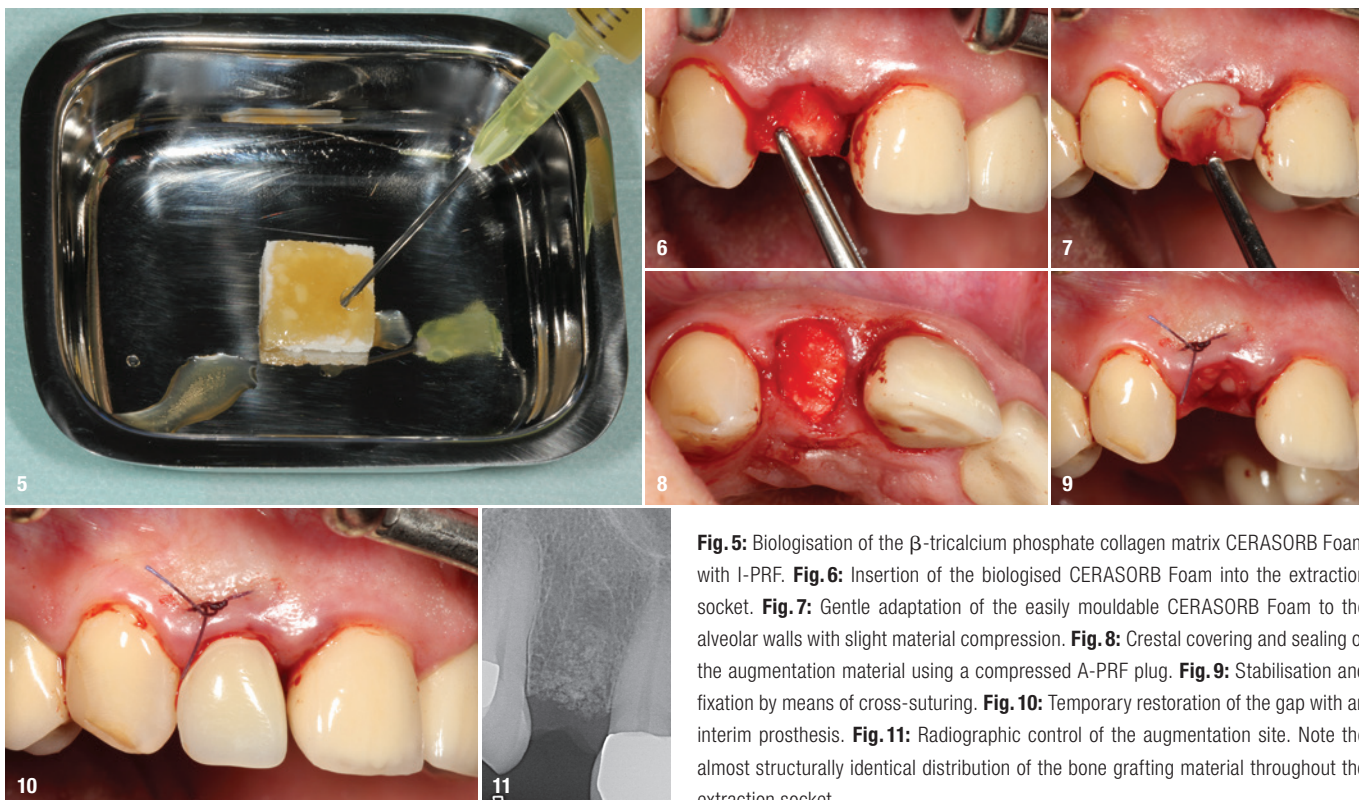


Fig. 5: Biologisation of the β -tricalcium phosphate collagen matrix CERASORB Foam with I-PRF. **Fig. 6:** Insertion of the biologised CERASORB Foam into the extraction socket. **Fig. 7:** Gentle adaptation of the easily mouldable CERASORB Foam to the alveolar walls with slight material compression. **Fig. 8:** Crestal covering and sealing of the augmentation material using a compressed A-PRF plug. **Fig. 9:** Stabilisation and fixation by means of cross-suturing. **Fig. 10:** Temporary restoration of the gap with an interim prosthesis. **Fig. 11:** Radiographic control of the augmentation site. Note the almost structurally identical distribution of the bone grafting material throughout the extraction socket.

An implant (CAMLOG PROGRESSIVE-LINE, CAMLOG; diameter: 3.8mm; length: 13.0mm) was chosen which would ensure sufficient high primary stability owing to its progressive thread design.

Six weeks after extraction and socket preservation, implant insertion in region #12 was performed under local anaesthesia. A crestal incision was made, and a flap was reflected in a minimally invasive manner. The surgical guide was put into position, and then the guide system and the 3.8mm drill set (CAMLOG) were used to prepare the osteotomy in several steps to the planned length of 13mm. Finally, guided implant placement was performed to a torque of 25Ncm (Figs. 16–18). After final positioning of the implant (Fig. 19), the insertion post was removed and a PEEK scan body (CAMLOG) with the same diameter of the implant (3.8mm) was inserted (Fig. 20). The implant and the jaws were then scanned intra-operatively (Medit i500® and Medit Link® software, Medit) to verify the position of the inserted implant (Figs. 21a & b). After scanning, the scan body was removed, the healing abutment was installed, the surgical site was tightly sutured for submerged healing and a dental panoramic tomogram (Orthophos XG 3D) was taken (Figs. 22a–c). During the healing phase of the implant, the scans were further processed for further planning (Fig. 23). The objective was to shape the soft tissue and to fabricate the definitive res-

toration in as few steps and as effectively as possible. Experience has shown that it is important to minimise insertion and extraction torque in order to protect and stabilise the peri-implant hard and soft tissue. This is essential for achieving long-term implant success, which, in the present case, was realised on the basis of the treatment protocol followed.

After an irritation-free healing phase of three months, the hard- and soft-tissue conditions were considered stable, and therefore the implant was exposed under local anaesthesia. Since the soft-tissue situation was considered quantitatively sufficient, the incision was made crestally. In collaboration with the external planning service centre (DEDICAM), a novel healing abutment was fabricated from PEEK during the healing phase and subsequently inserted. This one-piece healing abutment does not require further processing, thereby minimising possible sources of error and potential contamination (Fig. 24). The soft tissue was modelled in the coronal direction by means of a suspension suture, and the wound margins were fixed to the adjacent teeth by means of vertically modified backsuture (Fig. 25). Finally, a control radiograph was taken, and the interim prosthesis was adapted to the new situation (Fig. 26). With the customised healing abutment and the corresponding emergence profile, the soft tissue was entirely shaped within

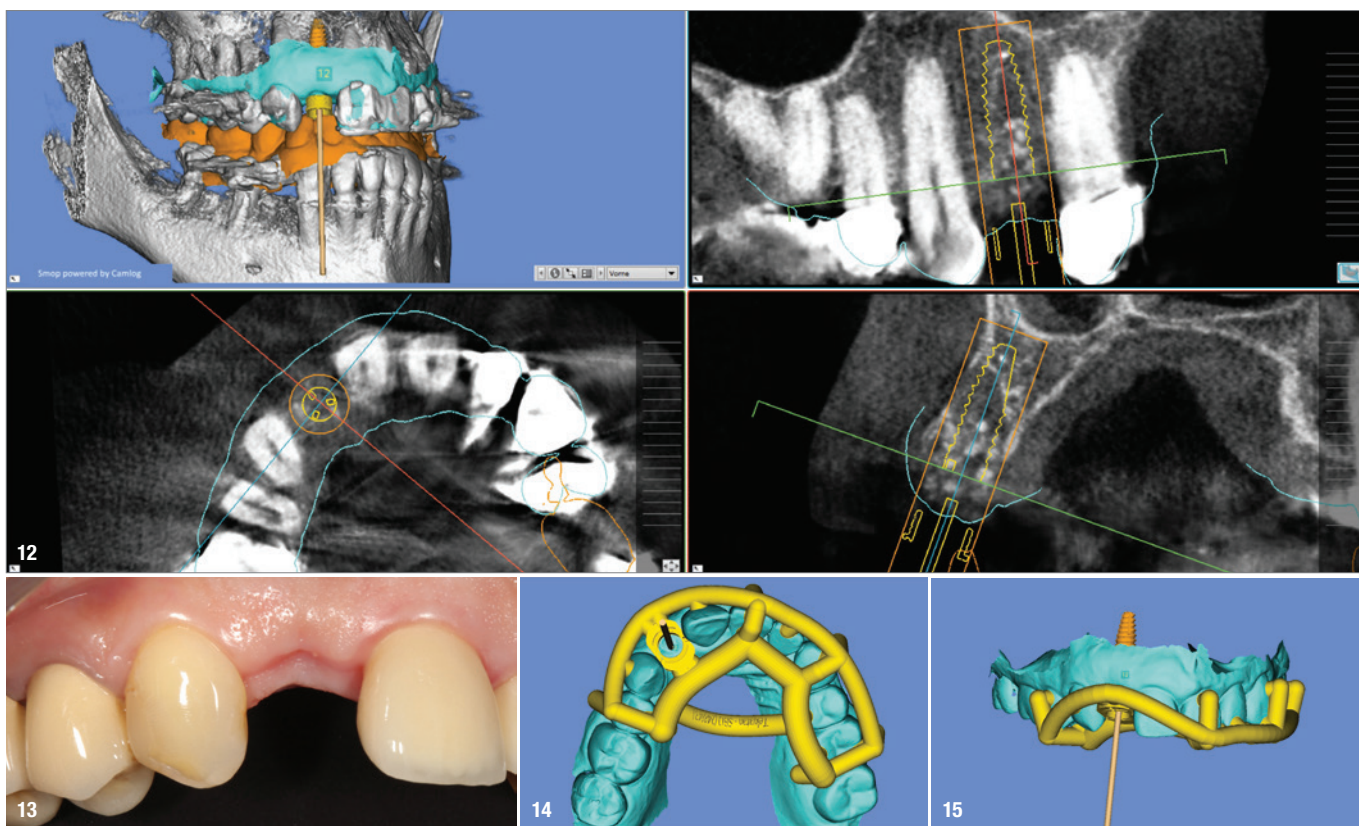


Fig. 12: Evaluation of 3D diagnostics showed sufficient stable bony conditions in all directions. **Fig. 13:** Clinical situation before implant placement. **Figs. 14 & 15:** Planning of the surgical guide (CAMLOG Guide), vertical and ventral views.