

DENTAL TRIBUNE

— The World's Dental Newspaper · Middle East & Africa Edition —

PUBLISHED IN DUBAI

October 2010

No. 8 VOL. 8



News & Opinions
CEO of VOCO: "Foreign markets are very important to us"
▶ Page 3



Media CME
Sedation: management of risk
▶ Page 6



Practice Matters
Complex reconstruction changes a patient's life
▶ Page 9

GlaxoSmithKline to Pay \$750 Million in Federal Health Care Fraud Settlement

GlaxoSmithKline has agreed to plead guilty and pay a massive fine totaling \$750 million to the federal government and the states to resolve allegations that the company caused false claims to be submitted to government health care programs for certain quantities of adulterated Kytril, Bactroban, Paxil CR and Avandamet.

The company had said in July it reached an agreement in principle relating to quality problems at its SB Pharmco Puerto Rico Inc's plant and would pay about \$750 million to resolve the allegations.

Of the \$750 million, Glaxo will pay \$600 million to settle allegations that, because the drugs were adulterated, false claims for reimbursement were submitted to government healthcare programs. -The drugs -- the anti-nausea medicine Kytril, skin ointment Bactroban, anti-depressant Paxil CR and diabetes drug Avandamet -- were made at the plant between 2001 and 2005.

The company was accused of failing to ensure the drugs were properly manufactured at the plant and thus effective, according to the Justice Department.



Under the plea agreement, SB Pharmco Puerto Rico will plead guilty to a felony of releasing adulterated medicines and pay a \$150 million criminal fine that includes forfeiture of \$10 million in assets.

Asked during a news conference if the actions by the company were intentional, Carmen Ortiz, the U.S. Attorney for Massachusetts, said that was the government's contention.

"They received warning letters from the FDA and yet they went ignored," she told reporters. Ortiz also said the investigation into individuals was "ongoing."

A whistleblower who filed a lawsuit under the U.S. False Claims Act will receive about \$96

million from the federal share of the settlement, the Justice Department said.

A federal judge must approve the plea agreement.

Glaxo expressed regret that its factory did not operate within the necessary standards and practices.

"GSK worked hard to resolve fully the manufacturing issues at the Cidra facility prior to its closure in 2009 and we are committed to continuous improvement in our manufacturing processes," PD Villarreal, the

→ DT page 2

UAE kids miss out on dental checks

The head of Dubai Dental Services of the United Arab Emirates' (UAE) Ministry of Health Dr Aisha Sultan has called on the central government in Abu Dhabi to increase spending on preventive oral-health programmes.

She said that while other Middle Eastern countries like Bahrain have successfully implemented such programmes, the UAE still lacks political will to introduce regular dental checks of schoolchildren, especially in the country's neglected Northern rural areas.



According to the results of a national oral health survey conducted in early 2010, caries is highly prevalent in the primary dentition of most five year-old children living in the UAE.

It also found that only 17 per cent of all children were complete caries free. [1]

Stem cell bank opens in Mumbai

Health care consulting company Gencoval Strategic Services in India has announced its partnership with a French biomedical institute to open the first dental stem cell bank in Mumbai. The new company Stemade Biotech will use a patented technology from Institute Clinident BioPharmain Aix-en-Provence in France

to extract and preserve Dental Pulp Stem Cells derived from primary and wisdom teeth under cryogenic conditions for various therapeutic applications in the future, company officials said.

The latest research has indicated that adult stem cells, which can also be extracted from bone marrow and other parts of

the human body, have the potential to treat non-communicable diseases like cancer or heart disease and to repair or regenerate entire organs. Dental Pulp Stem Cells have been found to form at least 29 different unique tissues, including dental enamel, dentine, blood vessels and nerve cells. [1]

AD

PROMEDICA

Highest quality made in Germany

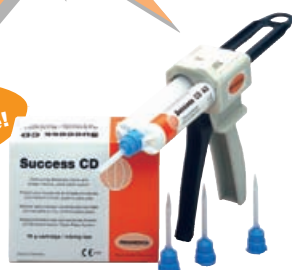- ▶ high quality glass ionomer cements
- ▶ first class composites
- ▶ innovative compomers
- ▶ modern bonding systems
- ▶ materials for long-term prophylaxis
- ▶ temporary solutions
- ▶ bleaching products...

All our products convince by

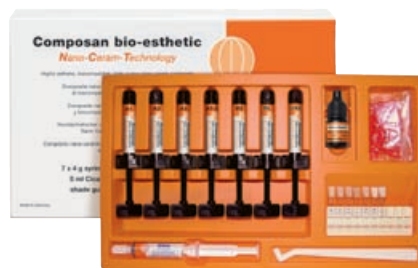- ▶ excellent physical properties
- ▶ perfect aesthetical results

Meet us at several exhibitions - www.promedica.de

New: Bleach Shade!

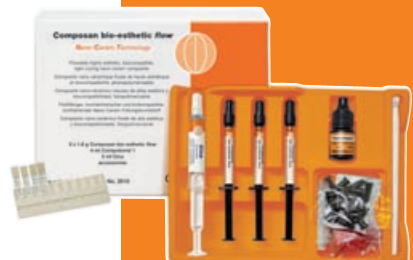

Temporary crown and bridge material
• particular fracture and wear resistance
• now available in 6 attractive shades



Light-curing nano-ceram composite
• universal for all cavity classes
• comfortable handling, easy modellation
• highly esthetic and biocompatible

Nano-Ceram-Technology



• exact match of translucency and shade to the packable Composan bio-esthetic



Resin-reinforced glass ionomer luting cement
• strong adhesion, very low film thickness
• especially suited for zirconia-based pieces

PROMEDICA Dental Material GmbH

Tel. +49 4321 / 54173 · Fax +49 4321 / 51908

Internet: <http://www.promedica.de> · eMail: info@promedica.de

PROMEDICA

Dental seminar in Dubai highlights risks of gum disease, gathers 350 dentists

Benefits of clinically proven Parodontax toothpaste demonstrated during event; Around 50 per cent of worldwide population suffer from gum problems

Editorial Board

Prof. Abdullah Al-Shammary, Restorative Dentistry, KSA
Prof. Hussain F. Al Huwaizi, Endodontics, Iraq
Prof. Samar Burgan, Oral Medicine, Jordan
Dr. Abdel Salam Al Askary, Implantology, Egypt

Dr. Talal Al-Harbi, Orthodontist, Qatar
Dr. Mohammed H. Al Jishi, Bahrain
Dr. Lara Bakaeen, Prosthodontist, Jordan
Dr. Aisha Sultan, Periodontist, UAE
Dr. Kamal Balaghi Mobin Aesthetics, Iran

DENTAL TRIBUNE

The World's Dental Newspaper - Middle East & Africa Edition

Published by Education Zone

in licence of Dental Tribune International GmbH

© 2010, Dental Tribune International GmbH. All rights reserved.

Dental Tribune makes every effort to report clinical information and manufacturer's product news accurately, but cannot assume responsibility for the validity of product claims, or for typographical errors. The publishers also do not assume responsibility for product names or claims, or statements made by advertisers. Opinions expressed by authors are their own and may not reflect those of Dental Tribune International.

President/CEO Yasir Allawi
y.allawi@dental-tribune.ae

Director mCME: Dr. D. Mollova
info@cappmea.com

Marketing manager Khawla Najib
khawla@dental-tribune.ae

Production manager Hussain Alvi
dentalme@dental-tribune.ae

PO Box 214592, Dubai, UAE, Tel + 971 4 391 0257
Fax + 971 4 366 4512 www.dental-tribune.com



(From Left to Right): Bahiya Shamsedin, Emirates Medical Association Member, Dr. Philippe Tardieu - Alabama Dental Clinic, Dr. Aysha Sultan - President of the Dental Society - Emirates Medical Association, Dr. Ramesh Bulbule - Scientific Committee, Dental Society - Emirates Medical Association, Dr. Pratima Vartak - Endodontist, Dr. Bassam Kinaia, Director, Department of Periodontology, Boston University Institute for Dental Research & Education

GlaxoSmithKline (GSK) Consumer Healthcare highlighted the benefits of its Parodontax toothpaste, which has been specifically formulated to address the problem of bleeding gums, during the dental conference and lecture it organised in Dubai in association with the Dental Society of the Emirates Medical Association at the Murooj Rotana Hotel. As daily toothpaste containing mineral salts and six natural herbs extracts, the clinically proven Parodontax helps stop bleeding gums, strengthen gum tissue, and fights plaque and tooth decay.

More than 350 dentists from the UAE gathered at the conference in Dubai, which featured discussions on gum disease, periodontics and dental hypersensitivity, and particularly focused on the risks associated

with ignoring bleeding gums. The event, accredited by the UAE Ministry of Health, served as a platform for dental experts to share best practices with regard to the latest gum disease treatment techniques, in addition to serving as a forum to discuss pertinent issues, trends and solutions. GSK Consumer Healthcare-Parodontax has been organising such conferences to create greater awareness about gum problems as statistics reveal that around 50 per cent of the population worldwide suffer from gum problems.

Periodontics was a key subject of discussion at the day-long seminar given the increasing cases of periodontal disease around the world. Periodontal disease is a chronic inflammatory disease that affects the gum tissue and other structures supporting the teeth. If left untreated, it can lead to tooth loss, and may also interfere with other systems of the body. [11](#)

← DT Page 1

company's head of global litigation, said in a statement.

Villarreal said the plant was closed because of declining demand for the medicines made there, and that the company no longer owned the facility

The federal government argues that "GSK sold certain batches, lots or portions of lots of drugs," that possessed a strength, purity or quality "which fell materially below" that which was specified in the drugs' FDA applications. Consequently, the government says GSK "knowingly caused false and/or fraudulent claims to be submitted" to

Medicaid and other federal health care programs.

"Adulterated drugs undermine the integrity of the FDA's approval process, can introduce substandard or ineffective drugs on to the market and, in the worst cases, can potentially put patients' health at risk," said Tony West, Civil Division Assistant Attorney General for the Department of Justice.

The Justice Department says this settlement is part of the government's ongoing effort to battle health care fraud under the False Claims Act. The law has helped the government to recover \$4.2 billion in cases related to federal health care fraud since January 2009. [11](#)

AD

Under the patronage of
H. H. Sheikh Hamdan Bin Rashid Al Maktoum
Deputy Ruler of Dubai, Minister of Finance
President of the Dubai Health Authority

هيئة الصحة بدبي
DUBAI HEALTH AUTHORITY

DUBAI 2011
1-3 February
Dubai International Convention & Exhibition Centre

Supported by
fdi

"Delivering Science & Technology"

15th Anniversary

UAE INTERNATIONAL DENTAL CONFERENCE & ARAB DENTAL EXHIBITION

"Where Oral Health Professionals Meet"







- Keep up to date with the newest developments and techniques in dentistry through a series of lectures and specialized courses
- Enhance your dental practice with various management and clinical workshops
- Learn the optimal prevention and treatment services in the field of dental traumatology
- Visit 20,000 sqm. of exhibition space and explore the latest innovations and business practices
- Enjoy a panoramic view from Burj Khalifa, the world's tallest tower
- Ride the Metro and see Dubai !

www.aeedc.com

Organised by



Strategic Partner



Supported by








INDEX® Conferences & Exhibitions Organisation Est.
P.O. Box: 13636 | Ibn Sina Bldg. #27 Block B, Office 203, Dubai Healthcare City | Dubai - United Arab Emirates
Tel: +971 4 3624717 | Fax: +971 4 3624718 | E-mail: aeedc@index.ae | Website: www.index.ae

“Foreign markets are very important to us”

An interview with Olaf Sauerbier, CEO of VOCO GmbH, Cuxhaven, Germany

VOCO, based in Cuxhaven on the northern coast of Germany, is an established international provider of high-quality dental materials. In addition to products for restorative dentistry, it offers a wide range of materials and preparations for the fields of prosthetics and prophylaxis. Dental Tribune Group Editor Daniel Zimmermann spoke with Olaf Sauerbier, CEO and chief of Marketing and Sales, about new products and aesthetic trends in restorative dentistry.

Daniel Zimmermann: The Association of Dental Dealers in Europe (ADDE) has recently predicted growth rates above 3 per cent for most European dental markets. Do you see any signs of recovery in your company?

Olaf Sauerbier: To be honest with you, the recession never really caught us. We usually tend to perform slightly better than the overall market and expect to be no different for this business year. The year 2010 started off better than last year ended, and we saw some significant growth in most of our business segments in the first and second quarters.

Although we have invested significantly in our German businesses by extending our sales team by 15 new employees, foreign markets are very important to us. At the moment, we are expanding our existing businesses worldwide, especially in North America. It will be a while before we are able to take full advantage of the enormous potential this market has to offer.

Did the products you introduced two years ago at IDS Cologne meet your expectations?

The most important product we introduced at IDS in terms of sales was definitely the non-run, non-drip NDT syringe. This new delivery form helped us to increase sales of most of our highly flowable materials like Grandio Flow, Grandio Seal and Ionoseal. Our gingiva-shaded restoration system Amaris Gingiva has also shown good performance. We have to admit that the market for such a product is still small but, on the other hand, we see the demand for aesthetic restorations of exposed necks of teeth increasing owing to demographic changes and people ageing. Those who have highly aesthetic requirements will find it hard to pass this product by.

Another bestseller has been the one-component, light-curing, nano-reinforced, self-etch bond Futurabond M that we launched in SingleDose and in a three-bottle value pack. Not to forget the Reblida Post System, an award-winning complete sys-

tem for placing 15 posts in post-endodontic treatment, that sold successfully in Germany and abroad within a short amount of time.

AD

Some segments in dentistry, dental implants in particular,

→ DT page 5



Olaf Sauerbier (left) in talks with DT Group Editor Daniel Zimmermann. (DTI/Photo Antje Kahnt, DTI)

E MODULUS

ABRASION

CONSISTENCY

الكومبوزيت الممتاز

Grandio® - الكومبوزيت الناجح عالمياً. استُخدم و اختبر ملايين المرات , يتميز بمعامل مرونة مشابه للعاج, ومقاومة فائقة للاهتراء للوصول إلى ترميمات ذات ديمومة طويلة. يسمح القوام الأملس لكومبوزيت Grandio® إضافة لخاصية عدم الالتصاق بالأدوات العمل بشكل مريح واقتصادي مع كل أصناف الحفر السنّية . اطلب النشرة العلمية الخاصة بـ Grandio®.

Grandio





ANNUAL DENTAL TRIBUNE STUDY CLUB

SYMPOSIA AT THE GNYDM

NOVEMBER 28 – DECEMBER 1, 2010, 10:00 AM DAILY



For the third year in a row, the DTSC hosts its annual CE Symposia at the GNYDM, offering four days of focused lectures in various areas of dentistry. Find us on the Exhibition Floor in Aisle 6000, Room # 3.

Each day will feature a variety of presentations on topics, which will be led by experts in that field. Participants will earn ADA CERP CE credits for each lecture they attend. DTSC is the official online education partner of GNYDM.



PLEASE SEE PROGRAM DETAILS UNDER WWW.DTSTUDYCLUB.COM/GNYDM

REGISTER NOW: WWW.GNYDM.COM

FREE FOR REGISTERED GNYDM ATTENDEES, BUT PRE-REGISTRATION IS RECOMMENDED.

For more information, please contact Julia E. Wehkamp, C.E. Director, Dental Tribune Study Club
Phone: (416) 907-9836, Fax: (212) 244-7185, E-mail: j.wehkamp@DTStudyClub.com

SUNDAY, NOVEMBER 28

10:00 - 11:00 Howard Glazer, DDS, FAGD
BEAUTIFIL: GO WITH THE FLOW - COURSE: 3020

11:20 - 12:20 John Flucke, DDS
LIGHT CURED ADHESIVE DENTISTRY - SCIENCE AND SUBSTANCE - COURSE: 3030

1:20 - 2:20 Martin Goldstein, DMD
A SIMPLIFIED APPROACH TO MULTI-LAYER DIRECT COMPOSITE BONDING - COURSE: 3040

2:40 - 3:40 Jay Reznick, DMD, MD
3D IMAGING AND CT-GUIDED DENTAL IMPLANT SURGERY - 3050

4:00 - 5:00 Louis Malcmacher, DDS, MAGD
TOTAL FACIAL ESTHETICS FOR EVERY DENTAL PRACTICE - COURSE: 3060

MONDAY, NOVEMBER 29

10:00 - 11:00 Mrs. Noel Brandon-Kelsch
ECO-FRIENDLY INFECTION CONTROL-UNDERSTANDING THE BALANCE - COURSE: 4120

11:20 - 12:20 Gregori Kurtzman, DDS
INCORPORATING NEW ADVANCES IN DENTAL MATERIALS AND TECHNIQUES INTO YOUR RESTORATIVE PRACTICE - COURSE: 4130

1:20 - 2:20 Damien Mulvany, DDS
OPTIMIZING YOUR PRACTICE WITH 3D CONE-BEAM TECHNOLOGY - COURSE: 4140

2:40 - 3:40 Edward Katz, DDS
IMPROVING PATIENT CARE WITH 3D CONE BEAM COMPUTERIZED TOMOGRAPHY - COURSE: 4150

4:00 - 5:00 George Freedman, Fay Goldstep and Edward Lynch
SOFT TISSUE LASERS AND CARIES DIAGNOSIS - COURSE: 4160

TUESDAY, NOVEMBER 30

10:00 - 11:00 George Freedman, Fay Goldstep and Edward Lynch
SOFT TISSUE LASERS AND CARIES DIAGNOSIS - COURSE: 5110

11:20 - 12:20 Greg Diamond, DDS
LASERS IN PERIODONTAL THERAPY - COURSE: 5120

1:20 - 2:20 Dov Almog, DMD
INTRODUCTION TO CONE BEAM CT (CBCT), ESPECIALLY AS IT PERTAINS TO PREVENTION OF FAILURES IN ORAL IMPLANTOLOGY - COURSE: 5130

2:30 - 3:30 Maria Ryan, DDS, PhD
DETECTING CORONARY HEART THROUGH PERIODONTITIS AND PERIIMPLANTITIS - COURSE: 5140

4:00 - 5:00 Dwayne Karateew, DDS
CONTEMPORARY CONCEPTS IN TOOTH RELACEMENT: PARADIGM SHIFT - COURSE: 5150

WEDNESDAY, DECEMBER 1

10:00 - 11:00 Mr. Al Dube
BEST MANAGEMENT PRACTICE, WASTE MANAGEMENT FOR THE DENTAL OFFICE, AND OSHA COMPLIANCE - COURSE: 6060

11:20 - 12:20 Glenn van As, DMD
HARD AND SOFT TISSUE LASERS - COURSE: 6070

12:45 - 4:45 Dr. Benedict Bachstein, Dr. David Hoexter, Dr. Jeffery Hoos, Dr. Dwayne Karateew, Dr. Enrique Merino, Dr. Ethan Pansick
THE FIRST ANNUAL OSSEO UNIVERSITY SUMMIT: IMPLANT DRIVEN DENTISTRY - COURSE: 6080

THIS PROGRAM IS SUBJECT TO CHANGE

←DT Page 3

have shown decreasing sales. What is the situation in the market segments you are involved in?

The recession might have had devastating effects on companies offering upscale materials and equipment but the situation in restorative and preventative dentistry looks far more promising. In the segments in which we are actively involved, such as prosthetics, prophylaxis or dental cements, we have been able to achieve growth rates between 10 and 20 per cent.

Filling materials did not perform very well owing to increased market competition. There are plenty of new and innovative filling materials on the market right now and we have to invest a great deal in order to stay ahead with new developments and products.

What current trends have you observed in the industry?

All manufacturers are striving for a product that offers almost ideal properties for a filling material and exhibits the same physical properties as natural tooth substance. All our competitors are moving towards this ideal but I see us far ahead. We have been working with nanotechnology since the early 2000s and based on the results of this launched our first nano-hybrid composite Grandio in 2003. This product is still in high demand in Germany and many other markets.

But we did not stop there. With GrandioSO, we are now able to present another nano-hybrid composite to the dental community that has outperformed our original expectations. In terms of its physical properties, it is probably the most tooth-like material on the market.

When and where will it be available?

It is already available in Germany and other selected European markets. Like its predecessor, GrandioSO is universally applicable but a little more translucent, so it can be used for restorations in the maxillary anterior region.

We will still offer Grandio to our customers worldwide. In the end, it is the dentists who decide which product they prefer.

Do aesthetics play a more prominent role in the development of a composite like GrandioSO?

The primary goal is function. There is a place for aesthetics too, but it must not compromise functionality or the stability of the filling. There are different points of view in dentistry regarding this matter right now but for us the primary goal cannot be highly opaque teeth that might be currently en vogue amongst Hollywood stars. In the US, for example, we found that dentists were using the white opaque shade of our flowable composite Grandio Flow for anterior restorations, as this is the typical

shade of highly bleached teeth in the US. Normally, we recommend it only be used to whiten dark spots or in cases in which dentists absolutely need an opaque layer.

This is not the direction we wish to take. Teeth have a natural translucency and we want to keep it that way. I believe that with our current portfolio we offer dentists viable solutions to achieving long-lasting and natural aesthetic restorations.

Some European companies develop their products especially for the North American market. Do you do the same?

We sell exactly the same products in North America as we sell in Europe. Usually, most products are launched there six months after they have been placed on the European markets. The only difference is the type of shade. In Germany, for example, the majority of dentists use Shade A3.5, which does not play any significant role in markets like the

US, where Shade A2 is more common.

Will GrandioSO be the main focus of your presentation at IDS next year and are you planning to introduce more products there?

GrandioSO will indeed be the main focus of our IDS presentation, but there are other products that we plan to launch this month and at IDS 2011.

Thank you very much for the interview.



Aerial view of the VOCO headquarters in Cuxhaven in Germany.

AD



EMS
ELECTRO MEDICAL SYSTEMS

EMS-SWISSQUALITY.COM

SUBGINGIVAL WITHOUT LIMITS

THE DEEPEST PERIODONTAL POCKETS NOW WITHIN REACH WITH THE ORIGINAL AIR-FLOW METHOD



> Subgingival application of the Original AIR-FLOW® method reduces periodontal pocket depth, removes biofilm, prevents periimplantitis

AIR-FLOW MASTER® is the name of the world's first subgingival prophylaxis unit. With two application systems in one. For sub- and supragingival use with matching handpiece and powder chamber.

Incredibly easy to operate. Uniquely simple to use.

Touch 'n' flow: Highly sensitive 3-touch panel for easy choice of settings.



The inventor of the Original Air-Flow Method is now first to cross the boundaries of conventional prophylaxis.

"I FEEL GOOD"

For more information > welcome@ems-ch.com

AIR-FLOW® KILLS BIOFILM

ems-swissquality.com



Sedation: management of risk

Dental sedation is a safe and effective method of anxiety control for patients undergoing dental treatment but you need to have the proper procedures in place, says Dental Protection

(mCME articles in Dental Tribune (always page 6) has been approved by HAAD as having educational content acceptable for (Category 1) CME credit hours. Term of approval covers issues published within one year from the distribution date (September, 2010). This (Volume/Issue) has been approved by HAAD for 2 CME credit hours.

Sedation can be provided by using drugs in several ways such as oral, inhalation or intravenous delivery, although each has its own merits and risks. Sedation is considered to lie within the skill of a general practitioner who has received appropriate postgraduate training.

Nervous patients

Some patients find it difficult and distressing to accept even the most routine of dental procedures when fully conscious and aware. Other patients, who will normally have no difficulty in accepting routine procedures, might feel the need for sedation when undertaking more complex or lengthy procedures. Certain surgical procedures, complex prosthodontics or endodontics might fall into this category.

Sedation has been linked in the past to dental anaesthesia. However, the move in most countries is away from the provision of general anaesthesia for most primary dental care procedures and, where it is deemed appropriate to provide it, to do so in specialist centres staffed by experienced medically qualified specialist anaesthetists with appropriate postgraduate training, and supported by experienced nursing and recovery teams who have received specific training in the field of dental sedation.

Many drugs used in sedation have the potential to induce anaesthesia. It is therefore important that dentists practising sedation should ensure that the drugs and techniques used carry a margin of safety sufficient to render the loss of consciousness highly unlikely. There are very strict requirements relating to the provision of general anaesthesia in many countries and dentists have had difficulties in the past when a patient undergoing sedation has lapsed into inadvertent anaesthesia. In general, a dentist should be able to maintain verbal contact with a sedated patient at all times.

One precaution which has been adopted in many countries, is the stipulation that only a single sedative drug should be used, thereby avoiding the possibility of a potentiation (exaggerated) effect that could occur when more than one drug is used. With this in mind, the need for an up to date written medical history, with all current medica-

tions recorded, is essential in order to avoid any interaction with, or potentiation of the patient's normal medication.

In most jurisdictions, dentists who provide sedation are required to undertake postgraduate training and to maintain a contemporary level of knowledge. Regular refresher courses in cardio-pulmonary resuscitation techniques should involve all members of the dental team, and training of the whole dental team under simulated conditions, in preparation for a possible real emergency, is an excellent risk management strategy. A log should ideally be kept of all such training for each member of the team.

Consent

Practitioners should take adequate steps to ensure appropriate consent for the sedation procedure itself, in addition to the treatment to be provided. Problems have arisen where patients have had additional treatment carried out under sedation without their prior knowledge and agreement.

The more accurate the diagnosis and the fuller the discussions prior to treatment, the less potential there is for additional treatment to become immediately necessary while the patient is still sedated; consequently, the less likely the patient will be to complain about a lack of consent.

In some parts of the world, the decision to provide additional treatment in such situations may not be accepted as appropriate, even if taken with the best interests of the patient in mind.

Patients have the right of autonomy, which they do not forego simply because they happen to be sedated when their treatment is carried out. Such a situation is more easily accepted in an emergency or where a patient would quite clearly be worse off, if left in pain for example. It is not always possible to establish the precise treatment

plan in advance of the patient being sedated. Because of this, a full discussion should take place with the patient, indicating that this might be the case and the patient's views should be sought in advance – particularly in respect of any treatment options that they specifically wish to avoid.

The obvious difficulty in obtaining a valid consent from a sedated patient, makes it a sensible precaution (and a formal requirement in some countries) that the patient's consent to both the sedation itself, and to the specific treatment to be carried out under sedation, is confirmed in writing in advance of the procedure.

Side effects

Clinicians sometimes overlook the mood modification that occurs when sedative drugs are used in dentistry. The pharmacological effect leaves the patient with a state of mind that is not entirely normal. Although the patient can still respond to their environment, and to the commands of others following the administration of conscious sedation, the higher level neurological functions are markedly altered.

Most sedative drugs cause a loss of inhibition and some are hallucinogenic. That is the nature of their action. The scientific literature contains no authoritative evidence, including randomised control trials, to establish the frequency of sexual fantasies. Such evidence that does exist suggests that about one in two hundred patients may experience erotic dreams. The benzodiazepines are the drugs most commonly implicated in this phenomenon, but they are by no means the only ones.

The dento-legal risk that results from the above is self-evident; allegations of sexual impropriety can have devastating consequences for a healthcare professional, and the media interest is always very

high. There have been many such cases around the world which have been associated with dental treatment provided under sedation.

Whilst sexual hallucination can be disturbing, it is not a common side effect. A balanced judgement has to be made for each patient as to whether or not this possibility has the potential to be significant, and if so, whether it is prudent to treat the patient under sedation, or indeed at all.

It is particularly useful to provide the patient with an information sheet. Not only should this explain what to do and what not to do before and after conscious sedation, but it should also explain the nature of the procedure and the processes involved, as well as the benefits and risks. A further section of the text can explore frequently asked questions.

This is also a good opportunity to explain that the effects of conscious sedation are similar to the effects of alcohol. Following from this it is useful and entirely appropriate to explain to the patient that they may dream, that some dreams can be vivid and intense, and that very occasionally, the dreams can be of a sexual nature.

Chaperonage

The presence of an appropriate third party goes a long way to protect the practitioner from allegations of indecent assault. Whenever this sort of procedure is being carried out there should be a strict rule that no practitioner is ever left alone with the patient:

- Not even for a short time
- Not during administration of the sedative drug
- Not during the patient discharge following recovery
- Not at any time in between

There should be no deviation from this rule and only careful staff training can ensure that this is the case on every occasion.

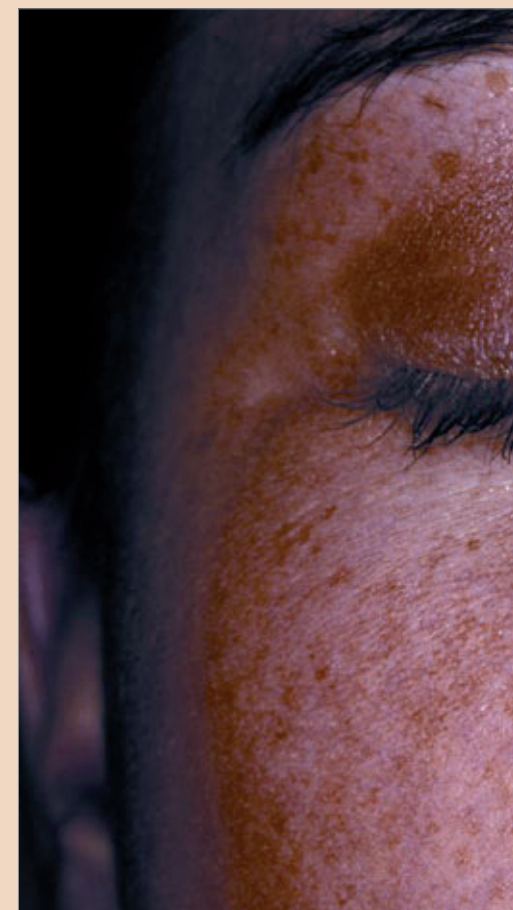For example, once the sedative has been administered it is inappropriate for the chaperoning dental nurse to leave the surgery or to move out of sight of the patient and dentist within the surgery. This applies even for the briefest period of time and for any reason that might cause the nurse to be temporarily out

of view (retrieving instruments or materials and any other duties away from the chair). Systems need to be developed such that if the situation should arise that extra equipment and materials are required from a site beyond the immediate surgery, then a third person should be summoned to obtain these.

Drugs must be used with care and consideration. There is evidence to suggest that higher doses of sedative drugs tend to increase the incidence of sexual hallucination. Frequent use of high dose sedative regimes is likely to increase the risk of alleged sexual assault.

Recovery

Once the operative procedure has been completed, the patient will on most occasions still display a residual level of sedation and will need time for further recovery before discharge or transfer to nursing care. Again the patient must be fully chaperoned throughout this stage. The dental nurse/assistant must not leave the dentist alone with the patient at any time. When moving the patient to dedicated recovery facilities, the patient should be transferred either by trolley or should be able to walk themselves with the minimum of supervision. It is inappropriate for the patient to require support from both the dentist and the dental nurse in the transfer process. Not only is the patient inad-



Make sure you follow best practice procedures for the sedation

'The dento-legal risk that results from the above is self-evident; allegations of sexual impropriety can have devastating consequences for a healthcare professional, and the media interest is always very high'

equately recovered to be transferred by this method, but this method of transfer produces an unacceptable level of close body contact, which has the potential to be misinterpreted.

Once in the recovery area, the patient should be monitored and accompanied by a responsible adult at all times. The patient should not be left alone with the dentist just 'popping in' to monitor the patient. The recovery period is one of the most frequently cited times of an alleged sexual assault, and a patient should be continuously and closely monitored by an appropriately trained person, taking account of any chaperonage issues.

Supervision

A patient who has been sedated, even after allowing sufficient time in a supervised recovery environment under the care of suitably trained and experienced personnel, should be accompanied from the practice by a responsible adult.

Under no circumstances should such patients be allowed to drive a motor vehicle, or operate any machinery or appliances unsupervised for an extended period (of several hours at least) after the administration of the sedation.

Such arrangements should be agreed with the patient in advance of the sedation appointment, supplemented by written preoperative instructions to this effect.

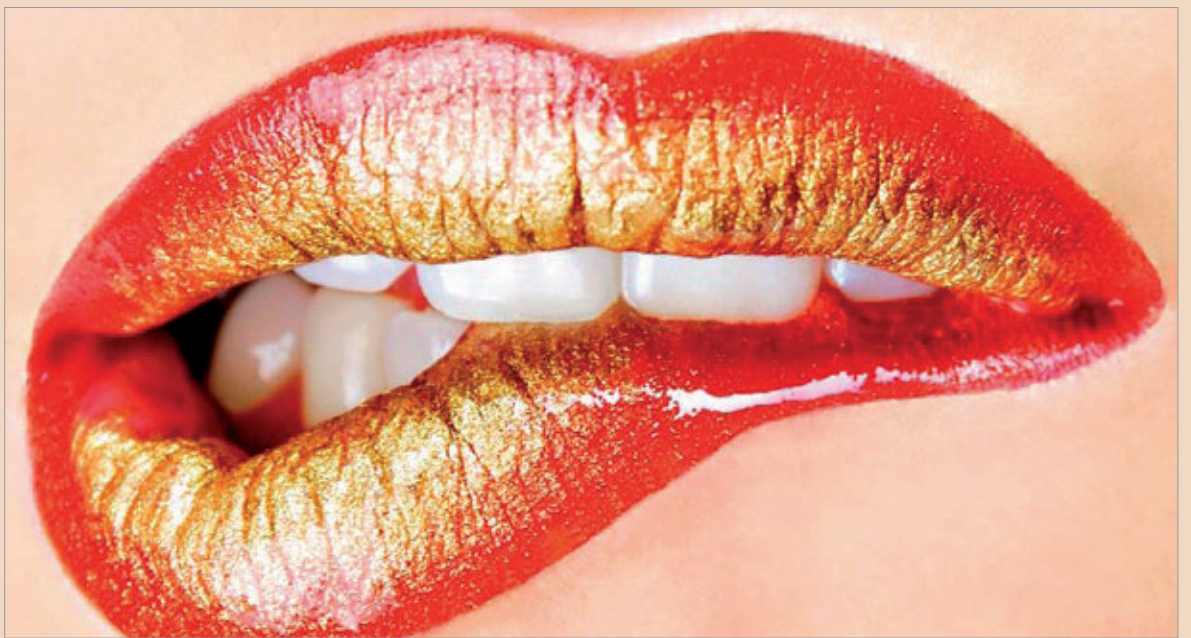It is certainly unwise to proceed with any treatment under sedation, unless and until the relevant accompanying person is physically on the practice

premises and intending to remain so. Situations have arisen in the past when such accompanying adults have never materialised at all, leaving the practice team in the invidious position of having to arrange for the same transit of the patient to their home, as well as for their subsequent supervision.

The record

The clinical records should include an up to date medical history, any referral correspondence, details of the consent process, and any pre-operative and post-operative instructions given to the patient. A carefully completed record of the sedation procedure itself is not only an essential component of good patient care, but it can prove invaluable in defending any allegation of improper conduct. Along with patient identification details, there should be a note of the patient's weight and their risk grouping - as defined by the American Society of Anesthesiologists, for example. The identity of every member of the operating team should be clearly stated in the notes, as should any drugs that were used (together with a record of their batch numbers).

It is important not only to record how much drug has been given but also when it was given and how quickly. This information can be used to justify the dose of drug used in a particular patient. Whilst sedative drugs are given in dosages loosely based on body weight, conscious sedation drugs used in dentistry are often titrated to the patient's individual needs. The clinical notes should also contain an indication of the quality of sedation, the level of sedation and patient's response to the



Giving patients advice sheets on sedation should help allay any concerns the patients may have

'Under no circumstances should such patients be allowed to drive a motor vehicle, or operate any machinery or appliances unsupervised for an extended period (of several hours at least) after the administration of the sedation'

procedure. Any subjective signs such as restlessness or a distinct change in the patient's demeanour should also be noted, particularly where the loss of inhibition is marked.

The records should include the name of the person into whose care the patient is entrusted on leaving the dental surgery premises.

Supporting staff

In the past, it was not unusual for a single dentist to act as both operator and sedationist/ anaesthetist. It is now widely accepted that such a practise does not al-

low an appropriate degree of focus and attention, to allow each of the two roles to be carried out to a necessary high standard of care. In some countries, and particularly where it is commonplace for health commissions to operate in rural or remote settings, inhalation sedation techniques such as relative analgesia (nitrous oxide/oxygen) are still considered appropriate for use by a single operator.

In all cases, however, sedation procedures become safer and more predictable when the dentist is assisted by nursing staff who have received specific training in dental sedation and in recovery procedures.

Amnesia

Many of the drugs used for dental sedation have the potential to create an amnesiac effect. Although this is often a significant advantage, it can also create a threefold problem. The patient may not remember discussions or explanations given to them during the treatment. The pa-

tient may recall some events or conversations that occurred during the treatment, but not others. The fact that they can sometimes recall certain events very clearly, can leave the patient to believe that other events did not take place at all - even when they clearly did.

The patient may not remember any postoperative instructions given to them at the time of treatment. For this reason, it is important to provide both preoperative and postoperative instructions in written form. Where appropriate, these instructions should be reinforced verbally with the accompanying person whose role it is to supervise the patient on their return home from the surgery. **DT**

Contact information

Dental Protection are the world's largest specialist provider of dental professional indemnity and risk management for the whole dental team. The articles in this series are based upon Dental Protection's 100 years of experience, currently handling more than 8,000 cases for over 48,000 members in 70 Countries.

35 Cavendish Square
London W1G 0PS
UK

E-mail:
General enquiries
querydent@mps.org.uk

The complete set of 36 risk management modules can be ordered from
lynne.moorecroft@mps.org.uk

www.dentalprotection.org

MEDIA CME Self-Instruction Program

Dental Tribune Middle East & Africa in collaboration with CAPP introduce to the market the new project mCME - Self Instruction Program.

mCME gives you the opportunity to have a quick and easy way to meet your continuing education needs.

mCME offers you the flexibility to work at your own pace through the material from any location at any time. The content is international, drawn from the upper echelon of dental medicine, but also presents a regional outlook in terms of perspective and subject matter.

How can professionals enroll?

They can either sign up for a one-year (10 exercises) by subscription for the magazine for one year (\$65) or pay (\$20) per article. After the payment, participants will receive their mem-

bership number and will be able to attend to the program.

How to earn CME credits?

Once the reader attends the distance-learning program, he/she can earn credits in three easy steps:

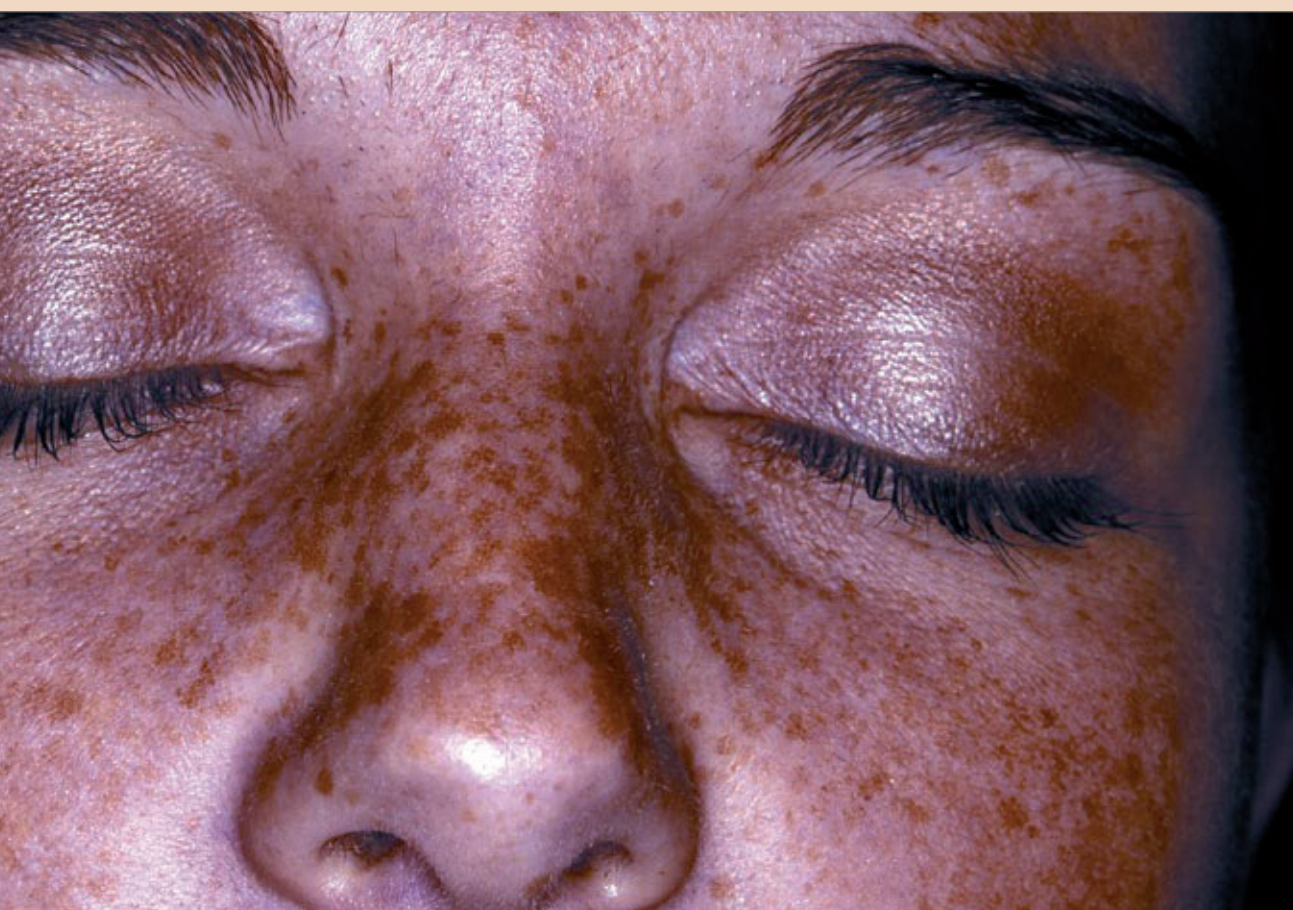1. Read the articles.
2. Take the exercises
3. Fill in the Questionnaire and Submit the answers by Fax (+971 4 3686885) or

Email :info@cappmea.com

After submission of the answers, (name and membership number must be included for processing) they will receive the Certificate with unique ID Number within 48 to 72 hours.

Articles and Questionnaires will be available in the website after the publication.

www.cappmea.com



tion of patients

Complex reconstruction changes a patient's life

by Jim Arnold, DDS

After years of not smiling and experiencing pain with chewing at every meal, Carmen decided to do something significant to change her life. My team and I were excited to meet her because we knew that our work could help give her the smile, comfort and dental health she had always wanted.

Carmen had seen examples of our work on our website, so she felt confident that she was coming to the right place for her care.

Despite her confidence in us, however, she was still nervous about having major dental work done.

We did everything we could to relieve her anxiety and make the process as easy and comfortable as possible.

Patient history

Several teeth had been broken because of abuse from a former boyfriend, and she had severe dental pain due to the trauma and resulting malocclusion. Carmen had been a model as a teenager, but she had rarely smiled since the teeth had been broken (Fig. 1a).

In fact, she was so self-conscious that she rarely opened her mouth in public, and she never showed her teeth in photographs.

After eight years of living with little hope, she hoped to regain her smile, self-confidence and faith in people because of her experience with us.

She cried with gratitude when I told her that we could help her to regain the confidence, chewing function and comfort that she had lost many years ago.

Clinical examination findings

Our comprehensive evaluation included a full series of radiographs, digital photographs, clinical examination of the teeth and periodontium, diagnostic models and patient interview. Carmen's teeth were also severely affected by tetracycline staining.

Heavy attrition, deteriorating restorations and extensive decay added to the complexity of her restorative situation.

A lack of regular dental care and many years of smoking helped lead to moderate periodontal disease and the loss of several posterior teeth. Carmen's measurement from the cemento-enamel junction (CEJ) of the maxillary central incisors to the CEJ of the mandibular central incisors (Shimbashi measurement) was only 11 mm.

This was a result of the heavy wear on her remaining teeth (Figs. 2-4). A Shimbashi measurement of about 16 to 18 mm is typical for patients exhibiting Class I occlusion.

Initial periodontal protocol

We began Carmen's treatment by addressing her periodontal disease. Thorough oral hygiene instructions were given,

scaling and root-planing appointments were scheduled immediately and she began rinsing with chlorhexidine twice daily. My hygienist thoroughly cleaned her teeth under local anesthesia in two visits. Then we reevaluated her periodontal health four weeks later at the follow-up cleaning.

She had already improved dramatically. Pocket depths decreased significantly (from 4 to 5 mm down to 2 to 4 mm), bleeding upon probing was eliminated and her plaque score improved significantly. For the first time in many years, the gingival apparatus appeared to be pink and healthy. Now convinced of her commitment to maintaining her oral health, we proceeded with additional records to finalize our restorative treatment plan.

Diagnostic records and the restorative plan

Carmen's needs were extensive, so we opted to perform full-mouth rehabilitation to restore her natural form, function and esthetics. New diagnostic models were made in order to facilitate creation of a full diagnostic wax-up.

We made an NTI appliance for her to wear for several nights in order to deprogram (or relax) her tense masticatory muscles. This allowed us to obtain a more accurate centric relation (CR) measurement. Facebow and stick-bite records were also made, and photographs were taken to aid our ceramist (Marv Staggs, Precision Dental Restorations [PDR]; Salem, Ore.). These records allowed him to accurately mount Carmen's models for a full-mouth wax-up.

We reviewed photographs from several smile guides with Carmen to decide how to design her new smile. We determined what she wanted her new teeth to look like, selecting shapes, embrasures, line angles and texture. We also decided on the desired colors and incisal translucency to be utilized.

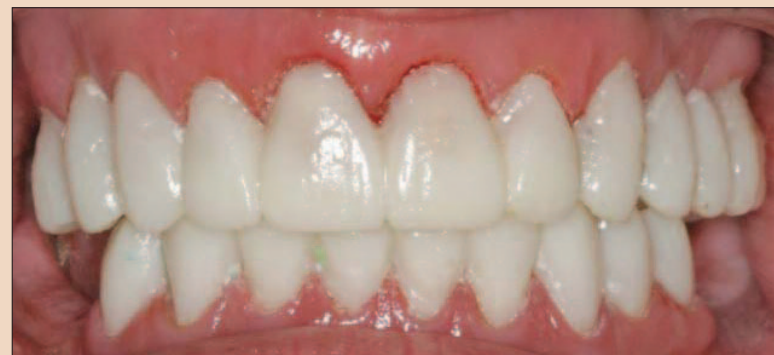

Fig. 5: Carmen's new temporaries make her feel better already.

Local anesthetic was administered so we could "sound" the bone to see how much gingival recontouring we could do. We were able to improve gingival symmetry with our laser, and we made new PVS impressions.

After reviewing restorative options with our ceramist, we decided to restore Carmen's upper



Fig. 1a: At her initial consultation, Carmen tries to smile for the camera.

and lower arches with crowns and a bridge. Because strength and maximizing esthetics were both high priorities, we decided to use Empress (Ivoclar Vivadent; Amherst, N.Y.) crowns for teeth #4-#11 and #21-#29, and a Lava (3M ESPE) bridge for #12-#14. Her missing posterior teeth would be restored later with implants or removable partials.

First restorative appointment

At the preparation appointment, we evaluated the wax-up with Carmen, and we were all very pleased. We therefore proceeded with her restorative treatment.

We modified several teeth with reduction models provided by PDR so that we could preoperatively transfer the wax-up to the mouth with Luxatemp (Zenith/DMG; Englewood, N.J.). This gave us a tool for verification of our records, desired lengths of teeth, CEJ-to-CEJ measurements, proper canine and anterior guidance and occlusion.

The full-mouth Luxatemp mock-up also served as an ideal intraoral preparation guide so that depth cuts could be made into the Luxatemp and tooth structure. This allowed us to maintain even reduction and ideal orientation within the arch

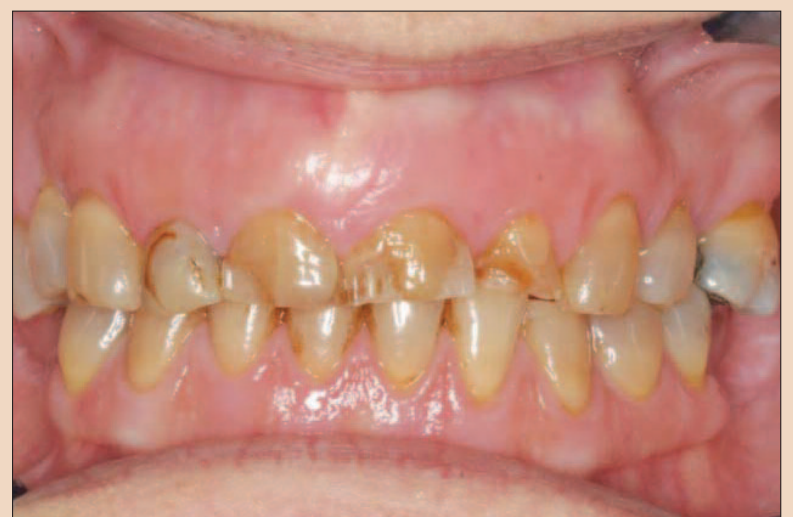

Fig. 2: Carmen's broken and heavily worn teeth make it hard for her to eat and smile.

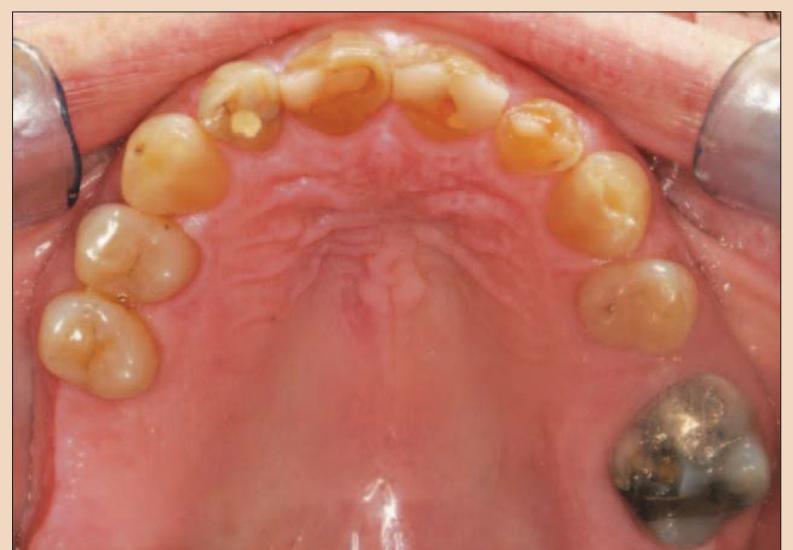

Fig. 3: Her maxillary teeth are heavily worn, have large restorations and significant recurrent decay.

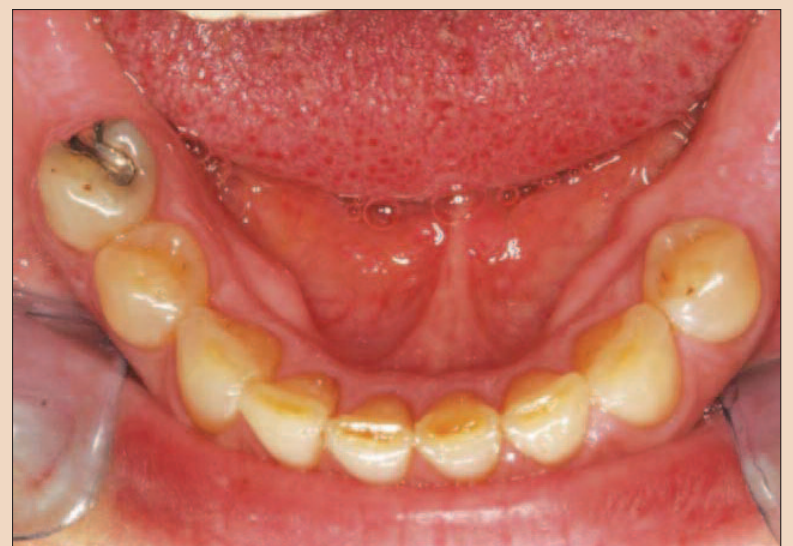

Fig. 4: Her mandibular teeth are significantly shortened by heavy wear.

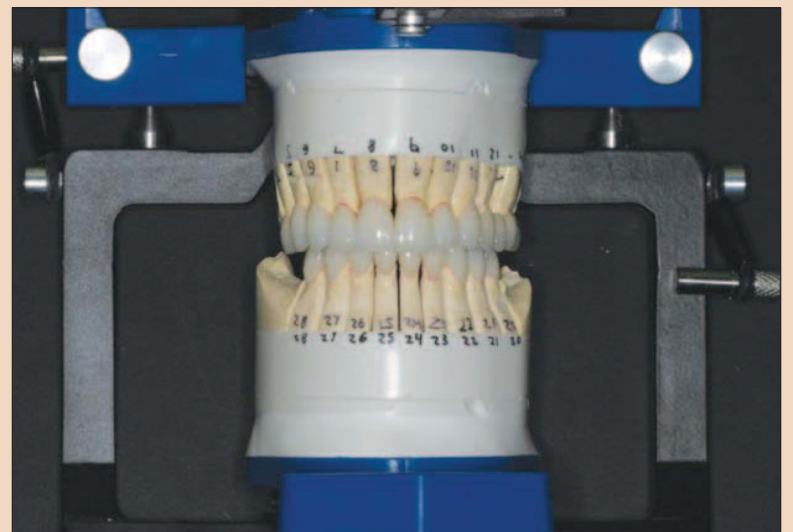


Fig. 6: The new porcelain restorations are evaluated for esthetics, fit, lengths and occlusion on the articulator.

checked the preparation shades, took photographs and made a maxillary final impression.

We used the Sil-Tech stint to make ideal temporaries, and the CEJ-to-CEJ measurements and

form. We segmentally prepared all maxillary teeth, making bite registrations (LuxaBite, Zenith/DMG) for the anterior, right side and left side, allowing us to maintain the new vertical dimension that had been established with the mock-up.

After the maxillary preparations were completed, we

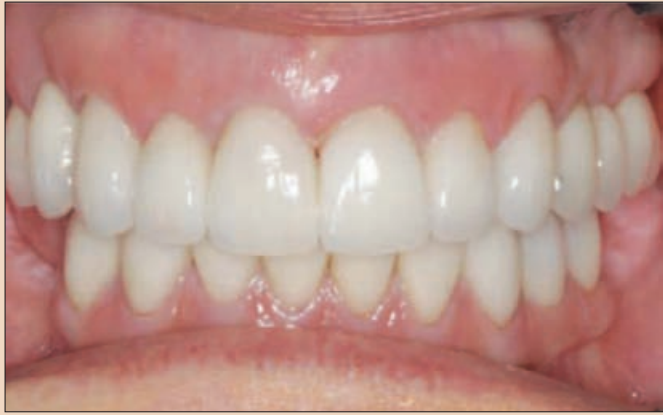

Fig. 7: Carmen's beautiful new restorations give back her smile and allow her to chew comfortably for the first time in years.

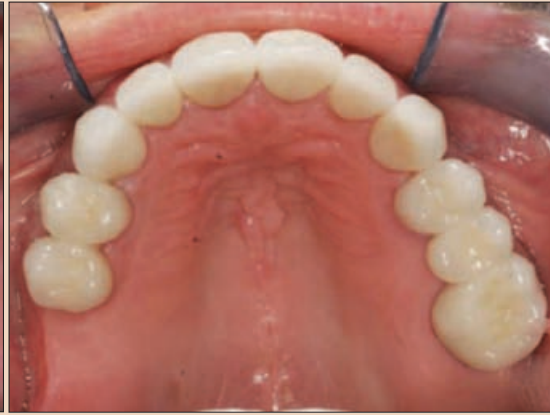

Fig. 8: The new maxillary porcelain restorations restore broken, decayed and worn-down teeth.

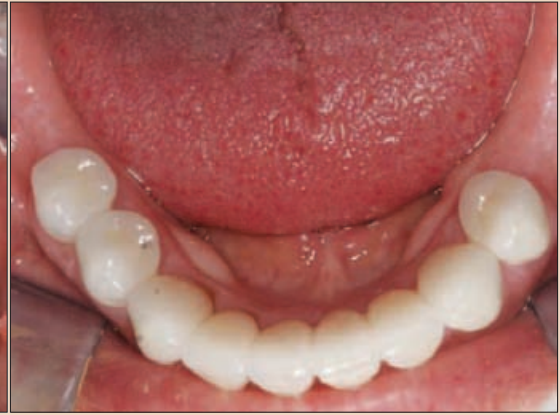

Fig. 9: The mandibular restorations add length and improve overall esthetics and function.

AD

tooth lengths were again verified.

Sequential bite registration records were again used while prepping the lower arch for the anterior and both posterior sections.

We systematically recorded the relationship from the lower to upper preparations and the lower preparations to the upper temporaries. This helped to ensure that all models could be easily cross-mounted by the laboratory and that the new vertical dimension was maintained.

We made the mandibular impression and temporized #21-#29 with Luxatemp. We then recorded the bite relationship between the maxillary preparations and the mandibular temporaries. After temporarily cementing the maxillary temps, we recorded the bite relationship between the upper and lower temps.

Facebow record and stick bites were also made, and photographs of each were taken. We completed the preparation appointment with photographs and PVS impressions of the temporaries (Fig. 5).

All of the relevant photos were sent to PDR on a disc, along with the laboratory prescription, impressions, bite registrations and models. We provided detailed instructions for completing her case.

Trial period with temporaries

Our goal was to restore Carmen to a Shimbashi measurement of 17 mm to allow for ideal function, comfort and maximum esthetics. Her occlusion was restored to CR in the temporary stage, and she adapted to the temporaries very well.

If she had any issues with the increased vertical dimension, we could have adjusted her temporaries to a position of greater comfort while maintaining proper function.

Her self-confidence increased dramatically with her temporary restorations, and she found herself smiling more than ever. Carmen was looking forward to a new future filled with hope and happiness, and her inner joy was reflected on the surface.

Seating the case

Evaluation of her new restorations on the articulator confirmed that the fit, lengths, esthetics, occlusion and color were all exactly as prescribed (Fig. 6).

كلية نيقولا وآسب الجامعية

NICOLAS & ASP UNIVERSITY COLLEGE

The 1st Accredited Dental Postgraduate Training Programs in the UAE

Register NOW...

Masters Degree in Pediatric Dentistry

- Next Intake - (February 2011)
- 3 years study in UAE
- Accredited by
 - UAE Ministry of Higher Education & Scientific Research

Diploma in Advanced Education in General Dentistry (AEGD)

- New Intake
- 2 years Higher Diploma in UAE
- Accredited by
 - UAE Ministry of Higher Education & Scientific Research

Masters Degree in Orthodontics

- 5th Intake (February 2011)
- 3 years study in UAE
- Recognized by Swedish National Board of Health and Welfare
- In collaboration with Malmö University, Sweden
- Accredited by
 - UAE Ministry of Higher Education & Scientific Research
 - Saudi Commission for Health Specialities

High Diploma in Oral Implantology

- 5th Intake (December 2010)
- 1 year (modules) for practicing dentists and specialists
- Program is offered in cooperation with Gothenberg University, Sweden
- Accredited By
 - UAE Ministry of Higher Education & Scientific Research

Unique group of European & American faculty

For more information: Tel.: 0097143624788

Abu Dhabi Headquarters

Admission Office:
Al Odaid Office Tower, Airport Road, Abu Dhabi, UAE
10th Floor, Office 1201
Telephone: +971 2 404 7141

Dubai Branch

Dubai Healthcare City
Ibn Sina Building (No. 27)
Block D, 3rd floor, Office 302
Telephone: +971 4 3624787

Fax: +971 4 362 4793
P.O. Box: 53382, Dubai, UAE
Website: www.dubai-postgraduate.com
Email: info@dubai-postgraduate.com