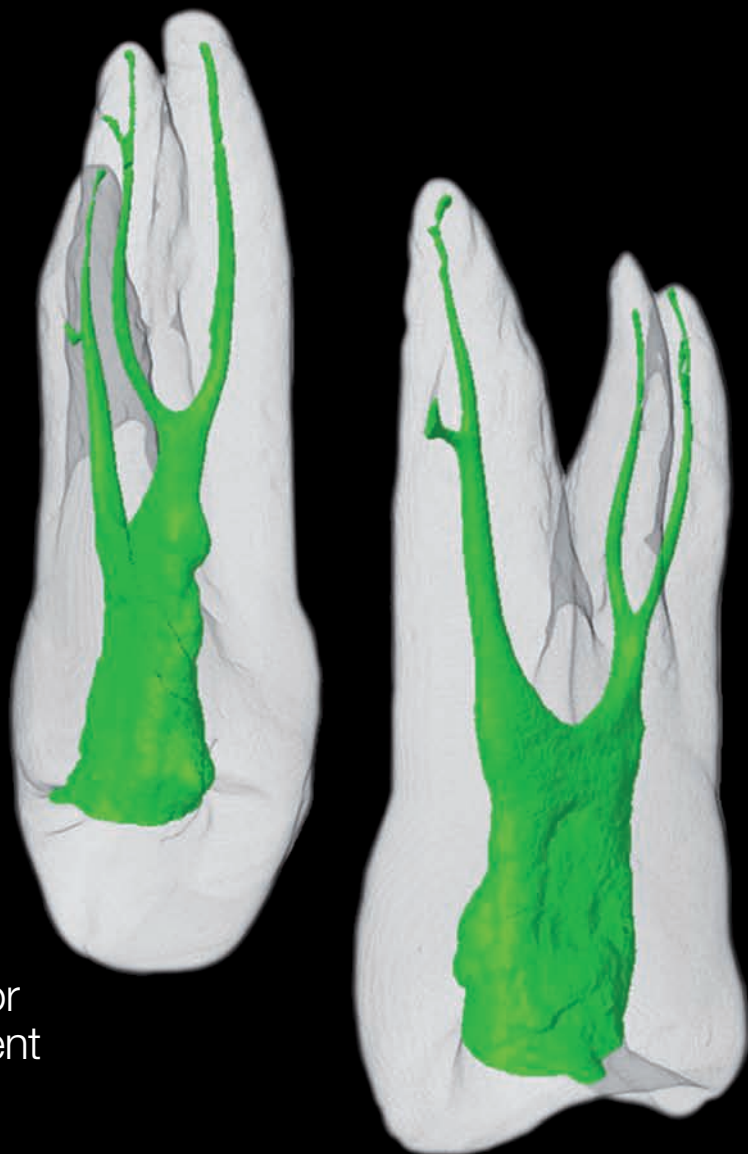


# roots

international magazine of endodontology

4<sup>2013</sup>



## | CE article

Diagnosis 2013:  
The things you need to know for  
successful endodontic treatment

## | technique

Bioactive endodontic obturation:  
Combining the new with the tried and true

## | special

Laser versus conventional therapies

0277773



# Live, Interactive Webinars and On Demand Courses

A growing education platform where you can find more than 400 dental courses, live Webinars, live Education Symposia.

## Interested in C.E. credits and quality learning?

Learn from the experts:

Richard Niederman

Louis Malcmacher

Eduardo Mahn

Robert Horowitz

Paul Weigl

Shamshudin Kherani

Christian Coachman

Ron Kaminer

Edgar Garcia Hurtado

Glenn van As

Marc Gottlieb

John Fluke

Marius Steigmann

David Hoexter

Dwayne Karateew

Fotinos S. Panagakos

George Freedman

Howard S. Glazer

Lynn Mortilla

Maria Emanuel Ryan

Michael Glick

Peter Barry

Barry Levin

Fay Goldstep

## Interested in sponsoring education?

Some of our partners:



**"83%** of the **dentists** visited the exhibiting sponsors as a result of attending the Symposia."

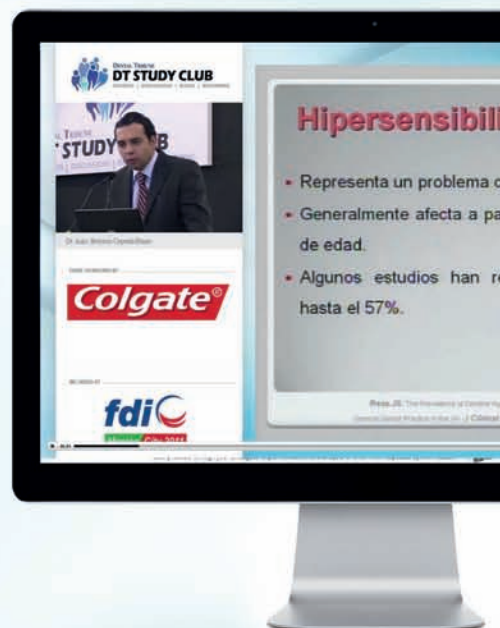
*this is what we've learned from our customers*



Register for **FREE** on [www.DTStudyClub.com](http://www.DTStudyClub.com)

## How to receive your C.E. Credits?

1. Go to [www.DTStudyClub.com](http://www.DTStudyClub.com) and log in.
2. Not a member yet? Register for a free account.
3. Find the courses you're interested in and register to access them.
4. Watch the course.
5. Take the Quiz and print the C.E. certificate.



# Lasers are mainstream in endodontics



Dr George Freedman

**One of the most innovative technologies** widely used in medicine, kind to tissue and excellent for healing, has only recently begun to make a significant dental impact. Dental lasers have been commercially available for several decades, but the profession has been slow to incorporate this technology into the practice. Lasers, extensively documented in the academic and clinical dental literature, have long been perceived by practitioners as too limited in intra-oral applications, too complicated and too expensive. In recent years, ease of use, scientific research and documentation, and greater affordability have converged to make lasers essential for every dental practice.

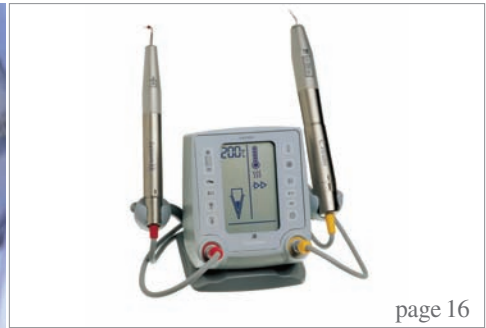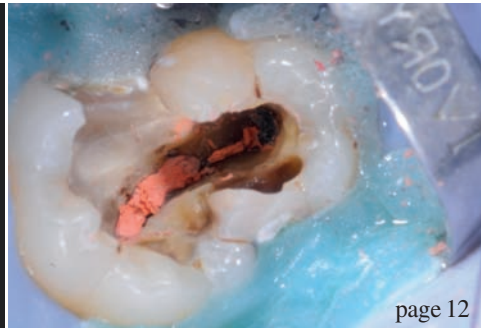
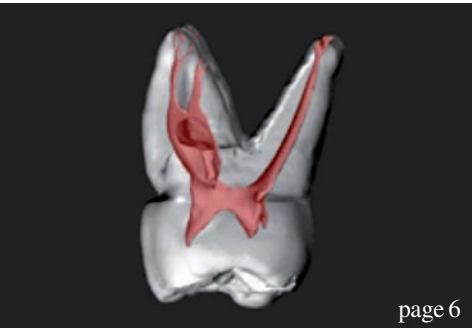Lasers were first indicated for soft-tissue treatment and management. Diode technology has reduced the initial financial investment and made lasers largely affordable for most practices. More recently, laser technologies have been successfully incorporated into endodontic procedures.

The success of intra-radicular endodontic treatment is dependent upon the cleaning and shaping of the root-canal space, disinfection of the root-canal space and 3-D obturation of the root-canal system. Many technologies have been utilised to accomplish these tasks: instrumentation systems, irrigants, intra-canal medications, and a host of obturation materials. Unfortunately, conventional endodontic therapy is still observed to fail on occasion owing to incomplete disinfection and subsequent reinfection. Bacteria may also be found outside the tooth's root-canal system at the apex and elsewhere on the root surface. These extra-radicular bacteria cannot be eliminated with conventional therapies, and the residual contamination maintains the active infectious process.

Laser-assisted endodontic therapy, undertaken after access and mechanical preparation, overcomes the inherent difficulties of existing treatment. Lasers must be considered additions to the existing endodontic armamentarium rather than as stand-alone instruments. The benefits of the variously documented endodontic laser therapies include patient comfort, effective debridement, and penetrating disinfection. Laser therapy avoids vibration, facilitating anaesthesia and eliminating microfractures. The energy of the laser and its associated hydro-photonic activity efficiently remove pulpal tissue, the smear layer and bacteria from the canal walls three-dimensionally, typically without physical contact and without the risk of over-instrumentation beyond the apex.

While the future mainstream laser tools and techniques are still in the process of development and definition, the mounting scientific and clinical evidence indicates that photoactivated debridement and disinfection instruments cannot be dismissed. Dentists who perform endodontic therapy must consider integrating endodontic lasers into their practices. Lasers have arrived in endodontics!

Dr George Freedman (DDS, BSc, Fellow of the American Academy of Cosmetic Dentistry, American College of Dentists, and International Academy for Dental-Facial Esthetics)



| editorial

03 **Lasers are mainstream** in endodontics  
| Dr George Freedman

34 **Treatment of aphthous stomatitis** using low-level laser therapy  
| Pedro J. Muñoz Sánchez, Cuba, José Luis Capote Femenias & Jan Tunér

| CE article

06 **Diagnosis 2013:** The things you need to know for successful endodontic treatment  
| Dr Thomas Jovicich

| meetings

38 **Navigating canal system** – The 16<sup>th</sup> ESE biennial congress  
40 **International Events**

| case report

12 **CBCT in endodontic treatment** of fused second and third mandibular molars  
| Dr Andreas Krokidis & Dr Riccardo Tonini

| about the publisher

41 | submission guidelines  
42 | imprint


| technique

16 **Bioactive endodontic obturation:** Combining the new with the tried and true  
| Dr Gary Glassman

| special


26 **SEM analysis** of the laser activation of final irrigants for smear layer removal  
| Dr Vivek Hegde, Dr Naresh Thukral, Dr Sucheta Sathe, Dr Shachi Goenka & Dr Paresh Jain

30 **Laser versus** conventional therapies  
| Cristiane Meira Assunção, Joanna Tatith Pereira, Renata Schlesner Oliveira & Dr Jonas de Almeida Rodrigues

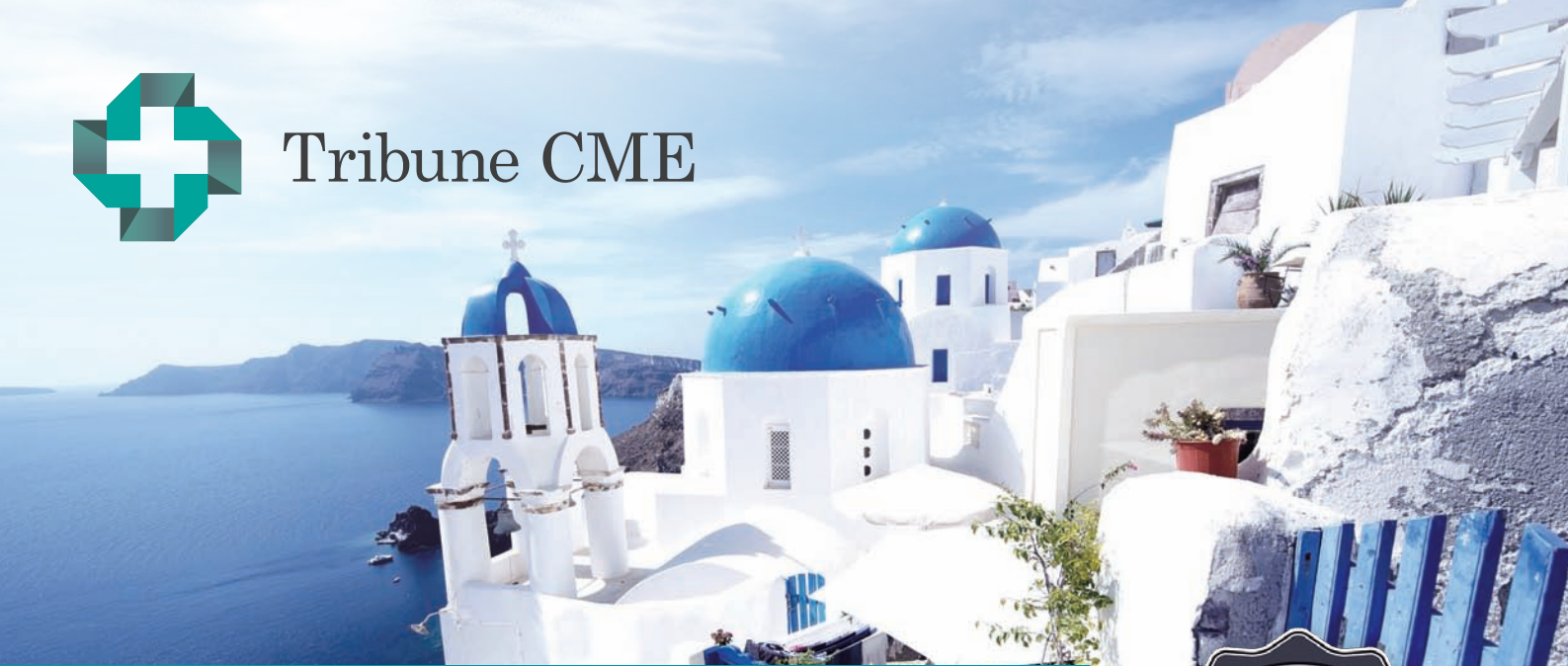

*Frontal and lateral views of a 3-D reconstruction of a maxillary first premolar showing a three-rooted canal system. This micro-CT image was developed as part of the Root Canal Anatomy Project <http://rootcanalanatomy.blogspot.com> in the Laboratory of Endodontics of the University of Sao Paulo in Ribeirao Preto, Brazil by Prof. Marco Versiani, Prof. Jesus Pécora & Prof. Manoel Sousa-Neto.*






Tribune CME



# 1 Year Clinical Masters Program in **Aesthetic and Restorative Dentistry**

13 days of intensive live training with the Masters  
in **Santorini (GR), Geneva (CH), Pesaro (IT)**



Three on location sessions with **live patient treatment, hands on practice** plus online learning and online mentoring under the Masters' supervision.

Learn from the **Masters** of Aesthetic and Restorative Dentistry:



### Registration information:

**13 days of live training with the Masters**  
in Santorini, Geneva, Pesaro + self study

Details and dates on [www.TribuneCME.com](http://www.TribuneCME.com)

**Curriculum fee: € 9,900** contact us at tel.: **+49-341-48474-302** / email: **request@tribunecme**  
(€ 900 when registering, € 3,000 prior to each session)

**Collaborate**  
on your cases

and access hours of  
premium video training  
and live webinars

**University**  
of the Pacific

you will receive a  
certificate from the  
University of the Pacific

**Latest iPad**  
with courses

all early birds receive  
an iPad preloaded with  
premium dental courses


**150** ADA CERP  
C.E. CREDITS

**ADA C.E.R.P.**® | Continuing Education  
Recognition Program

Tribune America LLC is the ADA CERP provider. ADA CERP is a service of the American Dental Association to assist dental professionals in identifying quality providers of continuing dental education. ADA CERP does not approve or endorse individual courses or instructors, nor does it imply acceptance of credit hours by boards of dentistry.

# Diagnosis 2013: The things you need to know for successful endodontic treatment

Author\_ Dr Thomas Jovicich, USA

_ce credit	roots
	<p>This article qualifies for CE credit. To take the CE quiz, log on to <a href="http://www.dtstudyclub.com">www.dtstudyclub.com</a>. Click on 'CE articles' and search for this edition of the magazine. If you are not registered with the site, you will be asked to do so before taking the quiz. You may also access the quiz by using the QR code below.</p>

value for the patient in my chair who has no pain and is here because his or her dentist "saw something" on the radiograph. Pain is the greatest patient motivator we have in dentistry today.

The focus of this article is on diagnosis, and it is my goal to provide the reader with a good grasp of diagnosis as it relates to endodontic treatment.

Endodontics is all about vision. You have it. I have it. The dentist down the street has it. Doing root canals today is all about having the confidence to make the proper diagnosis. This is achieved through repetition. The more you do it, the easier it becomes. In addition, you need consistency that is achieved through positive reinforcement. Once you believe you can do it and the results support that, you then develop competence. This allows you to retain the skills you have worked hard to hone. The most important trait to utilize in clinical practice today is common sense. This is what separates the true artisans from tooth mechanics.

The key component to endodontic treatment is diagnosis. It is based upon using a multifocal approach that involves:

- \_patient report,
- \_medical and dental history,
- \_clinical signs and symptoms,
- \_diagnostic testing,
- \_radiographic findings,
- \_restorability.

**The goal of endodontic treatment** is for the clinician to achieve an effective cleaning and debridement of the root canal system, including the smear layer and all of its mechanical and bacterial byproducts. Traditionally this is accomplished via mechanical instrumentation in conjunction with chemical irrigants together and actively engaged to completely debride and sterilize the root canal system.

The root canal system is a vast and complex three-dimensional structure comprising deltas and lateral canals, along with multiple branches off of the main root canal system (Figs. 1, 2, 9).

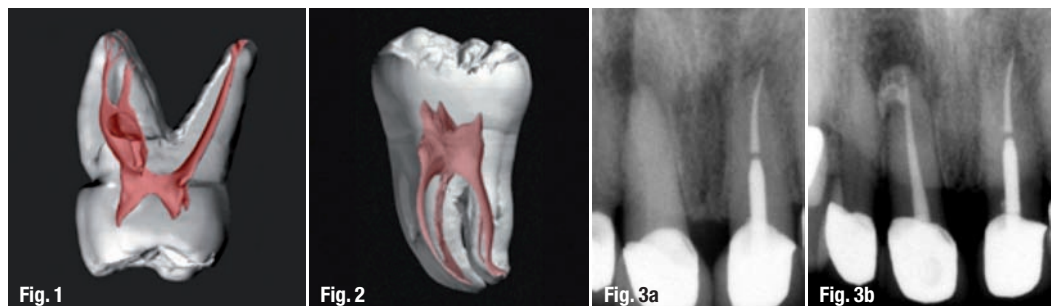
Before the clinician can begin to treat a patient in need of endodontic treatment, he or she first must come up with the proper diagnosis. Once the diagnosis has been made, it then must be integrated with the treatment plan. Taking that treatment plan and presenting it to the patient creates the next challenge: creating value for the patient. One of my most difficult challenges as a working endodontist is creating

**Fig. 1** \_Maxillary molar. Note the complex anatomy and multiple portals of exit. (Photos/Provided by Thomas Jovicich, MS, DMD)

**Fig. 2** \_Mandibular molar. Note the curvature along with the multiple portals of exit.

**Fig. 3a** \_Maxillary central incisor with a periapical lesion. This is a markedly calcified canal.

**Fig. 3b** \_Maxillary central incisor with completed root canal using Sybron TFA rotary nickel titanium instruments, Sealapex sealer. Note the multiple portals of exit in the apical region.



Taking and collating all of this information will allow the clinician to arrive at a proper and thorough diagnosis. Let's break these down and delve into what needs to be done.

### **\_Patient report**

This is the first opportunity to create a road map to a diagnosis. The goal is to ascertain the nature of the problem. Step one: Ask the patient where the pain is located. Once you've localized the area, it's imperative to ask a few more questions. The next question should involve determining pulpal vitality through the use of an ice pencil.

Other times the patient will volunteer this information with a statement like: "The minute I put anything cold on this tooth, the pain is present and quite intense." This information suggests that the pain may be pulpal in origin. Because the trigeminal nerve is involved in endodontics, it is important to determine any type of radiating pain. It is not uncommon for maxillary pain to radiate from the mandibular area and vice versa. A final area of feedback I want from patients relates to biting and chewing.

The patient's report is the foundation upon which we begin the diagnostic procedure. Asking probing and leading questions in "plain English" will allow the patient to give you critical diagnostic information.

### **\_Medical and dental history**

Once you have the patient's report, probing his or her medical and dental history gives clarity to the background. What are the patient's medical allergies? What recent dental treatment has the patient had? Was there any mention of restorations placed that were near or at the pulp?

Many times a patient will mention having heard the dentist tell his assistant that they were close to the pulp during the excavation of decay. Asking detailed questions enables you to enrich the diagnostic canvas as to why the patient is sitting in your chair.

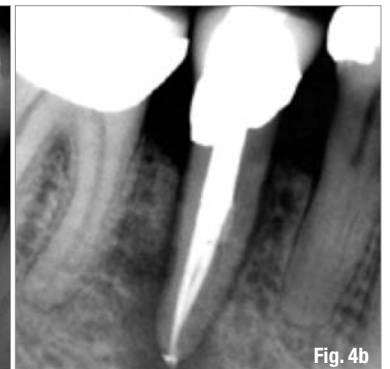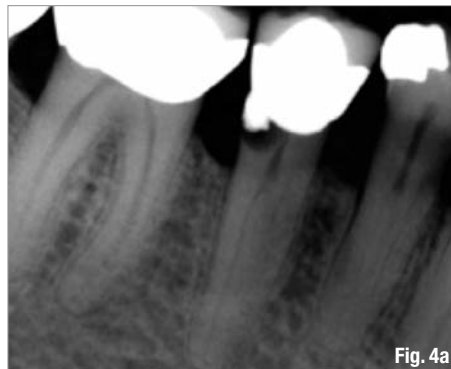
### **\_Clinical signs and symptoms**

By this point, you have listened to the patient's chief complaint and you have taken radiographs or digital images. It's time to "test" the patient. The "bite test" involves having the patient attempt to reproduce the pain through biting on an orangewood stick or a cotton swab or a wet cotton roll. If there is pain to bite, you are dealing with some degree of pulpal inflammation with secondary involvement of the periodontal ligament. Once you have this information, the next step is to look at your digital imaging

and analyze the relationship of the periodontal ligament (pdl) to the root. Is there a thickening? Is there a widening?

If the patient reports pain to bite upon release, this infers that there may be some structural root damage (Figs. 5a & b). At that point it is essential to look at the occlusal surface of the tooth, account for the type and age of any restoration and inquire if any recent dentistry has been done. In addition, it is imperative to probe the suspected tooth.

Probing from buccal to lingual with at least four measurements per side is the best barometer to assess periodontal health. If you find an isolated defect in any single probing, you are most likely dealing with a fracture of the root. Endodontic treatment to confirm or rule out a fracture is indicated in these clinical situations.



### **\_Diagnostic testing**

The percussion test involves using the blunt end of a mouth mirror or periodontal probe to assess for periodontal inflammation. It is imperative that the clinician gets a frame of reference. This is accomplished by testing the same tooth on the opposite side of the arch. In addition, it is prudent to test the suspected tooth as well as the teeth on either side. Testing should involve both the occlusal and facial surfaces.

Thermal tests utilizing hot or cold are the definitive modality to assess pulpal vitality. There are a myriad of ways to test with cold, including CO<sub>2</sub> systems, refrigerant sprays and ice cubes (pellets). I believe ice pellets are the best way to test for cold symptoms. In our practice, we use anesthetic carpules that are filled up with water and frozen.

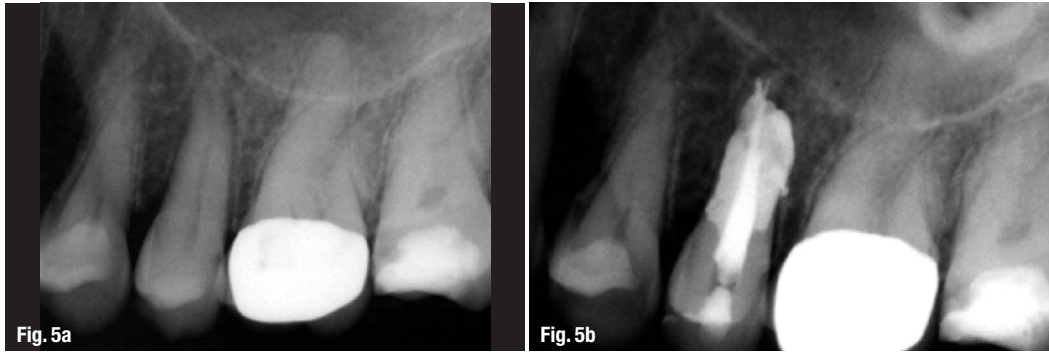
This method is cheap, efficient and plentiful. The goal is to reproduce the patient's symptoms. Many patients who report pulpal hyperemia have managed this symptom by utilizing the opposite side of their mouth. Temperature symptoms are a major motivator for patients to seek dental care.

**Fig. 4a** The presence of caries under the margin of a restoration. The caries extend to the pulp and will need endodontic treatment.

**Fig. 4b** The endodontic treatment is completed. In this case, the patient was lost to the practice for three years and came back when his face was swollen because of incomplete treatment.

**Fig. 5a**\_Cracked tooth syndrome. Pre-treatment radiograph.

**Fig. 5b**\_What can happen in a cracked tooth when you obturate with warm, vertical condensation of gutta-percha.



Testing with ice involves establishing a baseline to cold. Typically, I chose to test the same tooth on the opposite side or the maxillary central incisor. I ask patients to tell me when they feel an "electrical shock or jolt" to the tooth. As soon as they do that, I remove the ice from the tooth. This is easily accomplished on the buccal surface of the tooth at the margin of the gingiva. When porcelain restorations are present, I strive to put the ice right at the margin on or above any metal margins.

Sometimes it is necessary to apply the ice on the lingual aspect of the tooth. As unresponsive as porcelain restorations can be, the clinician needs to be aware that pulp testing gold restorations can have the opposite effect. This is because of the metallurgical properties of gold. It is an amazing conductor of temperature. Always forewarn the patient when testing gold-restored teeth.

Ask the patient if the cold on the tooth reproduced his or her pain. Also, ask if the pain lingered after you removed the ice from the test site. If the pain is lingering, it is a sign of irreversible pulpitis.

In some cases the pain can and does radiate along the pathway of the trigeminal nerve. Sometimes, especially in the maxilla, referred pain can be related to sinus issues, such as sinusitis, allergic rhinitis and rhinovirus.

If the patient does not respond to any thermal tests, both hot and cold, it is a sign that the pulp is necrotic, dying or infected. In this instance, studying

the digital imaging may aid the diagnosis. One caveat: It is possible to have a necrotic pulp without being able to quantify it via digital images. In many incipient pathology issues, it takes approximately 90 to 120 days for breakdown to manifest itself on imaging. Today's cone-beam imaging technology can shorten that process to 30 days. It is not uncommon to have a patient in the chair with symptoms that you cannot quantify radiographically.

### Radiographic findings

Radiographic findings (Figs. 8a & b) are the road map for endodontics. Thorough study and evaluation of imaging allows the clinician to determine a multitude of facts about the tooth in question. What does the image reveal? Can you see if there is a widening of the pdl? If there is a widening of the pdl, it is essential to have the patient bite down on a bite stick.

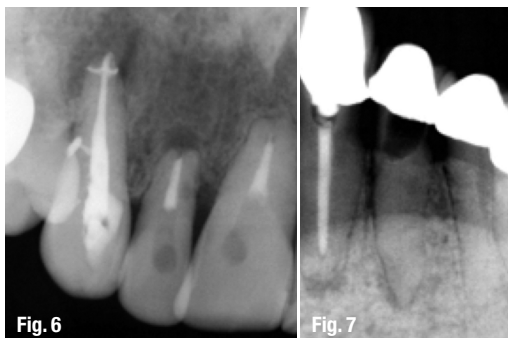Once he or she does that, you must ask if the pain, if present, is worse upon bite or upon release of bite. The latter is highly correlated with root fracture. Once that is confirmed, the next step is to prepare the patient for a root canal.

The dentist must convincingly explain the procedure's value as well as caution the patient about the possibility of losing the tooth due to the fracture extending apical from the cemento-enamel junction (CEJ). Is there a lesion (Figs. 3a & b) present? This information allows me to frame my diagnostic questions to the patient. These include: Is the tooth sensitive to cold? I know from the lesion that the answer to that should be no. If, however, the answer is yes, it automatically triggers my mind to look for another tooth.

Generally, speaking teeth with lesions of endodontic origin (LEOs) test non-vital to thermal or electric pulp testing. In sequencing, I first ask for the patient's report, followed by radiographic findings, which I then augment with clinical testing to tie it all together and arrive at a diagnosis. Lastly, are caries present? The location of caries is a determining factor as to whether a root canal is needed (Figs. 4a & b).

**Fig. 6**\_Well-done endodontic treatment of tooth #6. Notice the multiple portals of exit as they relate to the presence of lesions.

**Fig. 7**\_Know when to say when. This dentist attempted to do an endodontic procedure that should not have been done.





## \_Restorability

Restorability is an issue that has been a hot topic in dentistry for years. Its meaning has evolved as technology has become the backbone of modern dentistry. Prior to the incorporation of implant dentistry, restorability had a very different meaning. Dentists were much more motivated to save teeth. Options and creativity were necessary for clinical success, both in endodontics as well as in restorative dentistry.

Technology has taken away one form of resourcefulness and replaced it with the promise of a panacea. It has become far too easy for general dentists to recommend removal of a tooth to a patient with the promise that an implant will save the day.

**‘In modern endodontics, as technology advances and we bring on file systems that shape more efficiently and safely—and we develop a greater understanding of the role of irrigation in endodontics—we can offer higher success rates than at any time in history.’**

Historically speaking, the diagnosis of a tooth being non-restorable came after a myriad of attempts to save the tooth. Every aspect of dentistry came into play. Periodontists did osseous surgery and root amputations. Endodontists performed conventional endodontics and, if necessary, surgical intervention to do everything possible to save the tooth. Decisions involving the long-term prognosis of the tooth were relevant. Decisions about the type of restoration were discussed. Decisions about the osseous health of the roots and surrounding bone structures were relevant.

The goal of every specialist is to be an extension of the general dentist's practice. To that end, deciding whether a tooth was restorable or not was, at a minimum, a conversation to be had between the specialist and the general dentist.

Leap forward to the new millennium, and dentists no longer fight to save teeth. Dentists realize the financial windfall that implants offer their practices. Dentists can attend a myriad of continuing education

courses over a weekend and on Monday become nascent implantologists. This fact makes diagnosis and saving a tooth the most important facet of restorative dentistry moving forward.

Treatment planning and restorability are integral to success both for the patient and the dentist. A patient in pain presents a unique opportunity for the dentist. Many questions need to be asked and answered. Among them: What can the dentist do to manage the pain? What is the cause of the pain? How long has the patient been in pain? Once the initial triage phase is complete, other factors must be addressed. These include: Is the tooth restorable? If endodontic treatment is indicated, what further treatment will be needed? Is there a need for periodontal intervention? If so, what type of treatment is it? Osseous surgery? Does the tooth need crownlengthening surgery? How will these procedures affect the adjacent teeth?

The above paragraph speaks volumes as to the complexities of treatment planning in dentistry today. Every day in offices around the world, a patient visits his or her dentist in pain. How the dentist responds to this will go a long way in determining the patient's dental well-being. A well rounded practice with high moral fiber will enable the dentist and patient to work synergistically to develop a realistic treatment plan.

The last essential ingredient to success is that the dentist knows "when to say when" (Fig. 7). As a specialist and lecturer, I believe that if a general dentist does roughly 80 per cent of the endodontic cases that walk in the door of his practice and refers out the remaining 20 per cent, he or she will have a very busy endodontic practice. In the past five years, especially since the decline in the economy and busyness of practices, more than 50 per cent of my practice consists of retreatment. The general dentist should have never attempted more than half of those cases. I can only speculate how much more there would be if dentists didn't have implants to fall back upon.

## \_Implants vs. endodontic treatment

The next aspect of the diagnostic conundrum is the increasing role implants play in treatment planning. When I first began practicing endodontics in 1988, implants were in their nascent stages. If a patient had a root canal and continued to experience pain or discomfort, both the dentist and the endodontist had a myriad of choices, from retreatment to surgical correction. In 2013, the knee-jerk reaction to placing implants has never been greater. More and more general dentists go to weekend "seminars/courses," and on Monday morning they are placing implants. Much of this is based on the financially lucrative aspect of implant dentistry.