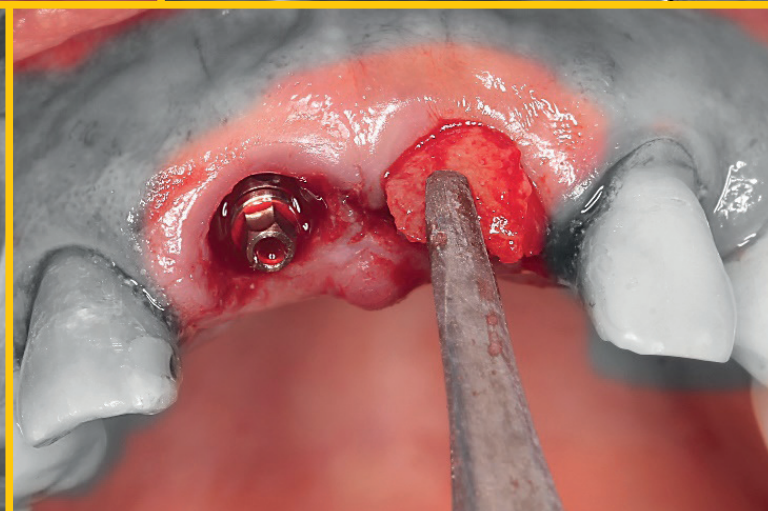
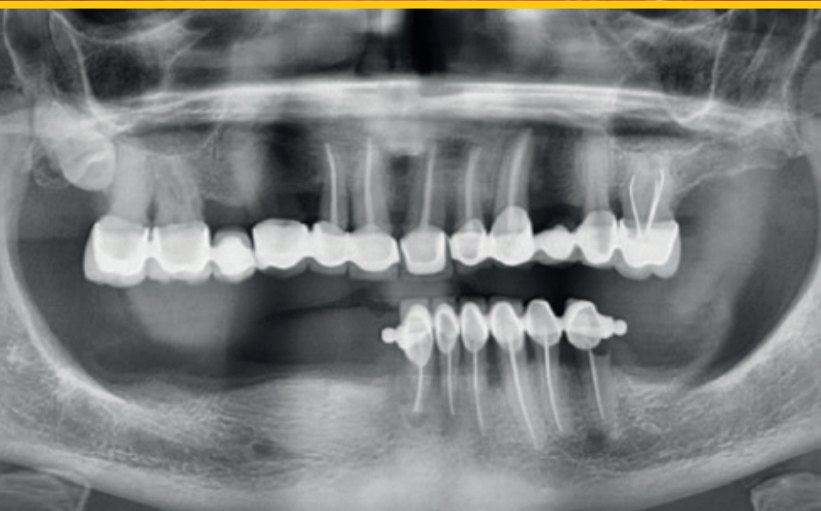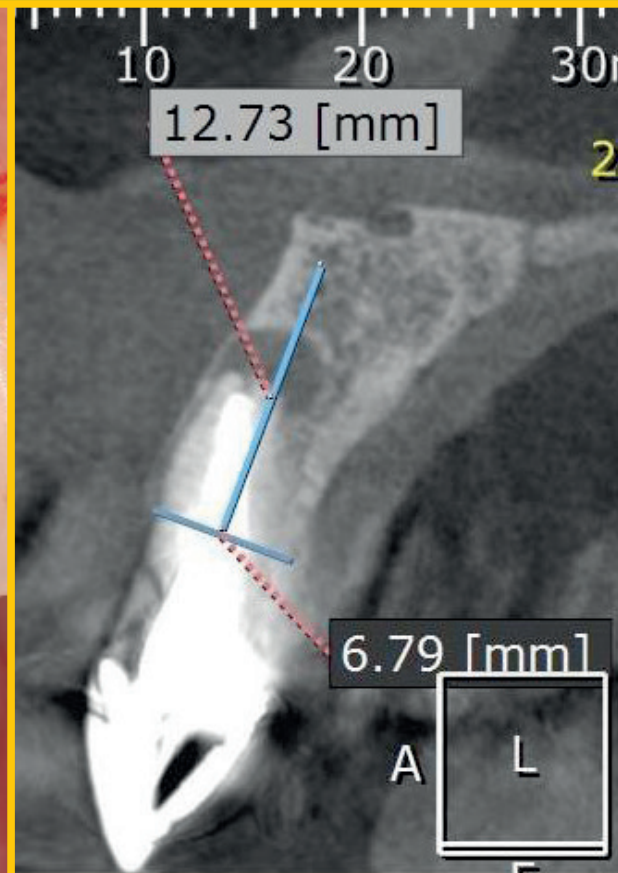
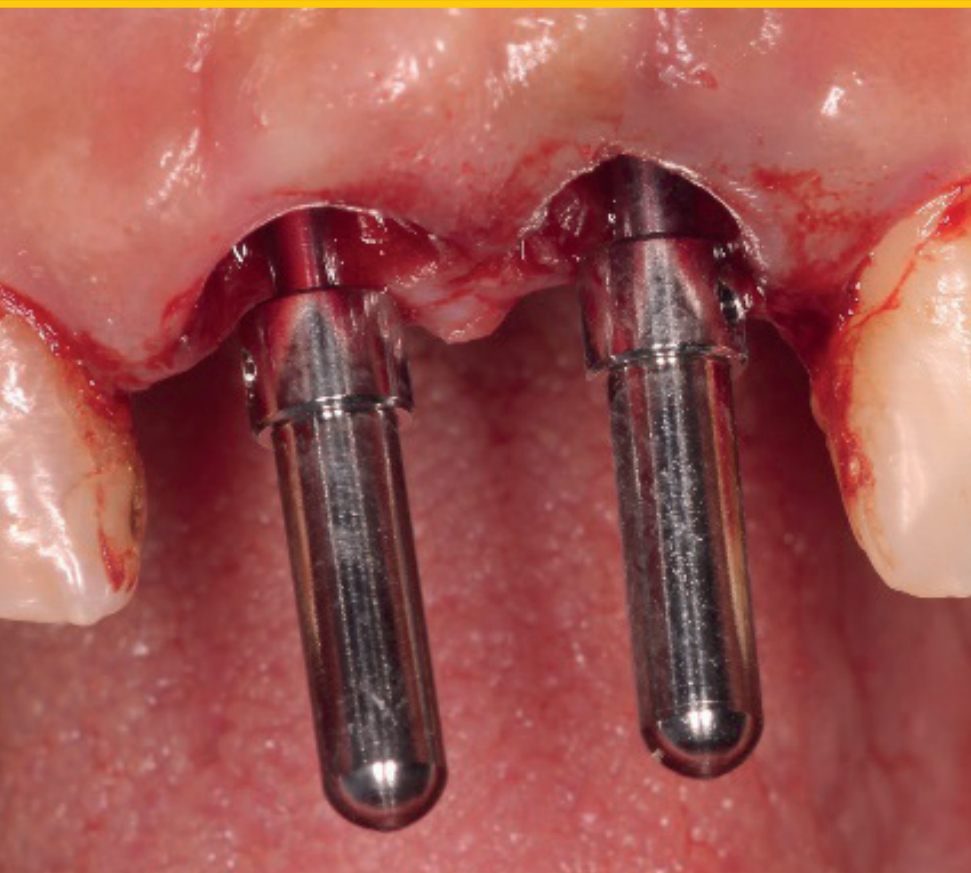



Journal of Oral Science & Rehabilitation

Journal for periodontology, implant dentistry,
dental prosthodontics and maxillofacial surgery



IT'S SIMPLE TO BE A
WINNER



**PROVEN SUCCESS MEETS ENHANCED
STABILITY. MAKE IT SIMPLE**

The biological stability and predictable esthetics of the SEVEN, combined with the extensive research and development process have given the SEVEN a potential advantage in soft tissue preservation and growth as well as an array of restorative benefits. Learn more about the SEVEN implant system and MIS at: www.mis-implants.com

**mis[®]
SEVEN[®]**



In atrophic edentulous maxillae, should we regenerate or use residual bone?

In the world, there are 500 million of completely edentulous people. Edentulism has a significant impact on quality of life: esthetic concerns due to alteration of the vertical dimension and facial profile, decreased masticatory efficiency, temporomandibular joint dysfunction and problems associated with the use of removable complete prostheses, such as stomatitis, angular cheilitis, oral candidiasis, ulcers and hyperplasia.^{1,2} Edentulism has repercussions in social life and day-to-day activities. Edentulous patients may feel embarrassed when talking, smiling or eating in front of other people, and this can lead to social isolation and subsequent loneliness.³

The best solution for patients with complete edentulism is rehabilitation with prostheses supported on implants. Improved oral health and quality of life can be seen in edentulous patients with atrophied maxillae after implant treatment with an immediate loading protocol.⁴ It is frequent that edentulous patients present severe bone atrophy. In these cases we should ask ourselves whether we need to regenerate before placing the implants or if can use the residual pristine bone. Therefore, we must establish whether it is better to place an implant with or without bone grafting.

A problem of regenerative procedures is bone graft resorption. Volumetric measurements of the grafts evidence progressive and unavoidable bone resorption of almost all the grafted bone in the maxilla and mandible. In a study with a number of years of follow-up, after vertical and horizontal alveolar ridge augmentation of atrophic maxillae and mandibles with autogenous crest block bone grafts, very high percentages of bone graft resorption were found.⁵ The use of anatomical buttresses is an alternative that overcomes the higher morbidity and higher treatment fees of regenerative procedures, as well as the longer postoperative periods for delivery of the definitive restorations. Flying buttresses are external discharge elements used in Gothic archi-

ture in the form of a half arch. Buttresses collect the pressure at the start of the vault and transmit it to another buttress attached to the wall of a lateral nave. They were first used in 1180 in the construction of the central nave of the Notre Dame of Paris to reinforce its vault. In orofacial structures, buttresses are areas of dense bone that form a protective frame and dissipate forces around the craniofacial cavities: fronto-maxillary buttress, pterygomaxillary buttress, zygomatic buttress, palatal cortical bone and nasopalatine duct (an additional area of residual bone).⁶⁻⁸

A study that compared conventional dental implants placed in augmented atrophic maxillae and the placement of implants in buttresses found a greater loss of implants in the augmentation group.⁹ It also found that the mean period for functional restoration was 1 week in the buttresses group and more than 1 year in the augmented patients.⁹

Prof. Miguel Peñarrocha Diago
Editor-in-Chief

Editorial note: A list of references is available from the publisher.

Contents

- 3 Editorial**
Prof. Miguel Peñarrocha Diago
- 6 About the Journal of Oral Science & Rehabilitation**
- 8 Marino Sánchez-Siles et al.**
Evaluation of primary stability and early healing of 2 implant macrodesigns placed in the posterior maxilla: A split-mouth prospective randomized controlled clinical study
- 16 Guillermo Cabanes Gumbau et al.**
All-on-4 with tapered neck implants and a hybrid prosthesis with a fiberglass-reinforced structure (TriLor Arch)
- 24 Lim Min Jim**
An unusual case of sublingual ranula with submandibular gland involvement
- 28 Igor da Silva Brum et al.**
Immediate dentoalveolar restoration
- 36 Guidelines for authors**
- 38 Imprint — About the publisher**



Masterclass
Dental



Welcome to MasterClass.Dental

Online classes taught by the world's best doctors
directly from their practice



OBSERVE



DISCUSS



YOUR CASE



ON DEMAND



ALL DEVICES



GUARANTEED

www.MasterClass.Dental



Tribune Group



ADA CERP® | Continuing Education
Recognition Program

Tribune Group GmbH is an ADA CERP Recognized Provider.
ADA CERP is a service of the American Dental Association to assist dental professionals in identifying
quality providers of continuing dental education. ADA CERP does not approve or endorse individual
courses or instructors, nor does it imply acceptance of credit hours by boards of dentistry.

Tribune Group GmbH designates this activity for 1 continuing education credits.
This continuing education activity has been planned and implemented in accordance with the
standards of the ADA Continuing Education Recognition Program (ADA CERP) through joint efforts
between Tribune Group GmbH and Dental Tribune Int. GmbH.

About the Journal of Oral Science & Rehabilitation

The aim of the *Journal of Oral Science & Rehabilitation* is to promote rapid communication of scientific information between academia, industry and dental practitioners, thereby influencing the decision-making in clinical practice on an international level.

The Journal of Oral Science & Rehabilitation publishes original and high quality research and clinical papers in the fields of periodontology, implant dentistry, prosthodontics and maxillofacial surgery. Priority is given to papers focusing on clinical techniques and with a direct impact on clinical decision-making and outcomes in the above-mentioned fields. Furthermore,

book reviews, summaries and abstracts of scientific meetings are published in the journal.


Papers submitted to the *Journal of Oral Science & Rehabilitation* are subject to rigorous double-blind peer review. Papers are initially screened for relevance to the scope of the journal, as well as for scientific content and quality. Once accepted, the manuscript is sent to the relevant associate editors and reviewers of the journal for peer review. It is then returned to the author for revision and thereafter submitted for copy editing. The decision of the Editor-in-Chief is made after the review process and is considered final.

About Dental Tribune Science

Dental Tribune Science (DT Science) is an online open-access publishing platform (www.dtscience.com) on which the *Journal of Oral Science & Rehabilitation* is hosted and published.

DT Science is a project of the Dental Tribune International Publishing Group (DTI). DTI is composed of the leading dental trade publishers around the world.

For more, visit → www.dental-tribune.com



Benefits of publishing in the journal for authors

There are numerous advantages of publishing in the *Journal of Oral Science & Rehabilitation*:

- Accepted papers are published as e-papers on **www.dtscience.com**; abstracts are published on **www.dental-tribune.com**.
- Authors' work is granted exposure to a wide readership, ensuring increased impact of their research through open-access publishing on **www.dtscience.com**.
- Authors have the opportunity to present and promote their research by way of interviews and articles published on both **www.dtscience.com** and **www.dental-tribune.com**.
- Authors can also post videos relating to their research, present a webinar and blog on **www.dtscience.com**.

Information

The journal is published quarterly. Each issue is published as an e-paper on **www.dtscience.com**.

Copyright © Dental Tribune International GmbH. Published by Dental Tribune International GmbH. All rights reserved. No part of this publication may be reproduced, stored or transmitted in any form or by any means without prior permission in writing from the copyright holder.

Evaluation of primary stability and early healing of 2 implant macrodesigns placed in the posterior maxilla: A split-mouth prospective randomized controlled clinical study

Marino Sánchez-Siles,^a Joao Baptista Ilha,^b
Juan Alberto Fernández Ruiz^c &
Fabio Camacho Alonso^d

^a Private practice, Murcia, Spain

^b Department of Oral Practice, State University of Maringá, Maringá, Brazil

^c Private practice, Ibiza, Spain

^d Department of Oral Surgery, University of Murcia, Murcia, Spain

Corresponding author:

Dr. Fabio Camacho Alonso

Clínica Odontológica Universitaria
Unidad Docente de Cirugía Bucal
Hospital Morales Meseguer (2 planta)
Avda. Marqués de los Vélez s/n
30008 Murcia
Spain

fcamacho@um.es

How to cite this article: Sánchez-Siles M, Baptista Ilha J, Fernández Ruiz JA, Camacho Alonso F. Evaluation of primary stability and early healing of 2 implant macrodesigns placed in the posterior maxilla: A split-mouth prospective randomized controlled clinical study. J Oral Science Rehabilitation. 2019 Sep;5(3):8–15.

Abstract

Objective

The aim of this study was to evaluate the clinical behavior of 2 implants of different macrodesigns placed in low-density bone at the moment of insertion and during bone healing.

Materials and methods

In this split-mouth prospective randomized controlled clinical study, 60 Avinent dental implants (Avinent Implant System) were placed in the posterior maxillae of 30 patients. Each patient received 1 tapered implant with a wide thread (OCEAN) and 1 cylindrical implant with a narrow thread (CORAL). Primary stability was evaluated at baseline by measuring the insertion torque applied and registering the implant stability quotient (ISQ). Periimplant crestal bone loss was evaluated from intraoral radiographs taken at 1 and 4 months after implant placement. Lastly, ISQ was registered after 4 months.

Results

At baseline, both insertion torque and ISQ values were significantly higher for tapered implants ($P = 0.008$). There was less periimplant crestal bone loss at 1 and 4 months with tapered implants with a wide thread (0.43 ± 0.27 mm and 0.59 ± 0.31 mm, respectively) than with cylindrical implants with a narrow thread (0.73 ± 0.28 mm and 0.95 ± 0.43 mm, respectively), and the differences at both evaluation times were significant ($P < 0.001$ and $P = 0.001$, respectively). The ISQ values at 4 months were higher for tapered implants with a wide thread, and the difference was significant ($P = 0.014$).

Conclusion

Although both implant macrodesigns can be placed in low-density bone, tapered implants with a wide thread appear to produce better results in terms of insertion torque, ISQ and crestal bone loss 4 months after placement.

Keywords: Dental implant macrodesign; tapered implant; cylindrical implant; low-density bone; thread.

Introduction

Bone density and especially cortical thickness are important factors in achieving adequate primary stability and a successful clinical outcome when placing dental implants.¹ Primary stability is defined as the absence of movement after the intraosseous insertion of the implant.² Different types of bone in the jaws have been clinically classified in various ways according to structural characteristics related to the proportion of cortical to trabecular bone. The most commonly used classification is that of Lekholm and Zarb,³ according to which type I is the most densely compacted bone type, and type IV the most trabeculated, with lower density and thinner cortical bone, which is generally considered less suitable for supporting dental implants.⁴ Nevertheless, none of the classification systems take the bone's biological capacity into account.⁵

In recent years, various quantitative methods for assessing primary stability have been introduced. These can be used to monitor implant stability repeatedly over time.⁶ Resonance frequency analysis (RFA) consists of applying a bending load that imitates clinical implant loading and its direction. This provides information about the rigidity of the bone-to-implant union, and the result is registered as a parameter known as the implant stability quotient (ISQ). ISQ values range from 1 (low stability) to 100 (maximum stability).⁷ Alternatively, insertion torque is a direct measure of the bone's cutting resistance during implant insertion surgery.⁸ But insertion torque is a mechanical parameter that can be influenced by the surgical procedure, implant design and bone quality.

The success of an implant depends largely on its primary stability, as mechanical stability provides a basis for osseointegration.⁹ Bone density and quality, surgical technique, primary stability and, of course, the implant's geometry are all important factors in achieving implant osseointegration.^{9, 2, 10}

Implant design and shape have undergone various modifications over the years, aimed at increasing the contact between implant surface and bone, and increasing primary and secondary stability.^{11, 12} An adequate macrodesign must balance compression and traction forces and minimize shear forces,¹² to

maintain micromovement at a level below 50–150 μm during the healing period.¹³ A tapered shape provides the implant with a good basis for primary stability, as it allows the gradual expansion of the bone and minimizes stress at its interface with the surrounding bone.¹⁰ It has been shown clinically that implants with a tapered design present better stability in areas with lower bone density.^{14, 15} The pitch and shape of the thread also influence primary stability, stress and initial bone-to-implant contact.¹⁶ According to some studies, a reduced pitch improves surface contact with bone, reduces the distribution of stress and improves primary stability in low-density bone.^{17, 18}

Thus, the aim of this split-mouth prospective randomized controlled study was to evaluate the clinical behavior of 2 implants of different macrodesigns at the moment of insertion in the low-density bone of the posterior upper jaw and during bone healing.

Methods and materials

Recruitment and patient characteristics

The study protocol was approved by the University of Murcia's ethics committee (Spain) (1933/2018) and was carried out between June 2018 and December 2018 at the university's dental clinic. Subjects were treated according to guidelines established by the Declaration of Helsinki for medical research involving human subjects. All the subjects provided their informed consent to participate. The entire protocol (clinical, surgical and radiographic) was carried out by a single clinician.

The inclusion criteria were as follows: aged over 18 years; total edentulism in the maxilla necessitating bilateral implant insertion in the posterior third in type III bone within a range of 350–830 Hounsfield units (HU), according to Norton and Gamble's classification;³ absence of medical contraindications to oral surgical procedures (ASA I/II); and willingness to provide informed consent to take part. The exclusion criteria were as follows: presence of a disease or condition or use of medication that could compromise healing or osseointegration (diabetes mellitus, severe osteoporosis or bisphosphonate administration); pregnancy or lactation; and radiotherapy of