

# ceramic implants

international magazine of ceramic implant technology



## research

Why titanium implants  
create silent inflammation in jawbone

## case report

A metal-free solution for restoring natural aesthetics

## interview

An implant suitable for all surgical indications



Straumann® PURE Ceramic Implant System  
Discover natural PURE white.  
Love your smile.

Two-piece design  
available soon



**OUTSTANDING  
ESTHETICS**

Favorable soft  
tissue attachment,  
high-end esthetic  
restorations



**PROVEN  
QUALITY**

High performance  
zirconia ceramic,  
100% proof tested



**EXCEPTIONAL  
SURFACE**

ZLA® surface with  
revolutionary  
osseointegration  
features



**METAL-FREE**

A metal-free  
alternative to  
titanium implants



**INNOVATIVE**

A new system that  
helps you expand  
your patient pool



Contact your local Straumann representative now or visit  
[www.straumann.com/pure](http://www.straumann.com/pure)

**Georg Isbaner**

Editorial Manager



# Scientific evidence and clinical outcomes—the facts count

There are not many luminary figures that greatly influence future generations through their inventive spirit, humanity and visionary power. Prof. Sami Sandhaus undoubtedly was one of those people. Like no other, he paved the way for modern ceramic implantology. He was invited as a guest of honour by the European Society for Ceramic Implantology (ESCI) to its first congress, but passed away at the biblical age of 92 a week before the event began.

Prof. Sandhaus's path was one of research and science, and fortunately, the younger generation is gratefully continuing his legacy. In the most recent past, dental manufacturers and courageous clinicians have helped elevate the still rather young discipline of ceramic implantology. Gradually, the first ten-year data of university studies is emerging, and this research was showcased at the ESCI congress, as well as at the events held earlier this year by the European Academy of Ceramic Implantology (EACim), the International Academy of Ceramic Implantology (IAOCI) and the International Society of Metal Free Implantology (ISMI). Science is the bedrock on which ceramic implants as a recommended treatment modality rest.

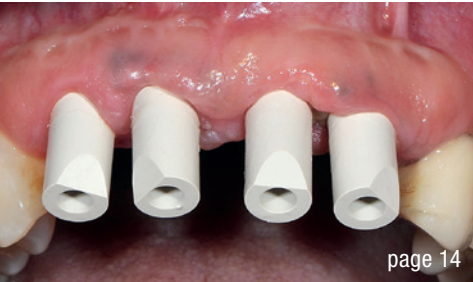
Even if the available amount of scientific data is still quite modest, evidence in clinical practice is already available in great abundance. This brings us to this issue of

*ceramic implants—international magazine of ceramic implant technology*, in which I am pleased to say that the most experienced clinicians in this medical field have shared their knowledge and expertise with us. Some of them have already placed thousands of ceramic implants and have been working with these metal-free systems for over ten years now. They all share a conviction that ceramic implants are a patient-friendly implant option—regardless of whether used for single-tooth restorations or complete prostheses.


In addition, the recent advancements made in ceramic implantology bring another aspect back in focus: the general health of the patient. Patients who wish to receive implant surgery often come to the dentist with systemic and/or immunological impairments. In some cases, metal-free oral rehabilitation is an essential part of the improvement process. The reasons for this are manifold and need to be investigated further in the future. Thanks to ceramic implants, however, the biological principles of oral health are beginning to be better understood in connection with general health. This is in keeping with the philosophy of Prof. Sandhaus.

Wishing you a great read,

Georg Isbaner



Cover image courtesy of  
Institut Straumann AG  
[www.straumann.com](http://www.straumann.com)



**editorial**

Scientific evidence and clinical outcomes—the facts count 03  
Georg Isbaner

**research**

Aspects of zirconia 06

Prof. Dr med. dent. Michael Gahlert

Why titanium implants create silent inflammation in jawbone 08

Drs Johann Lechner & Sammy Noubissi

**case report**

Treatment of an edentulous space with a digital workflow 14

Prof. Heinz Kniha, Thomas Lassen & Dr Kristian Kniha

A metal-free solution for restoring natural aesthetics 18

Dr Jens Tartsch

Restoration after augmentation in the maxillary anterior region 22

Dr Falk Nagel

Digital workflow with a metal-free surgical guide and zirconia implant 30

Dr Saurabh Gupta

Immediate restoration of one-piece zirconia implants 34

Drs Paul S. Petrunaro & Peyman Raissi

Two-piece implants restored in the maxilla and mandible 40

Dr Witalij Kolbe & DT Artur Wolf

Biological dentistry and ceramic implants 42

Dr Dominik Nischwitz

**interview**

An implant suitable for all surgical indications 54

Carbon fibre—established in implant dentistry 56

**obituary**

Pioneer of ceramic implantology Prof. Sami Sandhaus dies at 92 58

**events**

The City of Light provides backdrop for the first EACim Congress 60

The Zeramex Roadshow 2019—ceramic implants on tour 61

“Facts of Ceramic Implants” presented in Zurich 62

**news**

manufacturer news 48

news 64

**about the publisher**

imprint 66

# LIGHT UP YOUR SMILE

with TAV Dental Zirconia Implants



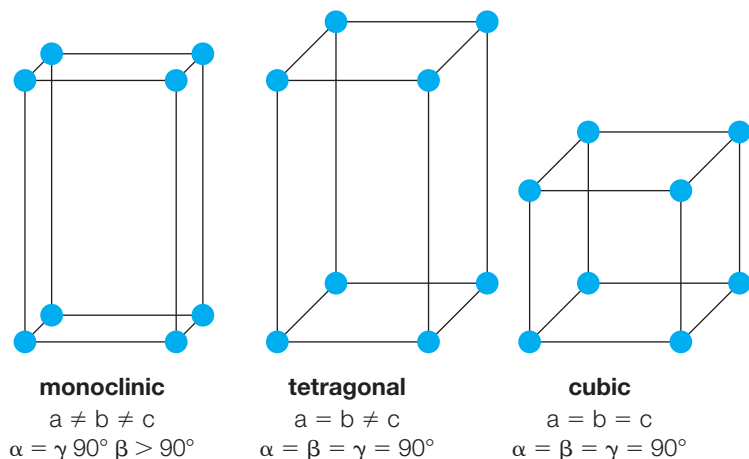
ZIRCONIA IMPLANTS



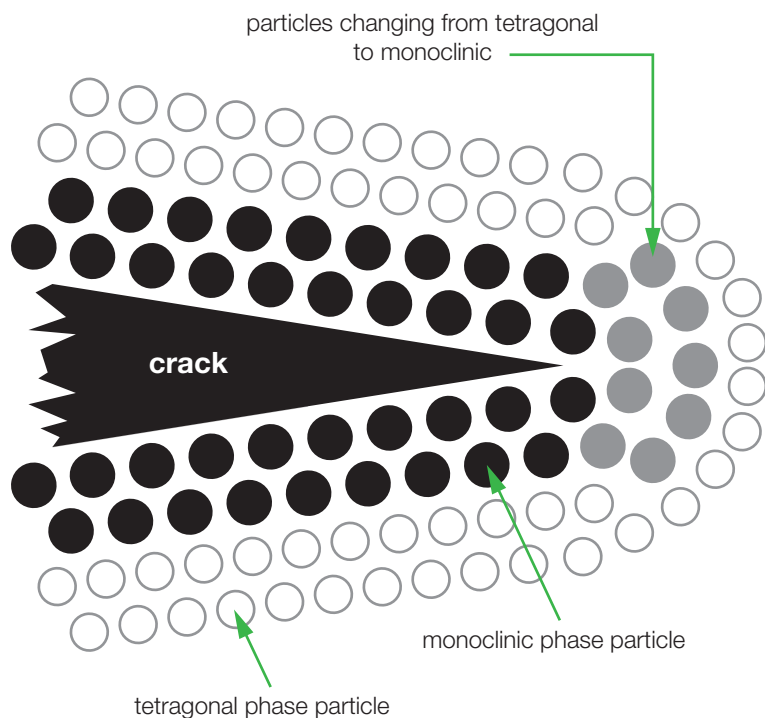
# Aspects of zirconia

## Phase transformation and its clinical relevance

Prof. Dr med. dent. Michael Gahlert, Germany



**Fig. 1a:** The addition of yttrium to zirconium dioxide induces the stabilisation of different phases of the material structure.



**Fig. 1b:** Transformation from a tetragonal phase to a monoclinic phase of the material structure of zirconium dioxide.

### On fracture susceptibility

The material-specific condition of zirconia implants right after the final industrial manufacture, as found by clinicians in the packaging and used by their patients, is referred to as the tetragonal phase condition of zirconium dioxide. “Tetragonal phase” refers to the most stable and resistant condition of ceramic implants that clinicians naturally desire for the safest and most durable treatment for their patients. It is guaranteed through stabilisers such as yttrium oxide, which are added in minute quantities to the starting material during industrial production. Phase transformation is the transition from the fracture-resistant tetragonal phase to the monoclinic, fracture-prone phase. Phase transformations of the material structure must be expected when grinding zirconium dioxide with rotating instruments. Uncontrolled grinding with, for example, coarse-grained diamonds and insufficient cooling of the material results in micro-cracks within the outer surface layer of the material and in the underlying material structure.

This phase transformation is associated with volume expansion and can stop the propagation of mechanically induced micro-cracks in the material structure. However, there are limits to this “self-healing mechanism” of zirconium dioxide. Once the unique compensatory capacity has been exceeded, micro-cracks in the microstructure remain, which can favour the unwanted introduction of water. This, in turn, can lead to an uncontrolled ageing process and consequently to instabilities in the material structure, a fatal development with regard to the tensile strength of the material zirconium dioxide. It thus becomes apparent that incorrect handling of the material has clinical relevance. This example shows that metallic materials are not comparable with ceramic materials. The grinding of titanium is not as clinically relevant, compared with zirconium dioxide. It would be a great mistake to draw conclusions about the processing of ceramic materials from metal processing.

### A brief history of zirconia

During the first stage of development of zirconium dioxide implants at the beginning of the 2000s, high blasting pressure and large particles were used to micro-roughen

**Fig. 2:** Fractured zirconia implant #11. **Fig. 3:** Crown with coronal fracture end of the ceramic implant. **Fig. 4:** Electron-microscopic image of the fractured implant (Prof. Susanne Scherrer, University of Geneva, Switzerland). **Fig. 5:** Detailed electron-microscopic image of the origin of the fracture with radial propagation over the cross-sectional area (Prof. Susanne Scherrer, University of Geneva, Switzerland). **Fig. 6:** Detailed electron-microscopic image of the micro-crack formation on the surface of the ceramic implant caused by processing blasting to generate micro-roughness (Prof. Susanne Scherrer, University of Geneva, Switzerland).

the surface of zirconium dioxide. As a result of this ambitious industrial production process, micro-cracks were found in the surface structure of ceramic implants, which in one case or another led to later fractures under high occlusal forces caused by teeth grinding or chewing, for instance. Even today, a great number of fractures of ceramic implants can be traced back to an improper industrial manufacturing process or the later mechanical handling by the dentist. The process according to which the micro-roughness of the surface of a zirconia implant is achieved has changed over the decades with each stage of evolution of the material and with the newly acquired knowledge about phase transformation. Nevertheless, there are still no industrial standards and therefore different manufacturing techniques that assess these aspects differently. For example, an implant manufacturer offers a lifetime material-specific guarantee for ceramic implants, provided that the implants are not ground by the dentist.




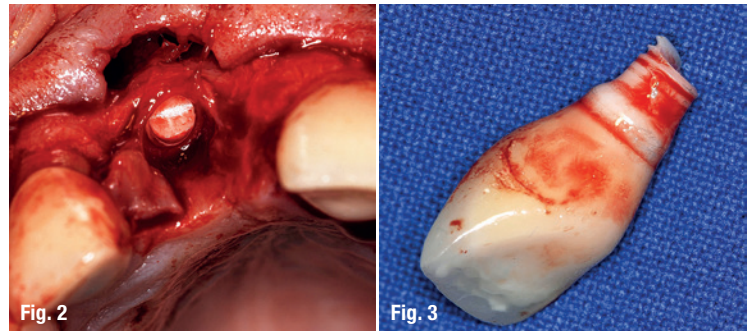
## about the author



**Prof. Dr med. dent. Michael Gahlert** is a fellow of the International Team for Implantology (ITI) and has been specialising on the development and placement of ceramic implants. He works as dentist for oral surgery in a private practice in Munich, Germany. In addition, he is a researcher at the department of Biomedical Engineering of the University of Basel, Switzerland.

## contact

**Prof. Dr med. dent. Michael Gahlert**  
Theatinerstraße 1  
80333 Munich, Germany  
Phone: +49 89 2366800  
www.drgahlert.de



# Why titanium implants create silent inflammation in jawbone

Drs Johann Lechner, Germany & Sammy Noubissi, USA

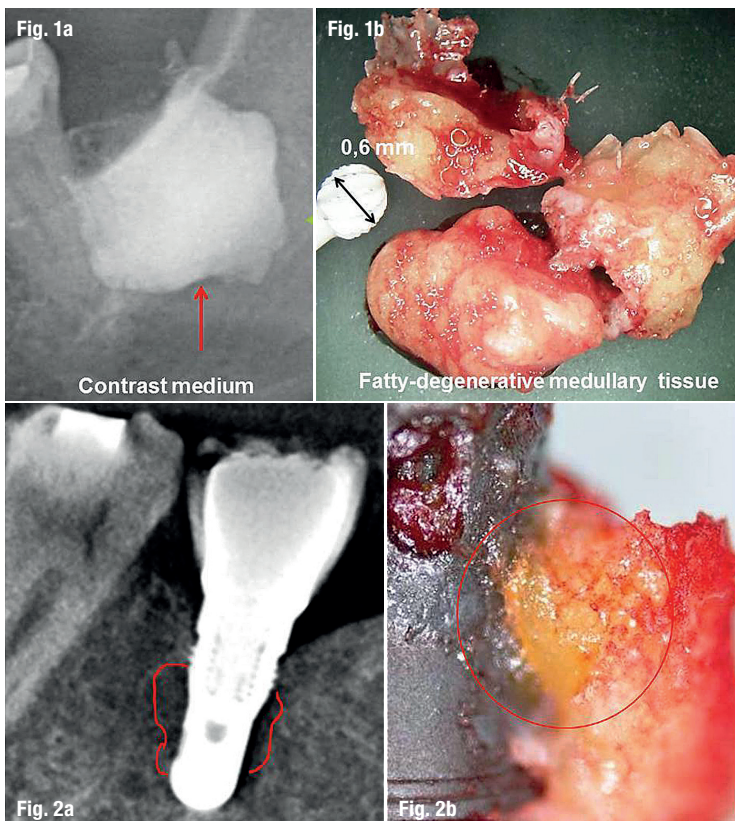
**In dentistry**, one of the most established methods is the replacement of lost or missing teeth with titanium (Ti) implants. However, investigators have found that Ti implants can induce inflammation in the surrounding tissue over time, leading to the expression of certain mediators known to cause chronic diseases through a constantly stimulated immune system.<sup>1-4</sup> These triggers lead to the activation of signalling pathways which favour a predisposition to the development of cancer and autoimmune diseases.<sup>5</sup> Signalling messengers like cytokines carry instructions and are received by those cells with specific receptors which are able to recognise them. In earlier publications, we defined this chronic inflammatory process as fatty-degenerative osteonecrosis in the medul-

lary spaces of the jawbone (FDOJ).<sup>6,7</sup> We started a study to elucidate the transition from acute trauma during the insertion of dental implants to chronic inflammation of the jawbone. Herein, we attempt to define the role of cytokines in areas of FDOJ surrounding implants in a cohort of patients with immune system disorders. We propose the following hypothesis: Ti implants may be a possible contributor to the development of chronic inflammation of the jawbone extending beyond the local condition of peri-implantitis.

We selected a group of patients with well-osseointegrated Ti implants and with clinical symptoms of immune system disorders: seven with rheumatic arthritis, three with neurodegenerative diseases (including chronic fatigue syndrome and multiple sclerosis), one with ovarian cancer and three with atypical facial pain/trigeminal neuralgia. A second mandatory inclusion criterion for the Ti implant group was local diagnosis of FDOJ apically and in areas surrounding Ti implants. All patients were required to have a CBCT scan and measurement of the bone density of the jawbone using trans-alveolar ultrasound technology (TAU). TAU is useful for establishing the presence of FDOJ.<sup>8</sup> In a healthy control group (n = 19), samples of healthy jawbone were removed in the form of drill cores during routine dental implantation surgery. The use of bisphosphonate medication was the main exclusion criterion.

## Clinical features of FDOJ: Definition and diagnostic criteria

FDOJ is a lesion similar to that found in long bones, also primarily defined as “bone marrow edema” and “chronic non-suppurative osteomyelitis”.<sup>9,8</sup> The softening of the bone marrow in FDOJ is very distinct, such that the marrow space may be suctioned out or curetted once the cortical bone has been removed. These hollow spaces, also known as “cavitations” are filled with fatty-degenerated adipocytes which have undergone dystrophic changes accompanied by demyelination of the bony sheath of the inferior alveolar nerve. Figure 1 shows a specimen of predominantly fatty transformation of the jawbone. The extent of the FDOJ lesion in the jawbone is indicated in the radiographic image with a contrast medium.



**Fig. 1:** Contrast medium in affected cavity after curettage (a) and jawbone sample of fatty and osteolytic degenerated bone marrow (b). **Fig. 2:** Titanium implant in area #46 as shown in the CBCT scan (a); fatty-degenerated tissue attached directly to the titanium implant (b).



## Dissolved titanium particles in the jawbone

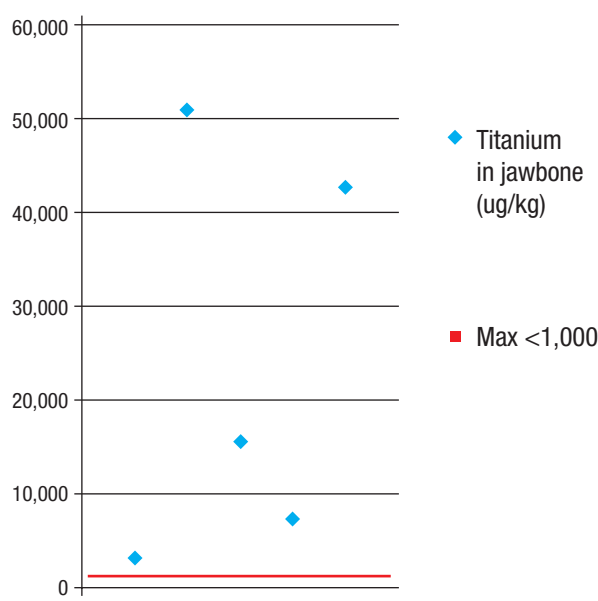
After reports in the literature concerning dissolved Ti particles in the surrounding bone,<sup>10–13</sup> we analysed five of the 14 jawbone samples from the group with FDOJ and Ti implants for levels of dissolved Ti. The amount of dissolved Ti in them ranged from 3,200 to 50,600 µg/kg with a median value of 24,200 µg/kg ( $\pm$  20,029 SD; Fig. 3). As we were unable to find an average maximum content of dissolved Ti which is regarded as biocompatible and acceptable in the literature, we defined the maximum dissolved Ti in healthy bone as 1,000 µg/kg of body weight, which is fourfold higher than the accepted level of all other heavy metals as described in the relevant literature ( $<$  250 µg/kg).

## Titanium dissolution in jawbone and TNF- $\alpha$ expression

Ti particles may dissolve and induce immunological reactions in the body and release systemic messengers. A study presented by Nakashima et al. elucidated the mechanisms of macrophage activation by Ti particles from implant materials and identified the cytokine-bound signalling activated by metal alloy implants via released particles.<sup>14</sup> Macrophages of patients were exposed to particles of Ti alloys taken from the connective tissue surrounding hip implants. Exposure of macrophages to Ti alloy particles *in vitro* over a period of 48 hours resulted in a 40-fold increase in the release of tumour necrosis factor alpha (TNF- $\alpha$ ) and a sevenfold increase in the release of interleukin-6 (IL-6).

## Analysis of cytokine expression in samples of FDOJ

To discern the cytokine patterns found in the jawbone of patients from the corresponding author's dental practice, 14 patients with diagnosed FDOJ in Ti implant sites had surgery on the affected area, including the removal of existing Ti implants. All of the patients displayed FDOJ in the bone marrow adjacent to neighbouring Ti implants, which was similar to FDOJ samples as described previously in the literature<sup>15,16</sup>. FDOJ tissue directly attached to a Ti implant was investigated and the cytokine profiles were evaluated. The corresponding CBCT image in Figure 2 displays no, or only minor, abnormalities in contrast to the significant area of yellowish and softened cancellous bone directly attached to the Ti implant surface. At the IMD Institute for Medical Diagnostics ([www.imd-berlin.de/labor](http://www.imd-berlin.de/labor)), the FDOJ samples were measured for cytokine expression. As we have shown in several previous publications,<sup>6,7</sup> the defining characteristic of FDOJ regions is the overexpression of the pro-inflammatory messenger RANTES (regulated upon activation, normal T-cell expressed and secreted), also known as chemokine C-motif ligand 5 (CCL5). The mean values of the 19 samples



**Fig. 3:** Distribution of dissolved titanium in jawbone surrounding titanium implants in five cases of fatty-degenerative osteonecrosis of the jawbone.

of healthy jawbone (blue columns) and the results of the multiplex analysis of the seven cytokines in the FDOJ and Ti implant cohort (red columns) are shown in Figure 4. Figure 5 presents an example of the type of morphology of FDOJ samples removed from areas adjacent to Ti implants which were collected and subsequently analysed for seven cytokines.

FDOJ is similar to silent or subclinical inflammation without the typical signs of acute inflammation. In chronic inflammation, the local production of inflammatory cytokines, such as TNF- $\alpha$  and IL-1/6, overwhelms regulatory and compensating mechanisms, contributing to the formation of FDOJ in the bone marrow. This phenomenon of an intramedullary source of RANTES/CCL5 (R/C) overexpression appears to be more widespread than dentists and physicians previously presumed. The surgical debridement of FDOJ areas, however, may halt the induction of R/C signalling pathways and thus possibly inhibit the progression of associated symptoms.<sup>17,7</sup>

## Why is this such an enigma in dentistry?

In previous research, we demonstrated the non-visibility and lack of obvious radiographic signs of FDOJ, which make it difficult to obtain an accurate diagnosis using common dental radiographs.<sup>18</sup> As a result, the existence of FDOJ and its systemic implications are largely neglected in today's dentistry. While conventional radiography is limited in its ability to properly reveal FDOJ, other means of identifying the presence of FDOJ are available. To aid the practitioner in diagnosing the bone marrow softening occurring within FDOJ lesions, a computer-assisted TAU device is available.<sup>19</sup> TAU has proven to be