


# IMPLANT TRIBUNE

**Risk Management**


**Dental Protection**



**Implants**  
The key to successful implant dentistry is planning and predictability, says dental Protection.

▶ pages 11–12


**OsseoSpeed**



**Osteoblast differentiation**  
In vivo and in vitro evidence of a bioactive process highlighted by Professor Lyndon Cooper.

▶ pages 14–15

**ADI (UK)**



**Anthony Bendkowski**  
The truth is out there—looking for the evidence behind bone regeneration.

▶ pages 16

**Oral hygiene**



**Implant maintenance**  
Kurtzman and Silverstein stress the importance of implant maintenance and home care.

▶ pages 17–19

**Saadoun**



**Recession**  
Dr. Saadoun investigates the prevention of peri-implant soft tissue recessions.

▶ pages 20–22

## Implants

### The key to successful implant dentistry is planning and predictability



There can be few techniques that have had such a fundamental impact upon restorative dentistry and prosthodontics than osseointegrated implants. It is no great surprise that implants are impacting on the dento-legal front as well.

Not only in terms of problems arising from the provision of implants, but also due to the fact that implants are increasingly being proposed as alternatives to bridgework or dentures as remedial treatment in negligence claims arising from the loss of one or more teeth. This can often drive up the amount of damages claimed by patients, although there is room for doubt that many of the patients receiving these damages ever proceed with the implants that have been proposed for them.

An analysis of the factors that result in negligence claims against dentists relating to implant dentistry (Fig. A) reveals that most of the problems arise from shortfalls in the preliminary stages (ie, patient selection, case assessment, investigations, diagnosis, treatment planning and consent) rather than the treatment itself.

Indeed, many of the problems that result from the procedures themselves can also be traced back to deficiencies in the case assessment and treatment planning stages. Let us now examine some of these issues in more detail.

#### Preliminary Considerations

**Training**  
A number of Dental Boards and Dental Councils around the world have expressed their

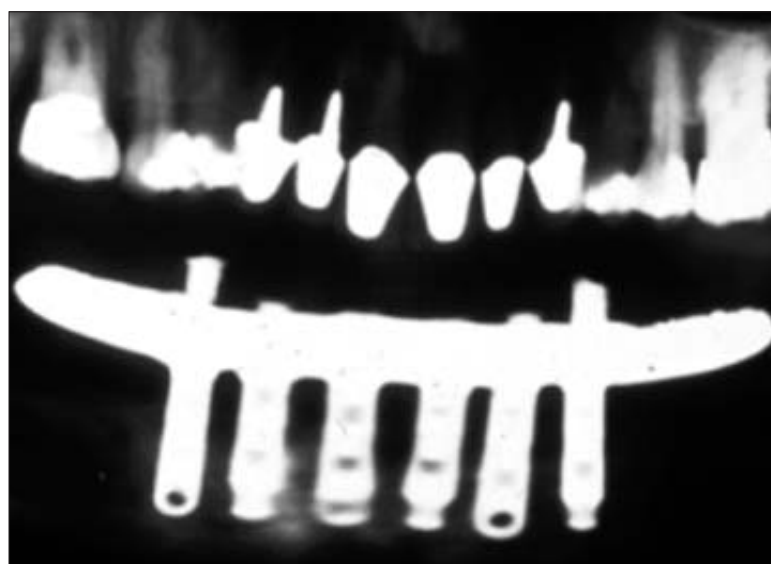


Fig. 1

concern that dentists sometimes get involved in implant procedures without having sufficient knowledge, under-

standing, training and experience to undertake these procedures safely and to an acceptable standard. Furthermore, this same allegation sometimes features in negligence claims as an alleged breach of a dentist's duty of care. Of particular concern is the short training course that is promoted, organised and conducted by those companies and individuals who have a direct commercial interest in expanding the number of dentists who are carrying out these procedures.

#### Team work

The provision of implant treatment requires both surgical and prosthodontic skills, while the diagnostic skills necessarily embrace both disciplines. In many cases, the two phases will be undertaken by different clinicians, and here the provision of the treatment must involve close and regular communication between the clinicians involved, throughout the course of treatment. This is particularly important when one of the clinicians has less experience than the other. The key

to successful implant dentistry is planning and predictability, and all parties involved need to work in harmony, each understanding the practical problems faced by the other.

In most cases, it is logical for the prosthodontist to be the team leader since the implant fixtures are a means to an end and not the end in themselves. To facilitate a successful final outcome, the implant fixtures need to be placed in an optimal position for the treatment that is to follow. A detailed preoperative assessment will help to avoid a situation where, during the surgical procedure, it is discovered that the implant fixtures cannot be placed in the originally intended position.

#### Approaching the Treatment

##### Patient selection

Not every patient who might seem, at first sight, likely to benefit from implants is going to be a suitable candidate for their provision. A number of risk factors (medical, social and psychological) have been identified in the literature, which have the potential to undermine the prognosis for implant dentistry; all of these need to be carefully considered. The provision of implant-supported restorations may be a last-ditch effort to avert the prospect of becoming edentulous and needing to wear complete dentures. On these occasions it is relevant to look back at the factors that led to the patient being in this situation. These might relate to oral hygiene and patient cooperation, to the patient's medical history and to a range of other host factors and tissue response generally.

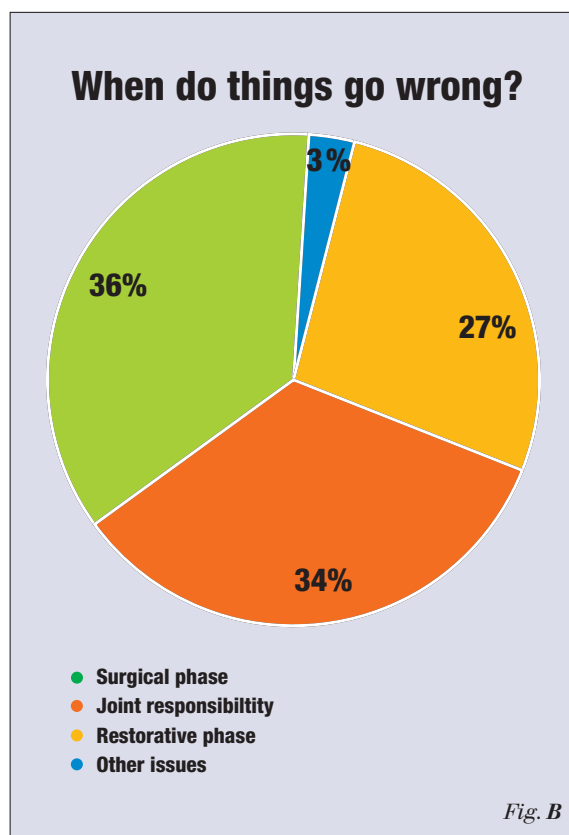
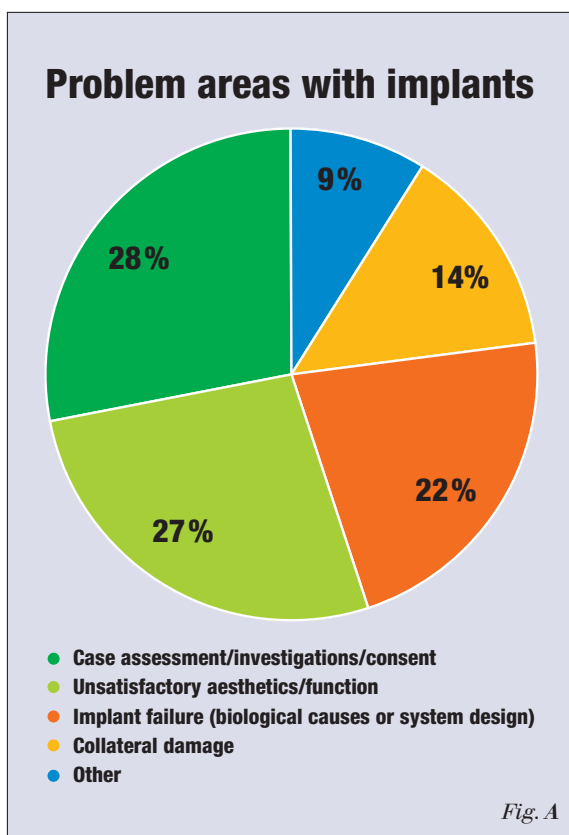
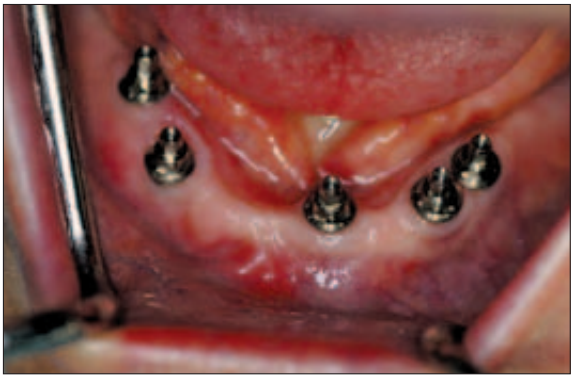



Fig. 2

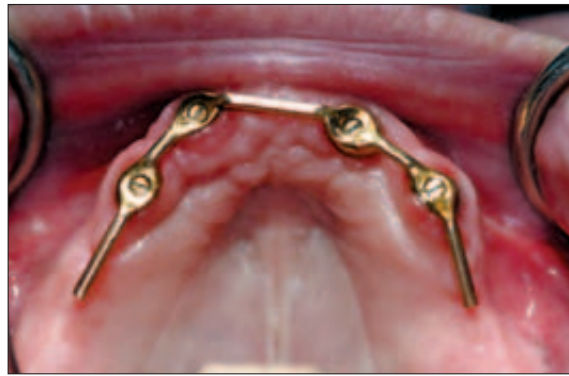

Fig. 3

← **II** page 11

### Systems selection

The use of an appropriate implant system, with a suitable weight of published research evidence to support its use, is essential. Beware of the “copycat” implant system that adopts some of the principles of various other systems, while having no independent research evidence of its own. The credibility of such a system is easily challenged, and this can raise questions of consent unless it has been made entirely clear to the patient, prior to treatment, that the proposed implant system is relatively unproven and/or experimental.

### Investigations

This is a critically important stage in the preliminary assessment of any case that involves implants. A detailed assessment of the hard and soft tissue would normally be accompanied by study models, photographs, radiographs and, if appropriate, cephalometric views, CT scans and 3-D reconstructions. It is essential to confirm that any implant fixture can be placed without damage to adjacent structures, and with sufficient bone available. Bone mapping allows a three-dimensional assessment of proposed implant sites to be made, although the quality of the bone in the proposed site may not be fully determined until the time of operation.

Where bone harvesting (or bone grafting) is necessary for a ridge augmentation, or for raising the floor of the maxillary sinus, proper considera-

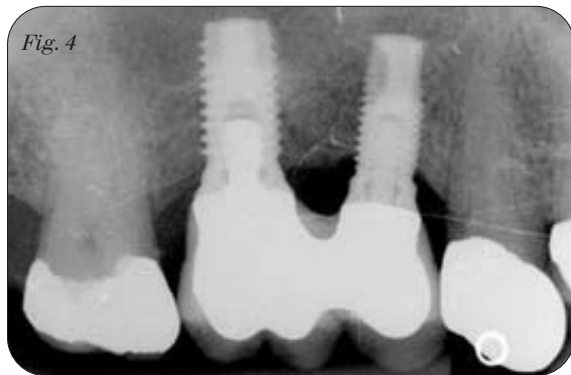


Fig. 4

tion must be given to problems that might be encountered at both the donor and recipient sites. These procedures are a frequent source of problems associated with implant dentistry, and they should never be undertaken without extensive training and experience.

### Consent

It often becomes clear that a clinician has given little or no consideration to any treatment option except that of placing implants. In some cases this is because the patient has been referred to the clinician in question by the patient's regular general dental practitioner, specifically for the purpose of assessing the patient's suitability for implants. In other cases, it appears that the clinician is simply keen to provide implants rather than to consider any alternative options.

In these cases there is a real risk that patients will be “talked into” implants without going through a detailed consent process. Implants are generally only one of many available treatment options, and each of these options needs to have been considered and discussed with the patient in detail. These discussions should include the purpose, nature, risks, benefits, and limitations of each treatment option in

turn. Avoid using universal “blanket” information that does not take into account the specific factors that apply in the situation of an individual patient.

Clinicians who are keen to be involved in implant dentistry might be tempted to spend more time explaining the benefits and predictability of implant dentistry—perhaps with the help of persuasive colour brochures provided by implant manufacturers—while spending less time explaining the potential risks and drawbacks. Many negligence claims arise from a failure to understand and manage the patient's expectations. It is particularly important that the patient should have a clear understanding, at the outset, of the likely appearance and function of the completed restoration, whether this is fixed or removable. By the time the patient is in a position to appreciate the final result at first hand, it is often too late to make fundamental changes to the treatment approach. Given the considerable investment of time, money, inconvenience and discomfort involved in implant procedures, this is likely to result in a very angry and aggrieved patient.

turn. Avoid using universal “blanket” information that does not take into account the specific factors that apply in the situation of an individual patient.

### Record keeping

The clinical records (including any available correspondence and documentation) will often be pivotal in determining the outcome of any complaint or negligence claim relating to implant dentistry. The records should comprehensively demonstrate each of the key stages in the provision of implants.

### Consultation and preliminary discussions.

Why are implants being considered, and at whose suggestion?

- Medical history
- Dental history
- Social history (including details of the patient's employment)
- Assessment of risk factors
- Detailed clinical examination (intra- and extra-oral)
- Investigations (see above)
- Diagnosis
- Provisional treatment plan and costing
- Consent (see above)
- Final treatment plan and costing
- Preliminary treatment (eg, preparation and trial placement of stents or other aids)
- Treatment carried out (including preparatory and preventive treatment and advice)
- Outcome
- Any adverse consequences and their management
- Follow-up and maintenance

### Collateral Damage

Most such damage relates to the surgical phase, which possibly explains why this phase does seem to be responsible for the larger share of the total problems encountered (Fig. B). Damage to the inferior dental nerve or the mental nerve is the problem most commonly encountered in the mandible, although lingual nerve damage and complications involving the maxillary sinus or adjacent natural teeth, are not uncommon in certain situations.

### Contractual Issues

Because of the cost involved in implant dentistry, the technical nature of the procedures, and their unfamiliarity to most patients, it is essential to explain the proposed treatment and the associated costs in advance and in writing. Try to use language that the patient is likely to understand, and avoid technical jargon.

It should be made clear if the fees quoted are an estimate and/or illustration, or a firm quotation of the treatment that is to be provided and the costs involved. If, as can happen in implant dentistry, the treatment plan subsequently changes for any reason, it is prudent to confirm the revised treatment plan and associated costs in writing once again. Many disputes have arisen from a breakdown in communication where such changes have been explained to the patient verbally, perhaps at a time when they were nervous or distracted, and less able to listen to and appreciate the information being provided for them.

Details that have created problems in the past include:

- The number of fixtures to be placed.
- The insertion of reserve fixtures (“sleepers”), which are not subsequently used to support the final restoration.
- The number and type of implant components required.

- The materials to be used.
- The design of the final restoration.

Patients cannot be expected to appreciate fine distinctions and technical details such as these unless the clinician takes the time to explain them. Similarly, the provision of treatment that is different in nature or extent to that agreed with the patient can result in allegations of breach of contract, as well as of negligence.

### Summary

There has been a steady increase in the provision of implants. It appears that they are being placed in more clinical situations, by more clinicians than ever before. Not all of these clinicians can demonstrate that they have received adequate formal training and supervision, and have sufficient technical knowledge and experience, to carry out these procedures safely and successfully. This factor causes great concern for the future. Furthermore, our patients are living longer and the fast-evolving science and technology of implant dentistry is perhaps leading some clinicians into this field who might otherwise have been prepared to refer their patients on to more experienced colleagues. While this increased clinical ambition is understandable, it is important for dentists to be aware that this is a potentially high-risk field for the inexperienced. In the longer term, the greatest threat to clinicians may well come not from negligence claims, but from the activities of regulatory bodies around the world. These organisations are becoming increasingly intolerant of dentists (and doctors) who show an apparent disregard for their responsibilities to patients and the quality of patient care in undertaking procedures for which they are not sufficiently skilled and trained. **III**

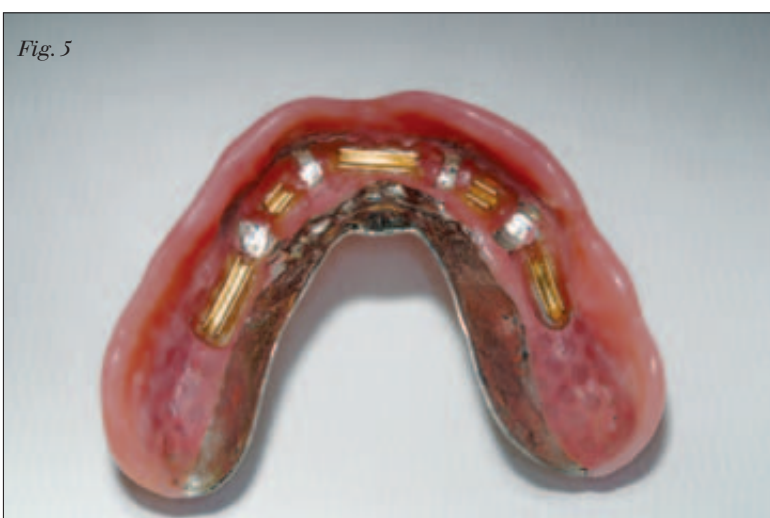

Fig. 5

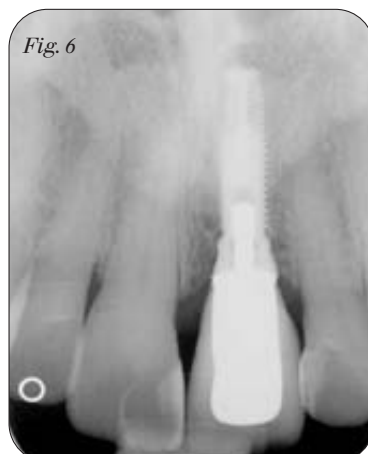

Fig. 6

### Contact Info

**Dental Protection** 

We are the world's largest specialist provider of dental professional indemnity and risk management for the whole dental team. The articles in this series are based upon Dental Protection's 100 years of experience, currently handling more than 8,000 cases for over 49,500 members in 70 Countries.

33 Cavendish Square  
London W1G 0PS, UK  
E-mail: [Generalenquiries@querydent@mps.org.uk](mailto:Generalenquiries@querydent@mps.org.uk)

The complete set of 36 risk management modules can be ordered from [lynne.moorcroft@mps.org.uk](mailto:lynne.moorcroft@mps.org.uk)

[www.dentalprotection.org](http://www.dentalprotection.org)



# In vivo and in vitro evidence of a bioactive process

## Osteoblast differentiation highlights the success of OsseoSpeed™

**B**one is formed by osteoblasts derived from uncommitted mesenchymal stem cells. After implant surgery the biomaterial surface is populated by these

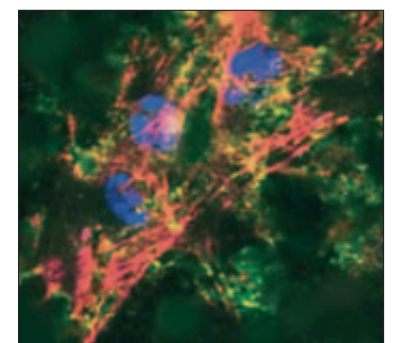
progenitor cells and eventually bone is formed directly along the surface. Astra Tech embarked on a research program to define a method of modifying the TiOblast™ surface to

support even more rapid bone formation by the implant surface-adherent cell. The discovery that ionic fluoride modification of the TiOblast™ surface improved the bone-to-im-

plant interface resulted in an intensive research program and development of an improved dental implant surface, namely the OsseoSpeed™ surface.

### Clinical challenges to osseointegration

Today, there are indications for dental implants that challenge osseointegration's success, including type IV bone, implant placement in extraction sockets, and immediate loading of dental implants. Further improvement in the rate and the amount of bone formation at implants may overcome these clinical challenges. OsseoSpeed™ has the potential to provide these improvements.



The confocal microscopic image reveals the cellular cytoskeleton (red) of three cells tightly adherent to the OsseoSpeed™ surface. A second cytosolic protein is stained yellow. A DNA specific dye prominently reveals the nuclei of the adherent cells. Using cell and molecular biology techniques, the development of the OsseoSpeed™ surface included the study of gene regulation in the adherent cell nuclei. Beyond engineering of a surface to support cell attachment, careful consideration of gene regulation by the OsseoSpeed™ adherent cells suggests rapid differentiation of adherent cells along the osteoblastic lineage.

### Studies confirm greater osteoblast differentiation

One way to examine the role of an implant surface in bone formation is to measure stem cell differentiation to osteoblasts in the cell culture laboratory, as Professor Cooper did at the University of North Carolina. When human mesenchymal stem cells were cultured on TiOblast™ surfaces modified with ionic fluoride, the rate and extent of osteoblast differentiation was greater than on the same surface without fluoride modification. An excellent indicator of osteoblast differentiation is the increased level of Bone Sialoprotein (BSP). Measurement of BSP after 14 days revealed that three times more BSP was made by cells grown on fluoride-modified surfaces than on unmodified ones. This important initial finding was reproduced in three different independent experimental models. The tests were carried out completely 'blind' on the samples sent from Astra Tech in Sweden. "I wanted to know what they were sending me, but I was told that the whole procedure had to be kept completely blind," says Professor Cooper. "They were not going to tell me anything until we had finished."

# The Clinical Innovations Conference 2008

2nd DTI World Congress 



Earn up  
to 14 hours  
verifiable  
CPD

**Friday 16th, Saturday 17th May 2008**

The world's leading thinkers in Aesthetic and Restorative dentistry are coming together again in 2008 – for the 5th year running - to share their experience and knowledge in the heart of London's Regents Park. Our approach is to gather together the finest brains from around the planet offering a unique experience in a fantastic setting.

We have some exciting names joining us this year.

Already confirmed: **Nasser Bargi, Dan Nathanson, Liviu Steier, Sandesh Mayekar, Linda Greenwall, George Freedman, Fay Goldstep, Wyman Chan, Howard Glazer, Nigel Pitts**

#### Venue

Regent's College, Inner Circle  
Regents Park, London, NW1 4NS

For more information

call **020 7400 8989** or visit  
[www.clinicalinnovations.co.uk](http://www.clinicalinnovations.co.uk)

**DENTAL TRIBUNE**  
— The World's Dental Newspaper - United Kingdom Edition —

 **smile-on Ltd**  
Inspiring Better Care



**Positive effects on adherent stem cells**

Additional details of the OsseoSpeed™ surface's effect on the adherent stem cell have recently emerged. For example, human mesenchymal stem cells produced 2.3 times more of the key regulator for osteogenesis (cbfa1) when they were grown for only one day on OsseoSpeed™ compared with TiOblast™. More information from genome-wide micro array analysis of the adherent cells' behavior indicates that specific signal transduction pathways important to cell proliferation and differentiation are upregulated within the OsseoSpeed™ adherent cell. Micro array analysis comparing cells cultured on the TiOblast™ and fluoride-modified surfaces showed the presence of a number of key 'enabler' genes that play an important role in osteogenesis.

**'Human stem cell and molecular research shows there is a bioactive process at work when the OsseoSpeed™ surface is in contact with human bone tissue,' says Professor Lyndon Cooper, at the Department of Prosthodontics, University of North Carolina, USA.**

**In vivo tests confirm in vitro findings**

Having established in vitro that the fluoride-modified TiOblast™ surfaces accelerated the process of osteogenesis, Professor Cooper then conducted in vivo tests to investigate if this would also be reflected in a greater bone-to-implant contact area. The surfaces used in the stem cell research were supplied in implant form and fixed in rat tibiae. The results were consistent with the in vitro findings: after three weeks, it was found that the OsseoSpeed™ surfaces that had stimulated the highest levels of BSP also produced a greater bone-to-implant area of contact (55.45% vs 34.21%) at the early 3-week point in time. The parallel cell culture studies suggest this effect is due to surface modification-dependent increases in adherent cell osteogenesis.

**Exciting clinical opportunities**

Professor Cooper says he is excited about the new opportunities that OsseoSpeed™ can provide for clinicians. The clear conclusion from his work is that the implant surface can be an active component of clinical success. A relatively small, but effective fluoride modification of the TiOblast™ surface is associated with greater osteoblast differentiation of ad-

herent mesenchymal stem cells as well as increased bone-to-implant contact in vivo. The advantages of more rapid and greater bone formation around dental implants may be clinically realized.

**Summary**

To examine the role of an implant surface in bone formation, Professor Cooper measured stem cell differentiation to osteoblasts in the cell culture laboratory. When human mes-

enchymal stem cells were cultured on TiOblast™ surfaces modified with ionic fluoride, the rate and extent of osteoblast differentiation was greater than on the same surface without fluoride modification. In fact, measurement of Bone Sialoprotein (BSP) after 14 days revealed that three times more BSP was made by cells grown on fluoride-modified surfaces than on unmodified ones. In addition, micro array analysis comparing cells cultured on

the TiOblast™ and fluoride-modified surfaces showed the presence of a number of key 'enabler' genes that play an important role in osteogenesis. Results from in vivo studies are consistent with the in vitro findings. ■

**Interviewed:**  
**Professor Lyndon F. Cooper, DDS, PhD, Department of Prosthodontics, University of North Carolina, School of Dentistry, North Carolina, USA**



Professor Lyndon F. Cooper

PracticeWorks  
Exclusive makers of **Kodak** Dental Systems

## Leading the way to a brighter future

In the current economic climate of money market uncertainty, the ongoing PCT funding and contract concerns, your practice management and business skills will need to be fit for the future.

Maximising your income and minimising your costs in every area of your practice will be key to success in the difficult times being forecast.

However, you can stay one step ahead of these additional challenges at the same time as improving your business and, safeguarding your future.

It's so easy to do with our market leading practice management and new business software.

**NEW**  
**KODAK Back Office Business Software & KODAK R4 Practice Management Software**

Packed with more features than any other Dental Software, designed to make a significant contribution to the success of your practice and your business

Staff Records • Payroll • Purchase Ledger • Nominal Ledger • Bank • Petty Cash • Stock Control • Comprehensive Reporting • Patient Central Appointment Book  
Today • Messenger • Integrated Digital Images • Patient Education and Presentations • Clinical Charting and Treatment Plans  
Text Messaging • Communications Centre • Online Appointment Booking • Credit Card Processing

### Offering security in an uncertain world

**For further information or to place an order  
telephone 0800 169 9692  
or visit [www.practiceworks.co.uk](http://www.practiceworks.co.uk)**





# The truth is out there – looking for the evidence behind bone regeneration

By Anthony Bendkowski oral surgeon and president of the Association of Dental Implantology (UK)

It is widely recognised that one of the key factors contributing to the long term success of dental implants is the quantity and quality of supporting bone. When undertaking implant surgery we are frequently faced with defects in the bone that are a consequence of previous underlying periodontal disease, infection or the trauma associated with the preceding extractions.

Even a minor bony defect can be a significant barrier where the correct placement of implants is concerned. Without appropriate bone support there is often less than optimal soft tissue profile and consequent compromise in the aesthetic outcome. As clinicians, we are fortunate that bone has a unique potential for regeneration without scarring, provided it is given the correct environment in which to do so.

The vascular and mechanical considerations are important, as is the need for contact with underlying sound living tissue together with passive tension free primary soft tissue closure. The fibrin clot serves as the initial calcifiable matrix containing a concentration of calcium and phosphate ions onto which precursor cells can migrate. This clot needs protection from mechanical stress as any distortion or disruption can profoundly impair the regeneration process.

A further major hindrance to new bone growth is the rapid formation and ingrowth of soft tissue in competition with the slower forming bone regrowth. Fibroblasts have a faster rate of migration than osteoblasts and their proliferation may totally prevent osteogenesis. It is therefore desirable

that the soft tissues are excluded from the graft site. This can either be achieved by the use of a barrier membrane, either laid or pinned in place over the underlying particulate graft, rather like a tarpaulin covering a mound of sand or by incorporating an additional hard-setting resorbable chemical phase into the graft material which acts as a barrier to soft tissue downgrowth.

The general term **Guided Bone Regeneration (GBR)** has been applied to procedures that attempt to regenerate bone, either prior to or at the same time as the placement of dental implants. GBR is accomplished using bone graft materials such as autogenous bone, xenografts, human donor grafts, as well as various synthetic ceramic materials, usu-

ally also in association with a bio-compatible membrane.

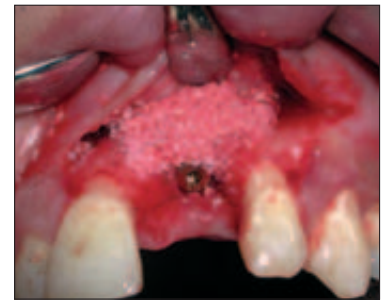As already mentioned, the use of a membrane ensures that competitive cells do not invade the area where we want new bone to regenerate. The mechanical barrier provided by the membrane offers a means of excluding mucosal tissue and epithelial cells that would interfere with bone healing from the clot. This permits the slower bone-producing osteoblasts to facilitate clot organization and produce unimpeded osseous healing.

GBR membrane materials must maintain the integrity of their barrier function long enough to allow osteoblasts to migrate into the wound. Both resorbable and non-resorbable membranes have been used as a GBR barrier. However, non-resorbable membranes such as e-PTFE, although effective, must be surgically removed after the healing period. A resorbable membrane that can transmit tissue fluid, but excludes undesired cells from the clot, has the advantage of not requiring surgical removal. Examples of resorbable membranes include bovine and porcine collagen, PLLA-PGA polymers and calcium phosphate.

The science, application and clinical effectiveness of the various bone graft materials, whether autograft, allograft, xenograft or alloplast, is currently one of the most controversial in implantology and periodontology. Autografts may still be considered by many surgeons to be the graft of choice for specific indications, but there is no current consensus regarding the most appropriate materials for each clinical situation.

There is still much work to be done in this field and we still await the production of good quality randomised controlled trials. Recent years have seen more development of synthetic based bone augmentation materials and a decrease in the prescription of human derived bone substitutes.

The ideal graft material should preferably be gradually resorbed and fully replaced by vital bone that is subsequently remodelled into a natural bone structure that is capable of supporting implants restored into the occlusion. If the implanted material does not fully resorb, as is the case with some hydroxyapatites, the incorporation is restricted to bone apposition to the material surface, but no substitution occurs during the remodelling phase. This may be desirable for cases where simple ridge preservation or augmentation is required, eg to help stabilise conventional removable prostheses or improve soft tissue outcomes



*Guided Bone Regeneration*

around conventional pontics, but is not so desirable in implantology.

As clinicians, we have a professional duty to discuss treatment options with our patients and only undertake those procedures which have a reasonable likelihood of a favourable outcome. This is particularly true of elective surgery such as dental implantology and associated bone augmentation procedures.

The gold standard for evidence supporting clinical practice is the randomised controlled trial. Unfortunately in dental implantology, as in many other branches of clinical practice, we are faced with a relative lack of high quality trials of this type. Around the world, researchers are working towards this gold standard, but much of the important evidence is still to emerge.

Before prescribing materials and treatments for bone augmentation, clinicians need to arrive at their own conclusions from the available information regarding the suitability of these materials and their limitations.

In recent years I have come to the conclusion that it is no small challenge to assimilate this information in an impartial way and free from commercial influence. Discussion with colleagues and much of the literature only really extends to anecdotal information and small groups of case studies or presentations. For some time I have nurtured a desire to put together a specialised meeting dedicated to reviewing the choice of materials available as bone substitutes.

One of my first initiatives, therefore, on recently taking over the presidency of the Association of Dental Implantology was to organise the forthcoming meeting – Focus on Bone Substitutes – to be held at the Manchester Conference Centre on Monday 28th April 2008.

This full day symposium will examine both the biological basis, as well as the evidence supporting the clinical use of the currently available bone augmentation materials. During the day, seven renowned experts will present the evidence for both xenografts and synthetic materials. Specifically, the performance of these materials in both alveolar ridge reconstruction and sinus augmentation will be highlighted.

Following this meeting, clinicians should be in a better position to critically evaluate the evidence supporting the techniques currently available for bone regeneration in day to day clinical practice. The truth is certainly out there to be discovered. ■

## FOCUS ON BONE SUBSTITUTES

A FULL DAY SYMPOSIUM

Zvi Artzi

Nick Donos

Marco Esposito

Christian Mertens

Michael Norton

Frank Schwartz

Pascal Valentini

Date: 28 April 2008

Venue: The Weston Building  
Manchester Conference Centre



**BOOK  
ONLINE NOW**  
[www.adi.org.uk](http://www.adi.org.uk)



# Oral hygiene and dental implants maintenance

By Gregori M. Kurtzman, DDS, MAGD, DICOI and Lee H. Silverstein, DDS, MS

Dentistry has become so exciting and challenging since predictability has been recognized for long-term dental implant and restoration success<sup>1-3</sup>. As the number of patients selecting dental implants as a treatment option continues to grow, the dental team must accept the challenges of maintaining these sometimes complex restorations.

Proper monitoring and maintenance is essential to ensure the longevity of the dental implant and its associated restoration through a combination of appropriate professional care and effective patient oral hygiene<sup>4,5</sup>. The value of using conventional periodontal parameters to determine peri-implant health is not clearly evident in the literature<sup>4</sup>. Therefore, it is paramount that the dental implant team understands the similarities and distinctions between the dental implant and the natural tooth. Subsequently, by examining the similarities and differences between a natural tooth and a dental implant, basic guidelines can be provided for maintaining the long-term health of the dental implant.

Direct anchorage of alveolar bone to a dental implant body provides a foundation to support a prosthesis and transmits occlusal forces to the alveolar bone. This is the definition of osseointegration<sup>6</sup>. With the increased acceptance of dental implants as a viable treatment option for the restoration of a partially edentulous or edentulous mouth, the dental team is faced with maintaining and educating those patients.

Recently, the focus of implant dentistry has changed from obtaining osseointegration, which is highly predictable, to the long-term maintenance health of the peri-implant hard and soft tissues. This can be achieved through appropriate professional care, patient cooperation, and effective home care<sup>7</sup>. Patients must accept the responsibility for being co-therapists in maintenance therapy, so the dental team essentially must screen the potential implant patient. Diagnosis and treatment planning based on a risk-benefit analysis should be performed subsequent to a thorough medical, dental, head-and-neck, psychological, temporomandibular disorder and radiographic examination.<sup>8</sup>

There is convincing evidence that bacterial plaque not only

*from the inventor of the interdental brush*

7mm cleaning access    5mm cleaning access    4.4mm cleaning access    1.3mm cleaning access



The Implant Range of interdental brushes from Curaprox provide your patients with the right tools to take the best care of their implants.

The durable wire core is reinforced and plastic-coated to protect sensitive titanium implants. Bent into a curved shape, they offer the strength and flexibility to clean effectively.

Curaprox invented the very first interdental brushes, now with over 30 years experience of designing and perfecting the most durable and effective brushes on the market.

The Implant Range is available in a range of access radii from 1.3mm to 2mm with effective cleaning radii of 3mm to 7mm.

As with all Curaprox interdental brushes they are completely interchangeable with any of the handles we produce.

The Implant Range is also now available in the Handy Range style, coloured coded for easy selection, with matching pocket-sized handles.

Call us now for more information on 01480 862084.

**Implant Range**

Curaprox UK Ltd  
Unit 11 Harvard Industrial Estate  
Kimbolton  
Cambridgeshire PE28 0NJ  
Tel: 01480 862084 Fax: 01480 862083  
[www.curaprox.co.uk](http://www.curaprox.co.uk)

**CURAPROX**  
UK  
SWISS DENTAL LIFE SCIENCE 



← II page 17

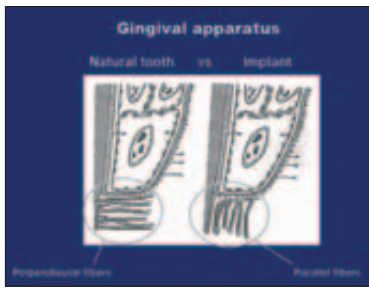


Fig. 1: Comparison of crestal gingival fiber orientation.




Fig. 2: Microscopic comparison of gingival fiber orientation (natural tooth on left, implant on right).

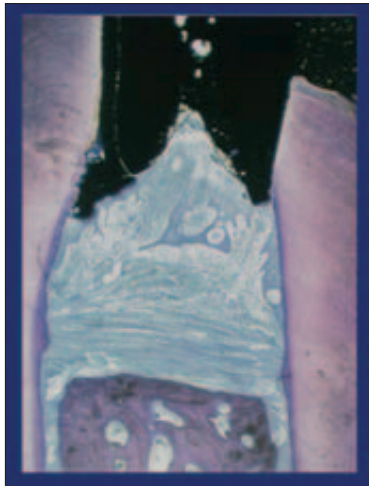

Fig. 3: Gingival fibers between 2 natural teeth showing orientation perpendicular to the long axis of the teeth.

leads to gingivitis and periodontitis<sup>9</sup>, but also can induce the development of peri-implantitis<sup>10</sup>. Thus, personal oral hygiene must begin at the time of dental implant placement and should be modified using various adjunctive aids for oral hygiene to effectively clean the altered morphology of the peri-implant region before, during, and after implant placement. For instance, interproximal brushes can penetrate up to 5mm into a gingival sulcus or pocket and may effectively clean the peri-implant sulcus<sup>11</sup>. In addition to mechanical plaque control, daily rinses using 0.1% chlorhexidine gluconate or Listerine<sup>12</sup> provide a welcome adjunct.

Hygiene with dental implants is so tedious and critical to their long-term success that the patient and dental professional must exercise considerable effort. During the maintenance visit, the dental professional should concentrate on the peri-implant tissue margin, implant body, prosthetic abutment to implant collar connection, and the prosthesis<sup>15</sup>.

Clinical inspection for signs of inflammation, ie. bleeding on probing, exudate, mobility, probe-able pockets, and a radiographic evaluation of the peri-implant bony housing still remains the standard mode for evaluating the long-term status of endosseous dental implants. For instance, successful and stable endosseous dental implants exhibit no mobility. But, if there is

clinically perceptible mobility, then subsequent to radiographic evaluation of the implant and its surrounding bony housing, the abutment retaining screw<sup>14</sup>, and/or prosthetic abutment collar interface should be examined for looseness or breakage.

All these modes of clinical assessment are used routinely, except for periodontal probing around peri-implant tissues that appear to be in a state of good health. The baseline data and data from subsequent recall visits should be recorded in the daily progress notes to properly assess the peri-implant status longitudinally.

Subsequent to a thorough intraoral examination, unless there is visual evidence of soft tissue changes, ie. inflammation of peri-implant tissue with even slight attachment loss or mucositis, routine probing of the peri-implant tissue should not be performed.

Usually during the first year subsequent to restoring dental implants, a 3-month recall schedule should be implemented, especially if the patient lost teeth because of periodontal disease. But if after 12 months, the patient's implants are stable and peri-implant tissues are healthy, then a 4-6 month recall regimen can be implemented<sup>15</sup>. However, be cognizant of each patient's level of home care effectiveness, systemic health, and periodontal status of the peri-implant tissue when determining these recall intervals.

With dental implant patients, the dental professional must evaluate the prosthetic components for plaque, calculus, and the stability of the implant abutment. Radiographs of dental implants should be taken every 12 to 18 months during these maintenance visits<sup>16</sup>. For dental implant restorations that are screw retained, the dental professional needs to remove the prosthesis at least once a year to more easily assess the status of the peri-implant's hard and soft tissues, the existence of acceptable mobility of the prosthetic components or the implant fixture itself, and the patient's level of home care effectiveness<sup>17</sup>. Remember that the presence of any symptoms of infection, radiographic evidence of peri-implant bone loss, and/or neuropathies may be indicative of an ailing or failing implant<sup>18</sup>.

### Implants vs natural teeth

It is essential to understand the periodontal relationship between the gingiva and the structure it attaches to be it a natural tooth or an implant. (Figs. 1 and 2) The fiber orientation of the gingival cuff around a natural tooth attaches perpendicular to the long axis of the tooth. (Fig. 3) This acts as a barrier when insertion of a periodontal probe within the sulcus. The probe tip advances apically till the tip contacts the perpendicular fibers and is halted. This orientation is not seen around implants. With an implant the gingival fiber orientation is parallel to the im-

plants long axis. (Fig. 4) When a periodontal probe is inserted into the sulcus around an implant the probe tip advances passing between the fibers of the gingival cuff till the crestal bone prevents it from further advancement.

The peri-implant mucosal seal may be less effective barrier to bacterial plaque than the periodontium around a natural tooth, tissue attachment<sup>19</sup>. There is less vasculature in the gingival tissue surrounding dental implants compared to natural teeth. This reduced vascularity concomitant with parallel-oriented collagen fibers adjacent to the body of any dental implant make dental implants more vulnerable to bacterial insult<sup>20</sup>. During recall appointments, peri-implant periodontal probing should be performed only where signs of infection are present, ie. exudate, swelling, bleeding on probing, inflamed peri-implant soft tissue, and/or radiographic evidence of peri-implant alveolar bone loss. Lastly, routine periodontal probing of dental implants should not be performed, because this procedure could damage the weak epithelial attachment around dental implants, possibly creating a pathway for the ingress of periodontal pathogens<sup>21</sup>. Commercially available plastic probes should be used when investigating the crevicular depth around dental implants. The probing depth around dental implants may be related closely to the thickness and type of mucosa surrounding the implant. A healthy peri-implant sulcus has been reported to range from 1.5 to 3.8mm, which is greater than those depths reported for natural teeth<sup>22</sup>. In essence, the best indicator for evaluating an unhealthy site would be probing data gathered longitudinally<sup>23</sup>.

For all of these reasons, personal home care and consistent professional maintenance have proven to be critical to the success and longevity of endosseous dental implants. This is especially true in an environment with adjacent natural teeth, which if affected by periodontal disease, could act as a reservoir for pathogenic bacteria, ie. gram-negative anaerobic rods, and seed the peri-implant sulcus<sup>24</sup>.

The physical characteristics of the peri-implant soft tissue are the focus of all oral hygiene instruction. The presence or absence of keratinized tissue in this critical area has not been unequivocally documented to state that peri-implant tissues are more vulnerable to the ingress of pathogenic bacteria with or without keratinized tissue being present around dental implants. However, the ability of the patient to maintain good home care around dental implants is facilitated by the presence of keratinized tissue surrounding implants. Thus, if a patient has no keratinized tissue around an implant, and a pull from a frenum or a chronic peri-implant mucositis exists, then placement of a soft tissue autogenous or alloplastic connective tissue graft is recommended to facilitate proper mechanical oral hygiene maintenance.<sup>25</sup>




Fig. 4: Gingival fibers between 2 implants showing orientation parallel with the long axis of the implants.



Fig. 5: Plastic curettes for scaling dental implants and demonstration of the implant surface after use. Note that there is no alteration to the surface.

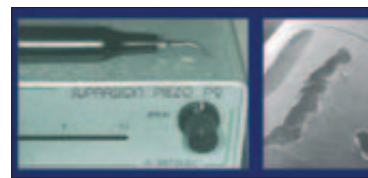

Fig. 8: Demonstration of gouging of the implant surface that may occur following use of an ultrasonic scaler.

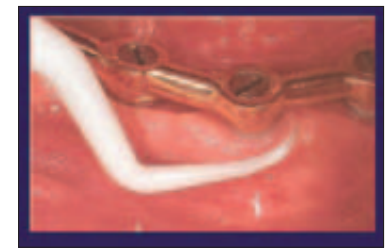

Fig. 6: Plastic scaler used for recall maintenance.

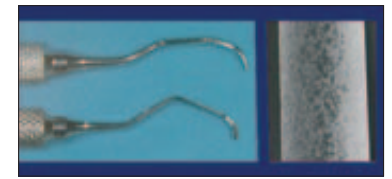

Fig. 7: Alteration of implant surface after use of stainless steel scalers.



Fig. 9: Demonstration of alteration of the implant surface following application of an air polisher and baking soda. Note the change in surface texture.

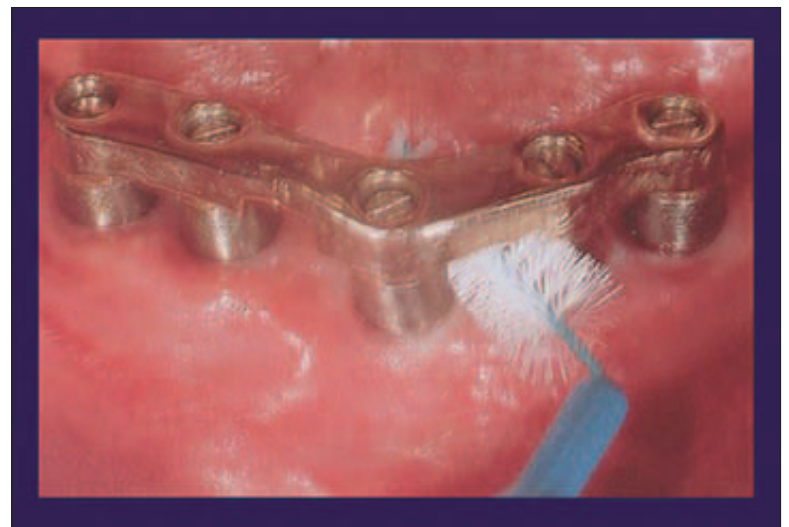

Fig. 10: Plastic-coated interproximal brush applied around implant abutments and under the superstructure for plaque removal.

Specific criteria for obtaining clinical data around dental implants that would allow proper monitoring and detect early possible failure of osseointegrated dental implants has not been clearly defined. Presently, the presence of mobility is the best indicator for diagnosis of implant failure. As opposed to natural teeth, dental implants exhibit minimal clinically undetectable movement because of the absence of a periodontal ligament. Therefore, healthy implants should appear nonmobile, even in the presence of peri-implant bone loss, if an adequate amount of supporting alveolar bone still exists<sup>26</sup>.

When monitoring the health of the peri-implant soft tissues, the practitioner should be cognizant of changes in soft tissue color, contour, and consistency. The presence of a fistulous tract could indicate the presence of a pathologic process or implant fracture.

### Bleeding

There is controversy in the literature as to the accuracy and significance of bleeding upon probing around dental implants. Presently, the literature advocates the use of bleeding on probing as an indicator of peri-implant disease, because it can occur prior to histologic signs of inflamma-

tion or concurrently with other signs of implant failure, ie. bone loss. However, as previously mentioned, routine probing is not recommended.

### Radiographic evaluation

Radiographic interpretation is one of the most useful clinical parameters for evaluating the status of an endosseous dental implant. Invasion of biologic width, predictable remodeling, or so-called saucerization, is an average marginal bone loss of 1.5.. during the first year following prosthetic rehabilitation followed by an average of 0.2mm of vertical bone loss every subsequent year. Thus, progressive bone loss around a dental implant that exceeds these averages may be indicative of an ailing or failing implant. Lastly, during radiographic evaluation, no evidence of a peri-implant radiolucency should be found, because such a rarefaction usually indicates infection or failure to osseointegration<sup>27</sup>.

### Professional cleaning instrumentation

Instruments made of metal, such as stainless steel, should be limited to natural teeth and not to be used to probe or scale dental implants. The rationale for this well-documented and spoken conclusion is that this metal is so hard it can scratch, contaminate,



or cause a galvanic reaction at the implant-abutment interface<sup>28</sup>.

Ideally, hand periodontal scalers for cleaning dental implants can be plastic, Teflon, gold-plated, or made of wood (Figs. 5 and 6)<sup>29</sup>. When using gold-plated curettes, the manufacturer recommends not sharpening these hygiene instruments, as the gold surface could be chipped exposing the hand metal underneath this coating. Stainless steel scaling instruments may abraid the implant surface, stripping off any surface treatment such as hydroxyapatite (HA) as the instruments hardness is greater than the titanium alloy the implant is fabricated from. (Fig. 7)

Other cleaning armamentarium contraindicated for use with dental implants are air powder abrasive units, flour or pumice for polishing, and sonic and ultrasonic scaling units<sup>30</sup>. Ultrasonic, piezo or sonic scaler tips may mar the implants surface leading to microroughness and plaque accumulation. The stainless steel tip may also lead to gouging of the implants polished collar. (Fig. 8) However, some clinicians advocate using a sonic instrument with a plastic sleeve over the tip for scaling dental implants. Air powder polishing units may also damage the implant surface and should be avoided during hygiene appointments. (Fig. 9) Even the use of baking soda powder in these units may strip off any surface coating on the implant. Additionally, the air pressure may detach the soft tissue connection with the coronal of the implant leading to emphysema.

Titanium or titanium alloy surfaces of dental implants can be polished using a rubber cup along with a nonabrasive polishing paste or a gauze strip with tin oxide. Not only is the hygiene armamentarium important, but so are the home care techniques used to maintain endosseous dental implants. Patients should be taught the modified bass technique of brushing using a medium-sized head, soft-bristled toothbrush. The use of intradental brushes should be used by implant patients after being shown their proper use. The plastic-coated wire brush is the only type to be used with dental implants to clean and not scratch the implant surface (Fig. 10).

Recently, automated mechanical toothbrushes have been advocated as a daily mode of tooth cleansing. These devices may be a rotary, circular, or sonic type. With these home care instruments, the key to their effectiveness is proper instruction on their use and then diligent daily use by the implant patient.

As with natural dentition, adjunctive cleaning aids such as flossing are still valuable. As with dentated patients, an implant patient's home care requirements should be individually tailored according to each patient's needs. Individual needs are based on the location and angula-

tion of the dental implants, the position and length of transmucosal abutments, the type of prosthesis, and the dexterity of each patient.

The other popularized type of cleansing device is the use of oral irrigators with or without the addition of antimicrobial solutions. Also, oral rinses with antimicrobial properties such as Listerine or chlorhexidine have been widely advocated throughout the literature<sup>31–35</sup>.

**Summary**

During the infancy years of dental implantology, the emphasis for long-term success of osseointegrated implants was the surgical phase of dental implantology. In the years that followed, the emphasis for success had switched from a purely surgical influence to focusing more on the proper fixture placement which would be dictated by the prosthetic and aesthetic needs of each particular case.

In more recent years, the dental professional has recognized professional implant maintenance and diligent patient home care as two critical factors for the long-term success of dental implants. The microbiota and clinical presentation of peri-implantitis is the same as periodontitis around a natural tooth. ■

*A complete list of references is available from the publisher.*

**About the authors**

Dr. Gregori Kurtzman, DDS, is in private general practice in Silver Spring, Maryland, USA. He can be reached at [dr\\_kurtzman@maryland-implants.com](mailto:dr_kurtzman@maryland-implants.com).

Dr. Lee Silverstein, DDS, MS, is in private periodontal practice in Marietta, Georgia, USA. He can be reached at [kenperio@bellsouth.net](mailto:kenperio@bellsouth.net)



*Catering for all your dental equipment needs*












Dental Dynamix has the in-house experience and expertise to find you the best equipment solution to fit the individual needs of your practice. We can offer you a complete “turn-key” service specialising in surgery design, installation, staff training, after sales service and support.

**Agencies include**

Cabinetry	-	A-dec & Modwood
Compressors	-	Bambi, Cattani & Dürr
Equipment	-	A-dec
Handpieces	-	NSK & W&H
Suction systems	-	Cattani & Dürr
Stools	-	A-dec, Murray
X-ray units	-	Gendex & Satelec

Full range of digital imaging equipment also available

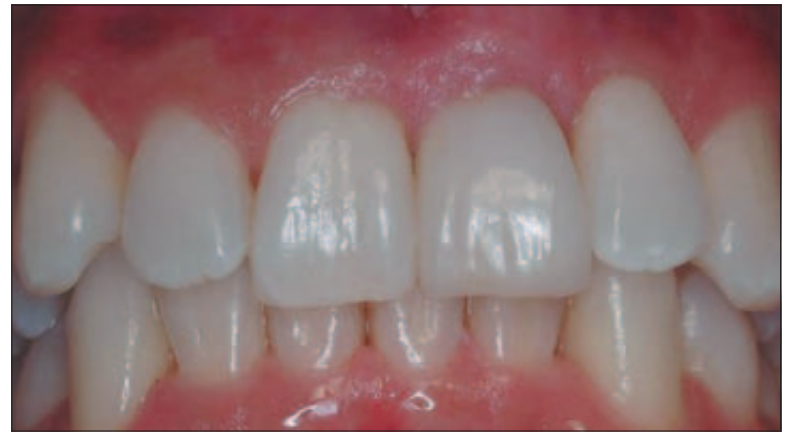**Contact Details**  
 Dental Dynamix Equipment  
 Office: 0844 800 8870  
 Bradley Marz: 07875 309 682  
 Email: [brad@dentaldynamix.co.uk](mailto:brad@dentaldynamix.co.uk)

**Servicing South East England**



# Peri-implant soft tissue recessions

By Dr. André P. Saadoun, D.D.S., M.S.



Smile aspect 6 months later

## Introduction

A beautiful aesthetic result is difficult to obtain with implants in the anterior areas. Both the alignment of the gingival margin and the presence of papillae are essential elements in resolving aesthetic implant problems to achieve a harmonious smile. These two soft tissue entities, however, are closely related to the patient's biotype and to the quality/quantity of underlying structural alveolar bone.

The peri-implant gingiva, particularly if it is narrow, with a thin-scalloped biotype, inevitably retracts six months after the abutment connection and restoration, owing to the reformation of the biologic space (Small and Tarnow, 2000).

The process of soft and hard tissue healing must be understood and incorporated into a carefully coordinated sequence of therapy. It is also important to identify complications and clinical mistakes and their implications on the final aesthetic outcome (Saadoun et al, 1999).

How, then, should soft tissue recession (bone and gingiva) around an implant be prevented or treated?

## Prevention of peri-implant recession

Marginal bone loss of 1 mm in the first year following the

abutment connection, followed by loss of 0.2 mm per year, were among the criteria defined for implant success (Albrektsson et al, 1986). Saving a few tenths of a millimetre of bone around an implant does not increase the longevity of the implant, and should be done only for aesthetic reasons. To prevent or to decrease peri-implant bone resorption and consequent gingival recession following implant restorations in the anterior zone, several strategies have been suggested, which are explained in detail in the following points.

### 1) Implant design and diameter

The design of the collar of the implant should stabilize the crestal bone by bringing the roughened surface right up to the platform, and the threads/microgrooves as close as possible to the platform, with no divergence of the collar walls.

The thread position of the implant determines the effective level of remodelling after loading, and this is perhaps even more important than the position of the implant abutment microgap. (Rompen et al., 2003).

Placement of the implant platform 1.5 mm above the bone, helps to minimize bone loss as the biological space around the implants is estab-

lished on the collar (Lezly Miller, 2005).

### 2) Implant placement and extraction timing

To make the best choice between different alternatives of implant placement, a precise pre-surgical diagnosis is necessary in order to evaluate the gingivo-osseous parameters, to determine the optimal moment to extract the tooth and place the implant, and to decide whether implant placement and loading should be immediate, early or delayed (Saadoun and Landsberg, 1997).

Orthodontic treatment is the best solution for patients who wish to limit the surgery required for the placement of implants to a single session, and to enhance the hard and soft tissue profile prior to extraction and implant placement (Salama et al, 1993).

### 3) Flap design

On healed site the limited flap design minimizes interproximal bone and papillae loss. Many flap design have been described for healed sites, some raising the total interproximal papillae with sulcular incision around adjacent teeth, others using mid-crest/palatal crest incision with sulcular envelope flap and, finally, tissue punch flap recommended in large amount of keratinized gingiva.

Flapless approach using tissue punch procedure has many advantages: less trauma to the bone and disturbances to the soft tissue stability, reduction of pain and oedema, and less post surgical information.

Immediate implant placement after extraction is usually a flapless surgical procedure, the extraction being done using a periosteal elevator to minimize traumatic damage to the hard and soft tissues.

### 4) Tridimensional implant placement

Satisfactory morphology of the papilla and of the gingival margin after anterior implant restoration depends ultimately on two factors: implant placement (Esposito et al, 1993, (Saadoun et al, 1998, Jovanovic, 1999, Grunder et al, 2005) and implant restoration.

The tridimensional criteria for implant placement in the aesthetic zone are:

- **Mesio-Distal:** 1.5-2mm between implant and adjacent tooth 3.5-4mm between implant and adjacent implant
- **Bucco-Lingual:** 2.5-3mm from the cervical height of contour of the adjacent teeth to the buccal surface of the implant platform.
- **Corono-Apical:** 2.5-3mm apical to the bucco gingival margin depending on the biotype

Therefore, if immediately post extraction implant placement is indicated, the osteotomy must be performed against the palatal wall to prevent any damage to the remaining (and usually thin) buccal cortical bone (Testori, 2003).

### 5) Connective osseous grafts

An autogenous bone and xenograft with a membrane is used to gain buccal thickness knowing that bone resorption/gingival recession always occurs after extraction/implant placement.

Gingival biotype plays an important role in determining tissue levels achieved around implants. A thin biotype is generally more susceptible to peri-implant recession, induced by the resorption of a thin labial cortical plate. The use of osseous and connective grafts converts a thin gingival biotype into a thick gingiva (Matheus, 2000), which can enhance gingival marginal stability and simplify tissue management during the restorative treatment phase.

### 6) Abutment and restoration

Optimal aesthetics will be promoted if the final abutment is installed at the time of implant placement, and left in place undisturbed, throughout the final restoration phase, avoiding disturbance of bone and soft tissue architecture.

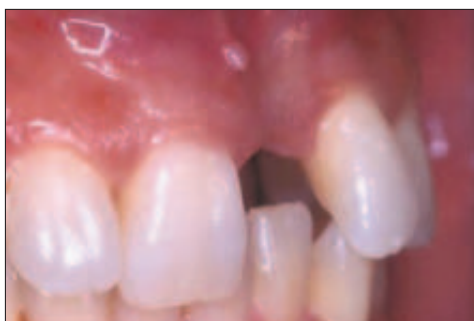

Fig. 1: Deformed ridge following traumatic extraction (right view)

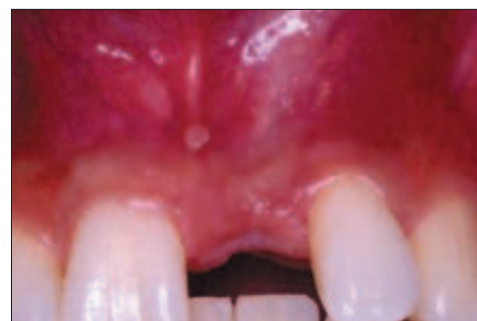

Fig. 2: Deformed ridge following traumatic extraction (central view)

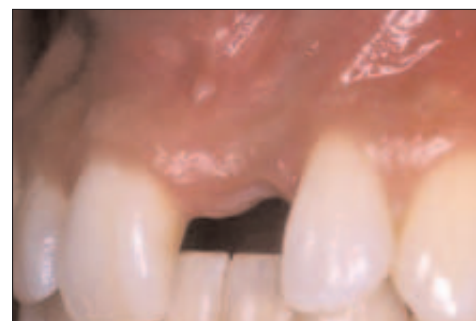

Fig. 3: Deformed ridge following traumatic extraction (left view)

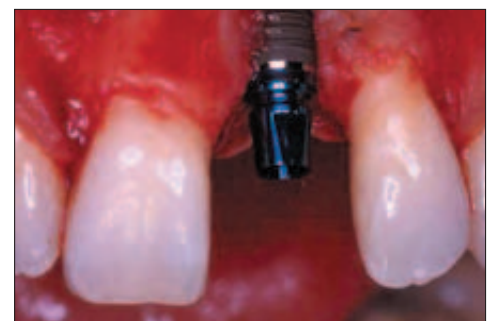

Fig. 4: Implant insertion after flap elevation

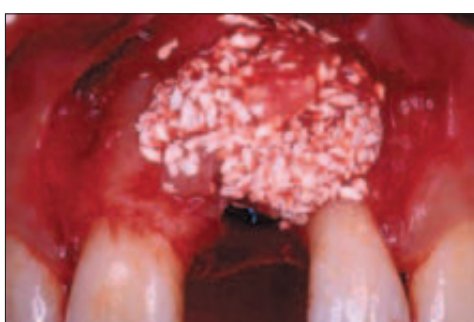

Fig. 5: Bio-Oss graft combined with PRF particulates

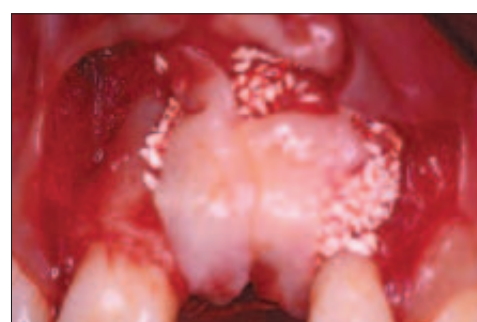

Fig. 6: Implant and graft covered with PRF membrane

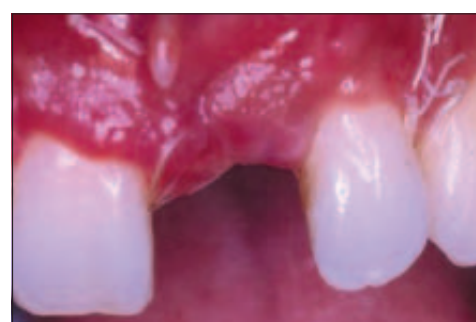

Fig. 7: Coronally advanced flap (frontal view)

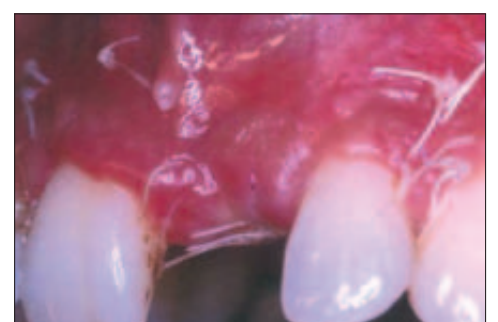


Fig. 8: Coronally advanced flap (left view)