

DENTAL TRIBUNE

The World's Dental Newspaper • Pakistan Edition



PUBLISHED IN PAKISTAN

www.dental-tribune.com.pk

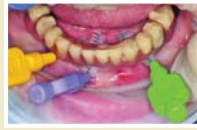JULY, 2019 - Issue No. 04 Vol.6



Brunch with the President: Reunion of ...

NEWS

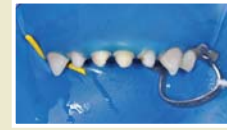▶ Page 4



Prevention 0: The best way to prevent ...

CLINICAL IMPLANTOLOGY

▶ Page 8



Edelweiss PEDIATRIC CROWNS: A new and innovative ...

PEDIATRIC DENTISTRY

▶ Page 9

Medical & dental colleges to be annually categorized on quality by PMDC

DT Pakistan Report

ISLAMABAD - Pakistan Medical and Dental Council (PMDC) has decided to initiate annual categorization of all public and private medical and dental colleges of Pakistan, based on quality. According to an official of PMDC, all medical and dental colleges will be ranked into five categories from A+ to D on the basis of their performance indicators, facilities and faculty, to help students in making the right choice along with improving the quality of the colleges. The ranking will clearly speak of the college's functionality and performance, along with pinpointing the flaws in the overall system.

To kick off the first phase, the council has decided to scrutinise all

the existing public and private medical and dental colleges; this would be the largest inspection that has ever taken place in the country. All 167 colleges will be examined and new frameworks will be decided for the coming year.

The PMDC official said that the inspection system was developed to facilitate a transparent and open merit-based system, adding that these will be carried out on a periodical basis- an annual or three-year basis. He added that a new organogram of the organization was also developed, which had setup the needed departments, with each department being headed by a Head of Department. This head will be supervising different sections of the department and will ensure the best possible implementation of industry-




related governance practices. The official said that the council had also developed a policy to impose a revalidation requirement upon doctors in line with the international practises instead of renewing their licences after a specific period of time. This step will help doctors to keep themselves updated on the

Continued on Page 14

Rs 600m allocated for FJID completion

KARACHI - The current government has allocated Rs 600 million in recent budget

for the long ignored project of Fatima Jinnah Institute of Dentistry (FJID) despite the economic



emergency in the country.

The long struggle of dental community, associations and media must be appreciated, as well as the efforts of Dr Arif Alvi, President of Pakistan, who finally made it possible to allocate necessary funds for the completion of FJID.

He paid a special visit to his alma mater, and assured that he would fulfil the commitment made by him at the special briefings in President House where he met with a delegation comprising Principal Prof Waheed Ul Hamid, Project Director Prof Usman Akhtar, and Dr Wasif Ali Khan. -PR

PDA honours Dr Inayatullah Padhiar S.I.

By Dr Hira Mustafa Khan

KARACHI - Pakistan Dental Association (PDA) hosted an iftar dinner to honour the esteemed Dr Inayatullah Padhiar (SI) the recipient of Sitara-e-Imtiaz by the President of Pakistan Dr Arif Alvi.

PDA President Dr Mahmood Shah presented a shield and an ajrak veil to Dr Inayat (S.I), on behalf of PDA, as a gesture of appreciation and recognition of his dental community work and selfless contribution to academic writing and organized dentistry in Pakistan. Dr Mahmood Shah said that Dr Inayat had been a source of learning and guidance for so many dentists including him.

Former PDA presidents, Dr Saqib Rashid, Dr Kamran Vasfy and Dr Mumtaz Khan, also came forward to pay tribute to Dr Inayat (SI). Dr Baqar



PDA President Dr Mahmood Shah presenting shield to Dr Inayatullah Padhiar S.I. (Photograph: DT Pakistan)

Askary, Dr Asif Niaz Arain and Dr Anwar Saeed lauded Dr Inayat (SI) for his work and effort toward bettering dentistry in the country. CEO Dental Tribune Syed Hashim Hasan acknowledged the outstanding human being and a mentor for so many not only in the dental profession but also for supporting the establishment of Dental News. It was his words of encouragement and constant guidance that made Dental Tribune what it is today.

A segment based on discussion on PDA affairs also took place, wherein the current and former PDA presidents along with others including Dr Asif Niaz Arain, Dr Anwar Saeed, Dr Ghulam Ali Sayyal and Dr Nasir Khan participated and discussed the various barriers and solutions, and ways to improvement.

Continued on Page 14

Brunch with the President: Reunion of de'Montmorency graduates, class 1966

DT Pakistan Report

ISLAMABAD - March 10th, 2019, was a day of excitement, significance, and immense pride for the dental graduates of class 1966 of de'Montmorency College of Dentistry, Lahore. This day, the President of Islamic Republic of Pakistan Dr Arif-r-Reham Alvi, who also belongs to the same batch of the dental college, invited all his former

classmates over brunch at the President House in Islamabad.

The meeting was scheduled from 11am to 1pm. President Arif Alvi and his wife, Samina Alvi welcomed all the arriving guests with an open and warm heart. It was an

afternoon full of reminiscence, nostalgia and celebration of the prized memories of these graduates from their time in dental college.

Dr Munir Ahmed who flew all the way from Canada for the reunion, played a primary role in arranging it. He created a WhatsApp group and put in relentless effort to reach out to all his UG batch-mates, 48 years after graduation, and invited them to the reunion.

Attendees of the reunion brunch included Dr Abid Bhaijan and Dr Tahira Abid (USA); Dr Munir Ahmad

and Mrs. Zohra Munir (Canada); Dr Javaid Ashraf and Mrs. Shezana Javaid; Capt Dr Abdul Rasheed Chaudhry; Brig (R) Dr Raza Ahmed Khan; Dr Asif Ali and Mrs Musarrat Ara; Dr Farrukh Mumtaz Rana; Col Dr M. Alamgir Dar (TIM) and Mrs. Asmat Yasmeen; Dr Zahoor Ahmad and Mrs Azra Yasmin; Dr Muhammad Umar Hayat and Mrs. Farzana Khanam; Col. Dr Naseer Ahmad; Col Dr Abdus Sattar

52 years, there was also conversation on the current status of Dentistry in Pakistan.

Dr Munir Ahmed said, "It is my wish that Pakistan has a separate Dental Council similar to the regulatory bodies in Canada, UK and USA; an adequate dental health policy must also be implemented. I have researched on it and I offer my services to Pakistan in this regard, and my services are dedicated to Dr Arif Alvi



who may be able to bring these changes."

The guests also discussed the potential for enhancing and improving the dental education and practice in Pakistan.

Dr Munir said, "Since dentists like me, Dr Abid and Dr Tahira

have spent years practicing in countries like Canada and USA, we have offered the president the amalgamation of our specialties, experiences and skills in redesigning the current dental curriculum of Pakistan."

Dr Arif Alvi welcomed all suggestions, and offered his own insight as well.

After an afternoon of exchanging professional ideas, and narrating stories from the time in de'Montmorency, the hosts led the guests toward brunch arrangement.

Lecture and workshop on endodontics and periodontology

KARACHI - A comprehensive and didactic lecture on endodontics and periodontology, featuring Fanta Dental Rotary system (AF F one), was arranged by Dentsco International at Fatima Jinnah Dental College (FJDC). The lecture had a grand attendance of renowned consultants and clinicians. Professor Saqib Rashid was the guest of honour; Prof. Yawar Ali Abidi, Prof Zahid Iqbal, Prof Henna Ahmed, Dr Yasir Raza, Dr Azmat Khan, Dr Sameer Qureshi, Prof Shoaib Khan, Dr Asjad Shoukat and Dr Ali Asghar were also present.

Those attending the workshop included dental students, postgraduates, and general practitioners. There was a remarkable response from sixty five keen participants.

Prof Abu Bakr shared insight of his vast knowledge in his intriguing lecture and workshop. The next lecture was by Dr Ashar Jamelle; he outlined his surgical cases and the new classification, which had the participants captivated. This was followed by the workshop on diagnosis and problem solving which was very well received and appreciated. - PR



DENTAL TRIBUNE

The World's Dental Newspaper - Pakistan Edition

Publisher/CEO

Syed Hashim A. Hasan
hashim@dental-tribune.com.pk

Editor Clinical Research

Dr. Inayatullah Padhiar

Editors Research & Public Health

Prof. Dr. Ayyaz Ali Khan

Editor - Online

Haseeb Uddin

Designing & Layout

Sh. M. Sadiq Ali

Dental Tribune Pakistan

3rd floor, Mahmood Centre, BC-11, Block-9
Clifton, Karachi, Pakistan.
Tel.: +92 21 35378440-2 | Fax: +92 21 35836940
www.dental-tribune.com.pk
info@dental-tribune.com.pk

Dental Tribune Pakistan cannot assume responsibility for the validity of product claims or for typographical errors. The publisher also does not assume responsibility for product names or statements made by advertisers. Opinions expressed by authors are their own and may not reflect of Dental Tribune Pakistan.

International Imprint

Publisher/Chief Executive Officer **Torsten R. Oemus**

Chief Financial Officer **Dan Wunderlich**

Director of Content **Claudia Duschek**

Senior Editors **Jeremy Booth
Michelle Hodas**

Clinical Editors **Nathalie Schüller
Magda Wojtkiewicz**

Editors **Franziska Beier
Brendan Day
Monique Mehler
Kasper Mutsche**

Assistant Editors **Luke Gribble
Iveta Ramonaite**

Copy Editors **Ann-Katrin Paulick
Sabrina Raaff**

Business Development & Marketing Manager **Alyson Buchenau**

Digital Production Managers **Tom Carvalho
Andreas Horsky
Hannes Kuschick**

Website Development **Serban Veres**

Project Manager Online **Chao Tong**

Database Management & CRM **Annachiara Sorbo**

Sales & Production Support **Puja Daya
Hajir Shubbar
Madleen Zoch**

Executive Assistant **Doreen Haferkorn**

Accounting **Karen Hamatschek
Anita Majtenyi
Manuela Wachtel**

E-Learning Manager **Lars Hoffmann**

Education & Event Manager **Sarah Schubert**

Media Sales Managers

Melissa Brown (International)
Hélène Carpentier (Western Europe)
Matthias Diessner (Key Accounts)
Maria Kaiser (North America)
Weridiana Mageswki (Latin America)
Barbora Solarova (Eastern Europe)
Peter Witteczek (Asia Pacific)

Executive Producer **Gernot Meyer**

Advertising Disposition **Marius Mezger**

Dental Tribune International GmbH

Holbeinstr. 29, 04229 Leipzig, Germany
Tel.: +49 341 48 474 302 | Fax: +49 341 48 474 173
info@dental-tribune.com | www.dental-tribune.com

©2019, Dental Tribune International GmbH. All rights reserved. Dental Tribune International makes every effort to report clinical information and manufacturer's product news accurately, but cannot assume responsibility for the validity of product claims, or for typographical errors. The publishers also do not assume responsibility for product names, claims, or statements made by advertisers. Opinions expressed by authors are their own and may not reflect those of Dental Tribune International.

How can you provide **more comfort** to your sensitivity patients?

Apply the superior science of **Colgate® Sensitive Pro-Relief™**  Toothpaste for **superior** sensitivity relief*



Instant[†] relief in office
48.9%[†] reduction in sensitivity after prophylaxis[†]

"Is it supposed to be sensitive?"
—Real Patient[¶]



Lasting[§] relief at home
90.1%[†] reduction in sensitivity after 2 weeks[†]

"Even when I drink cold water, it is much better."—Real Patient[¶]



Their satisfaction will speak for itself.^{¶1}

*Vs conventional sensitive toothpastes containing 5% potassium nitrate (equivalent to 2% potassium ion).

[†]For instant relief, apply directly to the sensitive tooth with fingertip and gently massage for 1 minute.

[†]Air blast hypersensitivity test in a clinical study after 1 application and after 2 weeks.

[§]Lasting relief with continued 2x daily brushing.

[¶]In the same study, testimonials were recorded from real patients after treatment with Colgate® Sensitive Pro-Relief™.

References: 1. Ayad F, Ayad N, Vazquez J, et al. *Am J Dent* 2018.

Colgate®

Periodontal disease management workshop by IADSR

KARACHI - Institute of Advanced Dental Sciences and Research (IADSR) recently held a two-day workshop on 'Comprehensive Management of Periodontal disease'. The workshop was a part of IADSR 8th Professional Diploma in Advanced General Dentistry (PDAGD). The participants were facilitated by Dr Muhammad Haseeb, Head of the Department of Periodontology at University of Lahore. He explained how to recognize periodontal disease, its signs and symptoms and emphasized on the surgical and non-surgical management in dental practice. Dr Muhammad Haseeb demonstrated the use of periodontal surgical instruments accurately and effectively. The following topics were taught: surgical and non-surgical management of periodontal disease including regenerative therapy, guided tissue regeneration, bone grafting procedures, gingivectomy, crown lengthening, splinting, and periodontal flap therapies. He emphasized a lot on patient's education related to the disease, and designing of a comprehensive treatment plan after diagnosing the disease. The attendees were given two different case studies to solve with an aim to disseminate new knowledge regarding problems which are commonly identified during clinical practice. Participants diagnosed and designed comprehensive treatment plans for different cases and performed surgical procedures on goat heads and phantom heads.

It was an interactive session and any queries raised while solving case studies were elaborately answered by Dr M. Haseeb. An in-depth discussion cleared doubts and misconceptions of the participating practitioners. **-PR**

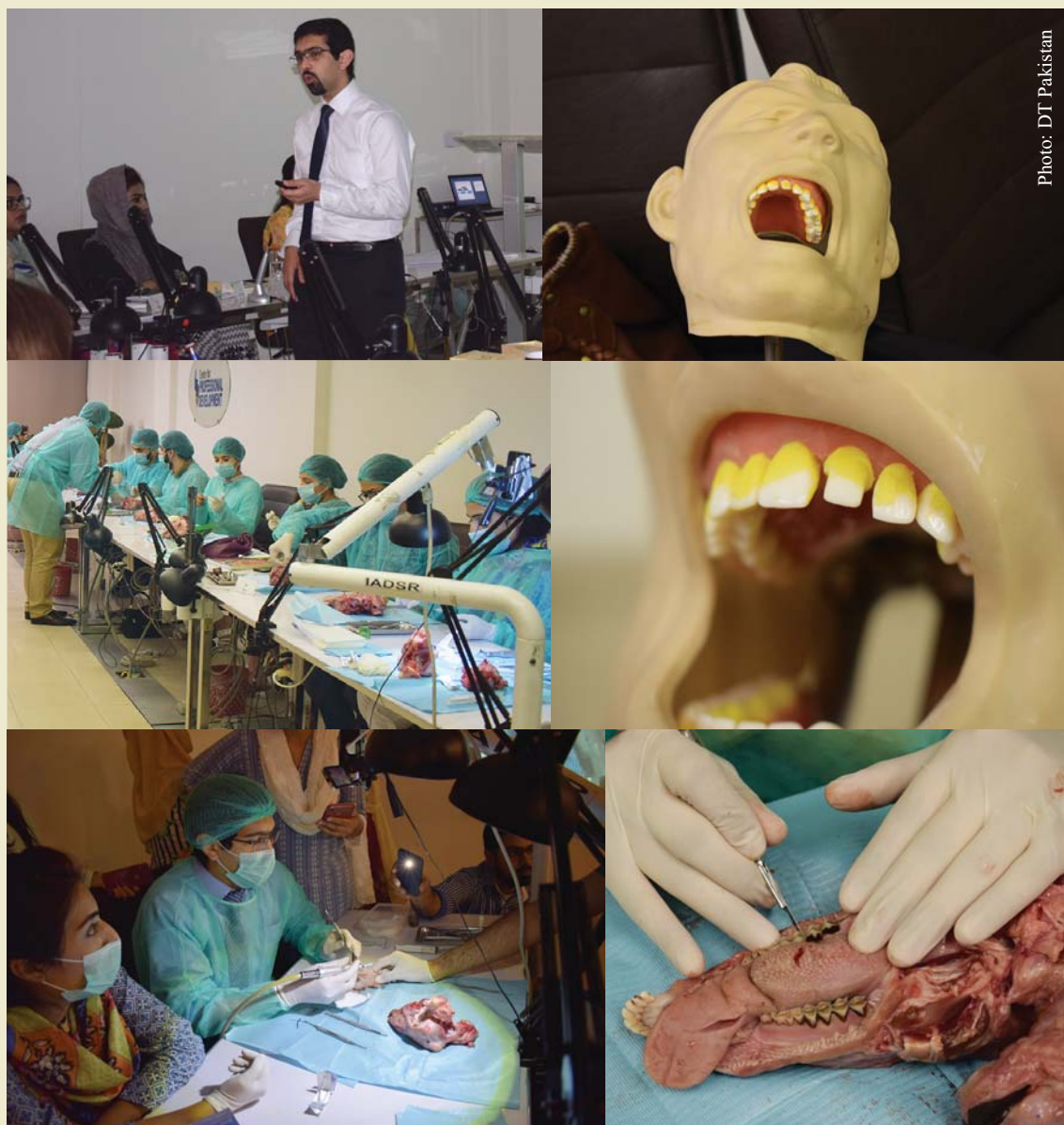

Photo: DT Pakistan

Dentists in Multan pull out 252 teeth from 14yr old's mouth

MULTAN - A team of oral and maxillofacial surgeons of Nishtar Institute of Dentistry, in Multan, pulled out 252 teeth from the maxilla of a 14 year old boy. The team was headed by Dr Saima Munir, Dr Sohail Fareed, Dr Khalil Ahmed, Dr Faizan Virk,

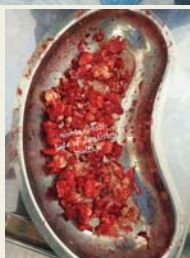

Photo: DT Pakistan

Dr Ayesha Gull, Dr Fishan Ali, and Dr Muzammil who performed stepwise surgery at Nishtar Hospital, Multan.

The boy was suffering from Complex Odontoma and had hundreds of teeth in his maxilla and mandible. In the first step, surgery was performed on the maxilla alone, from where 252 teeth were extracted; mandibular surgery will be done in the next step after healing of maxilla.

In previous literature, there is record of 232 teeth being extracted from a 17yr old boy's mouth, in India. **-PR**



Training workshop on modern dental implants at JSMU concludes

KARACHI - "Our mission is to produce a reliable, high quality dental implant system, based on scientific evidence and proven concepts, with the goal of making implant treatment affordable for all patients," said a Turkish dental implant expert at a training workshop in Jinnah Sindh Medical University (JSMU).

Institute of Oral Health Sciences (SIOHS) is providing this service to people at an economical cost on a no profit basis."

Pro Vice Chancellor Prof Lubna Ansari Baig told the visitors that it was encouraging to learn that they shared the university's goal of making high quality dental care affordable for people.

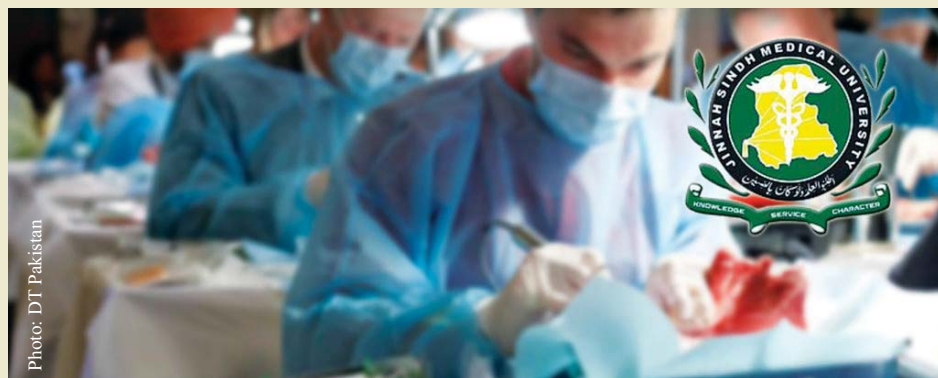

Photo: DT Pakistan

Vice Chancellor JSMU Prof SM Tariq Rafi welcomed the guests and described the vision of the university under which high quality dental care is being provided to the masses at nominal cost. "Dental implants are a very expensive option in the market. The Out Patients Department at our Sindh

Experts trained 80 participants in using the dental implant system in the workshop that lasted two days.

Registrar Prof Saadia Akram, Principal SIOHS Prof Zubair Abbasi, and organizer Dr Erum Behroz were also part of the programme. **-PR**

new

SENSODYNE

gsk

REPAIR & PROTECT

**ACTUALLY
HELPS REPAIR
SENSITIVE TEETH***

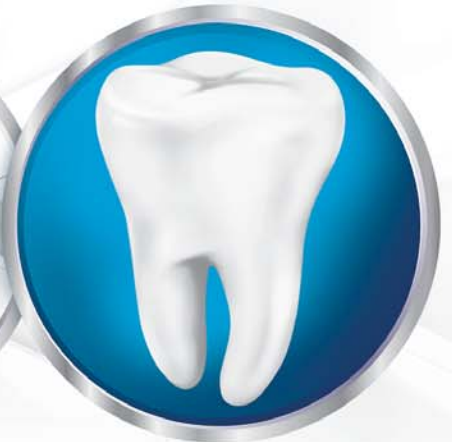Cause of
sensitivity pain

Tiny holes
in dentine

A hard
layer

Repairs
these holes

Helps protect
from pain



No.1 DENTIST RECOMMENDED BRAND FOR SENSITIVE TEETH

*Forms a protective layer over the sensitive areas of the teeth. Brush twice a day for lasting sensitivity protection.

CHPAKCHSENO001917

Sugar industry exploited dietitians to influence dentists, study shows

SAN FRANCISCO, U.S./VANCOUVER, BRITISH COLUMBIA, CANADA - In 1975, the U.S. Sugar Association (SA) created the Regional Nutritional Information Program (RNIP) in an effort to enlist dietitians to spread positive messages about sugar and health. A recent study has inquired into the RNIP and evaluated its impact on dental professionals. The findings suggest that the sugar industry used dietitians strategically in order to influence the dental community's views on sugar.


Researchers from the University of California, San Francisco School of Dentistry reviewed 304 internal SA documents dating from 1974 to 1978 related to the RNIP's operations, regulatory

activities and scientific research. To further explore the SA's influence on the dental community, they selected 59 documents for an in-depth analysis and identified the emerging themes. They used secondary sources to contextualize their findings.

The data revealed that the RNIP was an integral part of the SA's public relations campaign and was designed to portray the safety and benefits of sugar in a balanced diet. The target audiences included universities, public schools, professional associations and the media. According to the study, dietitians working for the SA hosted educational workshops, incorporated the association's literature into libraries and curricula,

monitored professional and consumer attitudes toward sugar and made media appearances. They also interacted with dental professionals by documenting their attitudes toward sugar, influencing a professional conference to include pro-sugar speakers, developing a media program that minimized sugar's role in causing dental caries, and by monitoring and criticizing dental researchers who sought to examine the high-sugar content of breakfast cereals.

According to the World Health Organization (WHO), dental caries is a major public health problem and is the most widespread noncommunicable disease. WHO states that it can be prevented by avoiding dietary free sugars.



The findings of a recent study have suggested that the U.S. Sugar Association used dietitians to refute dentists' anti-sugar messages at professional meetings and in the media. (Photograph: Kagai19927/Shutterstock)

The researchers caution the public health community to consider corporate relationships in the dietetic profession as potentially detrimental to oral health.

The findings were presented at the 97th General Session and Exhibition of the International Association for Dental Research, held in conjunction with the 48th Annual Meeting of the American Association for Dental Research and the 43rd

Annual Meeting of the Canadian Association for Dental Research. The event took place on June 19-22 in the West Building of the Vancouver Convention Centre.

An oral presentation of the findings of the study, titled "Sugar industry's use of dietitians to influence dental professionals, 1974-1978," was held on June 19, 2019. - **Dental Tribune International**

Family characteristics influence periodontal diseases in children

BRISSBANE, AUSTRALIA - Numerous studies have been published on the association between dental caries and various family contextual factors. However, similar research with regard to periodontal disease is limited. Thus, the aim of a recent systematic review was to assess the influence of family characteristics on periodontal diseases in children.

For the review of the relevant literature, 32 studies from a number of countries were included. Factors considered varied in the different studies but included family income, parents' socio-economic status, educational status and occupation, and parental knowledge, practices and clinical status.

The review found that parents' socio-economic status is significantly associated with periodontal diseases in children. Furthermore, children who are exposed to passive smoking and have parents with periodontal diseases are more likely to have periodontal diseases as well.



According to a recent systematic review, the socio-economic status of parents influences the prevalence of periodontal diseases in their children. (Photograph: MilanMarkovic78/Shutterstock)

"Similar to dental caries, three commonly used indicators of parent's socio-economic status namely income, education and occupation are significantly associated with periodontal diseases in children with better periodontal status being observed in children of parents with higher socio-economic status than those children whose parents are of lower socio-economic status," said lead author Dr Santosh Kumar Tadakamadla, Senior Research Fellow at the School of Dentistry and Oral Health at Griffith University in Brisbane. "However, there was not much research done to explore the effect of parental

psychosocial variables on periodontal diseases in children," he continued.

"It is important to understand which parental characteristics influence periodontal disease in children to plan health promotion or prevention programmes for preventing periodontal diseases in children," concluded Tadakamadla.

The study, titled "Effect of family characteristics on periodontal diseases in children and adolescents-A systematic review", was published online in the International Journal of Dental Hygiene on 2 April 2019, ahead of inclusion in an issue.

- **Dental Tribune International**

Scottish professor wins international dental research award

DUNDEE, UK/VANCOUVER, British Columbia, Canada: In recognition of his prominence in the world of dental academia, Prof. Graham Ogden of the University of Dundee has been awarded the 2019 International Association for Dental Research (IADR) Distinguished Scientist Award in Oral Medicine and Pathology Research. Ogden was presented with this accolade at the recent 97th General Session and Exhibition of the IADR held in Vancouver in Canada.



Prof. Graham Ogden is currently Professor of Oral Surgery at the University of Dundee, as well as Vice President of the Dental Faculty of the Royal College of Physicians and Surgeons in Glasgow. (Photograph: The University of Dundee)

The award is one of the highest honours bestowed by the IADR and recognises Ogden's outstanding and sustained body of peer-reviewed research that has contributed to an understanding of the mechanisms governing the health and diseases of the oral cavity and associated structures, which principally encompass skin, bone and the oral soft tissue. The award consists of a monetary prize and a plaque.

Continued on page 15



HELP KEEP YOUR PATIENTS ON A JOURNEY TO HEALTHY GUMS

PARODONTAX® TOOTHPASTE IS CLINICALLY PROVEN TO REDUCE PLAQUE, BLEEDING GUMS AND INFLAMMATION

4X

greater plaque removal*¹

48%

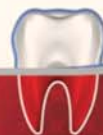greater reduction in bleeding gums*¹

Recommend parodontax® toothpaste to help patients maintain their optimal gum health between dental visits.

DAILY FLUORIDE TOOTHPASTE FOR HEALTHY GUMS & STRONG TEETH

parodontax®

EXTRA FRESH



Helps stop and prevent bleeding gums



GlaxoSmithKline Consumer Healthcare Pakistan Ltd.
35-Dockyard Road, West Wharf, Karachi - 74000

GSK is committed to the effective collection and management of human safety information relating to our products and we encourage healthcare professionals to report adverse events to us on +92 (21) 111-475-725 or pk_pharmasafety@gsk.com

* Compared to a regular toothpaste and professional clean and 24 weeks' twice-daily brushing.

Prevention 0: The best way to prevent peri-implant disease?

By Prof. Magda Mensi, T. Ives & Dr G.Garzetti

The philosophy of prevention in all medical professions is increasing from a global perspective. In fact, prevention of chronic non-communicable diseases, the major burden of illness and disability in almost all countries in the world, has been strengthened in recent years. The motivation is to ensure a better quality of life for people and to reduce public health expenditures. In dentistry, periodontitis is one of the major chronic non-communicable diseases. World experts in periodontics and science have published several principles regarding the prevention of periodontal diseases.

Peri-implantitis is a twenty-first-century version of periodontitis and

to patients if consideration is given from the beginning to the entire situation. Implants may not always be in the best interest of the patient. For these reasons, every clinician, before placing an implant, should consider not only patient- and site-specific aspects, but also surgeon, prosthodontist, dental hygienist and dental technician skills in order to minimise the possibility of peri-implantitis in the future.

The following should be considered before primary and secondary prevention, and it is the proposal of the authors that this approach be called "Prevention 0".

Patient-specific considerations

When deciding to rehabilitate a patient with dental implants, before surgical planning, we have to carefully inform the patient about the

alveolar process, inducing hard- and soft-tissue deficiencies. The clinician must evaluate carefully all sites exposed to the following factors, because they have the potential for major healing deficiencies: loss of periodontal support, endodontic infections, longitudinal root fractures, thin buccal bone plates, buccal/lingual tooth position in relation to the arch, extraction with additional trauma to the tissue, injury, pneumatization of the maxillary sinus, medications and systemic diseases reducing the amount of naturally formed bone, agenesis of teeth and pressure from soft-tissue-supported removable prostheses.

Other site considerations relate to anatomical knowledge and in respect to the suitable anatomical structure of the area (maxillary sinus, inferior alveolar nerve), endodontic and

dental coach or personal oral trainer, motivating patients not only in dental habits but also in lifestyle, for example regarding smoking cessation and diet. This is a friendly expert who strengthens patient fidelity to the dental office, even in fearful patients, and maintains restorative work and rehabilitations undertaken by the dentist.

To perform professional care in a minimally invasive way, wearing loupes and using plaque disclosing agents and appropriate devices are mandatory, especially if prosthetic rehabilitation is difficult for the patient to maintain. Correct and periodic biofilm removal should be considered the standard of care for prevention and management of peri-implant disease. For this reason, patients should be motivated and instructed in

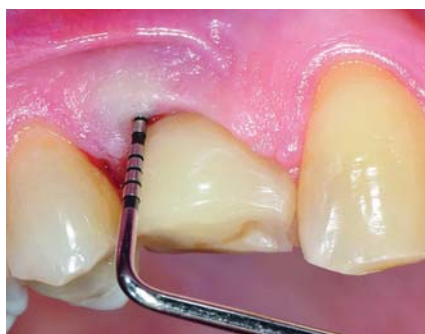

Fig. 1a: Implant in position #14 affected by peri-implantitis: periimplant probing a) with the prosthetic crown in situ and b) after prosthetic crown removal

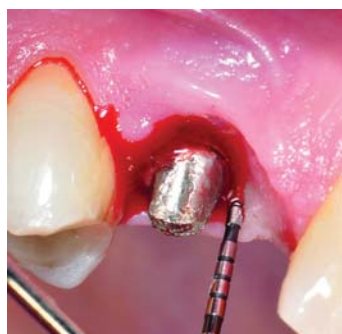


Fig. 1b: Implant in position #14 affected by peri-implantitis: periimplant probing a) with the prosthetic crown in situ and b) after prosthetic crown removal

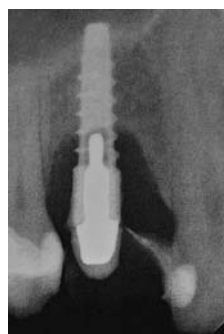

Fig. 2: Radiographic examination of the implant

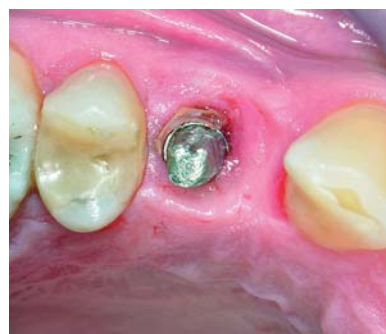

Fig. 3: Excess resin cement around the implant

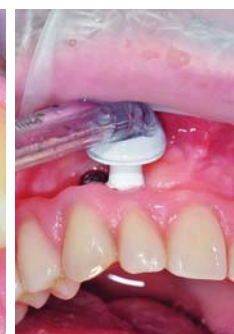

Fig. 4a: Peri-implant home care with a) AirFloss (Philips), b) X-Floss (ROEN) and c) interdental brush (TePe)

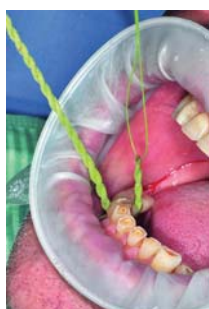

Fig. 4b: Peri-implant home care with a) AirFloss (Philips), b) X-Floss (ROEN) and c) interdental brush (TePe)

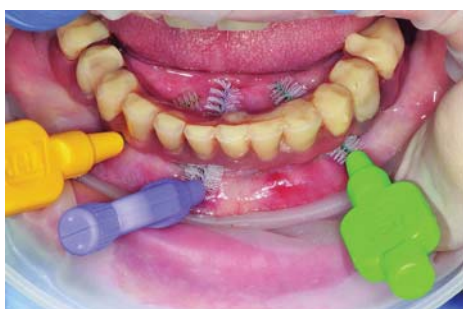

Fig. 4c: Peri-implant home care with a) AirFloss (Philips), b) X-Floss (ROEN) and c) interdental brush (TePe)

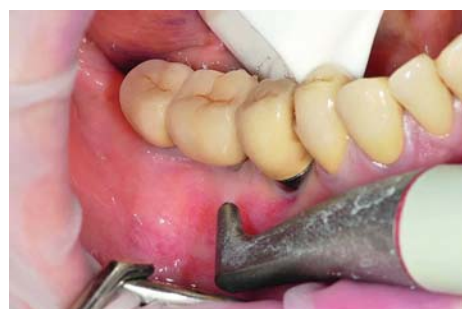

Fig. 5a: Professional peri-implant biofilm removal by a) AIRFLOW with erythritol powder (PLUS powder, EMS), b) PERIOFLOW with PLUS powder and c) with PEEK tip (PI, EMS)

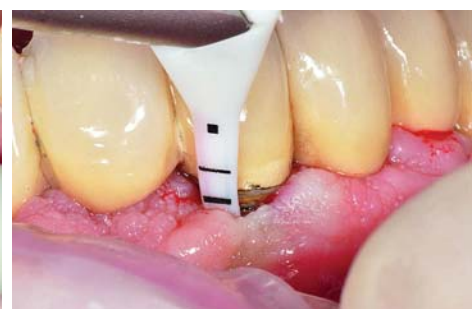

Fig. 5b: Professional peri-implant biofilm removal by a) AIRFLOW with erythritol powder (PLUS powder, EMS), b) PERIOFLOW with PLUS powder and c) with PEEK tip (PI, EMS)

increasing in occurrence as implant placement is increasing (Figs. 1-3). Like periodontitis, it is a biofilm-associated pathological condition, but instead of affecting periodontal ligaments and bone, it is characterised by inflammation in the peri-implant mucosa and subsequent progressive loss of supporting bone. The main reasons for concerns in this area are an aetiology in which several risk factors can play a determining role and a lack of a gold standard therapy. Primary and secondary preventative measures are really important to prevent mucositis and peri-implantitis and to avoid recurrences, but there are many details to consider before placing implants to mitigate iatrogenic problems. There are many different prosthetic solutions besides implants that dental professionals could propose

characteristics of this procedure. It is important to underline that personal daily maintenance at home and appropriate compliance regarding follow-up controls and dental hygiene therapies are effective preventative measures. Procedure awareness and compliance are the foundation for success, but the clinician must also inform the patient about the impact of systemic disorders (osteogenesis imperfecta, ectodermal dysplasia, diabetes), medications (bisphosphonates), therapies (radiotherapy in the jawbone), habits (smoking, poor biofilm control) and a history of aggressive periodontitis as being relevant risk factors for peri-implant disease.

Site-specific considerations

The healing process after tooth loss leads to a variable reduction of the

periodontal health of adjacent teeth, and patient phenotype. According to Linkevicius et al. there is significant evidence that thin soft tissue leads to increased marginal bone loss compared with thick soft tissue around implants.[3, 8] Lack of bone has led to the development of various alternative surgical techniques to avoid large bone regenerations or grafts, such as short implants, tilted implants, pterygoid implants and palatal implant mesh, with questionable results, but definitely decreasing the cleanability and maintainability of implants and prostheses.

Dental hygienist skills and devices

This professional figure plays a key role in disease prevention and oral health promotion.[9] Dental hygienists should not limit their activities to being an oral cleaner, but act as the patient's

daily implant maintenance, which should begin before implant placement and be continued after treatment within a regular, personalised recall regime (Figs. 4 & 5).

Surgeon skills

Nowadays, especially in Italy, a new professional figure has appeared: the implantologist, who is a graduate dentist, generally a co-worker, and goes to different dental offices or clinics and mainly places implants, often without sufficient expertise in periodontal and prosthetic fields. That means, in some cases, implant mispositioning, resulting in reconstructive and maintenance problems. In order to avoid fabrication of specific prosthetic parts, unrestored implants and surgical interventions to remove or reposition them in

Continued on page 15

Edelweiss PEDIATRIC CROWNs: A new and innovative approach to restoring primary teeth

By Dr Desigar Moodley, Dr Kunal Gupta, Dr Stephan Lampl

The management of dental caries in children is necessary because caries is a progressive disease which can eventually damage the tooth and can be detrimental to the permanent teeth and the child's general well-being. As outlined in this clinical case, edelweiss PEDIATRIC CROWNs are a simple solution which is aesthetic but also functional in providing an effective treatment option for the restoration of decayed primary teeth.

Introduction

The main objective of restorative treatment in the paediatric patient is to repair or limit the damage from caries, protect and preserve the tooth structure, and maintain pulp vitality whenever possible. Although stainless-steel crowns have proved to be successful in clinical treatment, the views of dental practitioners on the use of these crowns differ. The majority of general dental practitioners consider these crowns to be an impractical restorative technique for a busy daily practice and unsuitable for most children. Guidelines on the use of stainless-steel crowns as set out by the British Society of Paediatric Dentistry have largely been ignored, as they do not reflect the views of the majority of general dental practitioners. In recent years, because of increased demand for aesthetics, prefabricated zirconia crowns have become increasingly popular. Zirconia paediatric crowns, however, require a more aggressive approach with subgingival preparation margins to restore primary teeth, which can often lead to pulpal exposure because of the large pulpal chambers and high pulpal horns in primary teeth. Because zirconia crowns cannot be crimped, the clinician must prepare the teeth to fit the zirconia crowns. Therefore, an increase in preparation and fitting time is necessary. Furthermore, preparation of subgingival margins can often result in gingival haemorrhage, which can compromise the retention of zirconia crowns.

To overcome the shortcomings of the above-mentioned treatment options, a minimally invasive, highly aesthetic paediatric crown was recently introduced to the market that is produced from a laser-sintered and -vitrified composite. This process improves the flexural strength of the crown to 550 MPa and produces a highly aesthetic glossy surface. Edelweiss PEDIATRIC CROWNs are prefabricated crowns that are contoured to mimic the anatomy of

the primary tooth and are supplied in various sizes for both anterior and posterior teeth for different clinical situations.

Clinical case report

A 4-year-old girl was referred to the Children's Dental Center in Gurgaon in India with the complaint of painful teeth when eating and the presence of unsightly maxillary anterior teeth. Clinical examination showed large carious lesions in the maxillary anterior teeth (Fig. 1). A radiographic examination showed pulpal involvement of caries in teeth #51 and 61 (Fig. 2).

The objectives of the treatment plan were first to alleviate pain and remove any pathology and then restore function and aesthetics. After rubber dam placement, routine endodontic treatment was performed on teeth #51 and 61 and the root canals were filled with Vitapex (Neo Dental), a resorbable calcium hydroxide-based paste with iodoform. Since aesthetics was a priority, edelweiss PEDIATRIC CROWNs were used to restore the four anterior teeth. Using a sizing gauge (supplied by the manufacturer) to determine the size, the appropriately sized crowns were selected (Fig. 3).

All caries was removed using a round diamond bur, and mesial and distal reduction were achieved with a fine tapered diamond bur to open the interproximal contacts and to begin circumferential reduction. Buccal and lingual reduction were achieved with a round-ended straight fissure diamond point. All margins and the extent of reduction were dictated by the caries and kept to a minimum in order to preserve as much tooth structure as possible. The margins were kept supragingival (Fig. 4).

The crowns were then checked for fit and prepared for the bonding procedure. The inside surfaces of the crowns were lightly roughened using a diamond football bur (RA 379), rinsed off and air-dried. Edelweiss VENEER Bond (Fig. 5) was applied to the inside of the crown and light-cured for 20 seconds.

The prepared tooth surface was etched with 37 per cent phosphoric acid for 10 seconds, and bonding agent was applied and light-cured for 20 seconds (Figs. 6 & 7). Edelweiss composite in Shade A0 was added to the inside of the crown and placed over the prepared tooth, the crown was seated firmly and excess composite was removed from the margins (Fig. 8). Incisal edges and labial inclination were then assessed,

Continued on page 15

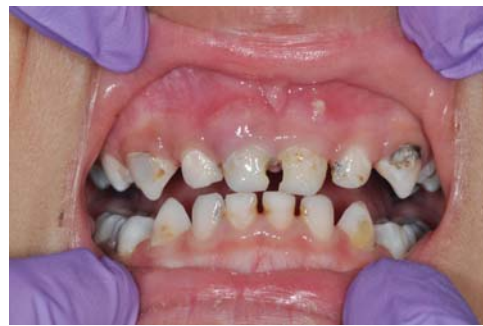

Fig. 1: Caries associated with the four front teeth

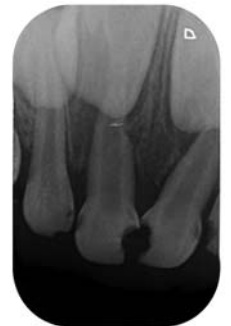

Fig. 2: Radiographic examination revealed pulpal involvement of caries in 51 and 61.

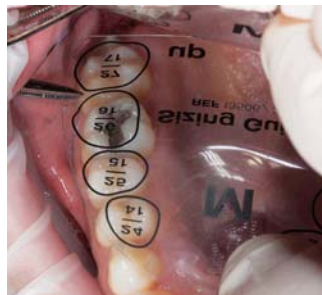

Fig. 3: Edelweiss Sizing Guide in small, medium and large size for crown size selection

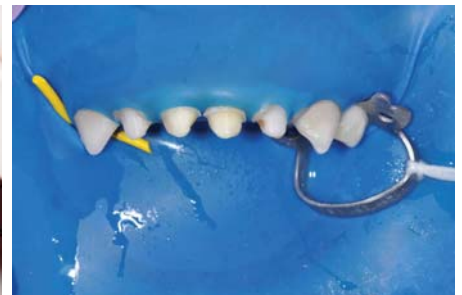

Fig. 4: Crown preparations with margins kept supra-gingival

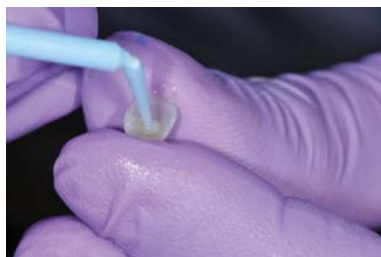

Fig. 5: Edelweiss Veneer Bond applied to inner surface of the pediatric crown, air dried and light cured

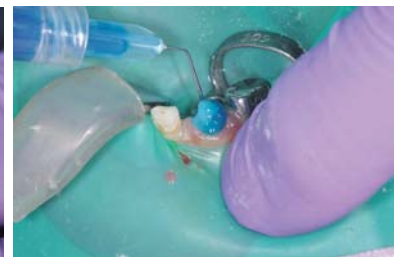

Fig. 6: Tooth surfaces prepared with 37% phosphoric acid for 10 seconds.

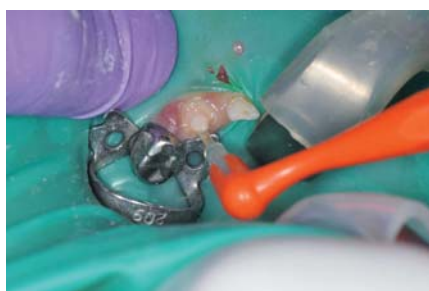

Fig. 7: Bonding agent applied and light cured for 20 seconds

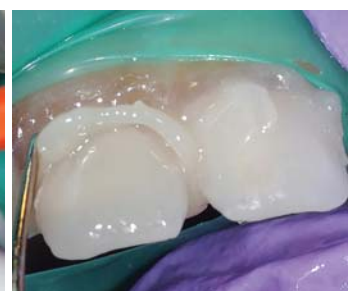

Fig. 8: Excess cement removed from margins prior to final cure.

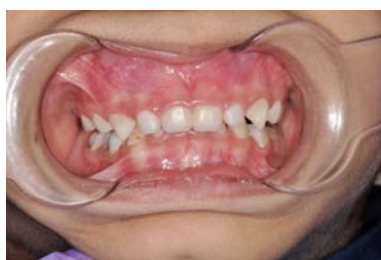

Fig. 9: Front teeth restored with edelweiss pediatric crowns

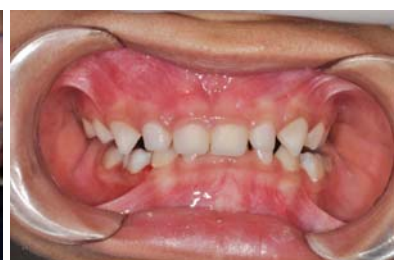

Fig. 10: Four month follow up showed good gingival health and no discoloration of the crowns.

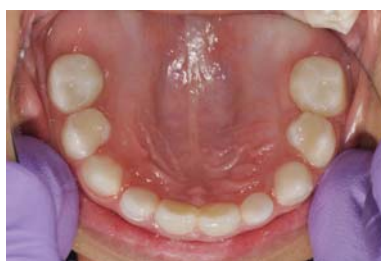

Fig. 11: Preoperative situation

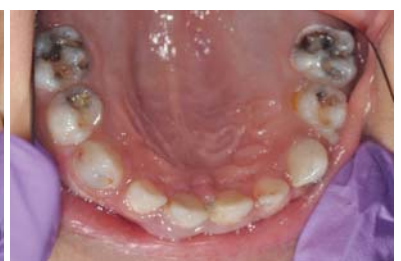

Fig. 12: Postoperative situation