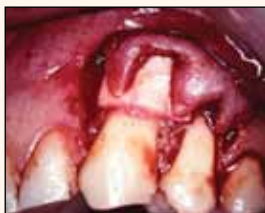

BARRIERS OF SUCCESS

Dr. David L. Hoexter presents latest installment in series of articles on barriers used in cosmetic periodontal surgery.
▶ page A4



HYGIENE TRIBUNE

WIN AN AUDI A3 CABRIOLET

Tickets are on sale for Oral Health America's 'Gala & Benefit,' Feb. 25 in Chicago.
▶ page B1



IMPLANT TRIBUNE

AO PUTS 'FOCUS ON SOUTH KOREA'

Fast-growing market gets attention at Academy of Osseointegration meeting.
▶ page C1



Chicago's 'Midwinter Meeting' promises three days of dental excellence

Lectures, hands-on courses and exhibit hall

The numbers confirm it: The Chicago Dental Society Midwinter Meeting attracts dental professionals from far beyond the borders of Chicagoland. Registrations for the meeting, one of North America's largest, typically surpass 30,000. And this year, the meeting's 150th anniversary, promises to be as big as ever.

The big numbers continue in the exhibit hall, on track to host more than 600 companies in Hall F on level three of the McCormick Place West Building during all three days of the meeting. Exhibit hall hours are from 9 a.m. to 5:30 p.m. on Thursday and Friday, Feb. 26 and 27, and from 9 a.m. to 4 p.m. on Saturday, Feb. 28.

Exhibit-only passes are available to ADA dentists, international dentists and non-ADA dentists who wish to visit only the exhibit hall. The only way to get an exhibit-only pass is to purchase one at McCormick Place during the meeting for the day you want access.

Most of the scientific programming offered at the Midwinter Meeting is included in the registration fee. That fee is waived for all Chicago Dental Society regular and associate members with 2015 memberships. For \$125, you can become an associate member of the society and qualify for the free registration.

Advance registration guarantees you a seat in any paid course. All programs, including the free "F" courses, require a ticket for admission, with the exception of the "Live TV" courses. To attend those "Live TV" courses, you simply need to show your Midwinter Meeting badge.

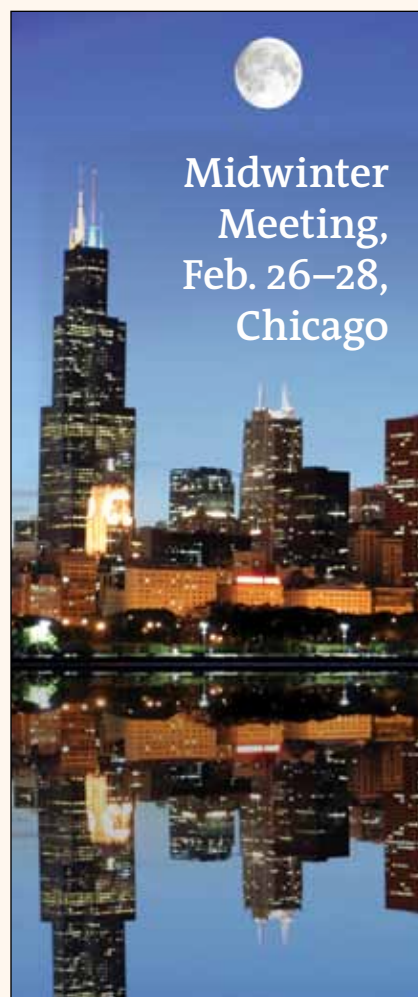Access to the meeting's free courses is on a first-come, first-seated basis. The free courses are all ticketed, so if you want to reserve your seat, you should register for the course in advance and arrive with your ticket prior to the start time. If you don't reserve a ticket in advance through registration, you can ask at the classroom door if any tickets are still available.

Other educational offerings include lectures, which are either full- or half-day sessions, and panels, which are group presentations on a subject or theme of common interest to all panelists. Questions from the audience are encouraged.

Online registration, available through www.cds.org, ends Feb. 20.

Organized in 1864, the Chicago Dental Society represents more than 4,000 dentists in the Chicago area. Its mission is to represent interests of dentists, promote the art and science of dentistry and advocate for improving oral health for all.

(Source: Chicago Dental Society)



Entry to most of the scientific programming offered at the Chicago Midwinter Meeting, at McCormick Place West in downtown Chicago, is included in the registration fee.
Photo/Provided by www.dreamstime.com

NEWS A2

- Chronic periodontitis correlated to heart attack prognosis and severity

CLINICAL A4-A6

- Cosmetic periodontal surgery

MEETINGS A7-A8

- Pacific Dental Conference exhibit hall includes 'Live Dentistry Stage'
- 'Sunsational' education also comes with beachside fun
- Downtown Seattle will host pediatric dentists May 21-24
- JDIQ dates in Montréal, May 22-26

INDUSTRY NEWS A10-A20

- The dentist and the technician: A love story about breaking up with traditional methods
- Intraoral camera boasts HD clarity
- Cefla brands: Cutting-edge products, competitive prices
- Rhein'83 is presenting its latest innovations at Chicago lab meetings
- Dentatus president explains why sales aren't the focus
- At your fingertips: Every detail about owning a dental practice
- Family-owned Flow Dental adds to digital imaging line
- Wykle Research offers Calasept Endo irrigation needles and syringes
- New and improved from EDS: EZ-Fill Xpress and Ti-Core Flow+

AD

PAID
US POSTAGE
PRSR STD

Dental Tribune America
116 West 23rd Street
Suite #500
New York, N.Y. 10011

NO MORE SLUMPING OUT OF CLASS V'S!

[conventional flow]



GrandISO
Heavy Flow



83% filled means up to 50% more fillers than weaker regular flowable composites. The new universal GrandISO Heavy Flow gives you the high wear resistance only achieved by modern universal composites.

Light more and order your **FREE SAMPLE**

at www.vocoamerica.com

Call 1-888-658-2584



GrandISO
Heavy Flow

The first flowable composite that is strong enough for occlusal surfaces of class I and II restorations.

VOCO
THE DENTALISTS

Chronic periodontitis correlated to heart attack prognosis and severity

Researchers have demonstrated for the first time that chronic periodontitis is closely related to the severity of acute myocardial infarction.

In research published in the Journal of Dental Research, titled "Acute myocardial infarct size is related to periodontitis extent and severity," a team from the University of Granada demonstrated that the extent and severity of chronic periodontitis is related to the size of acute myocardial infarction through seric levels of troponin I and myoglobin (biomarkers of myocardial necrosis).

This research results in part from the conclusions of Rafael Martín Marfil Álva-

rez's doctoral dissertation, which was directed by UGR professors Francisco Mesa Aguado (stomatology department), José Antonio Ramírez Hernández (medicine department) and Andrés Catena Martínez (experimental psychology department). The research analyzed 112 patients who had suffered from acute myocardial infarction, at the Virgen de las Nieves University Hospital cardiology unit. Patients all underwent a series of cardiological, biochemical and periodontal health checks and tests.

According to Mesa Aguado, "Chronic periodontitis appears as a death risk factor and plays an important role in the prog-

nosis of acute myocardial infarction."

The researchers said it will be necessary to conduct follow-up checks with periodontal patients who have suffered myocardial infarction to monitor their clinical evolution (new coronary events, cardiac failure or even death).

"If that happens to be the case, chronic periodontitis should be considered as a predictor in the development of myocardial infarction, and be therefore included in the risk stratification scores," Mesa Aguado said.

(Sources: University of Granada and Science Daily)

DENTAL TRIBUNE

The World's Dental Newspaper · US Edition

PUBLISHER & CHAIRMAN

Torsten Oemus t.oemus@dental-tribune.com

PRESIDENT & CHIEF EXECUTIVE OFFICER

Eric Seid e.seid@dental-tribune.com

GROUP EDITOR

Kristine Colker k.colker@dental-tribune.com

EDITOR IN CHIEF DENTAL TRIBUNE

Dr. David L. Hoexter feedback@dental-tribune.com

MANAGING EDITOR U.S. AND CANADA EDITIONS

Robert Selleck r.selleck@dental-tribune.com

MANAGING EDITOR

Fred Michmershuizen
fmichmershuizen@dental-tribune.com

MANAGING EDITOR

Sierra Rendon s.rendon@dental-tribune.com

PRODUCT/ACCOUNT MANAGER

Humberto Estrada h.estrada@dental-tribune.com

PRODUCT/ACCOUNT MANAGER

Will Kenyon w.kenyon@dental-tribune.com

PRODUCT/ACCOUNT MANAGER

Maria Kaiser m.kaiser@dental-tribune.com

MARKETING DIRECTOR

Anna Kataoka a.kataoka@dental-tribune.com

EDUCATION DIRECTOR

Christiane Ferret c.ferret@dtstudyclub.com

ACCOUNTING COORDINATOR

Nirmala Singh n.singh@dental-tribune.com

Tribune America LLC
116 West 23rd St., Ste. #500
New York, N.Y. 10011
(212) 244-7181

Published by Tribune America
© 2015 Tribune America, LLC
All rights reserved.

Dental Tribune strives to maintain the utmost accuracy in its news and clinical reports. If you find a factual error or content that requires clarification, please contact Managing Editor Robert Selleck at r.selleck@dental-tribune.com. Dental Tribune cannot assume responsibility for the validity of product claims or for typographical errors. The publisher also does not assume responsibility for product names or statements made by advertisers. Opinions expressed by authors are their own and may not reflect those of Tribune America.

EDITORIAL BOARD

Dr. Joel Berg
Dr. L. Stephen Buchanan
Dr. Arnaldo Castellucci
Dr. Gorden Christensen
Dr. Rella Christensen
Dr. William Dickerson
Hugh Doherty
Dr. James Doundoulakis
Dr. David Garber
Dr. Fay Goldstep
Dr. Howard Glazer
Dr. Harold Heymann
Dr. Karl Leinfelder
Dr. Roger Levin
Dr. Carl E. Misch
Dr. Dan Nathanson
Dr. Chester Redhead
Dr. Irwin Smigel
Dr. Jon Suzuki
Dr. Dennis Tartakow
Dr. Dan Ward

Tell us what you think!

Do you have general comments or criticism you would like to share? Is there a particular topic you would like to see articles about in Dental Tribune? Let us know by sending an email to feedback@dental-tribune.com. We look forward to hearing from you!

If you would like to make any change to your subscription (name, address or to opt out) please send us an email at c.maragh@dental-tribune.com and be sure to include which publication you are referring to. Also, please note that subscription changes can take up to six weeks to process.

AD

A different implant for different challenges





With changes in the healthcare environment calling for more affordable treatment options, now is the time to incorporate narrow-body implants from Dentatus into your armamentarium.

FDA approved and backed up with over 10 years of clinical use, Dentatus ANEW, the only screw-retained, one-piece narrow diameter implant, is fast becoming the implant of choice for your narrow-diameter needs.



Learn how you can treat more patients with Dentatus ANEW at First Fridays, a monthly hands-on workshop at our implant center in New York City. For more information visit Dentatus.com or call 800-323-3136.



New York: 800-323-3136
Stockholm: +46-8-546-509-00
dentatus.com

Available in 1.8, 2.2 and 2.4 mm diameters

© 2015 Dentatus USA, Ltd., All Rights Reserved



PARADISE DENTAL INSTITUTE PRESENTS
SUMMERS IN PARADISE
1st Annual Conference

Set your coordinates for **July 30th - August 1st, 2015**
to latitude 25.075 N and longitude 77.32 W to the
Atlantis Resort and Casino, Paradise Island,
Bahamas. Full briefing to follow....



Navigating the Past

SAILING TO THE FUTURE

www.summersinparadise.com

Cosmetic periodontal surgery (Part 4B)

Barriers of success

By David L. Hoexter, DMD, FADC, FICD,
Editor in Chief

This is a continuation of the fourth article in a series of Dental Tribune clinical articles dealing with cosmetic periodontal surgery. As a follow-up to Part 4A, Part 4B in this series focuses on barriers used in cosmetic periodontal surgery. It also presents and deals with the predictable regenerative coverage of unesthetic root recession through cosmetic periodontal surgery, using the guided tissue regeneration (GTR) technique with resorbable barriers.

In Part 4A, I concentrated solely on the use of polylactic and polygalactic membranes used to regenerate gingival root coverage where root recession is clinically noted. While I presented clinical results using the Guidor polylactic barrier to aid in achieving excellent results when covering recessed area of teeth for up to 10 years, it should be noted that a 10-year study published in the Journal of Peri-

odontology concluded that after 10 years, Guidor used for gingival recession coverage, the same GTR technique as described in Part 4A, resulted in a larger recessed area than originally presented.

The “pin-hole technique” treatment to cover recession — recently popularized via the Internet — is not new. This technique was used as early as 1953 and, as was true then, still does not use barriers to help regenerate a blood supply on the previously exposed recessed tooth, as this series of articles emphasizes.

Without the newly regenerated connective tissue, the tissue covering the exposed root appears to be held in place by an adherence of a long junctional epithelium (not a regenerative attachment) and is thus doomed to repeated recession in the future.

Barrier enables selective guidance of restoration of lost periodontia

Periodontal disease leads to destruction that causes a void in which undesired cells have diminished the supportive

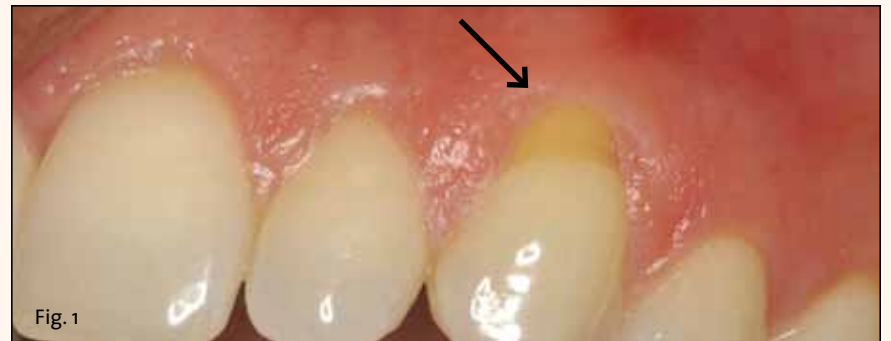

Fig. 1: Note the obvious singular defect of recession at the gingival area of #11. Photos/Provided by Dr. David L. Hoexter

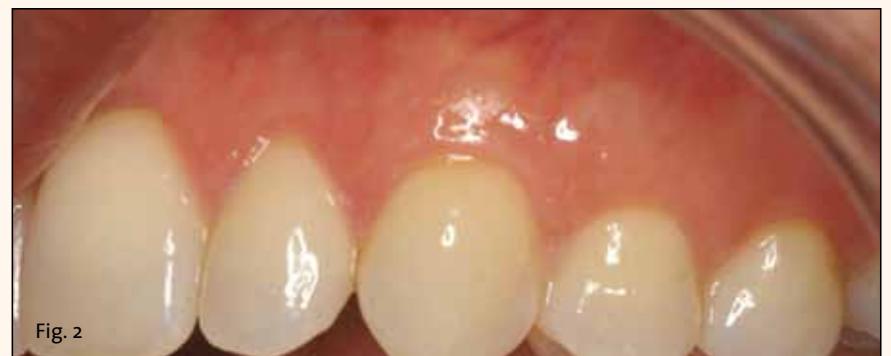

Fig. 2: Final 10-year result. Using the collagen barrier with the coronal repositioned flap technique permits the regeneration of the attached gingiva, with its pinkish white color blending naturally with the healthy lateral tissue of the area. Also, note the complete covering of the previous recessed root, with its tan color, to a natural appearing healthy area and a glowing smile that can be maintained with good oral hygiene.

AD

Wake up loving what you do
Have fun doing what you love



And make a difference in the world
Challenge the status quo
Join the LVI family of dedicated professionals
Find out how LVI can change you and your patients' lives

"My personal journey at LVI taught me the best, most cutting edge techniques in dentistry. It taught me how important it is to work on my business and most of all it allowed me to enjoy what I do whilst providing my patients with life changing dentistry."
Dr. Conchi M. Sanchez-Garcia, Miami, FL

888.584.3237 | LVIGlobal.com | youtube.com/user/LVITV

ADA CERP® | Continuing Education
Recognized Provider

LVI GLOBAL



periodontia. Periodontal surgery to correct this ideally hinges on proper sequential regeneration of the lost tissue. Restoration of the lost periodontia involves regenerating the lost supporting structures, including alveolar bone, connective tissue, keratinized epithelium, periodontal ligament and cementum. By placing a barrier to inhibit the undesired cells and to enable the desired progenitor cells to procreate, we can selectively guide the desired restoration of the lost periodontia.

For the past 40 or so years, regeneration of the periodontia — including osseous as well as soft tissue — has been achieved successfully by the use of barriers. The most popular barrier used to date is a membrane, although there have been several others used throughout the history of this type of treatment.

A barrier should create and maintain a sufficient space where an adequate blood supply may form to enable regeneration to occur. The space must be preserved for a certain period of time, and the barrier should be immobile during that time period. It needs to preserve this space while preventing epithelial cells and connective tissue cells from migrating into it. The barrier also must be porous so that metabolites can penetrate through to keep the underlying developing regrowth alive.

By using the GTR technique popularized by Dr. S. Nieman, we can inhibit the causal factors of this periodontal disease and support proper cellular regenera-

tion. This technique involves forming a porous barrier membrane that excludes the undesired cells, yet allows nutrition through its porous membrane to aid the selective population by undifferentiated mesenchymal cells toward the regenerative goal.

Nonresorbable membranes require second surgical procedure

Historically, different materials were developed to act as barriers for the GTR technique. Initially, nonresorbable membranes were utilized. A porous Teflon barrier membrane, expanded polytetrafluoroethylene (e-PTFE), was popularized by Gore.

This e-PTFE and its more economical equal, Sartorius, along with other nonresorbable barriers, such as Millipore filters, worked well. However, being nonresorbable, they required a second surgical procedure after the healing process was complete (usually months later) to remove the nonresorbable membranes. This second procedure required the patient to receive another local anesthetic and go through another uncomfortable healing process.

Other Teflon membranes that were nonporous and nonresorbable also were made available, but were not recommended for GTR because the lack of porosity inhibited essential nutrition from passing through — thus stopping newly forming blood supply from regenerating. Such membranes have, in fact, the same

► See BARRIERS, page A6

Maximize Clinical Performance with **BruxZir**® Solid Zirconia

Visit us at booth #4220

SUPERIOR PERFORMANCE AT 3+ YEARS

Gordon J. Christensen
Clinicians Report Reprint
 Reprinted June 2014, with permission, from Volume 7 Issue 6, June 2014, Pages 1-3
 A Publication of CR Foundation® • 3707 North Canyon Road, Building 7, Provo UT 84604 • 801-226-2121 • www.CliniciansReport.org

BruxZir and e.max CAD: Superior Clinical Performance at 3+ Years

TRAC Conclusions: BruxZir® and e.max® CAD full-contour crowns on molars have demonstrated clinical service superior to all other tooth-colored materials studied clinically by TRAC over 39 years.

IPS e.max is a registered trademark of Ivoclar Vivadent.

MARGINS



PFM

When a PFM is fabricated for this prep, there is a bulky 1 mm margin that catches on the explorer. Even if the margin is sealed, the emergence profile is unacceptable.

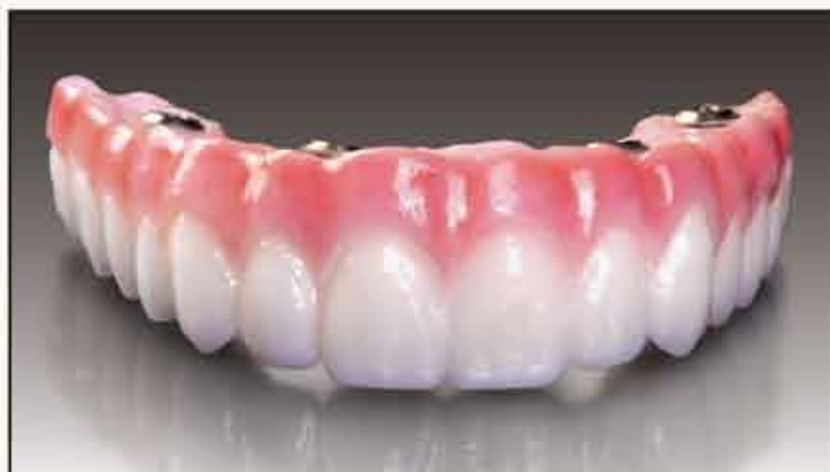VS



BruxZir Crown

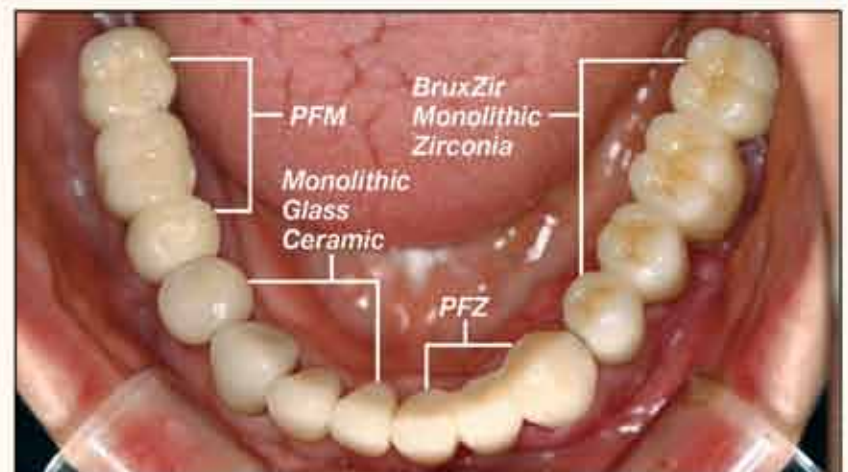
Because BruxZir is a monolithic crown and can be milled to a feather edge, your explorer will not detect where the tooth ends and the BruxZir crown begins.

STRENGTH



BruxZir Solid Zirconia has become the new high-strength, biocompatible option for fixed restorations, from single-unit crowns to full-arch implant-supported prostheses.

VITALITY



Full-arch case from dentist Sung-Kim, Republic of Korea, shows the natural-looking esthetics of BruxZir Solid Zirconia compared to PFM, PFZ and monolithic glass ceramic restorations.

FIND A BRUXZIR LABORATORY NEAR YOU



Select from
over 290 Authorized BruxZir[™]
 Laboratories in the United States

www.bruxzir.com



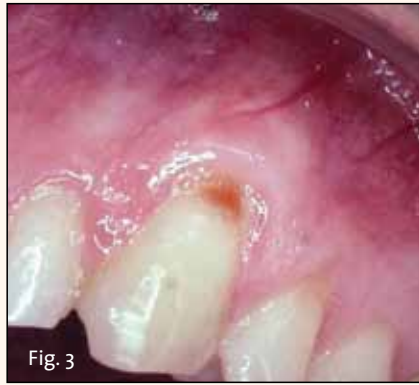

Fig. 3: Pretreatment view of #11 and #12. Note the large recessed gingival area exposing their respective roots.

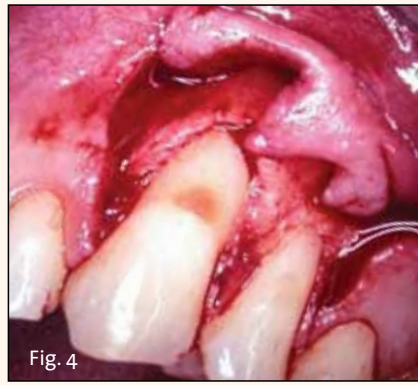


Fig. 4: Surgical mucogingival flap exposing recession areas of #11 and #12.

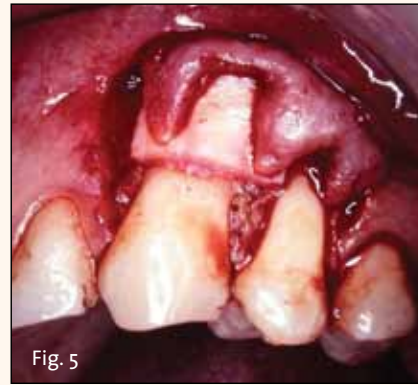

Fig. 5: Placement of connective-tissue barrier on only #11.

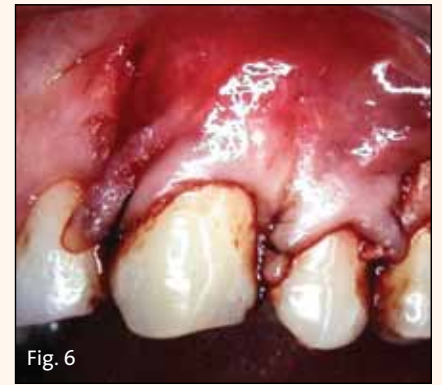

Fig. 6: Sutured coronal repositioned flap to desired level covering all exposed recession.

← BARRIERS, page A4

regenerative properties as a rubber dam and should not be used or considered for GTR.

These various challenges ultimately led to the development of resorbable barrier membranes that eliminated the necessity of a second surgical procedure — appreciated by patient and practitioner alike.

The resorbable membrane barriers that companies started to develop had all of the desired qualities of the nonresorbable group but did not need a second surgical procedure to be removed. Different materials led to different rates of absorption time, resulting in different amounts of time for inhibition of epithelium and/or connective tissue invagination. Therefore, different materials may result in dif-

ferent consistency of results.

The resorbable membrane barriers that are used most often in cosmetic root recession coverage are divided into three main groups, based on the type of material: 1) polylactic acid, 2) polygalactic acid and 3) collagen.

The polylactic and polygalactic membranes are similar except that polylactic acid membrane contains a citric acid ester, which enables it to be malleable.

Resorbable polygalactic barrier membranes were the first popular resorbable membranes approved by the FDA. Produced under the commercial name of Guidor, and developed for GTR procedures, they were made of polylactic acid with a citric-acid ester to enable malleability and easier clinical handling. The resorption of this material is through hydrolysis. Results show no soft-tissue

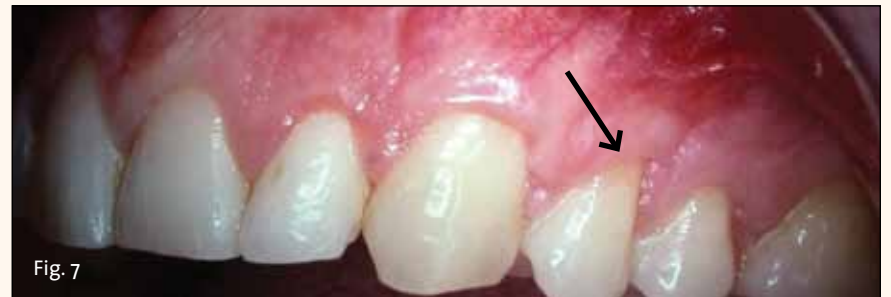

Fig. 7: Final result at 10-plus years. Complete recession coverage on #11. But note that root recession exposure on #12 returns as it was before surgery.

reactions during healing. Yet, there are reduced probing depths during healing and a definite gain of clinical attachments.

Options: Human, bovine or porcine

This article concentrates on collagen resorbable membrane barriers, which are made from three sources: human, bovine and porcine. While all three are adequate, my personal preference is human. Bovine has been used quite successfully, but it and porcine are xenografts (from different species). Additionally, I do not use porcine in my private practice out of respect for the religious preferences of many of my patients.

The specific acellular barrier that is used in these presentations is distributed through TBI (Tissue Banks International) under the brand name TranZgraft® ACD. There are several popular companies, but this company's product is a sterilized graft, compared with Alloderm, which is not.

Once again, it must be emphasized that before commencing any surgical correction, the practitioner must relieve the initiating factors that led to the recession.

Case No. 1

The patient presented with an obvious singular defect of recession at the gingival area of tooth #11 (Fig. 1).

Using a collagen barrier with the coronal repositioned flap technique enabled regeneration of the attached gingiva with a pinkish white color blending naturally with the healthy lateral tissue of the area.

In follow-up 10 years later, it was ob-

served that the complete covering of the previous recessed root was natural and healthy appearing and would continue to be able to be maintained with good oral hygiene.

Case No. 2

This case describes two areas of recession in a single mouth, thus influenced by identical saliva and oral habits. I used the same cosmetic surgery technique on both areas but used a barrier on only one of the areas (Figs. 3–6).

The 10-plus year outcome (Fig. 7) shows complete root coverage of gingiva on tooth #11, where the barrier collagen TranZgraft was used. The adjacent bicuspid #12 had the same coronal repositioned gingival flap procedure at the same time but without use of the connective tissue barrier.

The results clinically demonstrate that use of a barrier helped achieve complete restoration of gingiva tissue on previously recessed root. The same technique in this case, without the use of a barrier membrane, results in no root coverage (Fig. 7).

This particular case would appear to confirm that barriers aid in predictability of root coverage when using this cosmetic surgery technique.

Editorial Note: Part 1 in this series appeared in the Dental Tribune U.S. Edition, Vol. 4, No. 13/14; Part 2 ran in Vol. 6, No. 17; Part 3 ran in Vol. 7, No. 11; and Part 4A ran in Vol. 8, No. 11. These editions can be accessed as e-papers or PDF files through the "E-Paper" link in the top navigation menu on www.dental-tribune.com.

AD

ELEVATE
your expertise

A MICRODENTAL LABORATORIES
SPONSORED COURSE, 8 CE CREDITS

Learning Objectives:

- Principles behind the most comfortable Sleep appliance.
- Physiologic Dentistry and Sleep medicine in your practice.
- Professional success by incorporating Sleep into your practice.
- Recognizing patients who suffer from Sleep problems.
- Why Sleep should be managed in your practice "on Monday."

TO REGISTER OR FOR FULL COURSE DETAILS
Call MicroDental at 925.803.8618 or email
Events@MicroDental.com

LOCATIONS & DATES
San Jose, CA: 3/6; Vancouver, BC: 9/11; New York, NY: 11/6

ADA CERP® (Continuing Education Recognition Program)
LVI Global is an ADA CERP-Recognized Provider. ADA CERP is a service of the American Dental Association to assist dental professionals in identifying quality providers of continuing dental education. ADA CERP does not approve or endorse individual courses or instructors, nor does it make acceptance of credit hours by boards of dentistry. Concerns or complaints about a CE provider may be directed to the provider or to ADA CERP at www.ada.org.

MICRODENTAL LABORATORIES

Money Back Guarantee

This activity is supported by funding from MicroDental Laboratories. LVI Global has a number of corporate partners who contribute products and services that enhance the educational experience of those attending LVI Global courses and events, which are disclosed to participants at the activities.



DAVID L. HOEXTER, DMD, FICD, FACD, is director of the International Academy for Dental Facial Esthetics and a clinical professor in the department of periodontics and implantology at Temple University, Philadelphia. He is a diplomate of implantology in the International Congress of Oral Implantologists as well as the American Society of Osseointegration and a diplomate of the American Board of Aesthetic Dentistry. He lectures throughout the world and has published nationally and internationally. He has been awarded 12 fellowships, including FACD, FICD and Pierre Fauchard. He maintains a practice at 654 Madison Ave., New York City, limited to periodontics, implantology and esthetic surgery. He can be reached at (212) 355-0004 or drdavidlh@gmail.com.

Pacific Dental Conference exhibit hall includes popular 'Live Dentistry Stage'

More than 150 sessions and courses fill the March 5-7 event in downtown Vancouver

You can experience the true flavor of Canada's West Coast — and earn C.E. credits at the same time — at the Pacific Dental Conference, March 5-7, in Vancouver, British Columbia.

The PDC has an expert lineup of local, North American and international speakers.

With more than 130 presenters, 150 open sessions and hands-on courses covering a variety of topics, the meeting should be able to offer something for every member of your dental team.

Some of dentistry's top speakers

Here is a peek of just some of the presenters and topics on the agenda:

Gordon Christensen — materials and techniques; Jeff Brucia — restorative materials; Lee Ann Brady — restorative; Ann Eshenaur Spolarich — pharmacology; Jim Grisdale — periodontics; David Harris — fraud in the dental office; Michael Norton — implants; Bethany Valachi — ergonomics; Trisha O'Hehir — hygiene; Shirley Gutkowski — periodontics; Fernanda Al-

meida — sleep apnea; Anthony (Rick) Car-doza — forensics; and the Madow Brothers — practice management.

According to meeting organizers, you will be able to explore the largest two-day dental trade show in Canada, providing you the year's first opportunity to see the newest equipment. The exhibit hall features innovative techniques demonstrated on the live dentistry stage, and attendees will be able to examine products and services from more than 300 exhibiting companies with representatives who are ready to engage attendees in discussions on creating practice solutions.

Two days of sessions on the 'Live Dentistry Stage' in the exhibit hall

The Live Dentistry Stage is back on the exhibit hall floor, with demonstrations throughout the day on Thursday and Friday, March 5 and 6.

At 11:30 a.m. on Thursday, Mark Kwon and Bernard Jin will present "Immediate Anterior Implant Solution Using Total-Digital-Technology," co-sponsored by

Hiossen Implant Canada Inc. At 2:30 p.m., Shannon Pace Brinker will present "Whitening Techniques."

At 8:30 a.m. on Friday, Peter Walford will present "Multisurface Composite Restorations — A New Matrix and Other Key Success Determinants." At 11:30 a.m., Elliott Mechanic will present "The Single Crown Simplified," co-sponsored by the Canadian Academy for Esthetic Dentistry. At 2:30 p.m., Glenn van As will present "Lasers and Dental Implants," co-sponsored by Hiossen Implant Canada Inc.

Royal Canadian Dental Corps centennial celebration

This year marks the 100th anniversary of the Royal Canadian Dental Corps (RCDC). Since the formation of the Canadian Army Dental Corps on May 13, 1915, Canada's military dental services have worn six cap badges, served overseas in both World Wars and many other peace-making, peace-keeping, humanitarian and forensic operations, and looked after the oral health needs of Canada's troops.

In recognition of the centennial, this year's meeting includes two presentations by military personnel. Both topics should be of interest to a diverse civilian audience of dental professionals. Lt. Col. Genevieve Bussière will speak on "Military Forensic Identification Operations," and Maj. Sandeep Dhesi will speak on "Operational Oral and Maxillofacial Trauma Care."

Additionally, the RCDC will have a booth in the exhibit hall (No. 1351), where visitors can view a multimedia presentation highlighting various aspects of the RCDC centennial celebration.

Explore Vancouver

At the conclusion of the conference, you can take a day to relax and revitalize by exploring some of Vancouver's tourist attractions. The ocean is just steps from the Vancouver Convention Centre, and nearby snow-capped mountains offer up late-season skiing options.

(Source: Pacific Dental Conference)



Mornings are for learning, and afternoons and evenings are for the beach and other fun stuff at Smiles in the Sun. The 2015 session is April 22-26, in Long Boat Key, Fla.

Photo/Provided by Smiles in the Sun

'Sunsational' education includes beachside fun

Quality location plus quality education plus quality family time equals Smiles in the Sun 2015 in Longboat Key, Fla., April 22-26. Now you can earn C.E. credit while your family has a vacation that you can enjoy with them. All the programs are in the morning — leaving you the balance of your day to spend time with your family. Reduced rates are available at the family-friendly Longboat Key Club and Resort.

Speakers include Howard S. Glazer,

DDS, "What's Hot and What's Getting Hotter: New Materials and Techniques," George Freedman, DDS, "Improve Your Productivity with Innovative Dentistry," Fay Goldstep, DMD, "The Bioactive Patient," and Tennli Toole, "The Next Level for the Digital Dental Practice."

Register at smilesinthesun@verizon.net, www.smilesinthesun.net, or call (631) 423-5200.

(Source: Smiles in the Sun)

Explore The Future of Dentistry with Aurum Ceramic and LVI Global

The Physiologic Approach to Treating TMD and Sleep Breathing Disorders
FREDERICKSBURG, TX
March 6, 2015

The What, Where, When, Why & How of Neuromuscular Dentistry
HOUSTON, TX
April 17, 2015

Secure Your Future in These Difficult Times
REGINA, SK
April 24-25, 2015

Modern Advances, Techniques and Procedures that will Dramatically Enhance the Lives of You and Your Patients!
CALGARY, AB
May 8-9, 2015

Limited Seating
 Please register early to avoid disappointment. Dates and Locations subject to change. Please call to confirm dates.


Presented by

ERAMIC®
 DENTAL LABORATORIES

LVI GLOBAL

For more information, register:
 Email: ce@aurumgroup.com
 Phone: 1-800-363-3989
 Fax: 1-888-747-1233
 Mail: 1320 N. Howard
 Spokane, WA
 99201-2412

Downtown Seattle will host pediatric dentists May 21–24



The AAPD welcome reception features exclusive access to the Space Needle, EMP Museum and Chihuly Gardens. Photo/Provided by EMP Museum

Pike Place Market, the Space Needle, the EMP Museum and some of the top thought leaders in pediatric dentistry are among the reasons to be in Seattle May 21–24 for the American Academy of Pediatric Dentistry (AAPD) annual session.

Scientific sessions are at the Washington State Convention Center, in the heart of downtown, adjacent to hotels, restaurants, nightlife and shopping. Taking advantage of the location, the welcome reception on Thursday, May 21, features exclusive access to the Space Needle, EMP Museum and Chihuly Gardens.

The keynote, on May 22, features Frank Abagnale with “The True Story of Catch Me If You Can.” An authority on forgery, embezzlement and secure documents, Abagnale became an expert of sorts 40 years ago as a world-famous con man, as depicted in his best-selling book, “Catch Me If You Can.” Leonardo DiCaprio and Tom Hanks starred in a Steven Spielberg film based on the book.

Attendees must register for the meeting prior to making hotel reservations to get the meeting rate. Hotels in the AAPD official block are the Sheraton Seattle (headquarter hotel), the Grand Hyatt Seattle, the Hyatt at Olive 8, the Fairmont

Olympic, the Crowne Plaza, the Hilton Seattle and the Renaissance Seattle.

Three-day exhibit hall

Products and services in the meeting’s exhibit hall will be geared toward pediatric dental practices. An AAPD booth will have a bookstore, which will have copies of the Coding Manual, the new pediatric dentistry handbook. Also in the exhibit hall will be the Healthy Smiles, Healthy Children Donor Lounge, where you can learn more about Access to Care Grants and donate to its supporting foundation.

The exhibit hall schedule provides attendees plenty of time to explore without conflicting with education courses, while also leaving time to enjoy the city. A hospitality area on the exhibit hall floor will offer a continental breakfast, and there will be complimentary beverages each morning and afternoon and lunch available for purchase.

You can register for the meeting online by visiting www.aapd.org/annual.

(Source: AAPD)

AD

Bringing the global community together...the journey never ends.

Discover a World of Difference with Williams Dental Laboratory Regional Event

- Create a constant revenue \$55 stream WITHIN your office... NO NEED to refer out!
- Earn Continuing Ed credits
- Learn how to realize your dream future in dentistry
- Connect with the best dental community in the world
- Innovative techniques that will transform your practice
- Empower your patients beyond the limitations of their insurance
- OSA - Dentistry's role in the hottest topic of 2015

March 6-7, 2015
Sheraton Arlington Hotel
1500 Convention Center Drive
Arlington, TX 76011
817.261.8200

March 27, 2015
Coastyard OKC Downtown
3 West Reno Ave
OKC, OK 73102
405.232.2290

The instructors for these courses are hand-chosen clients of Williams Dental Laboratory and are REAL dentists in successful private practices... NOT consultants!

Register by visiting www.lvregionalevents.com or call 888.584.3237

PRESENTED BY: WILLIAMS
A world of difference... in every smile.

908.713.3390 | 908.412.8200
www.williamsdental.com
2330 Anthony Road | Edison, NJ 08817
www.williamsdental.com

JDIQ dates in Montréal, May 22–26

The Journées Dentaires Internationales du Québec, Canada’s largest bilingual dental meeting, according to organizers, is from May 22–26 (Friday through Tuesday) in Montréal. Online registration is available at www.odq.qc.ca.


Meeting apps for Apple and Android phones and tablets can be downloaded through www.odq.qc.ca, the app store or the Play Store. Onsite at the meeting, free WiFi will be available to all delegates and exhibitors at the venue, the Palais des congrès de Montréal.

The meeting’s educational program has more than 125 prominent speakers from Canada, the United States and Europe presenting approximately 175 educational sessions in English and French during the five-day convention.

Among the educational sessions: “Lights, Camera, Action! Patient Photography Made Easy — A Hands-On Workshop,” “Endodontics for General Dentists: Advanced, Comprehensive and Practical Hands-On Training,” “Oral Surgery for the General Dentist: Faster, Easier, and More Predictable” and “Hands-on Infection Control Workshop.”

Many other lectures and workshops are scheduled, with details in the program online.

The exhibition hall will feature more than 225 companies in 500 booths in the 133,563-square-foot space.



Saint-Paul Street in Old Montréal is one of many sights awaiting attendees of the 2015 Journées Dentaires Internationales du Québec, May 22–26.

Photo/MTTQ/André Rider, Tourism Montréal

More than 2,000 company representatives will be on hand to help you see, compare and make decisions on new furniture, equipment, instruments, techniques and other products and services — all under one roof.

One C.E. hour per day can be earned by visiting the exhibit hall. Just be sure to have your badge scanned at the entrance.

The exhibition hall hours are 8 a.m. to 6 p.m. on Monday, May 25 and 8 a.m. to 5 p.m. on Tuesday, May 26.

The organizers invite you to join the more than 12,000 expected delegates to meet, learn, share and enjoy this gathering of friends and colleagues.

(Source: JDIQ)

HIGH DEFINITION

IRIS ^{HD}

Introducing
IRIS HD USB 3.0
Intraoral Camera.
Experience the Clarity.

The new IRIS **HD** USB 3.0 brings the smallest details into brilliant full-screen high-resolution focus. With dual capture buttons and one-touch focus, control is always within reach. IRIS HD even knows to turn itself on and off when you pick it up or set it down.

Extreme clarity in HD is obtained with the IRIS HD precision optical lens array and Sony's advanced HD sensor for the finest picture quality.



A touch of the button and the newly designed electronic focus will advance automatically to the next focus mode, all five positions are shown onscreen.

Equipped with a motion sensor, it will Auto-On when lifted and Auto-Off after ten minutes of inactivity. The streamlined soft-tip has brilliant 8-point LED lighting and a new tapered USB 3.0 connector that fits in a standard delivery unit.

See why Digital Doc is the #1 choice in intraoral cameras. Call 1-800-518-1102 or visit us at www.digi-doc.com.



© Digital Doc LLC, 4789 Golden Foothill Parkway,
El Dorado Hills, CA 95762. The Digital Doc logo
and IRIS HD logo are trademarks of Digital Doc LLC.
All rights reserved.

