

DENTAL TRIBUNE

The World's Dental Newspaper • Pakistan Edition



PUBLISHED IN PAKISTAN

www.dental-tribune.com.pk

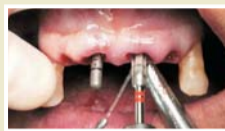MARCH, 2019 - Issue No. 02 Vol.6



Dental treatment service worsens in rural areas ...

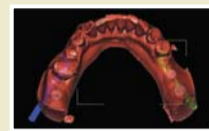NEWS

► Page 2



The fully digital Pro Arch protocol

CLINICAL IMPLANTOLOGY ► Page 6



Comparison of guided and non-guided implant placement accuracy ...

CLINICAL IMPLANTOLOGY

► Page 8

IDS reaffirms its leading position as global dental trade fair

DT International Report

COLOGNE, GERMANY - The International Dental Show (IDS), which took place in Cologne from 12 to 16 March, fulfilled the high expectations of the global industry and once again underlined its position as the leading trade fair. With 2,327 companies from 64 countries participating, this year's event welcomed 20 more exhibitors compared with two years ago, as well

as 160,000 trade visitors from 166 countries. The overall number of visitors rose by 3.2 per cent (about 5,000 more people) and the number of foreign trade visitors by 6.0 per cent.

Gerald Böse, CEO of Koelnmesse, which stages the show, said: "IDS is a trade fair in a class of its own and always sets new benchmarks. It manages to surpass the already excellent results of the previous event



The 2019 International Dental Show exceeded the results of the previous event and the organisers attained their goals of greater internationality and higher quality in supply and demand, boosting the satisfaction of both exhibitors and attendees. (Photograph: Dental Tribune International)

trade fair for the dental industry," he continued.

The official figures confirm the high level of internationality at IDS: 73 per cent of the exhibitors and 62 per cent of the visitors came from 166 foreign countries, including Argentina, Australia, Brazil, Canada, Chile, Egypt, Japan, Korea, New Zealand, South Africa and the US. Regarding

the 6 per cent increase in foreign visitors, IDS 2019 recorded significant growth in the number of visitors from Asia (+23.1 per cent), eastern Europe (+19.6 per cent), Africa (+17.0 per cent), Central and South America (+14.6 per cent) and North America (+5.3 per cent) specifically.

An independent visitors' survey

Continued on Page 15



Image: PTV News

Dr Inayatullah Padhiar receives Sitara-e-Imtiaz

DT Pakistan Report

KARACHI - Dr Inayatullah Padhiar was honoured with Sitara-e-Imtiaz in recognition of his services rendered to dentistry in Pakistan. The prestigious civil award was conferred by the President of Islamic Republic of Pakistan, Dr Arif Alvi, in the ceremony held at President House on March 23rd 2019.

Dr Inayat's academic journey and professional career make an inspirational story not only for his countrymen but for any and every person associated with dental profession, and academic and medical writing.

After graduating with Bachelors in Dental Surgery from Liaquat University of Medical and Health Sciences in 1974, he began to show eager and active participation in organized dentistry in the country. He had

Continued on Page 15

WORLD ORAL HEALTH DAY'19

3.6 million smiles spread across Pakistan!

DT Pakistan Report

KARACHI - The World Oral Health Day 2019 campaign concluded successfully, resulting in 3.6 million bright smiles! In Pakistan, the campaign was organized by Dental News in collaboration with World dental Federation (FDI) and Pakistan Dental Association (PDA), in close association with Shield Pakistan, which sponsored the CSR activity. Dental Tribune International (Pakistan) was the official media partner for the events conducted under the aegis of WOHD. The movement for oral care awareness probed and penetrated many diverse population groups. Various programs aimed at oral care consciousness were conducted as part of their WOHD'19 campaign.

The official theme of the 2019 World Oral Health Day (WOHD)

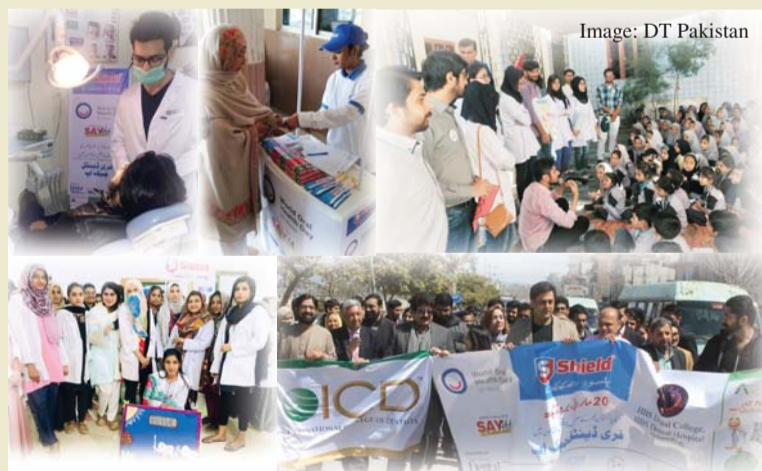

Image: DT Pakistan

campaign was, 'Say Ahh: Act on Mouth Health'. The scheme for this year was to 'motivate people to take action about their mouth health.'

To realize these objectives, several resources were deployed to awaken and foster the sense of care for oral health among masses. Through different contests and

polls people were educated on the various facts and concerns regarding oral care; efforts were contributed toward raising awareness about the weightiness of mouth problems in order to push the masses to consider the status of their oral health. People were encouraged to immediately report

Continued on Page 14

Dr Tariq Bhutta elected new PMDC president

DT Pakistan Report

ISLAMABAD - On March 31, first meeting of the newly-constituted Council constituted under the 2019 Ordinance was held to elect the president and vice president.



Pakistan Medical and Dental Council has elected new president and vice president after running on ad-hoc basis for 13 months. The 17-member new council notified by Ministry of National Health Services, Regulations and Coordination has elected Dr Tariq Bhutta as new president while Dr Amer Zaman as Vice President of the council.

Officials said that Dr Tariq Bhutta secured 11 votes for the slot of president, while his opponent Dr Shoaib Hassan Shah got 5 votes. Meanwhile, on the post of VP, Dr Amer Zaman secured 10 votes, while his opponent Dr Shabir Lehri received six votes. Dr Syed Shoaib Hassan Shah, Dr Tariq Bhutta, Dr Shabir Lehri and Dr Amer Zaman Khan and contested in the polls for the position of president and vice president of the PMDC.

Elections were conducted at PMDC headquarters. An official said that president and vice president of the council are elected under section 4 (3) of the PMDC Ordinance 2019.

Dr Shabir Lehri earlier served as president of PMDC before the council was dissolved by the former chief justice Saqib Nisar. The former CJP in January 2018 had dissolved the 35-member council and formed a 9-member ad-hoc council headed by former Supreme Court judge, Justice

Continued on Page 15



Photo: DT Pakistan

Dental treatment service worsens in rural areas: PDA press conf

DT Pakistan Report

KARACHI - The Pakistan Dental Association (PDA) has warned that the situation concerning the availability of dentists in small towns and the rural areas of the country has become so dismal that fatal oral diseases among their populace could spread like an epidemic if the due corrective measures are not taken on an emergency basis.

The PDA issued this health alert recently following a press conference at the Press Club held by officials on the eve of World Oral Health Day which is globally celebrated every year on 20th March. General Secretary, PDA, Prof Nasir Ali Khan, Senior Vice-President, PDA, Dr Anwar Saeed, and Dr Asif Arain were also present on this occasion.

"In Karachi, one dentist is available for every 5,000 people on average. The situation is similar in other big cities like Lahore and Islamabad. However, when we go to the relatively faraway district of Tharparkar, not a single dentist is available for a section of the population as big as 200,000 people," said Dr Mahmood Shah, President, PDA, while speaking to the press.

Dr Shah said that the situation of availability of dental treatment services in the rural and far-flung areas of the country had been getting worse with each passing year instead of improving owing to the utterly indifferent attitude of the relevant public health authorities.

He informed that the dentist-

population ratio in Pakistan had been alarmingly uneven across the country as it fluctuates heavily between urban and rural areas as these statistics fall much lower than the standards of public health services set by the concerned global agencies like the World Health Organization.

"One of the means to rectify this situation is by the opening of dental colleges in the small towns of the country as these institutions of dental education should not be just confined to the big cities," said the PDA President.

He said that another way of tackling the situation could be done via the proper activation of rural health centres of the provincial governments. Dental surgeons should be recruited for placing them at these RHCs for the provision of much-needed dental health services to the villagers.

Dr Shah added that such measures had to be taken to extend the dental care services across the country as oral cancer had become the second most recurring form of cancerous disease in Pakistan after lung cancer. He said that various forms of chewable tobacco and other hazardous chewing material like Gutka, Mainpuri, betel nuts, Supari, were being consumed in the society unchecked as this social epidemic is equally affecting large cities, city suburbs, small towns, and rural areas.

Dr Shah stressed that early screening and diagnosis of a case of oral cancer could ensure its complete treatment as otherwise, it could prove

Continued on Page 14

DENTAL TRIBUNE

The World's Dental Newspaper - Pakistan Edition

Publisher/CEO

Syed Hashim A. Hasan
hashim@dental-tribune.com.pk

Editor Clinical Research

Dr. Inayatullah Padhiar

Editors Research & Public Health

Prof. Dr. Ayyaz Ali Khan

Editor - Online

Haseeb Uddin

Designing & Layout

Sh. M. Sadiq Ali

Dental Tribune Pakistan

3rd floor, Mahmood Centre, BC-11, Block-9
Clifton, Karachi, Pakistan.
Tel.: +92 21 35378440-2 | Fax: +92 21 35836940
www.dental-tribune.com.pk
info@dental-tribune.com.pk

Dental Tribune Pakistan cannot assume responsibility for the validity of product claims or for typographical errors. The publisher also does not assume responsibility for product names or statements made by advertisers. Opinions expressed by authors are their own and may not reflect of Dental Tribune Pakistan.

International Imprint

Publisher/Chief Executive Officer **Torsten R. Oemus**

Chief Financial Officer **Dan Wunderlich**

Director of Content **Claudia Duschek**

Senior Editors **Jeremy Booth**
Michelle Hodas

Clinical Editors **Nathalie Schüller**
Magda Wojtkiewicz

Editor & Social Media Manager **Monique Mehler**

Editors **Franziska Beier**
Brendan Day
Luke Gribble
Kasper Mussche

Assistant Editor **Iveta Ramonaite**

Copy Editors **Ann-Katrin Paulick**
Sabrina Raaff

Business Development & Marketing Manager **Alyson Buchenau**

Digital Production Managers **Tom Carvalho**
Hannes Kuschick

Project Manager Online **Chao Tong**

IT & Development **Serban Veres**

Graphic Designer **Maria Macedo**

E-Learning Manager **Lars Hoffmann**

Education & Event Manager **Sarah Schubert**

Product Manager Surgical Tribune & DDS.WORLD **Joachim Tabler**

Sales & Production Support **Puja Daya**
Hajir Shubbar
Madleen Zoch

Executive Assistant **Doreen Haferkorn**

Accounting **Karen Hamatschek**
Anita Majtenyi
Manuela Wachtel

Database Management & CRM **Annachiara Sorbo**

Media Sales Managers
Melissa Brown (International)
Hélène Carpentier (Western Europe)
Matthias Diessner (Key Accounts)
Maria Kaiser (North America)
Weridiana Mageswki (Latin America)
Barbora Solarova (Eastern Europe)
Peter Witteczek (Asia Pacific)

Executive Producer **Gernot Meyer**

Advertising Disposition **Marius Mezger**

Dental Tribune International GmbH

Holbeinstr. 29, 04229 Leipzig, Germany
Tel.: +49 341 48 474 302 | Fax: +49 341 48 474 173
info@dental-tribune.com | www.dental-tribune.com

©2019, Dental Tribune International GmbH. All rights reserved. Dental Tribune International makes every effort to report clinical information and manufacturer's product news accurately, but cannot assume responsibility for the validity of product claims, or for typographical errors. The publishers also do not assume responsibility for product names, claims, or statements made by advertisers. Opinions expressed by authors are their own and may not reflect those of Dental Tribune International.

Prof Charlotte of King Abdullah University visits KCD

DT Pakistan Report

PESHAWAR - Professor Dr Charlotte A. E. Houser of the King Abdullah University of Science and Technology (KAUST), Jeddah, Kingdom of Saudi Arabia paid her second visit to Khyber College of Dentistry (KCD) this month.

She delivered a lecture on "Peptides for Regenerating Life: Use of Peptide Biomaterial for Injectable Therapies and 3D Tissue Printing."

MoU has been signed between Khyber College of Dentistry and King Abdullah University, Saudi Arabia, as they share a common goal to advance science and technology through bold and collaborative research and education, while addressing challenges of national, regional, and global significance.



Image: DT Pakistan


Raise the level of satisfaction for your sensitivity patients...

...with **superior* science** both in your office, and at home.

In a clinical study, patients reported feeling better both **instantly** and **after 2 weeks** of using **Colgate® Sensitive Pro-Relief™** Toothpaste¹



Apply before procedures for instant[†] relief
48.9%¹ reduction in sensitivity after prophylaxis[‡]



Provide superior dentin occlusion
91% occlusion vs 67% with Sensodyne® Rapid Relief^{§2}



Recommend continued 2X daily brushing for long-lasting protection[¶]
90.1%[‡] reduction in sensitivity after 2 weeks of continued 2X daily brushing[†]



*Vs conventional sensitive toothpastes containing 5% potassium nitrate (equivalent to 2% potassium ion).

[†]For instant relief, apply directly to the sensitive tooth with fingertip and gently massage for 1 minute.

[‡]Air blast hypersensitivity test in a clinical study after 1 application and after 2 weeks.

[§]In-vitro study, actual confocal image after 5 treatments.

[¶]Lasting relief with continued use.

References: 1. Ayad F, Ayad N, Vazquez J, et al. *Am J Dent* 2018. 2. Hines D, Rinaudi-Marron L, Lavender S, et al. Accepted poster, July 2018 IADR. Colgate-Palmolive Company 2018.

Colgate®

PMDC requests doctors to halt practice if without license

DT Pakistan Report

ISLAMABAD - The Pakistan Medical and Dental Council has asked doctors to avoid private practice or work in public or private sector hospitals without a valid council license. According to an official of the PMDC, without a valid council registration, no doctor is eligible to practice in the country, and they have been clearly warned through a public notice that the council will take strict action against doctors having invalid council registration. He said that no medical certificate, prescription, or advice would be considered valid unless obtained from a medical or dental practitioner having valid registration.

He said that it had been observed that doctors and dentists were practicing without having a valid license as per the Pakistan Registration of Medical and Dental Practitioners Regulations, 2008. The council through a public notice warned them that after one month of issuance of this notice, names of the doctors with invalid registration would be published in the newspapers for strict action.



Image: DT Pakistan

Under the law, no person, other than a registered medical or dental practitioner can practice medicine or dentistry. If any person who acts in contravention of the provisions of sub-section (I) will be punishable with imprisonment for a term which may extend to two years but will not be less than six months or with fine. The amount for the fine may extend to Rs200000 but will not be less than Rs100000. He added as per law, any medical practitioner or a dentist possessing any recognized medical or dental qualification whose name was maintained on the register of the council can work or start practice as doctors in the country. He said that as per PMDC regulations, only those names would be retained on the register, who

have paid the dues of the council and only these names will be considered to have valid registration.

He said that through its public notice, all medical and dental practitioners, specialists and faculty with expired or invalid registration had been asked to get their PMDC registration renewed within two months. Those who fail to comply will be met with the council who will take strict action to exercise its powers conferred under the PMDC ordinance of 1962.

He said that the council has planned to take strict action against the doctors having invalid council registration. He added that the Pakistan Medical and Dental Council would ensure the countrywide renewal and registration process of doctors.

SBDC shines at 7th International Students Dental Conference

DT Pakistan Report

SHARJAH - The 7th International Students Dental Conference was held at the University of Sharjah from February 10th to 11th. The theme for the event was 'to inspire the dentists of tomorrow, nations are united today', and was specifically organized for dental students and junior dentists. Alongside scientific & social programs, a variety of workshops were also offered at the conference; various competitions were held as well.



One such segment was the Jeopardy Quiz, which took place between two contesting teams. The 'Alpha Group' included two house officers from Sardar Begum Dental College (SBDC), Dr Muhammad Asif and Dr Siddiq Yousufi, and a candidate from University of Sharjah, Dr Nadine Al-Wazzan. Team Alpha won the quiz with an impressive score.

Dr Siddiq Yousufi of SBDC scored another achievement at the international conference by claiming 1st position in poster competition. The topic of his poster presentation was 'Use of Antibiotics in teaching dental hospitals of Peshawar, Pakistan. How justified are we?' Co-investigators for the research project included Dr Yasir Israr and Dr Shaina Zaman. The project was supervised by Dr Syed Imran Gilani, Assist. Prof. Community and Preventive Dentistry.

Ministry to push for 'Health Tax' in budget against tobacco products

DT Pakistan Report

ISLAMABAD - The Ministry of National Health Services, Regulations and Coordination will urge the government to include the "Health Tax" in the upcoming budget for the fiscal year 2019-20 to cut the rising tobacco consumption and increase the revenue, reported officials. A senior official of the ministry stated that they would soon forward a "Health Tax 2019" summary to the relevant government departments, suggesting additional taxes on tobacco products and beverages to discourage their consumption.

Earlier in February this year, the Federal Cabinet rejected the proposal of the Health Ministry for the imposition of 'sin tax' on consumption of tobacco and beverages owing to the legal and administrative lacunae in the enforcement of the



Image: DT Pakistan

levy. Under the "Health Tax," the ministry had proposed imposing an additional Rs10 on each cigarette pack, while Rs10 for 250ml beverage bottle.

The official said that the Federal Board of Revenue (FBR) opposed the imposition of the health levy as it would only increase taxation on multinational

companies that are already paying "heavy taxes."

A special audit report on the causes of the decline in tax collection of the tobacco sector has revealed that the cigarette manufacturing industry was involved in tax evasion of Rs33 billion, and recommended the withdrawal of the third tier of the taxation system for the tobacco

industry, which has resulted in the annual loss.

It suggested the government to increase the Federal Excise Duty (FED) on an annual basis to comply with the World Health Organization (WHO) rules, as this will also result in higher revenues for the government. According to the WHO, a minimum of 70% of the retail price is an

excise tax, but in Pakistan, 45.79% of retail price is an excise tax. The economic cost of smoking in Pakistan amounts to Rs143.208 billion annually, and it includes direct expenses related to healthcare expenditures and indirect costs related to lost productivity due to early mortality and morbidity, as told by a report.

The report also revealed that every year more than 160,100 people die in Pakistan of tobacco-caused diseases and still more than 125,000 children (10-14 years old) and 14,737,000 adults (15+ years old) continue to use tobacco each day. The health ministry official said that keeping in view all this economic and health loss; they have been trying to convince the Federal Cabinet, FBR and other relevant departments for the imposition of the "Health Tax" in the upcoming budget.

SENSODYNE
RAPID ACTION



**BEAT
SENSITIVITY
PAIN
FAST**

Clinically proven relief in just
60 SECONDS



The fully digital Pro Arch protocol

By Cuadrado de Vicente, Becerra, Cuadrado Canals

The Straumann Pro Arch concept involves different treatment solutions for the fully edentulous patient. The objective is to provide a predictable, reproducible and simple treatment that restores patients' oral health and consequently improves their quality of life dramatically. The possibility of immediate, same-day rehabilitation by means of temporary fixed prostheses offers maximum treatment quality and satisfaction for both the dental team and patient. The objective of the treatment with an immediately loaded fixed prosthesis on implants is to improve the patient's quality of life by providing function, aesthetics and health until

reproducible results, with the use of the intra-oral scanner as the principal element. Our protocols include the use of certain elements (adequate implant system, Osstell, etc.) and action protocols for scanning, surgical and prosthetic procedures and laboratory operations, including the production and maintenance of the provisional prosthesis.

In this case report, we present the i2 Standard protocol. This can be applied to patients requiring the removal of terminal dentition. In summary, this involves selected extractions, implant placement, intra-oral digital impressions, and the design and production of the temporary fixed prosthesis in PMMA, with placement in the patient on the same day.

It is important to note that our fully

periodontist. A panoramic radiograph and dental CT scan were taken to evaluate the bone availability, disposition and density (Figs. 1 & 2). After the different treatment options were discussed, and in view of the patient's overall dental, social and financial situation, an implant treatment with a same-day fixed temporary restoration was the first choice for both the dental team and the patient.

Treatment planning

The goal was to load the implants immediately with a fixed screwed temporary prosthesis. To achieve this, the strategic extraction of some dental elements was planned, with the temporary preservation of those key elements that, in the intra-oral scanning, determined the patient's

occlusion and occlusion (Fig. 3).

The surgery was performed under local anaesthesia and with patient monitoring by an anaesthesiologist using conscious intravenous sedation with midazolam and pulse oximetry monitoring. Removing failing teeth was the first task, keeping in place those teeth with less mobility and in strategic positions to maintain antagonist contacts, and trying to keep the same preoperative bite (Fig. 4).

Extraction sockets were fully debrided with a bur to remove all of the granulomatous tissue. Gingival trimming was also performed on those gingival parts with deep pockets. Cleaning with hydrogen peroxide and saline was the final step, obtaining fresh places for the implants.

Keeping in mind the bone anatomy,

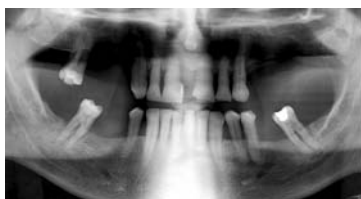

Fig. 1

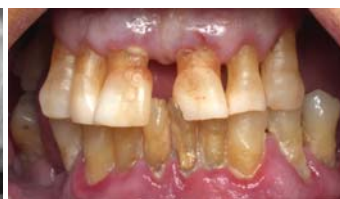

Fig. 2

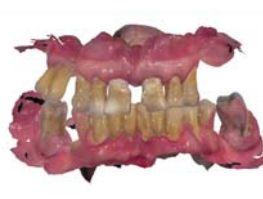

Fig. 3

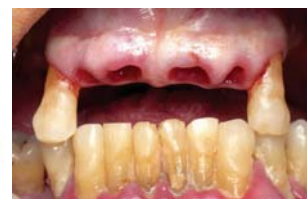

Fig. 4

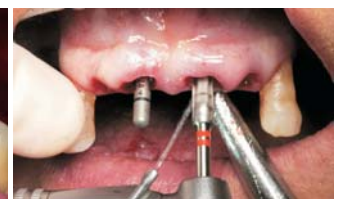

Fig. 5

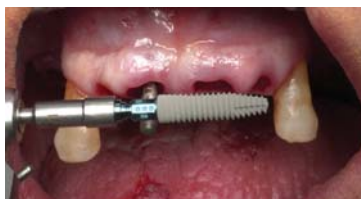

Fig. 6

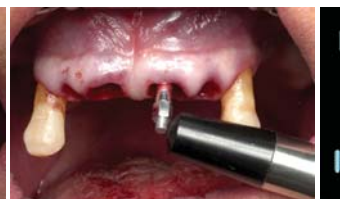

Fig. 7

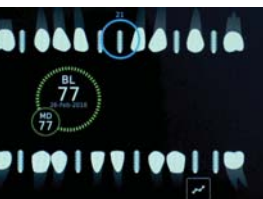


Fig. 8

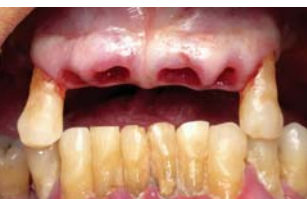

Fig. 9

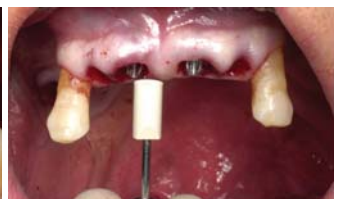

Fig. 10

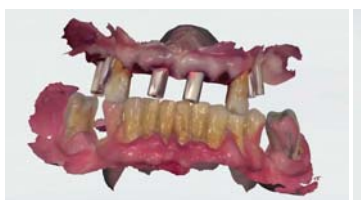

Fig. 11

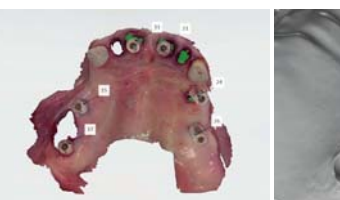

Fig. 12




Fig. 13



Fig. 14

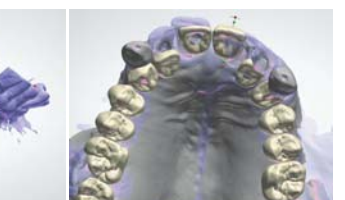

Fig. 15

Fig. 16

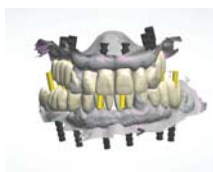

Fig. 17

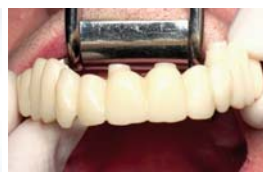

Fig. 18

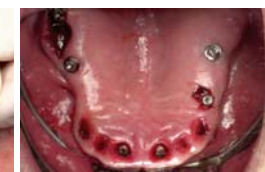

Fig. 19

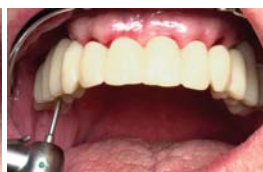

Fig. 20

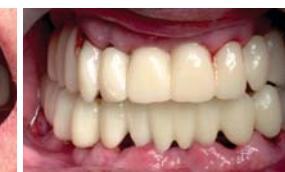

Fig. 21

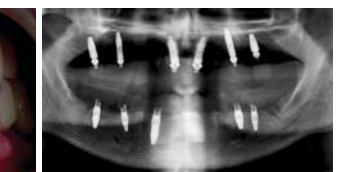


Fig. 22

osseointegration is established.

Owing to the fully digital workflow, which starts with the use of an intra-oral scanner, the work team is able to offer a treatment of extreme precision in a simple way. This marks the beginning of a completely digital treatment right up to the final prosthesis. This could be considered as a new form of implantology in which the different elements of treatment are optimised to obtain a spectacular result.

With this objective in mind, at i2 Implantología, we have developed a number of solutions and protocols covering the different clinical situations in fully edentulous patients and based on classical implantology principles to obtain predictable and

digital protocol to reach the final prosthesis is based, if needed, on the production of subsequent different temporary prostheses until osseointegration is established. We will modify the initial design (and produce further temporaries) always according to a fully digital approach, in order to obtain the final mock temporary prosthesis that fulfils the functional and aesthetic parameters in the patient. The information provided by this final mock temporary will be copied on to the final prosthetic design. A trained dental team, clinic and laboratory are mandatory.

Initial situation

A 68-year-old patient with no medically relevant history and hopeless dentition was referred by his

aesthetics, vertical dimension of occlusion and prosthetic arch. We decided to perform minimally invasive surgery, where possible, with a flapless technique to avoid any mobile tissue that could affect intra-oral scanning. The placement of six Straumann Bone Level Tapered, Roxolid, SLActive implants with screw-retained abutments (SRAs) was planned for the restoration.

Surgical procedure

Before starting the surgery, an initial study model scan was obtained with the intra-oral scanner and sent to the laboratory as the patient's original file (File 1). This file contained all of the information concerning the patient's preoperative situation, including teeth, aesthetics, vertical dimension of

availability and expected density, the final implant locations were selected and the implant beds were prepared at 800 rpm with continuous saline irrigation. The implant beds have to be prepared such that parallelism is maintained between all the implants. When placing tilted and/or non-parallel implants, the preparation angle should be either 17° or 30° to match the available SRA custom angulation. Accordingly, the dentist is constantly striving for the least divergent implant preparation, drilling at 0, 17 or 30°. The Pro Arch guide is very useful for this purpose.

Furthermore, undersized drilling with continuous bone density assessment according to the operator's

Continued on Page 12



HELP KEEP YOUR PATIENTS ON A JOURNEY TO HEALTHY GUMS

PARODONTAX® TOOTHPASTE IS CLINICALLY PROVEN TO REDUCE PLAQUE, BLEEDING GUMS AND INFLAMMATION

4X

greater plaque removal*¹

48%

greater reduction in bleeding gums*¹

Recommend parodontax® toothpaste to help patients maintain their optimal gum health between dental visits.

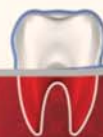DAILY FLUORIDE TOOTHPASTE FOR HEALTHY GUMS & STRONG TEETH

parodontax®

EXTRA FRESH

gsk

Helps stop and prevent bleeding gums



GlaxoSmithKline Consumer Healthcare Pakistan Ltd.
35-Dockyard Road, West Wharf, Karachi - 74000

GSK is committed to the effective collection and management of human safety information relating to our products and we encourage healthcare professionals to report adverse events to us on +92 (21) 111-475-725 or pk_pharmasafety@gsk.com

* Compared to a regular toothpaste and professional clean and 24 weeks' twice-daily brushing.

Comparison of guided and non-guided implant placement accuracy – In vitro study with 3-D printing

By Dr Lukasz Zadrozny et al.

The procedure of implantation is becoming an increasingly popular method for replacing teeth. The critical factor in the achievement of a therapeutic and aesthetic long-term effect is the accuracy and precision of implant placement, being the support for the future prosthetic work. Thanks to modern digital technologies, it is possible to plan the implantation virtually. Evaluation of this plan by 3-D printing in a subsequent step allows the creation of implant guides.

Using the guides, which provide precise information on implant placement and insertion depth and angle, allows the maintenance of all the parameters included in the planning stage, lowering the risk of a mistake during implantation. Using 3-D printing allows the fabrication of both implant guides and study models that accurately represent patients' true clinical conditions. This makes it possible to compare the precision of procedures under the in vitro conditions, which are safe and representative of actual requirements. During the implantation, clinical conditions very often hinder precise orientation in the operating field, thus the precision of implant positioning

is lower. According to the literature, both more and less experienced clinicians face this problem. Introducing virtual planning based on CBCT is highly useful while preparing for the procedure; however, what allows the fully controlled preparation of the implantation site is the transfer of its result to the guide imposing the positioning. The virtually created implant guide can be printed using a 3-D printer, sterilised and then used in the procedure. The use of the guide affects the precision of the procedure and shortens its time.

Aim of the study

The aim of the study is to prepare 3-D models for the analysis of the precision of implant procedures performed on the basis of digital planning, conducted with and without the use of implant guides. Methodology Based on the CBCT examination of the patient, who underwent implantation in the mandible, a 3-D model corresponding to the actual bone and mucosal conditions before implantation was created in DDS-Pro software (www.dds-pro.com.pl). It was then reprinted 20 times. The print was produced with selective laser sintering technology using polyamide powder

in the TPM Elite P3600 SLS System printer (Solveere). It yielded ten identical pairs of mandibular models. Virtual planning (DDS-Pro; Fig. 1) of implant positioning and placement (TSIII, OSSTEM IMPLANT) and the implant guide, printed in 3-D with Jet technology (ProJet MP 3000 printer, 3-D Systems), with stock sleeves for three implants with regular platforms previously used clinically (sterilised), were used to introduce implants into every second printed model, using the OsstemGuide KIT (Taper). The drilling speed was set at 1,200 rpm. Water cooling was not used. Osteotomies were performed according to the manufacturer's instructions. Other models were used for implantation based on the planning performed, but without additional help (no guide), using the same implant kit and under the same conditions. As the test was conducted in vitro, TSIII training implants with dimensions of 4 × 10 mm were used. It was assumed that all ten procedures performed would yield the same results.

Findings

The use of 3-D printed models allows implantation under conditions spatially corresponding to those of a clinical situation. However, the models printed in this study were

hard. The material cut during osteotomy preparation was deposited on the drill and the implant thread, making it difficult to perform full-depth insertion. More torque was required to insert the implant than is clinically used. It was observed that, when an osteotomy was prepared in the vicinity of a preserved tooth, there was a need to use the drill extension in order to avoid leaning the contra-angle handpiece on the guide or tooth. Because this tool is missing in the OsstemGuide KIT (Taper), one must have an additional implant kit when using it clinically. The use of the guide shortens the implantation time, compared with the same procedure performed with no help of a guide.

In the following stage of the project, the models will be optically scanned and undergo comparative analysis in terms of repeatability, accuracy and compliance with the planned virtual goal.

Editorial note: The study is being carried out as a part of a project in the field of scientific developmental research aimed at the development of young scientists and students enrolled in PhD studies, financed as part of the scientific activity of the Medical University of Warsaw in Poland.
- Dental Tribune International

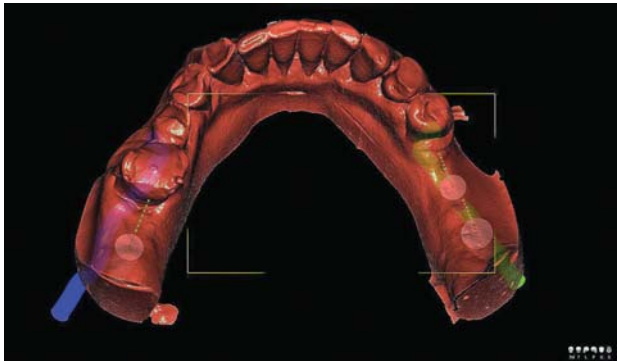


Fig. 1a: Virtual planning of implant positioning.

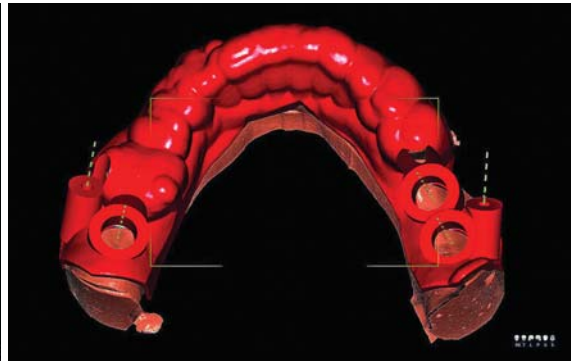


Fig. 1b: Virtual planning of implant positioning.



Fig. 2: Exemplary pair of models before the procedure: on the left, without the guide, and on the right, with the guide.

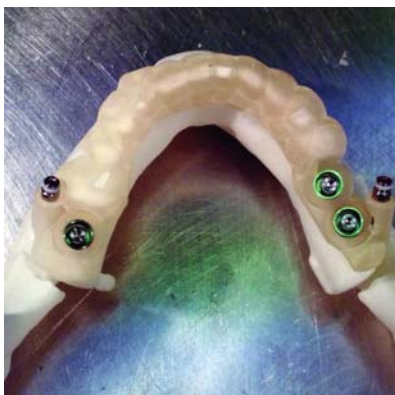

Fig. 3: A model with the guide and implants after the implantation. The guide was stabilised with two posts.

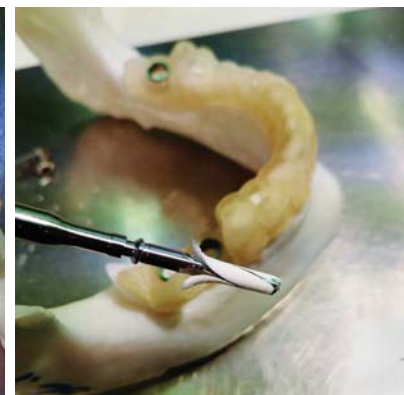


Fig. 4: The material was deposited on the drill attached to the extension.

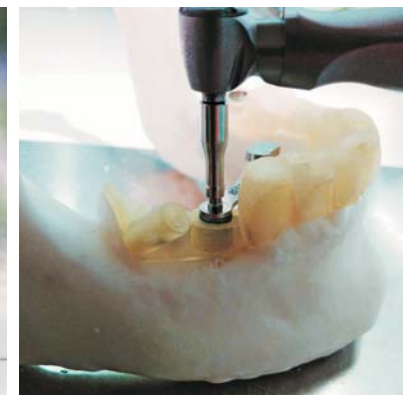


Fig. 5: Drill attached to the extension passing through the reduction sleeve. The extension allows the drill to be guided correctly without touching the template on the adjacent tooth with the contra-angle handpiece.

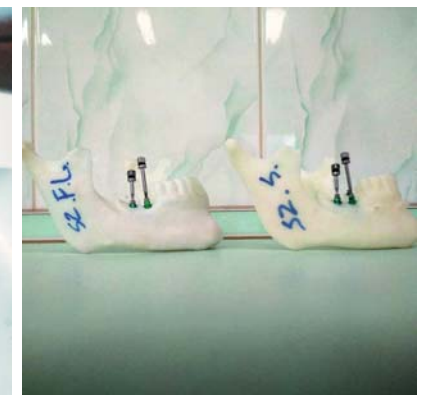

Fig. 6: Models after performing the procedures with the use of the guide. The same axes of the implants inserted are visible.

Annual Publishers' Meeting: DTI looks towards the future

By Brendan Day

COLOGNE, GERMANY - In the lead-up to the 38th International Dental Show (IDS), Dental Tribune International (DTI) held its 15th Annual Publishers' Meeting over 10 and 11 March in Cologne. This year's gathering saw 75 members of the DTI network from all over the globe in attendance to discuss the latest developments and projects the company is undertaking.

Among the highlights of the meeting was the official introduction of Dental Tribune Algeria, the newest international licence partner. Led by Dr Ouahes Aziouez, the new partner will produce Dental Tribune Algerian Edition, a quarterly publication that will focus on the latest developments in dentistry within the Maghreb region. Its first issue will be formally launched at IDS and will be available for viewing at the DTI Media Lounge in Hall 4.1 at Booth D060-F061.

The Annual Publishers' Meeting also provided an opportunity for an exciting announcement about DTI's upcoming expansion into the Scandinavian dental media market. Though the details are still being finalised, new Dental Tribune editions for the region will be launched soon, according to DTI President and CEO Torsten Oemus. "We look forward to welcoming our Scandinavian friends into the fold here at DTI and expanding our international presence," he said.

Oemus also spoke about one of the newest additions to the DTI portfolio, Smyle magazine. With its flagship German-language edition currently delivered to over 60,000 dental practices in Germany, Smyle is to be expanded to include an international English-language version later this year. "By introducing an international edition of Smyle, we will be able to highlight the latest global trends in well-being, health, beauty and more," said Oemus.



This year's gathering saw licence partners from all over the globe in attendance to discuss the latest developments and projects the company is undertaking. (Photograph: Tom Carvalho, DTI)

An update on the status of the highly anticipated DDS.WORLD was also provided at the meeting by Joachim Tabler and Martin Troppa, departing and incoming DDS.WORLD managers, respectively. A full-service digital marketplace for products, news, e-learning and practice management, DDS.WORLD is targeted at all participants in the dental industry. It offers a web shop and an associated search facility, practice management and inventory management systems, direct customer communication tools and much more. Attendees were

informed that DDS.WORLD will initially be launched in select pilot markets—Greece, Serbia and Poland—and will provide all-in-one solutions for running a dental practice.

Alyson Buchenau, Business Development and Marketing Manager at DTI, thanked those in attendance and emphasised the importance of cooperation. "The DTI network currently reaches 785,000 dental professionals worldwide via our print and digital portfolio," she said. "If we work together, our audience will continue to grow." - *Dental Tribune International*

New study shows cancer-linked genetic changes in electronic cigarette users

LOS ANGELES, U.S. - Despite their thriving market, electronic cigarettes may not be a harmless alternative to smoking after all. A recent study has shown that e-cigarette users develop some of the same cancer-related molecular changes in their oral tissue as cigarette smokers, adding to growing public health concern.

In the study, researchers at the University of Southern California (USC) analyzed gene expression in the oral epithelial cells of 42 e-cigarette users, 24 cigarette smokers and 27 nonsmokers to test for gene alteration, as certain alterations in gene expression can lead to cancer. Both smokers and vapers displayed abnormal expression, or deregulation, in a large number of genes linked to cancer development. About 26 percent of the deregulated genes in e-cigarette users were identical to those found in smokers. Some deregulated genes found in e-cigarette users, but not in smokers, are associated with lung cancer, esophageal cancer, bladder cancer, ovarian cancer and leukemia.

"The existing data show that e-cig vapor is not merely 'water



A recent study has suggested that molecular changes seen in e-cigarette users may serve as an early warning of a process that may eventually lead to cancer. (Photograph: Andrey_Popov/Shutterstock)

vapor' as some people believe," said senior author Dr. Ahmad Besaratinia, Associate Professor of Research Preventive Medicine at the Keck School of Medicine of USC. "Although the concentrations of most carcinogenic compounds in e-cig products are much lower than those in cigarette smoke, there is no safe level of exposure to carcinogens."

Besaratinia noted that the molecular changes seen in the study are not cancer, or even pre-cancer, but rather an early warning of a process that could potentially lead to cancer if left untreated. The scientists are planning to replicate the study with a larger group of subjects

and explore the mechanisms that cause gene deregulation. They are also launching another study in which smokers will switch to e-cigarettes to see whether any changes occur in gene regulation after the switch. "For the most part, the participants are as curious as we are to know whether these products are safe," said Besaratinia.

The study, titled "Deregulation of biologically significant genes and associated molecular pathways in the oral epithelium of electronic cigarette users," was published online in the first February 2019 issue of the International Journal of Molecular Sciences. - *Dental Tribune International*

Dental, medical and nursing students work together in new study

NEW YORK, U.S. - With dental caries being the most common chronic childhood disease, it is imperative that health care professionals across all sectors work closely together. In a new study, led by the New York University (NYU) Rory Meyers College of Nursing, dental, medical and nursing students worked together in order to help improve interprofessional skills and collaboration between primary care and dental providers.



In a recent study, dental, medical and nursing students worked together to help test the success of interprofessional collaboration in child oral health. (Photograph: Andrey_Popov/Shutterstock)

"Collaborative, workplace-ready students are valuable assets to any clinical team. Our goal is for team-based, whole person care to become the norm for promoting children's oral health and preventing cavities," said Dr. Erin Hartnett, Program Director of Oral Health Nursing Education and Practice (OHNEP) at NYU Meyers and the study's lead author.

As part of the interprofessional experience, family nurse practitioner, medical and dental students worked as a team to assess patients. Together, they reviewed patients' charts, looked at patients' medical and dental

Continued on Page 15