

roots

international magazine of
endodontics

study

Cyclic fatigue resistance of several
glide path rotary and reciprocating files

technique

Improved endodontic efficiency
with Er:YAG AutoSWEEPS modality

practice management

Slow down everyone—
dentistry does not need to be done at speed



Fotona[®]
choose perfection



The Power of **ASP**

SWEEPS[®] Photoacoustic Endodontics

Looking for a more effective endodontic treatment?

- Shock Wave Enhanced Emission Photoacoustic Streaming
- Improved debridement and disinfection
- Minimally invasive
- Faster, safer and more effective
- More patient friendly

Visit www.fotona.com to find out more!

Available with  LightWalker[®] and SkyPulse[®]

For related patents see: www.fotona.com/patents

Magda Wojtkiewicz

Managing Editor



Modern endodontics: What is next?

In the field of endodontics, as in many other fields of dentistry, developments in science and research have enabled dental professionals to succeed in diagnosis, treatment planning and treatment. The future of dentistry and endodontics is facing a change curve. Change is the only constant in the future, and those who adapt well and embrace innovation can succeed. Technological advancements make complex procedures easier and more successful, but demand new approaches and changes in the perception of root canal therapy.

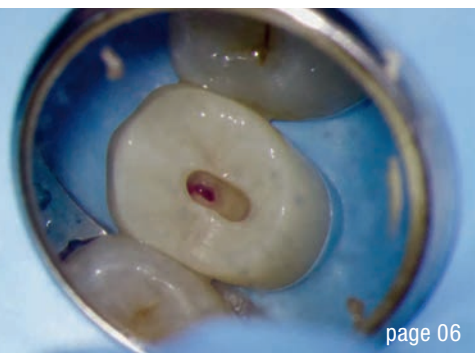
Endodontics has experienced major changes. Firstly, the rapid spread of information and technology has transformed endodontics forever in the best possible way. Such a transformation has made endodontic procedures safer, easier and more predictable and thus less stressful for the patient and dentist. Secondly, endodontics has been incorporated into an interdisciplinary approach to dentistry. As endodontic treatment has become more predictable, more dental professionals have taken it into consideration in preparing complex treatment plans. Thirdly, increased longevity means that patients want to keep their own teeth for as long as possible, enjoy good health and have quality of life. Fourthly, the success rate and predictability of end-

odontic treatment have made it serious competition for implant treatment.

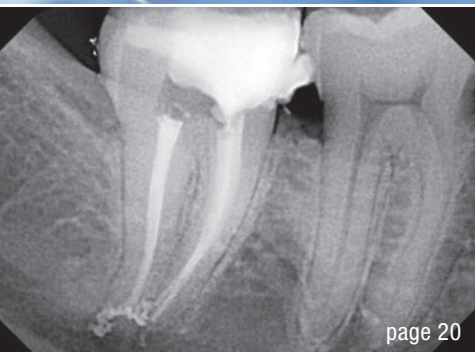These changes have started a new era in endodontics, one in which root canal therapy is no longer regarded as a risky procedure with unpredictable results. New, innovative root canal therapy methods have now replaced conventional procedures, being safer and giving long-lasting results. Cone beam computed tomography, nickel–titanium files, apex locators, irrigation and microscopes are only some new technologies which have changed completely the way dentists perform root canal therapy.

The complexity of root canal systems is still a challenge for the newer and more advanced technologies to solve. The rapid developments in science and technology promise a bright future for root canal therapy. Advancements in 3D printing, microscopic equipment and sonic frequencies can benefit root canal procedures immensely.

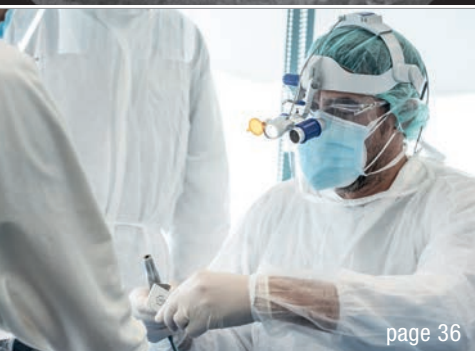Magda Wojtkiewicz
Managing Editor



page 06



page 20



page 36

Cover image courtesy of FKG (www.fkg.ch).



editorial

Modern endodontics: What is next? 03
Magda Wojtkiewicz

trends & applications

Armamentarium for dentine conservation during endo treatment 06
Drs Bobby Nadeau, Viraj Vora & Dale Jung

case report

Endodontic treatment of maxillary left first molar with **complicated root canal system** 18
Dr Paulina Piasta-Kielkiewicz

Driving on autopilot 20
Dr Richard J. Gray

Autogenous transplantation followed by conservative root canal therapy: Three years follow-up 26
Dr Jenner Argueta

technique

Improved endodontic efficiency with Er:YAG AutoSWEEPS modality 22
Dr Tomaz Ivanusic

study

Cyclic fatigue resistance of several nickel–titanium **glide path rotary and reciprocating files** 30
Dr Sławomir Gabryś

practice management

Slow down everyone—dentistry does not need to be done at speed 36
Dr Miguel Stanley

feature

Dental fitness: The future concept of sustainable dentistry 40
Prof. Ivo Krejci

interview

Environmental sustainability in endodontics 42
Monique Mehler

news


COVID-19 and dental education: Will dental schools admit new students in 2021? 44
Iveta Ramonaite

manufacturer news 46

about the publisher

submission guidelines 48

international imprint 50



Reciproc family

Take the one
that fits best



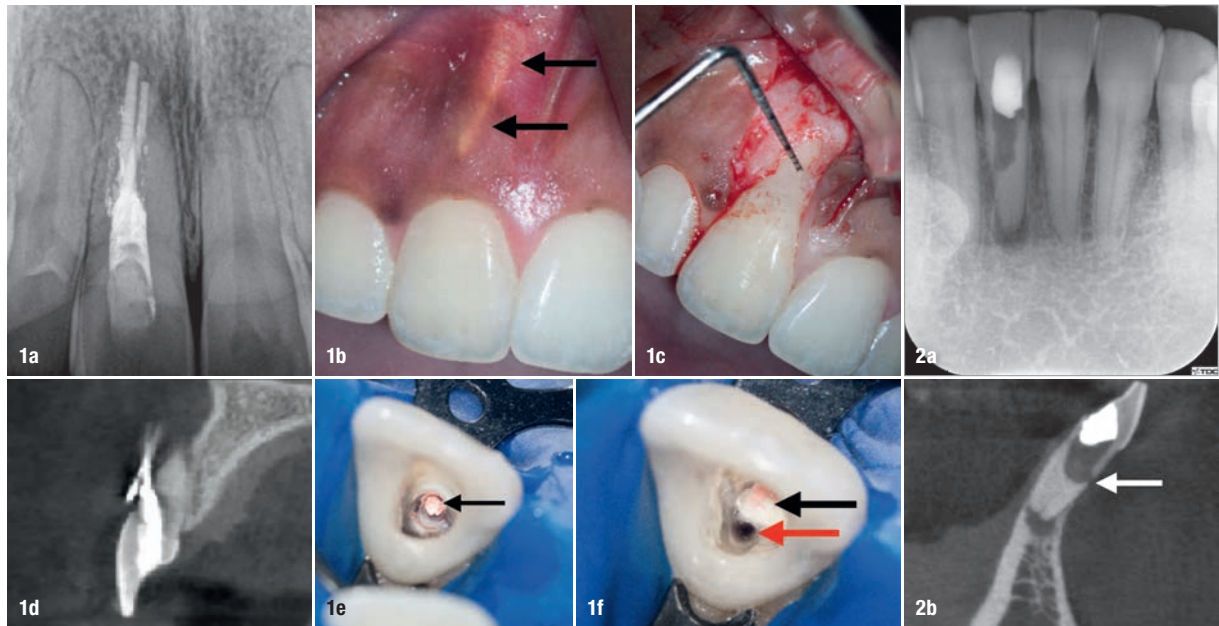
The universal and flexible instrument
for the majority of cases.



The instrument particularly efficient
for retreatments.

Armamentarium for dentine conservation during endo treatment

Drs Bobby Nadeau, Viraj Vora & Dale Jung, Canada & USA



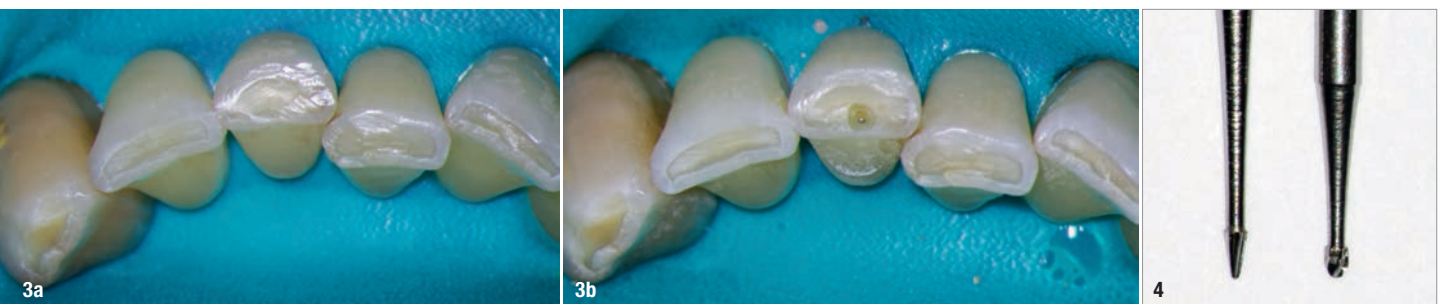Figs. 1a–f: Cingulum access using round burs promotes facial gouging and perforation (a). Gutta-percha showing under soft tissue (b). Perforation confirmed clinically (c). Pre-op sagittal slice showing facial perforation. Facial perforation (black arrow; e). True canal (red arrow; f). **Figs. 2a & b:** Cingulum access using round burs promotes violation of the peri-cervical dentine, an inverse funnel effect and perforation (white arrow).

Introduction

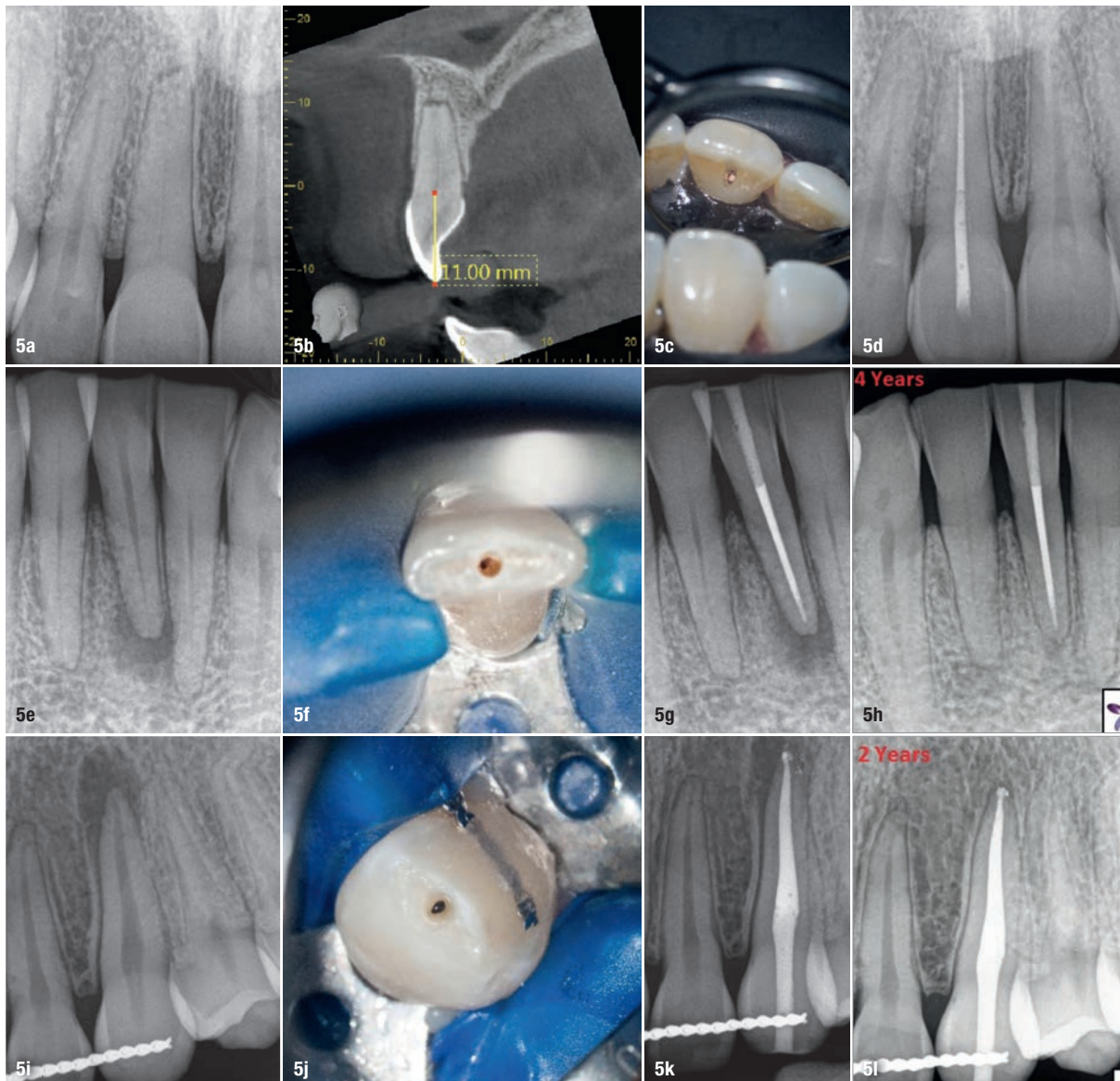
“Primum non nocere” [first do no harm]—Hippocrates

In today’s society, as life expectancy increases, patients expect their teeth to last a lifetime, healthy dentition being important for a good quality of life.^{1–4} Endodontic therapy is usually the last resort for retaining natural teeth, and teeth requiring root canal therapy are often structurally compro-

mised owing to caries and cracks. Minimally invasive surgical techniques have been utilised in medicine for many years;⁵ however, their adoption in dentistry has been much slower. As newer technologies emerge and develop, minimally invasive approaches have become possible today in endodontics while still adhering to biological principles of treatment. As clinicians, in order to provide a high quality of care, we all want to know what the best currently available evidence is.



Figs. 3a & b: In cases with attrition, the access is created in the middle of the incisal edge. Dental dam isolation that includes some adjacent teeth can help the clinician to visualise the angulation of the root to be treated. (Case treated by Dr Bobby Nadeau) **Fig. 4:** Conical carbide burs such as the EndoGuide bur (SS White Dental; left) have a tip less than half that of the corresponding round bur (right).



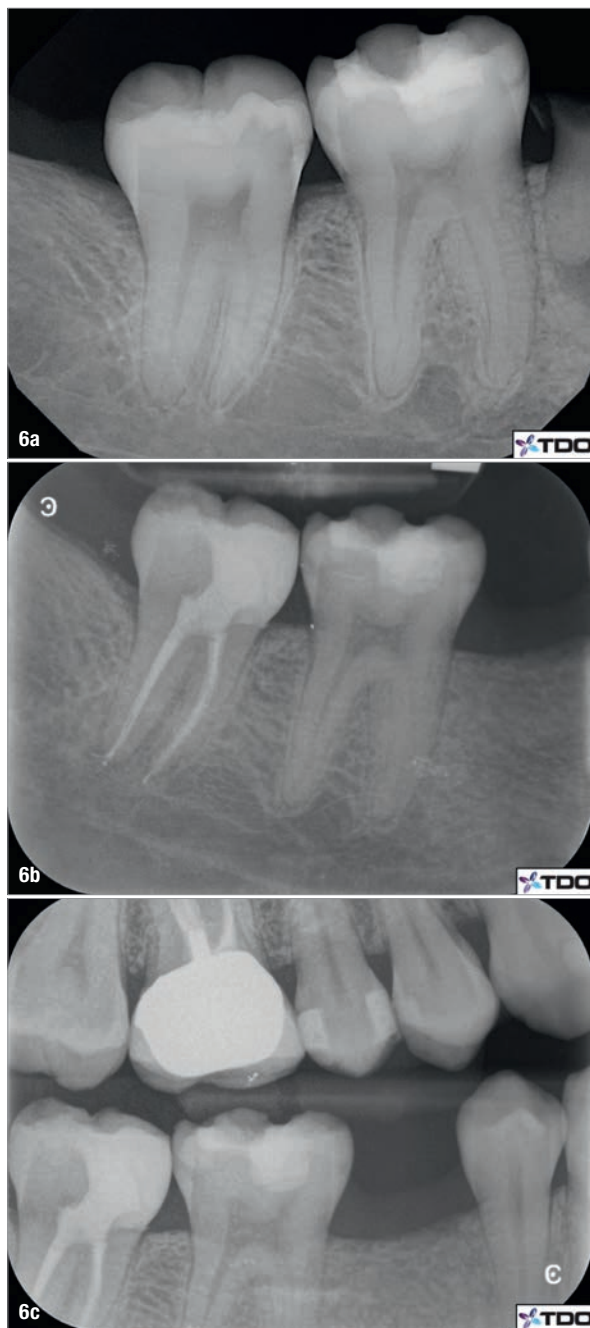
Figs. 5a–l: Incisal access allows for maximum peri-cervical dentine preservation. CBCT can be used for access cavity planning in calcified cases (a–d). All cases are immediately restored at the time of obturation. Four-year (e–h) and two-year (i–l) follow-ups showing complete radiographic healing. Both teeth were asymptomatic and functional. (Cases treated by Dr Viraj Vora)

The quality of the evidence for the long-term effectiveness of the mechanical objectives of endodontic therapy is weak, and thus treatment protocols are highly variable among clinicians and often the treatment approaches that are the most expedient prevail. Traditional objectives have been focused on maximising the visual field of access cavity preparation and preparing canals to certain dimensions to facilitate a certain appearance of the radiographic obturation, which is used as a proxy for cleanliness of the canal systems.^{6,7} The long-term survival of endodontically treated teeth (ETT) has been investigated through epidemiology.^{8–16} These studies suggest that maintaining dentine and achieving appropriate restorative management during endodontic procedures are two of the most critical factors for tooth survival and longevity, which is really what our patients desire. Minimally invasive endodontics stem from the restorative

requirements for ETT to survive in the long term. Some approaches to achieving adequate immediate restoration of ETT were described in our previous article.¹⁷ The current article discusses the armamentarium available to the clinician to maintain residual dentinal structure during endodontic therapy without compromising root canal disinfection and obturation. The two main opportunities for maintaining dentinal structure present to the clinician during access cavity preparation and root canal instrumentation.

Armamentarium for conservative access cavity preparation

Access cavity preparation is defined as the removal of a coronal portion of the pulp complex to facilitate canal location and debridement.¹⁸ Despite the lack of compelling clinical



Figs. 6a–c: Example of caries-leveraged access design (a). The tooth was immediately restored at the time of obturation (b & c). (Case treated by Dr Dale Jung)

evidence, a set of rules for endodontic access, established at a time when the endodontic armamentarium had significant limitations, continue to be promoted today to achieve endodontic success while decreasing procedural time and difficulty. These rules include complete unroofing of the pulp chamber and complete visualisation of the pulp chamber floor, wall-to-floor junctions and canal orifices with one view.¹⁸ This concept of straight-line access was meant to provide the clinician with convenience, at a time when high magnification and illumination, flexible heat-treated nickel-titanium (NiTi) instruments and cone beam computed tomography (CBCT) were not available. With the advent of

these new technologies, instead of prescribing a one-size-fits-all access cavity design, it is now possible to customise the access based on the tooth's particular presentation, in order to maintain as much healthy dentine as possible and achieve the best possible outcome for our patients.

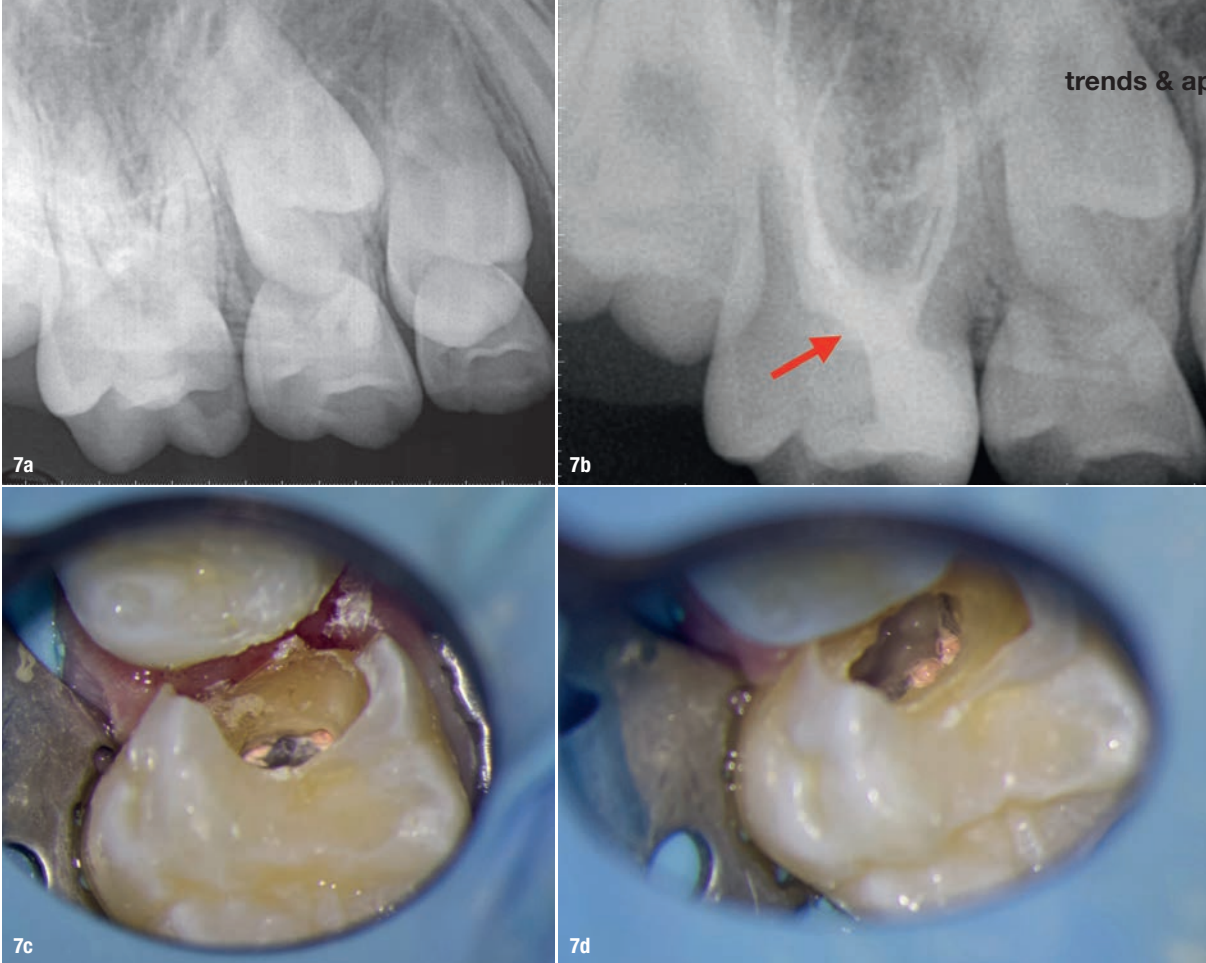
Access cavity design in anterior teeth

Traditional access cavity design in anterior teeth involved entry on the lingual or palatal surface using a round bur, through the cingulum (cingulum access), complete lingual shoulder removal and full pulp horn unroofing, leading to a triangular access outline form.⁷ This approach was chosen to favour the aesthetic demand; however, unnecessary internal dentine removal, facial gouging, perforation and weakening of the tooth at a critical location (peri-cervical dentine) often occurs (Figs. 1a–f & 2a & b).¹⁹ As mentioned in our previous article, peri-cervical dentine (PCD) is the dentine located 4 mm coronal and 6 mm apical to crestal bone. It has been proposed that PCD plays a crucial role in transferring occlusal forces along the root and that maintaining intact PCD is arguably the single most important factor in achieving long-term retention of ETT.²⁰ Cingulum access, owing to the initial orientation of the bur angulated towards the facial surface of the tooth, can also increase the risk of facial perforation. Two previously published articles in the endodontic literature suggesting a more incisal approach for anterior endodontic access have recently been revisited.^{21,22} The new model for anterior access involves moving the entry point away from the cingulum and towards the incisal edge.¹⁹ This allows for the preservation of PCD, the least amount of dentine removal, the straightest path to both the facial and lingual/palatal canals, and better canal debridement compared with cingulum access.²¹ In cases in which there is attrition, the access is initiated in the middle of the incisal edge (Figs. 3a & b). Bur selection is also critical for anterior access. Round burs, which have traditionally been recommended for endodontic access, are contra-indicated. The inherent shape of a round bur creates an inverse funnel, in that the size of the access cavity becomes wider as the bur progresses deeper (Figs. 2a & b).²³ Using a bur that minimises gouging and maintains the narrowest part of the access cavity preparation near the PCD is recommended (Fig. 4).¹⁹ This approach maintains as much PCD as possible as the PCD is an area under severe tensile forces when the anterior tooth is in function (Figs. 5a–l).²⁴ Additionally, data from a CBCT scan, if indicated, can help the clinician visualise the coronal projection of the canal and plan the exact entry point in order to achieve straight-line access (Figs. 5a–l). Dental dam isolation that includes some adjacent teeth can help the clinician to visualise the angulation of the roots (Figs. 3a & b).

Access cavity designs in posterior teeth

Restorative- and caries-leveraged access

Tooth structures of no value, as described by Clark and Khademi, include tertiary dentine, undermined enamel,



Figs. 7a–d: Caries-directed mesialised access (a). The soffit was preserved for added strength (red arrow; b). Straight-line access to the two mesiobuccal orifices (c) and two distobuccal orifices (d) was achieved. The tooth was immediately restored at the time of obturation. (Case treated by Dr Bobby Nadeau)

caries and restorations.²³ These areas should therefore be leveraged during access cavity preparation (Figs. 6a–c). The premise of classic endodontic access is to gain straight-line access into the root canal systems usually through all coronal structures or dental materials, whereas carefully removing materials of no value (leveraging) allows for better visualisation and greater volume of residual dentine, which is the foundation for fracture resistance and long-term retention of ETT.^{25,26}

Leveraged access designs often lead to the preservation of the soffit. The soffit consists of undermined dentine at the level of the pulp chamber roof, and this is thought to provide additional strength (Figs. 7a–d).²⁰ Advancements in dental materials include modern flexible martensitic heat-treated NiTi rotary files with regressive taper that can be prebent (Fig. 8), high magnification and illumination, and smaller burs allowing access to canal orifices even in the absence of true straight-line access. Data from 2D and 3D (CBCT) radiography can also be utilised to approximate the depth of the pulp chamber and design the access cavity. Figures 7a–d and 9a–j are examples of caries-/restorative-leveraged mesialised/distalised access designs. Buccally and lingually located structures that can be leveraged can also dictate the access entry point (Figs. 10a–f & 11a–f).

Stepped access

The stepped access cavity design can be used in both anterior and posterior teeth. It is the design of choice for most access cavities through indirect restorations like crowns

and onlays. It involves cutting a larger outline in restorative materials down to the level at which dentine is encountered (Figs. 12a–e & 13a–d).²³ The clinician can then assess the location and angulation of the entry point to the pulp chamber based on its anticipated location and dentine colour map. The stepped access can also leverage direct restorative materials, leading to an unobstructed path to dentine, which facilitates conservative access to the pulp chamber (Figs. 14a–f & 15a–f).



Fig. 8: Modern flexible martensitic heat-treated NiTi rotary files can be prebent for easier insertion in contracted access cavities and for predictable root canal negotiation. The DC Taper rotary file system (SS White Dental) is an example of rotary files with regressive taper.