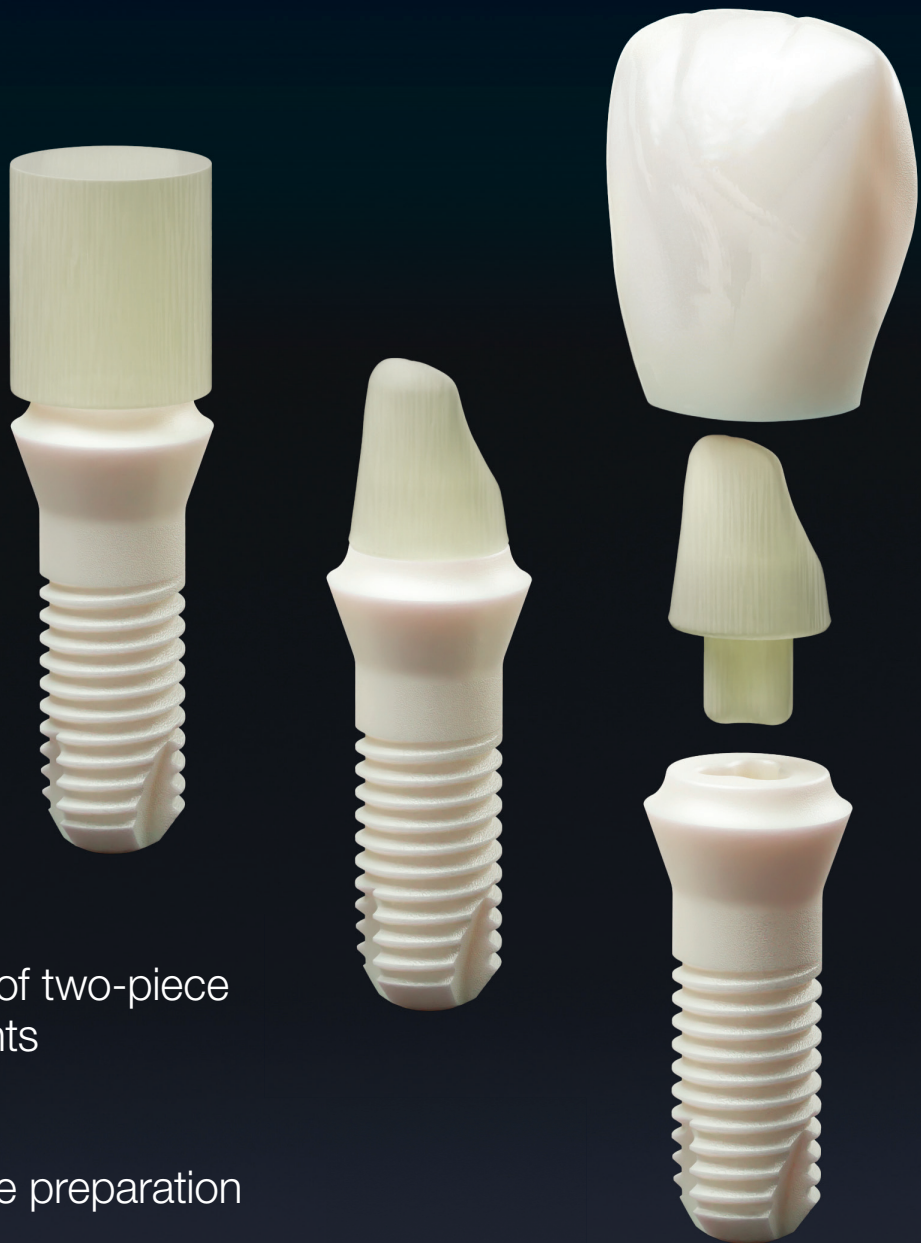

# ceramic implants

international magazine of ceramic implant technology



## research

Clinical success rate of two-piece zirconia dental implants

## case report

Magneto-dynamic site preparation for zirconia implants

## news

First long-term study on two-piece zirconia implants published



# Ceramic Implant System

A new mindset



## A new esthetic mindset

Outstanding esthetic performance, comprehensive portfolio and natural esthetic result.



## A new flexibility mindset

Flexibility of a 2-pieces connection combined with a strong screw-retained ceramic-ceramic connection.



## A new stability mindset

Zi combines a naturally tapered implant design and implant treated surface.



Download the **Clinical Casebook** to check out how reliable and stable is the **Zi Ceramic Implant System**.  
[neodent.com/zicases-pr](https://neodent.com/zicases-pr)



## Celebrating is a choice

Neodent® is celebrating its 30<sup>th</sup> anniversary!  
Over time, millions of smiles have been created in  
partnership with professionals worldwide.

30 years



# Titanium versus zirconia? Osteo-immunology in implantology

Titanium and zirconia are the two primary materials used in dental implantology. While both materials have been used successfully for many years, there is still a debate about which one is better. Titanium has been the traditional choice for dental implant surgery for over 40 years. However, there are some concerns with the use of titanium implants. One growing concern is that dissolved titanium particles induce inflammatory reactions not only in the superficial margin but also around the bony bed of the titanium implant. Specifically, the inflammatory cytokine tumour necrosis factor-alpha (TNF- $\beta$ ) is expressed in the adjacent bone. The transition from TNF- $\beta$ -induced local inflammation after placement of titanium implants to a chronic stage of "silent inflammation", that is, low-grade chronic inflammation, could be a cause of apparently unexplained medical conditions, and this neglected area of consideration is investigated in osteo-immunology. Osteo-immunology, however, is an emerging field, but has already provided valuable insight into the mechanisms of bone growth, development and regeneration, as well as the role of the immune system in these processes. In the context of implantology, osteo-immunology is important because the success of dental implants depends on the ability of the implant to integrate with the surrounding bone tissue. When a foreign material such as a dental implant is introduced into the body, the immune system reacts to it. This immune response can be beneficial, as it can help to promote the integration of the implant with the surrounding bone tissue. However, if the immune response is too strong, it can lead to chronic inflammation and potentially contribute to implant failure. By understanding the interactions between the immune system and bone tissue, researchers can develop better implant materials and techniques that minimise the risk of inflammatory responses and improve the long-term success of dental implants.

Multiple studies have proved that zirconia implants induce little to no peri-implant tissue inflammation and allow for high levels of epithelial attachment. Thus, in recent years, these ceramic implants have gained significant traction as a viable alternative to traditional titanium implants. They offer numerous advantages, including superior biocompatibility, enhanced aesthetics and excellent mechanical properties.

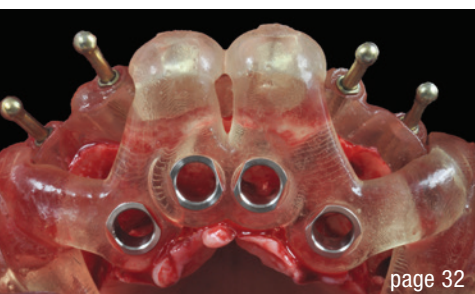
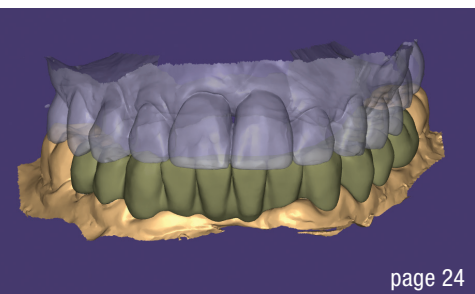
In conclusion, the choice between titanium and zirconia implants ultimately depends on the individual patient. While titanium implants have been the traditional choice, zirconia implants are becoming increasingly popular.

Yours,  
Dr Johann Lechner



**Dr Johann Lechner, Germany**  
Integrative Oral Medicine and Osteoimmunology  
Founder of the International College of Maxillo-mandibular Osteoimmunology





Cover image courtesy of Zircon Medical Management/Patent™ [www.mypatent.com](http://www.mypatent.com)



**editorial**

Titanium versus zirconia? Osteoimmunology in implantology 03  
Dr Johann Lechner

**research**

Clinical success rate of two-piece zirconia dental implants 06  
Dr Joseph Sarkissian & Minehli Kamarzar

**case report**

Immediately placed two-piece zirconia implant with customised healing abutment in the maxillary molar region 12  
Dr Alexandre Marques Paes da Silva

Magneto-dynamic site preparation for zirconia implants: A dry, cold and minimally invasive protocol 18  
Dr Franco Giancola

Modern workflow of immediate zirconia implant surgery utilising dynamic navigation: case studies and benefit analysis 24  
Dr Daniel Madden

Looking for a ceramic solution 30  
Dr Olivier Chéron

Full-arch maxillary rehabilitation using Y-TZP protheses on ceramic implants 32  
Dr Rodrigo Gomes Beltrao

**interview**

Discover the latest in ceramic implantology at the EACim's 2023 congress in France 38  
An interview with Dr Fabrice Baudot

**events**

5<sup>th</sup> Group & Experts Meeting at IDS 2023 42

Zeramex congress in Zurich: Exciting insights into metal-free implantology 44

**news**

manufacturer news 46

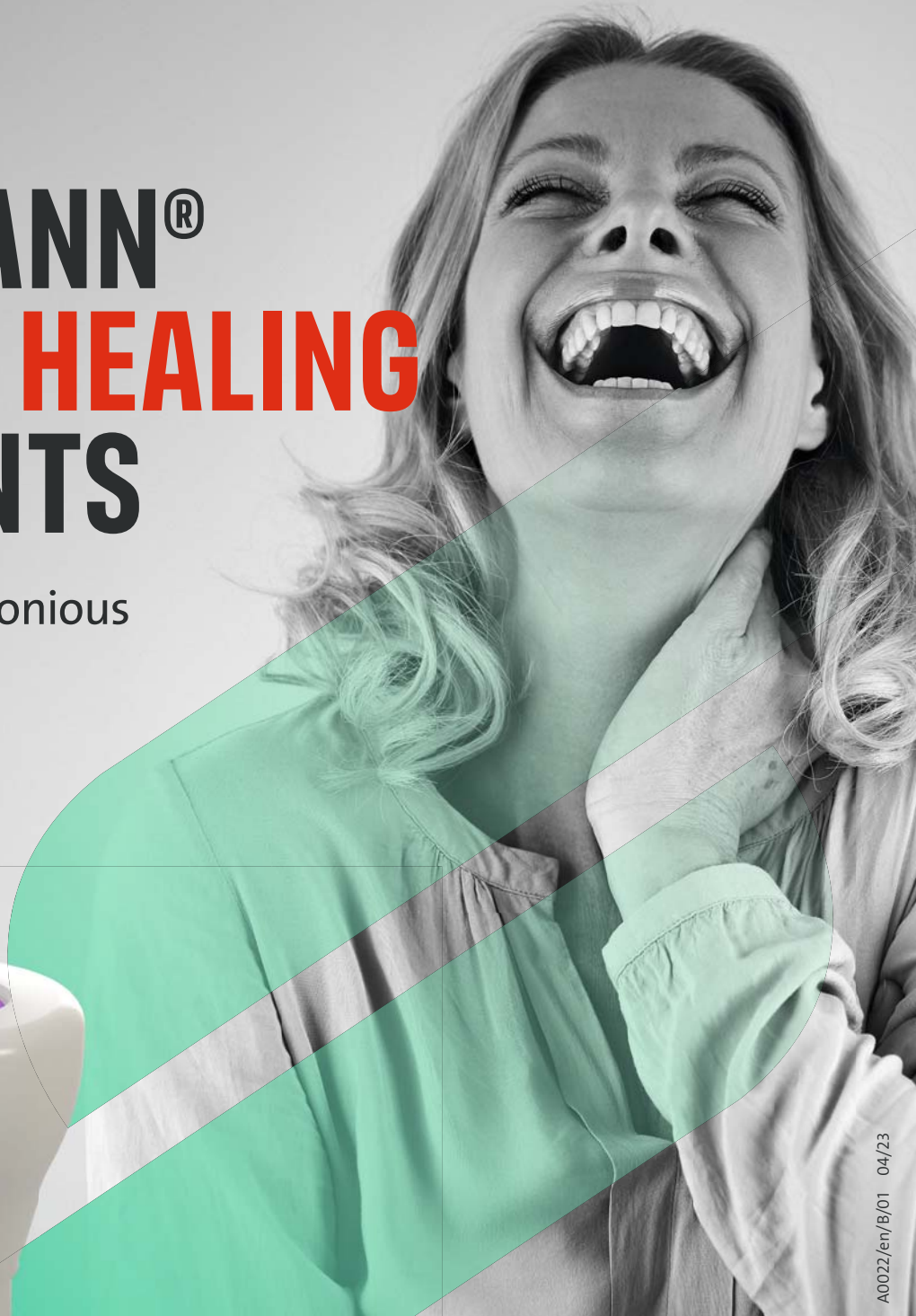news 48

**about the publisher**

imprint 50

# STRAUMANN® CERAMIC HEALING ABUTMENTS

The first step to harmonious  
soft-tissue healing.



## ESTHETICS FROM THE DAY OF SURGERY

Ceramic for healing phase and final restoration.



## EASE OF USE

Aspiration-security and color-coding.



## FAVORABLE SOFT-TISSUE ATTACHMENT

With blood circulation similar to that around natural tooth.<sup>1,2\*</sup>



## DESIGNED FOR HEALTHY PERI-IMPLANT ENVIRONMENT

Less plaque attachment.<sup>2,3,8-9\*</sup>

\* references on [www.straumann.com/ceramic-healing-abutments](http://www.straumann.com/ceramic-healing-abutments)

→ Contact your local Straumann representative or visit:  
[www.straumann.com/ceramic-healing-abutments](http://www.straumann.com/ceramic-healing-abutments)

# Clinical success rate of two-piece zirconia dental implants

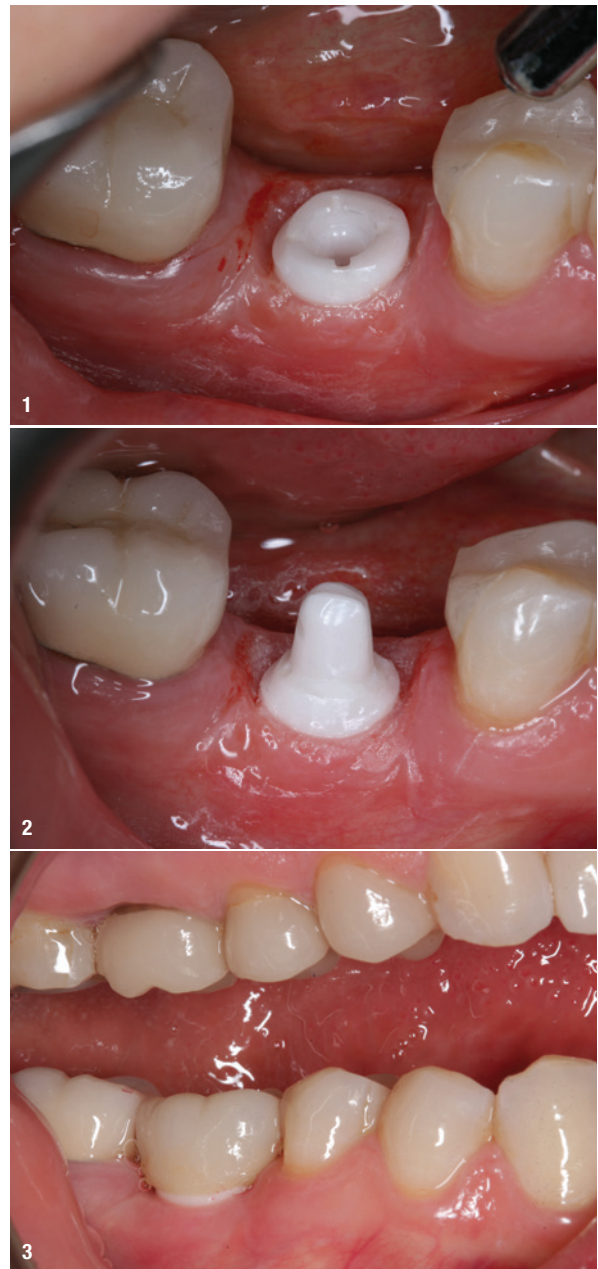
Dr Joseph Sarkissian & Minehli Kamarzar, USA

With the recent development of mechanically improved and clinically versatile zirconia implants, their clinical use over the past several years has become more widespread globally. Although zirconia implants currently represent a niche market, their popularity worldwide is growing rapidly.<sup>1</sup> Studies show that zirconia implants offer many advantages over metal implants, including aesthetics, greatly reduced plaque retention and incidence of peri-implantitis, lower accumulation of surface biofilm compared with titanium implants, outstanding biocompatibility, and a degree of osseointegration and soft-tissue response that is superior to that of titanium dental implants.<sup>2-5</sup> Owing to the white colour of zirconia implants, they do not exhibit the unsightly metallic grey shadowing under the gingival tissue as do titanium implants. This fact alone imparts a significant aesthetic advantage of zirconia over metals as a material choice for dental implants. Zirconia has a very high hardness scale, is a strong insulator, is not electrogalvanic and does not corrode. Overall, zirconia implants provide an excellent aesthetic and biocompatible alternative not only for today's health-conscious patients but for mainstream dentistry as well.

This article reports on a study involving only one of the many zirconia dental implant models offered by Z-Systems. Specifically, the clinical performance of all Z5c implants placed in our dental practice between January 2016 and July 2022 will be presented.

The Z5c is a two-piece implant system which has an implant with a flared platform intended to be at tissue level and an abutment which is cemented into an internal access hole in the middle of the platform. The proprietary Zirkolith process and SLM (Surface Laser Modified) technology used in the production of all Z-Systems' implants were introduced in 2009.<sup>6</sup>

All Z5 implants are made from TZP-A Bio-HIP. The hot isostatic pressing (HIP) process results in a material which has a far greater flexural strength than titanium.<sup>7</sup> The laser modification of the surface increases the surface area, facilitating excellent osseointegration and tissue response. The tissue-level design of the implants allows for preparation of both the abutment and the



**Fig. 1:** Z5c implant after the four- to six-month healing period and preparation and exposure of the implant margins with the Waterlase prior to cementing the abutment. **Fig. 2:** Abutment cemented and prepared prior to scanning. **Fig. 3:** IPS e.max CAD crown milled with CEREC and cemented on the same day.

# The only scientifically proven two-piece zirconia implant system

First long-term study offers  
groundbreaking results\*

## Only we can make it

The patented production process, in which all surface-machining steps are carried out before sintering, creates two unique product features:

- **No process-induced micro-cracks**
- **Ideal surface topography for hard- and soft-tissue adaptation**

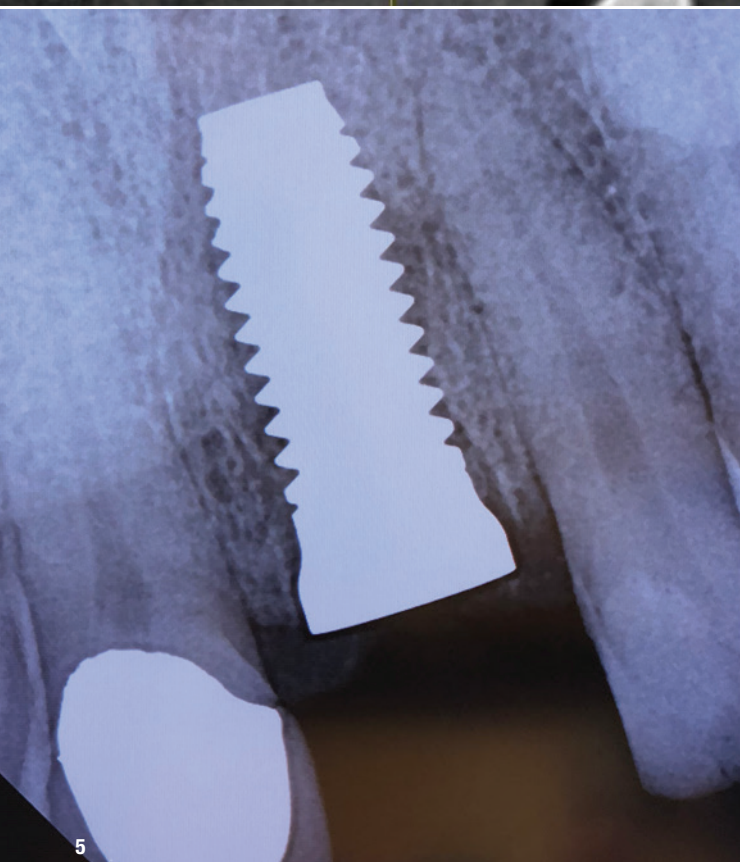
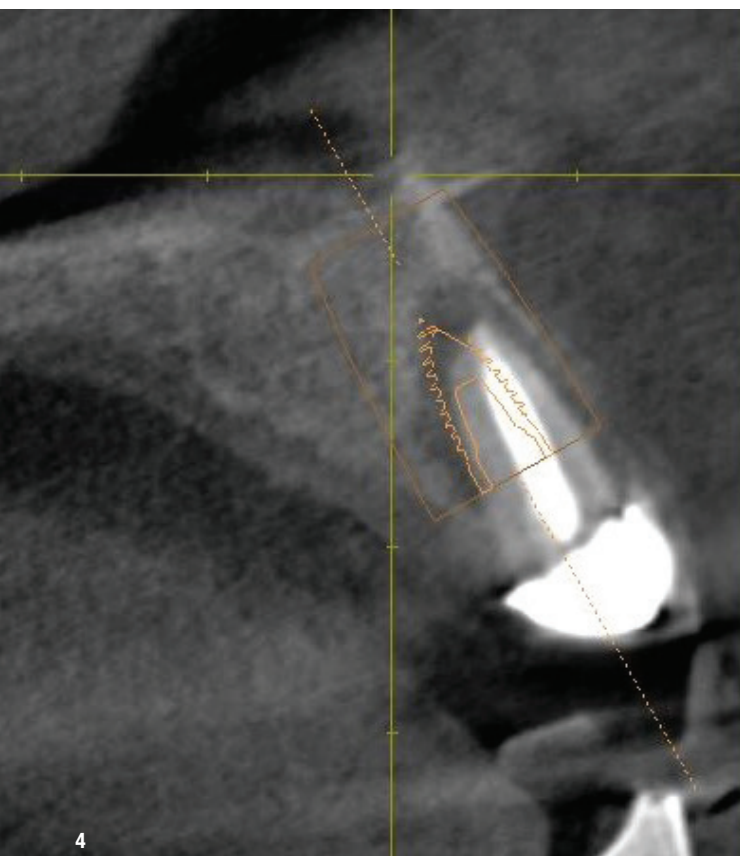


\*Brunello G, Rauch N, Becker K, Hakimi AR, Schwarz F, Becker J. Two-piece zirconia implants in the posterior mandible and maxilla: A cohort study with a follow-up period of 9 years. Clin Oral Implants Res. 2022 Dec;33(12):1233-1244. doi: 10.1111/clr.14005. Epub 2022 Oct 31. PMID: 36184914.



## The New Standard

Long-term oral health: Patent™ has redefined implant success in the latest long-term studies. Learn more at: [www.mypatent.com/scientific-studies](http://www.mypatent.com/scientific-studies)



**Fig. 4:** Failing endodontically treated maxillary incisor planned for extraction and immediate replacement with a Z5c implant.

**Fig. 5:** Radiograph of the implant after immediate placement.

margins. The most desirable attribute of the tissue-level implant is that it does not interfere with the highly vulnerable biological zone between the alveolar crest and the gingival surface.

## Materials and methods

Of the 110 implant cases, 74 were performed in female patients and 36 in male patients. The final cases included in the study were a cohort of 73 patients, 47 female patients and 26 male patients.

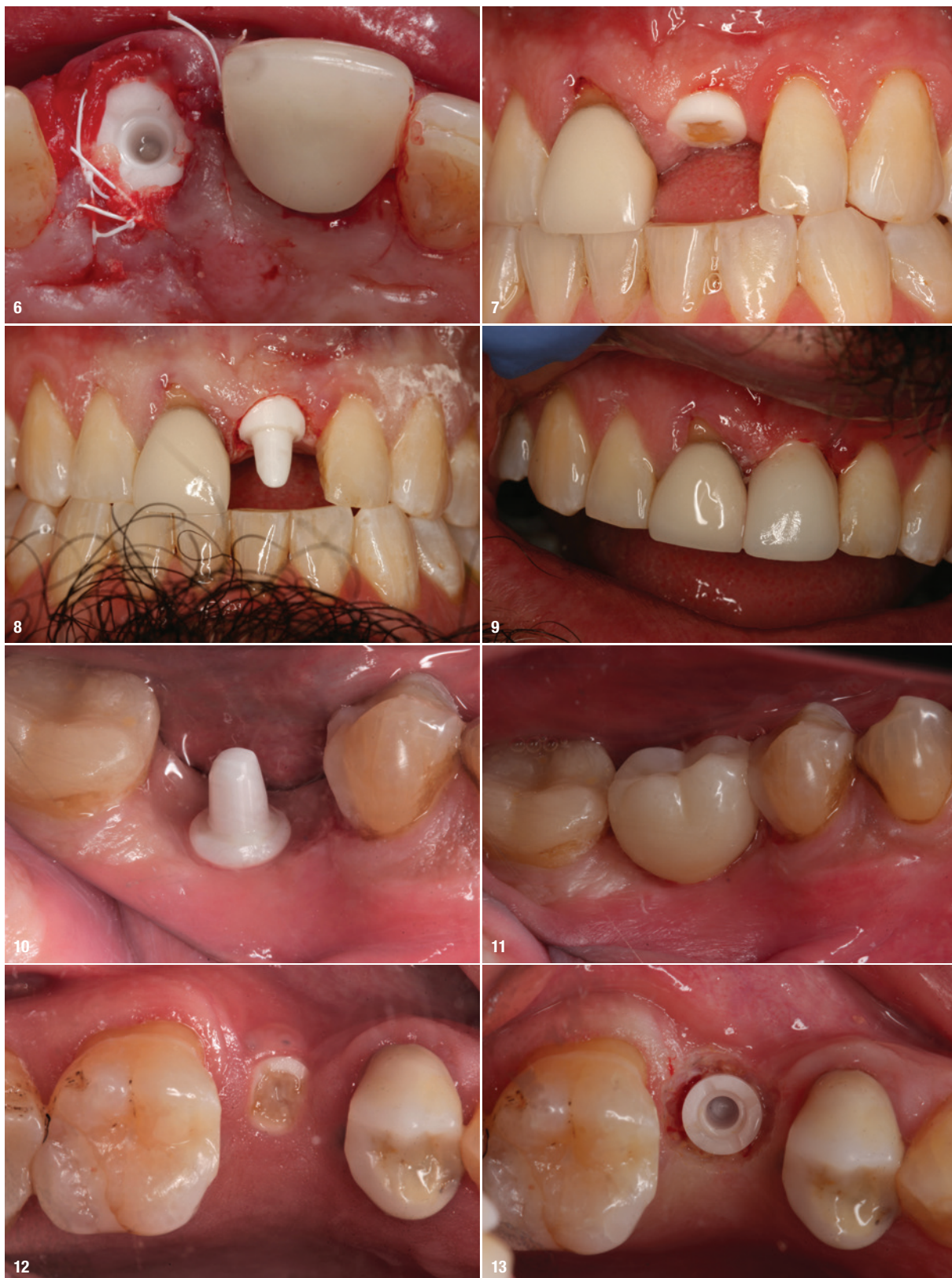All the surgeries followed a semi-guided protocol. A CBCT scan was obtained, and a surgical guide was made using various methods. The surgical guides were intended and designed to be used for the initial osteotomy with a pilot drill to a depth short of 2 mm of the projected depth. In most cases, a flapless or conservative papilla-sparing flap design was used. A radiograph with a guide pin was taken to confirm and modify depth and angulation after the initial osteotomy. Bone threading was performed except in sites of D3 and D4 bone quality. All the implants were placed within 1 mm of the gingival level; however, most were placed either at or slightly below gingival level. Only implants of 4 and 5 mm in diameter and lengths of 8, 10 and 12 mm were used, depending on the osseous anatomy. The placement torque ranged from 25 to 35 Ncm.

All the patients were required to wear a protective Essix appliance 24/7, even while eating, for two months. The Essix appliances were made on a preoperative model with a vacuum forming unit using Essix A+ or PLUS Plastic (Dentsply Sirona) of 1 mm thickness. The implant sites were blocked out to prevent any contact during wear. The healing times ranged from three to six months.

After healing, testing for successful osseointegration was carried out with a torque test at 20 Ncm. After the internal access hole had been thoroughly decontaminated and primed, the abutments were cemented with a dual-polymerising resin cement, such as PANAVIA SA Cement Universal (Kuraray Noritake Dental) or RelyX Unicem (3M). After placement of the abutment, a Periotest reading (Medizintechnik Gulden) was obtained. Fully integrated implants exhibit a Periotest value of between  $-0.5$  and  $-7.0$ , a higher negative number indicating stronger integration.

The abutment and implant shoulder were typically ground and shaped with a fine, red-stripped diamond bur to conform to the contours of the gingiva and create adequate abutment angulation, taper and clearance. The implant margins were prepared and exposed with the Waterlase (BIOLASE) prior to cementing the abutment. The crowns were made in-house on the same day with CEREC technology from either IPS e.max CAD (Ivoclar) or Lava Ultimate materials (3M). Their occlusion was designed with less intensity than on the rest of the dentition. The crowns were cemented with the same dual-polymerising resin cement used for the abutments. The implants were typically followed up every six months during the recall appointments, and Periotest values were taken (Figs. 1–21).





**Fig. 6:** Occlusal view of the implant after immediate placement. **Fig. 7:** Occlusal view of the same implant after five months of healing, ready to be restored. **Fig. 8:** Same implant after laser exposure of the margins, abutment cementation and preparation for a CEREC-milled crown. **Fig. 9:** Same implant after receiving the final crown on the same day. **Fig. 10:** Implant ready to be scanned, demonstrating excellent tissue response after ideal margin exposure and emergence profile creation performed on the same day with the Waterlase. **Fig. 11:** Same implant restored on the same day with a CEREC-milled IPS e.max CAD crown. **Fig. 12:** Implant replacing a maxillary second premolar after four months of healing, demonstrating excellent tissue healing and no foreign-body response. **Fig. 13:** Same implant after laser margin exposure and removal of the abutment access hole seal.