

ceramic implants

international magazine of ceramic implant technology



case report

Digitally customised asymmetrical zirconium dental implant

research

Contaminants on ceramic implants:
Do manufacturing deficits
compromise their value?

interview

Advancing technologies in ceramic
implantology—AI sets new
milestones in dental treatments



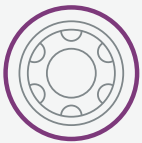Ceramic Implant System

A new mindset



A new esthetic mindset

Outstanding esthetic performance, comprehensive portfolio and natural esthetic result.



A new flexibility mindset

Flexibility of a 2-pieces connection combined with a strong screw-retained ceramic-ceramic connection.



A new stability mindset

Zi combines a naturally tapered implant design and implant treated surface.



Download the **Clinical Casebook** to check out how reliable and stable is the **Zi Ceramic Implant System**.
neodent.com/zi-clinicalcasebook



NEODENT

WORLD TOUR

30

years

The road to celebrating our 30 years is just beginning. Throughout the decades, we continue to create new smiles and change lives in 90 countries. For the next months, 12 countries will receive the Neodent World Tour, celebrating our 30th anniversary. Stay tuned!



Check out the complete schedule, scan the QR code, or visit the website: neodent.com/worldtour

 **NEODENT**[®]
A Straumann Group Brand

Choose your way— but choose with passion

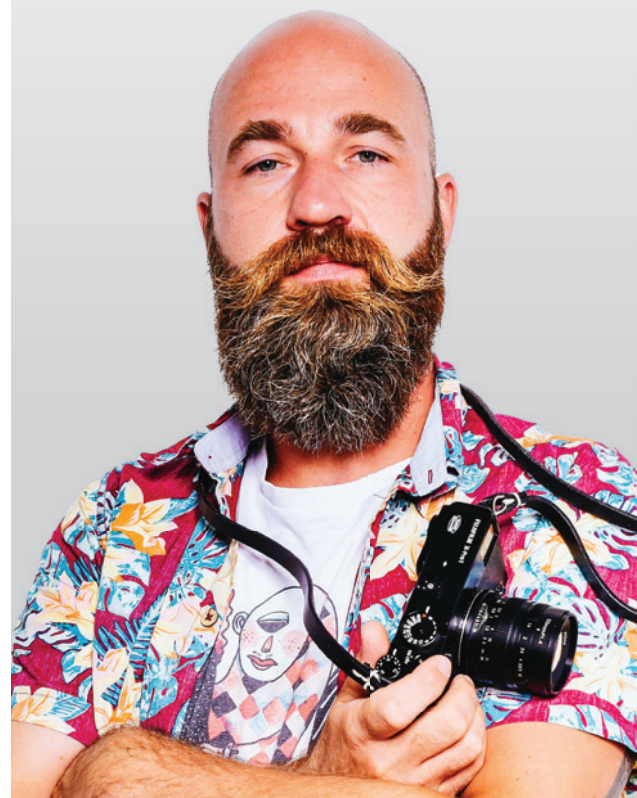These days are full of change—socially, economically, biologically, and ecologically. The world is not the same anymore. What will future bring, what will be left behind? Many questions—who has the answers? Please let these thoughts buzz in the room.

In this issue of *ceramic implants*, I would like to invite you to read the printed content with pleasure and with humility. Please let us all consider ourselves privileged—we got the opportunity to visit school, graduate from university and pursue our professions. Some of you are dedicated to research, others to practice. There is one thing we have in common: we have the same goal—we want to make a difference. We participate in our networks and in our exchanges—in what we read, in what we discuss at conferences.

The last issue of the year is very special to me. It challenged me a lot because I had the beautifully painful task to choose from so many great inputs. This issue no. 3 shares with you the latest case reports with most individualistic approaches, reviews on wonderful conferences, and at the same time looks towards the future—what is possible if we bring together AI and dentistry ...

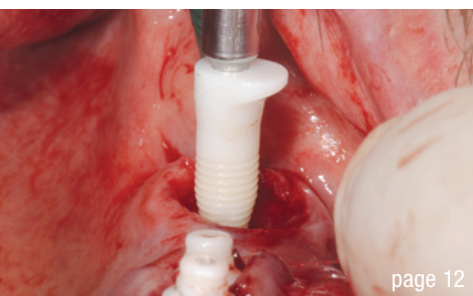
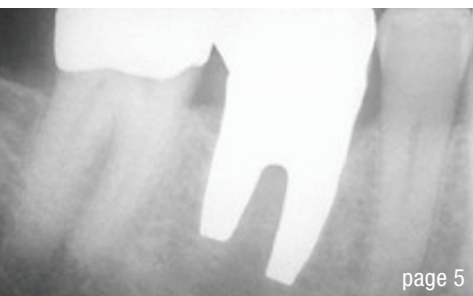
“Share your knowledge. It is a way to achieve immortality.”—with this in mind and with these words from Dalai Lama XIV, I would like to thank all authors and our partners from industry for your constant support. I would like to thank friends for trusting into this wonderful publication.

Sincerely,
Timo Krause



Timo Krause, Germany
Editorial Manager





Cover image courtesy of
SDS Deutschland GmbH
www.swissdentalsolutions.com



editorial

Choose your way—but choose with passion 03
Timo Krause

case report

Digitally customised asymmetrical zirconium dental implant 05
Dr Dumitru Gogarnoiu, Jonathan Korostoff, Rodolfo Gianserra & Melania Gogarnoiu

Full-arch: Full rehabilitation of the upper jaw—Part 1 12
Dr Dr Michael Rak, Norbert Wichnalek, Arbnor Saraci & Lukas Wichnalek

Zirconia implants: New treatment option for the partially edentulous posterior mandible 20
Dr Phongphan Chinnahathaiwat

research

1-piece and 2-piece ceramic dental implants 24
Curd Bollen & Martin Jörgens

Contaminants on ceramic implants: Do manufacturing deficits compromise their value? 30
Ken Serota

First long-term study on two-piece zirconia implants published 32

interview

Advancing technologies in ceramic implantology—AI sets new milestones in dental treatments 34
An Interview with Dr Shepard DeLong

Implant dentistry without peri-implantitis 38
An Interview with Marco Waldner

events

Consensus-based clinical recommendations 40

SUMMARY SEMINAR EACim 2023 42

DIGITAL TRANSFORMATION in CERAMIC IMPLANTOLOGY—the future is now 44

news

events & products 46

about the publisher

imprint 50

Digitally customised asymmetrical zirconium dental implant

Replacement of a mandibular molar—Surgical and prosthetic aspects

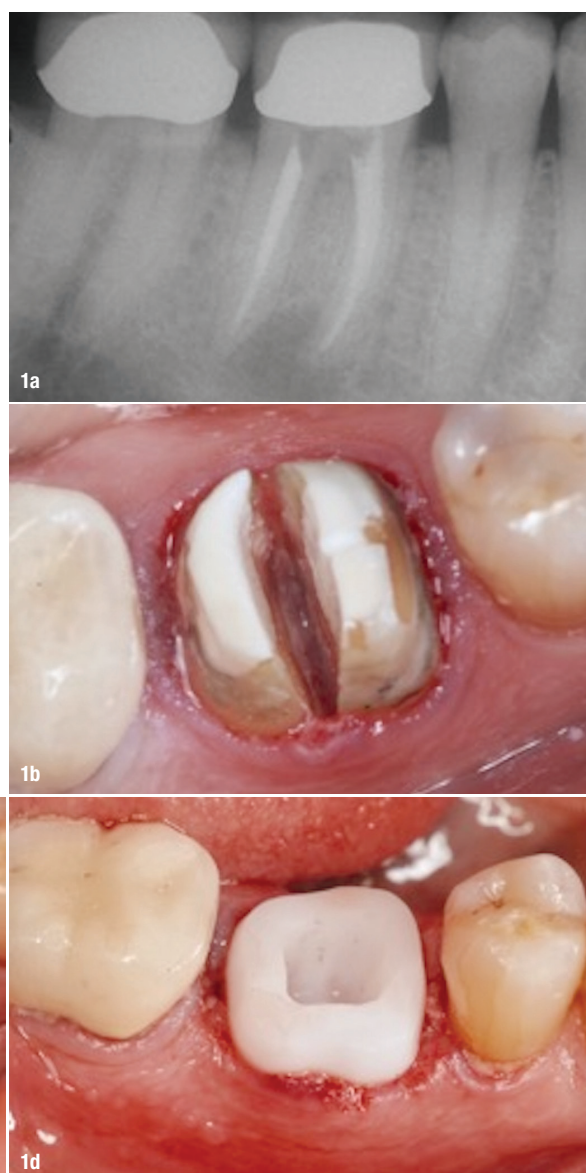
Dr Dumitru Gogarnoiu, Jonathan Korostoff, DMD, PhD, Rodolfo Gianserra & Melania Gogarnoiu, DMD, USA & Italy

Abstract

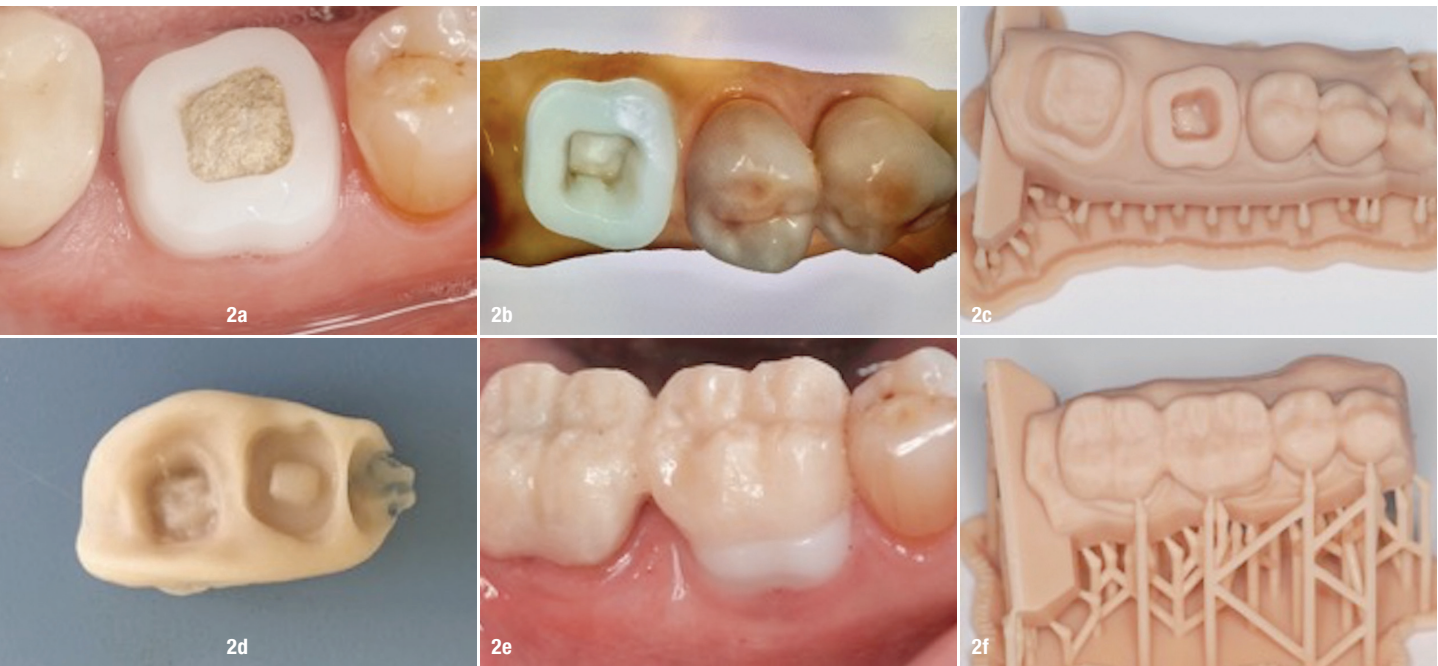
To reduce the overall treatment time required for replacement of a tooth with an implant-supported crown, clinicians will place the fixture immediately after an extraction. Under appropriate circumstances, especially in the anterior aspects of the jaws, this approach yields highly predictable functional and aesthetic results. In the posterior areas of the jaws, the anatomy of roots often compromises the available volume of bone to the extent that it is not possible to achieve primary stability of an immediately placed implant. To circumvent this issue, a customised two-piece implant system was designed in which the shape of the intraosseous component corresponds to the actual anatomy of the extracted tooth. The case report describes the implant and illustrates how it can be immediately placed following extraction of a mandibular molar that had a hopeless prognosis.

Introduction

Although initially intended to support mandibular fixed full-arch restorations by following very rigid surgical and



Figs. 1a–d: Extraction of tooth #30 and placement of customised zirconium implant. Radiograph demonstrating periapical pathology on #30 (a). Hemisection of #30 to facilitate minimally traumatic extraction (b). Extraction socket with intact buccal alveolar bone (c). Zirconium implant in place demonstrating immediate support of adjacent peri-implant soft tissues (d).



Figs. 2a–f: Provisionalisation of the zirconium implant. Healthy peri-implant soft tissues six months after implant placement **(a)**. Scanned digital impression **(b)**. 3D-printed model derived from digital impression **(c)**. Block carving of provisional crown **(d)**. Provisional restoration cemented in place **(e)**. 3D-printed model derived from digital scan of the provisional restoration **(f)**.

prosthetic protocols,¹ implants are now placed via either immediate^{2–4} or delayed approaches and subsequently used to support dentures, crowns and/or bridges (fixed partial dentures) to address partial edentulism in all parts of the mouth. Often, extraction of a molar with the intention of replacing it with an implant-supported crown is achieved via a delayed protocol due involving placement of a bone graft to preserve the morphology of the alveolar ridge.⁵ In other situations, the walls of the socket are not intact, requiring an actual guided bone augmentation procedure to re-establish sufficient volume for implant placement. Both approaches typically yield a flat crestal bone profile that does not restore the normal osseous architecture present around healthy teeth. This, in part, contributes to less-than-ideal aesthetic results and crestal bone resorption.

The morphology of the portion of natural teeth that is positioned between the bone crest and gingival margin (transition zone) is highly variable, ranging from the rather simple ovoid shape of mandibular incisors to the highly complex rhomboidal shape of maxillary molars. With the implants in use today, dentists and laboratory technicians must reproduce this aspect of a tooth with the starting point being the round symmetrical platform of the fixture, in essence, attempting to “fit a square peg into a round hole”. This necessitates a supracrestal soft-tissue thickness of 3 to 4 mm to facilitate development of an appropriate emergence profile for the future crown. It is critical to consider this in the context of the biologic width associated with implant-supported restorations, which also

typically varies from 3 to 4 mm. If the supracrestal soft tissue is thinner and the implant is placed at the bone crest, remodelling of the bone occurs to naturally re-establish the biologic width while simultaneously providing sufficient soft-tissue thickness for restorative purposes. Alternatively, clinicians will artificially provide space for reformation of the biologic width by placing the implant subcrestally. This can lead to additional bone remodelling such that an infra-bony defect develops around the implant that is then subject to further breakdown. Furthermore, this results in the abutment–implant interface being positioned subcrestally and it is well established that a zone of inflamed connective tissue can form in this area.⁶ Thus, to provide sufficient space for the biologic width and tissue thickness for the emergence profile of the crown, a clinician could be creating a scenario that is highly susceptible to future crestal bone loss.

In this case report we describe a novel approach to replacing mandibular molars with a customised tooth-shaped implant that positions the abutment–implant interface supracrestally. The design of this implant will facilitate immediate placement in molar sockets, minimise the extent of crestal bone loss and yield highly aesthetic results.

Case report

A 70-year-old male physician with a non-contributory medical history presented with a compromised mandibular right first molar (#30) that was deemed to have a

The ONLY two-piece zirconia implant with long-term studies

Independent 9-year study (University of Düsseldorf)¹

Only we achieve this

- No peri-implantitis¹
- No implant fractures¹
- Predictable osseointegration²
(Over 70% BIC after 4 weeks)



¹ Brunello G, Rauch N, Becker K, Hakimi AR, Schwarz F, Becker J. Two-piece zirconia implants in the posterior mandible and maxilla: A cohort study with a follow-up period of 9 years. Clin Oral Implants Res. 2022 Dec;33(12):1233-1244. doi: 10.1111/clr.14005. Epub 2022 Oct 31. PMID: 36184914.

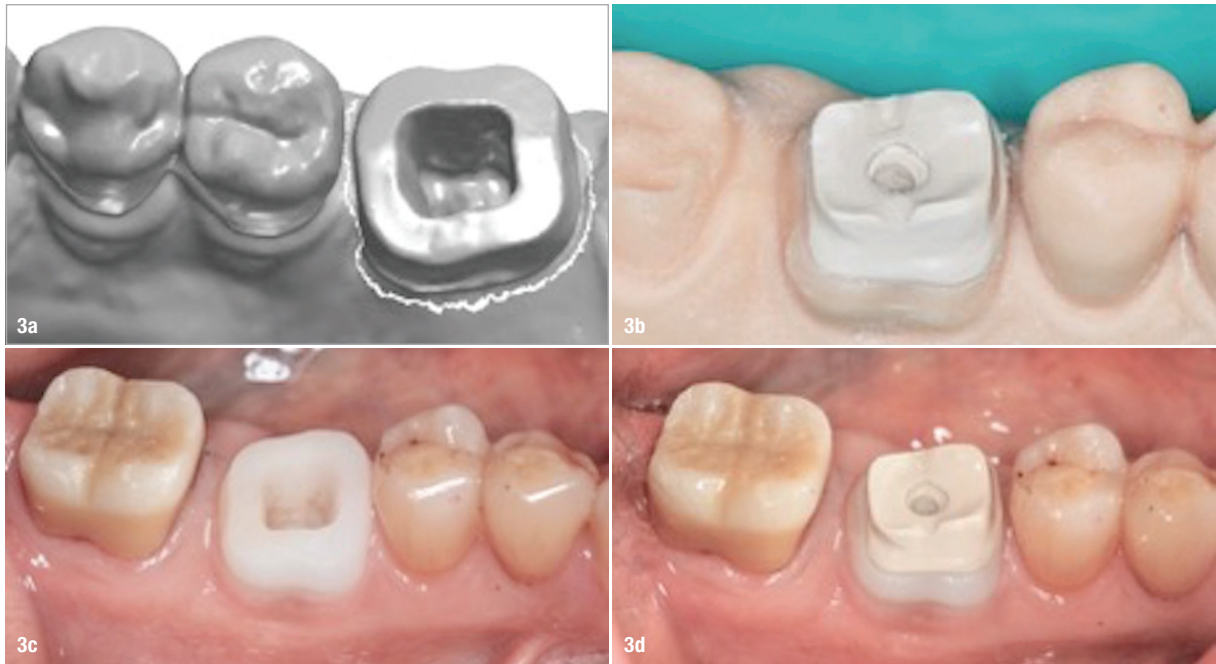
² Glauser, R., Schubach, P. Early bone formation around immediately placed two-piece tissue-level zirconia implants with a modified surface: an experimental study in the miniature pig mandible. Int J Implant Dent 8, 37 (2022). <https://doi.org/10.1186/s40729-022-00437-z>

The New Standard



Long-term oral health: Patent™ redefines success in the first long-term study on two-piece zirconia implants. Learn more: www.mypatent.com/scientific-studies





Figs. 3a–d: Fabrication of the abutment. Digital design of abutment (a). Abutment milled from PEEK exhibiting adequate retention and resistance form for the future crown. A venting hole is present to allow complete seating of the abutment during cementation (b). Implant–abutment interface prior to cementation of the abutment (c). The abutment cemented in place (d).

hopeless prognosis due to a failed endodontic procedure (Fig. 1a). He was offered three treatment options:

1. a removal partial denture,
2. a three-unit tooth supported-bridge from #29 through #31 or
3. an implant-supported crown.

After discussing the risks and benefits associated with each approach the patient decided on the third option. From casual discussions, he was extremely familiar with our work on the customised implant system and, understanding the experimental nature of the device, requested that one be used to replace his tooth. Informed consent was obtained for the procedure.

A CBCT demonstrated ample alveolar bone height and width for implant placement without the need for augmentation. The same CBCT scan was used to design and fabricate the implant construct from a zirconium dioxide block (yttrium-stabilised tetragonal zirconia polycrystalline) using computer-aided design/computer-aided manufacturing technology. The custom implant construct did not reproduce the entire natural tooth but did incorporate root-form and transgingival elements both of which mimicked the actual morphology of the patient's tooth. In contrast to traditional bone level implants, this design placed what would be considered as the implant–abutment interface in a supragingival position. Furthermore, the coronal aspect of the implant–abutment construct was not flat but was designed with slants in the mesiodistal and buccolingual dimensions to accommo-

date the natural ten-degree lingual angulation of mandibular molars. The gingival collar of the construct was polished while the transition zone and sub-osseous aspects of the implant were sandblasted with 50-micron aluminium oxide. The implant was cleaned, autoclaved, and maintained in a sterile package.

Local anaesthesia was administered via buccal and lingual infiltration injections adjacent to #30 using 4% Septocaine and 1:100,000 epinephrine. The tooth was sectioned buccolingually and the roots extracted in a minimally traumatic manner (Figs. 1b & c). The implant construct was press fit into the extraction site resulting in complete obliteration of the sockets (Fig. 1d). The hole in the coronal aspect of the construct was sealed with cotton and Cavit (3M ESPE). Postoperative instructions were reviewed with the patient as were prescriptions for Ibuprofen (600 mg, one tablet q6–8h PRN pain) and Amoxicillin (500 mg q8h for seven days). The patient tolerated the procedure well and was reappointed for a follow-up visit.

At the one-month follow-up visit, the patient denied any postsurgical complications and healing was progressing normally (Fig. 2a). The patient was seen six months later for insertion of a provisional restoration. The peri-implant soft tissues were found to be healthy and there was no radiographic evidence of bone loss around the implant. The old metaloceramic crown on #31 was removed to address recurrent caries and deteriorating margins followed by preparation for a full coverage crown. A digital

impression was taken of the implant at site #30 and prepared tooth #31 (Fig. 2b). The provisional crowns were fabricated out of acrylic using a block carving technique and cemented in place (Figs. 2c & d). An additional impression was made with the provisional restorations in place (Fig. 2e). The two STL files created from the digital impressions were merged into the 3Shape software (3Shape) to design the implant abutment, the implant-supported crown, and the conventional crown for #31. The implant abutment was digitally designed and milled from PEEK block material (Figs. 3a–c). After sandblasting and priming, the abutment was permanently cemented (Fig. 3d).

Digital versions of the final crowns were designed, and the files transferred to a milling machine (Figs. 4a–d). The restorations were milled from unsintered zirconium blocks (Fig. 5a), chromatised with liquid paint shade A4 (Fig. 5b) and subsequently sintered (Fig. 5c). Seven months post placement, the crowns were seated in the patient's mouth, adjusted, glazed extra-orally and polished. The crowns were then cemented with RelyX Unicem 2 (3M) resin cement. The restorations provided adequate support for the adjacent soft tissues and were aesthetically acceptable to the patient (Figs. 6a & b). A periapical radiograph was taken that confirmed the seating of the crowns and showed the intimate fit of the implant within the sockets of the extracted tooth (Fig. 6c).

Discussion

With appropriate case selection, immediate placement and restoration of implants is safe and yields predictable outcomes when replacing incisors, canines, and premolars. For numerous reasons, the same level of predictability has not been achieved in molar sites. To point out is the lack of adequate bone volume to achieve primary stability of the immediately placed implant. To address this issue, several groups have evaluated the use of customised one-piece implants mimicking the anatomy of natural teeth.^{7,8} The reported clinical outcomes have been mixed such that these types of fixtures are not a component of the arma-

mentarium of modern-day implant dentistry.^{9–11} Thus, this represents one clinical scenario that warrants development of alternatives to the implants currently on the market.

Recognising the potential benefits of customised root-form implants and appreciating the previously demonstrated deficiencies of the one-piece systems, a prototype of a unique two-piece customised implant system has been developed to be used for immediate placement following extraction of mandibular molars. Since this is a two-piece system, it avoids the necessity for immediate loading. Based on our fundamental knowledge regarding the wound healing response of alveolar bone and the overlying soft tissue following implant placement, the components were designed to minimise crestal bone loss while providing an environment that facilitates the fabrication of restorations with ideal emergence profiles. This case report describes the successful replacement of a compromised mandibular right first molar (#30) with this customised two-piece zirconia implant–abutment system.

The design of the implant and abutment incorporate several properties that should lead to quicker healing, reduced pre- and post-loading crestal bone loss, enhanced peri-implant soft-tissue health and improved aesthetic outcomes relative to conventional bone level implants. Since the shape of the implant is based on the anatomy of the patient's tooth, no site preparation is required for its placement. Minimally traumatic extraction of the tooth via a flapless approach is followed by press fitting the implant into the socket resulting in intimate contact with the adjacent alveolar bone allowing for quick and uneventful healing. By mimicking the shape of the natural tooth in the transition zone between the bone crest and gingival margin, the soft tissue is constantly supported in its natural configuration, greatly diminishing the likelihood of recession. Furthermore, the tissue level design of the implant positions the implant–abutment interface supra-crestally permitting the biologic width to form on the fixture itself thereby mitigating the likelihood of crestal bone resorp-



**Precise
measurement of
jawbone density!**

**Ensuring your
implant success
and the health of
your patients.**

**GET IN TOUCH:
info@cavitau.de**

**LEARN MORE:
www.cavitau.de/en**

