

ceramic implants

international magazine of ceramic implant technology



case report

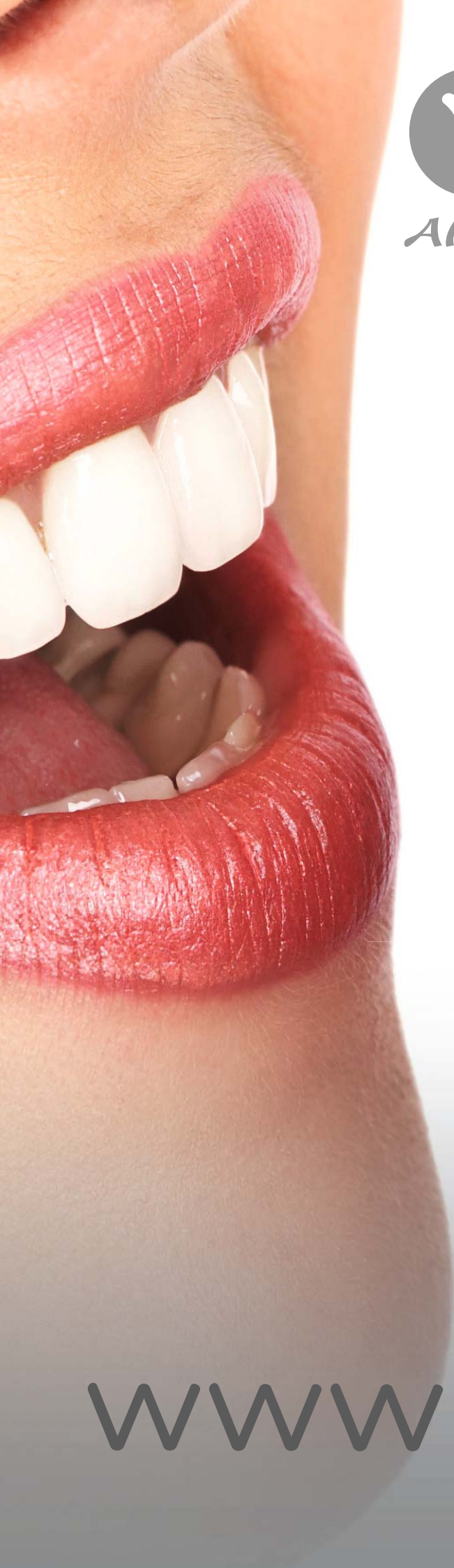Integrative oral medicine
meets aesthetic dentistry:
Mission possible

interview

Advocating for the superiority
of ceramic systems

events

Discover the EAO annual
scientific meeting in Berlin



AWI

Albus WITAR Implants



www.witar.de

Fifty shades of white?

The advantages of implants fabricated from zirconium dioxide, such as aesthetics and high corrosion resistance, make them an interesting therapeutic alternative. Clinicians must realise, however, that just like implants made of titanium and titanium alloys, not every ceramic implant successfully osseointegrates.

The etiology of complications in implant therapy is not always found in those patients with pre-existing conditions, poor oral hygiene, or placement by those physicians with inadequate training and experience. Some manufacturers assert that these factors are the root cause of failure to osseointegrate, conveniently omitting their role as a result of flaws in the manufacturing and packaging process.

Implant quality is a key factor for successful osseointegration. After unboxing, every implant must be free of foreign particles and contaminants resulting from deficits in the complex chain of production. Sterility does not equate with a clean surface. Even though it is not rocket science, some manufacturers fail to strive for sufficient quality assurance. In particular, micron-sized plastic residues on the implant surface are associated with unwanted biological effects ranging from bone loss to implant failure.

We reached a critical degree of research integrity if a manufacturer in a renowned scientific journal portrays a level of implant cleanliness that technically does not exist—by showing manipulated and “cherry-picked” SEM images of his ceramic implant system.

It is even less supportive in building trust among implantologists if the analysis of another ceramic implant system reveals a cell-toxic biocide on the implant surface in a quality assessment study. After this manufacturer was informed accordingly, the authors of the study were subject to intimidation tactics and threats of legal action in the event of any publication of the scientific findings.


In this way, few manufacturers tarnish the success of the dental industry’s pursuit of enhancing clinical safety in ceramic implantology. Fortunately, there are responsible manufacturers who meet the quality expectations in their products and deliver flawless dental implants.

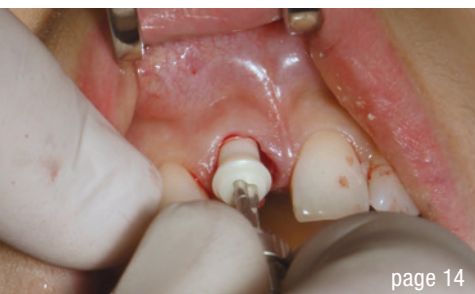Ceramic implants deserve the trust of practitioners and patients, provided they are as clean as promised. Trust is like paper. Once it’s crumpled it can never be perfect again.

With respect,
Dr Dirk U. Duddeck

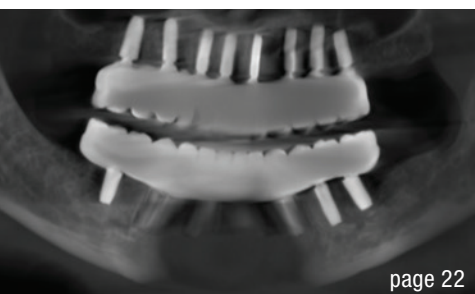

Dr Dirk U. Duddeck, Germany
Founder and Head of Research
of the CleanImplant Foundation





page 14



page 22



page 34

Cover image courtesy of
Z-SYSTEMS
www.zsystems.com



editorial

Fifty shades of white? 03
Dr Dirk U. Duddeck

case report

Integrative oral medicine meets aesthetic dentistry: 06
Mission possible
Drs Fabian Schick, Johann Lechner & Florian Notter

Single-tooth restoration with a two-piece Patent™ Implant 14
Dr Harald Fahrenholz

Restoring anterior aesthetics with two-piece zirconia implants 18
Dr Saurabh Gupta

testimonial

Stability ensured 22

research

CleanImplant Foundation Trusted Quality seal: 24
More manufacturers prove the production quality of their implant systems

interview

Advocating for the superiority of ceramic systems 26
An interview with John Sheehy

industry

Neodent, a Straumann Group brand 28

events

Zirconia implant: An evolution or a revolution? 30

Discover the EAO annual scientific meeting in Berlin 32

“Ceramic Implants meets Aesthetics”: 7th Annual Meeting of 34
ISMI successful in Munich

news

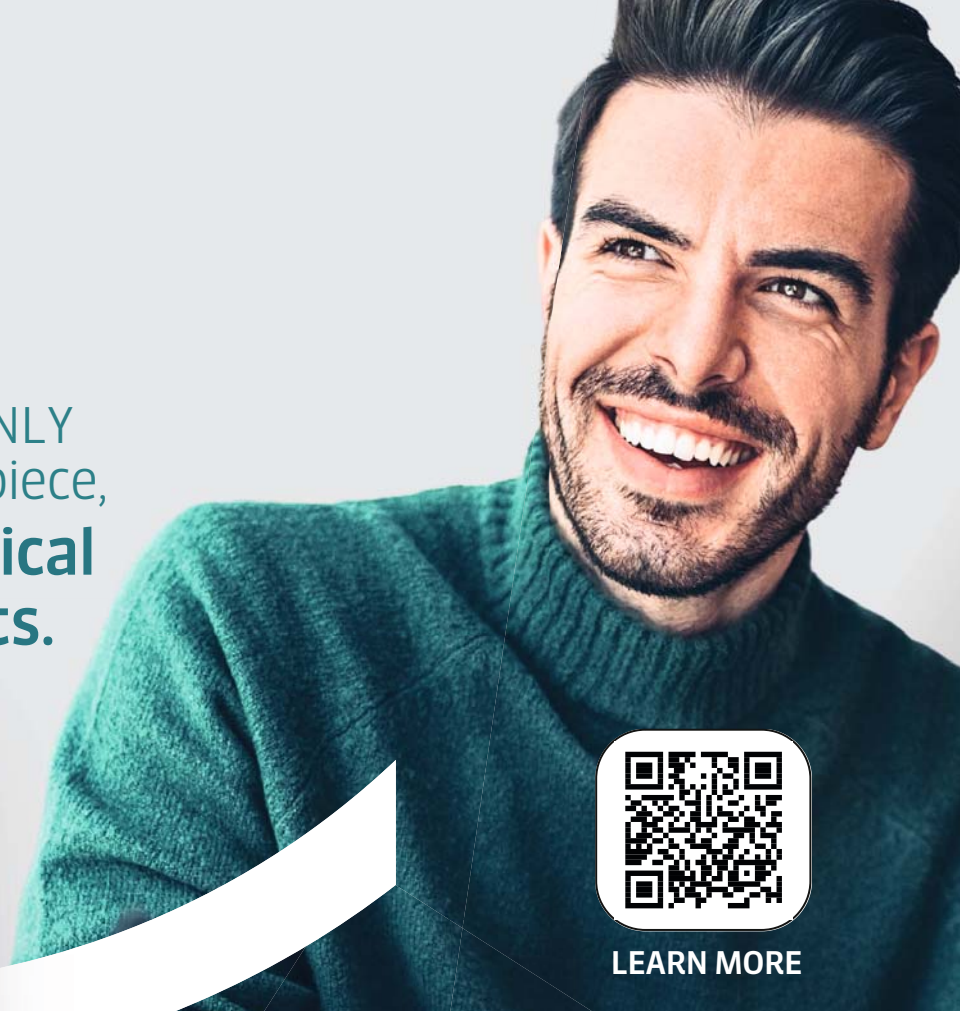manufacturer news 36

about the publisher


imprint 42





The world's FIRST and ONLY
100% fully-ceramic two-piece,
**screw-retained conical
connection implants.**





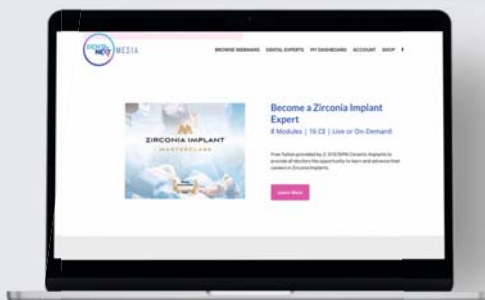
LEARN MORE



-  Conical screw connection with internal thread for micro-gap-free connection and prevention of a pump effect.
-  Wide range of straight and angled abutments for optimal esthetics and flexible functionality

Z-SYSTEMS provides all doctors the opportunity to
learn and advance their careers in Ceramic Implants!


-  On-Demand Instruction by Zirconia Implant Experts
-  Earn Continuing Education Credits!



CONNECT NOW
FOR FREE!

sales@zsystems.com
www.zsystems.com/ceramic-dental-implants

Integrative oral medicine meets aesthetic dentistry: Mission possible



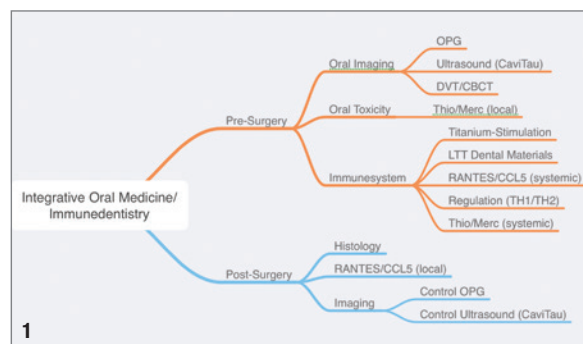
Drs Fabian Schick, Johann Lechner & Florian Notter, Germany

Introduction

Modern dental treatment concepts face a growing number of difficulties. Aesthetics, biocompatibility, and immunological release for the purpose of enhancing health are all factors that are increasingly important in addition to sustainability and functionality.

This article aims to demonstrate how bioinert materials and biological-functional regeneration-based integrative dental treatment concepts are progressively becoming promising superior treatment options that can even exceed the highest aesthetic demands. Sustainable, functional, and immunologically ideal results can all be accomplished simultaneously using minimally invasive and defect-oriented surgical procedures and protocols to optimise healing and regeneration of oral hard and soft tissues.

There is research on whether long-term immunological stress and dysregulation can cause chronic fatigue.¹ But it is not always clear where this persistent dysregulation and immunological stress comes from. Hence, views that chronic diseases also have an oral origin are becoming more frequent:



“We now know that many chronic diseases originate in the oral cavity,” says Prof. Zeltner, Chairman WHO, 2022.²

Question

This case study demonstrates that the aesthetic restoration of a patient with a high smile line and immunological release by removal of chronic inflammatory lesions in the oral cavity are not at all incompatible.

Can immunologic stress occur in the oral cavity even when there are no acute symptoms? Can a disorder with

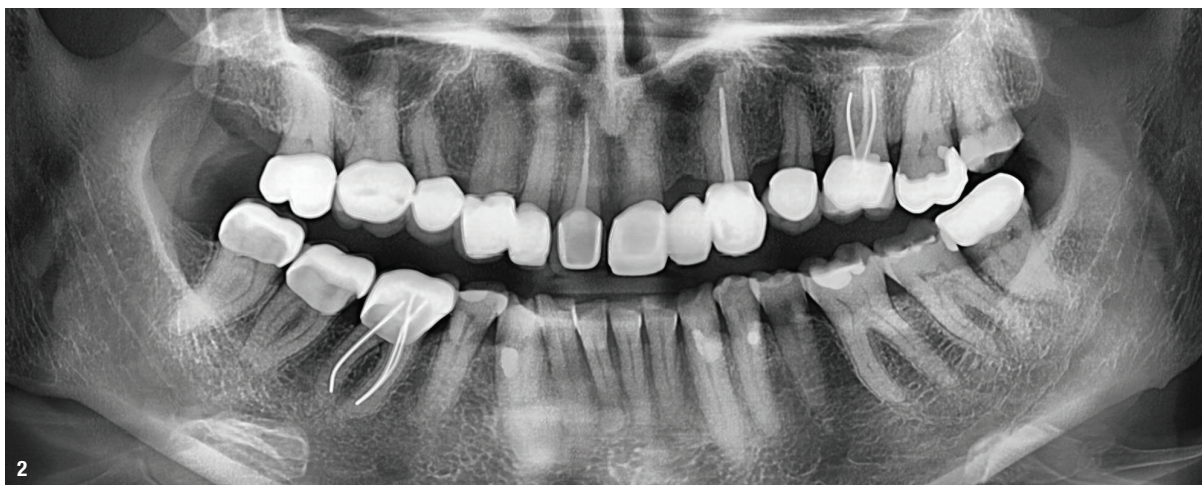

Fig. 1: Diagnostic scheme Integrative Oral Medicine/Immunedentistry. Fig. 2: Preoperative orthopantomograph (OPG) transalveolar ultrasound sonography.

an unknown etiology like chronic fatigue arise because of this continuous stress and the dysregulation it causes?

Material and methods

A middle-aged patient with a prominent smile line and strong aesthetic expectations comes to see us at the beginning of 2021. She inquires about the clarification of chronic inflammatory lesions in the oral and maxillofacial region as she suffers from chronic fatigue. We perform complete oral imaging, toxicological, and immunological tests in accordance with a standardised diagnostic system, after which we develop an individual treatment plan. The primary goal is to identify osteoimmunological chronic inflammatory lesions in the oral and maxillofacial region. Secondly, we want to release and stabilise autologous immunological regulation through the removal of chronic stress. An overall health symptom such as chronic fatigue is also to be achieved through immunological release and the interdisciplinary connection can be brought up.

Oral imaging

Prosthetically insufficiently restored teeth, metal-containing crowns, endodontically treated teeth 11, 23, 26, missing tooth 22. Possible apical osteolysis 21. No signs of other acute or chronic inflammatory lesions.

Transalveolar ultrasound sonography

Areas of lower bone density (red) and higher bone density (green) were visible using transalveolar bone densitometry and ultrasonography. Red areas surrounding root-treated teeth and in toothless bone areas indicate osteolytic degeneration of the bone, which is expected to have increased RANTES/CCL5 cytokine expression.³ Hence, red bone areas indicate immunologic stresses such as unformed dental germs, endodontically treated teeth with increased expression of toxins such as thioethers and mercaptans, and improperly healed wounds. A three-dimensional CBCT/DVT is then performed if it is suspected that the relevant areas contain chronic inflammatory lesions.

Numerical evaluation of TAU measurement of bone density in CTU

A quantitative and qualitative evaluation of the osteolytic bone regions is required for individualised treatment planning. For this goal, the authors have created a method to evaluate each odonton's transalveolar ultrasound examination (TAU). The darker levels of each individual sensor field are analysed and evaluated for this purpose; this grade can, for example, support in the therapeutic decision of immediate implantation after removal of the osteolytic areas or delayed implantation. This prevents osteoimmunological stress and results in a problem-free osseointegration. A

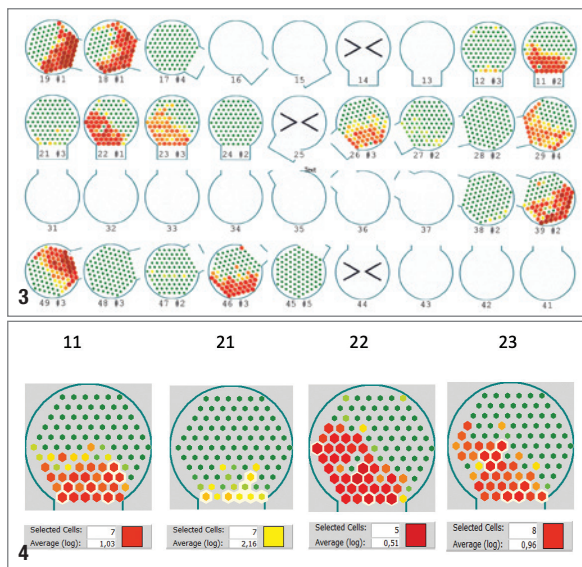


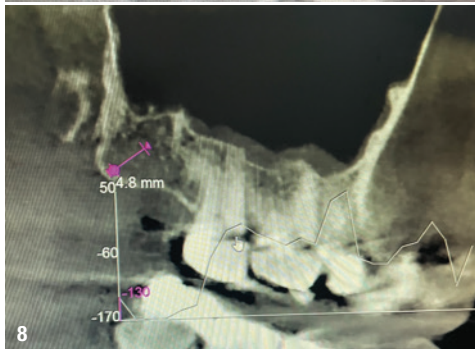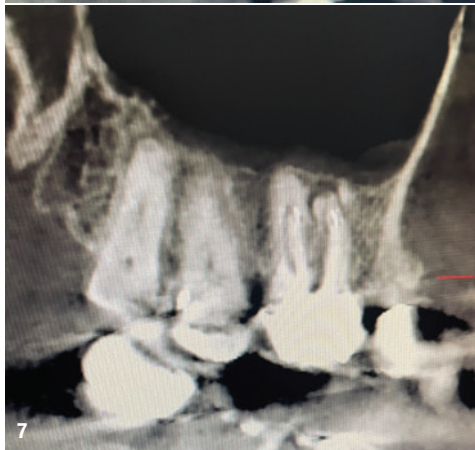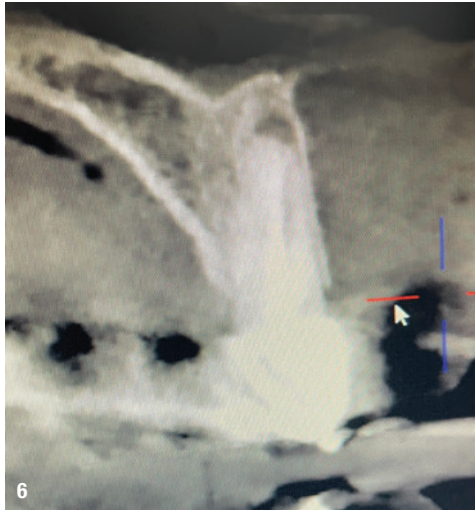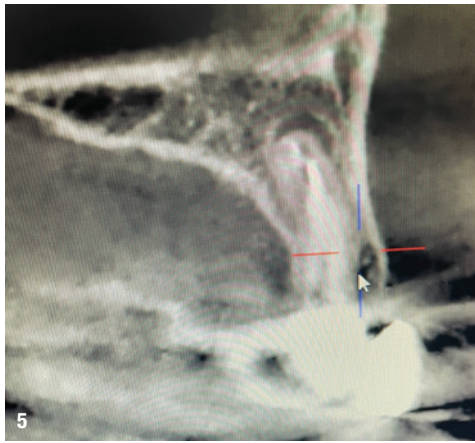
Fig. 3: Preoperative transalveolar bone densitometry (TAU), numerical evaluation of TAU measurement of bone density in CTU. **Fig. 4:** Transalveolar bone densitometry (TAU) for tooth region 11-21.

logarithmic average value (Average [log]) of the absorption intensity and, therefore, of the recorded bone density is computed by selecting the darkest sensor fields of the analysed odonton (area 11, 21, 22, 23 in red; Fig. 4).

A CTU of 0.51 for fatty degenerative osteolysis/osteonecrosis (FDOK/FDOJ) is shown in this instance at site 22. In order to enable an excellent biologic-functional regeneration with high bone quality, it was necessary to pay special attention to a complete removal of the osteolytic bone regions before implant drilling 22, extraction 23, and before implant insertion 22, 23. An implant osseointegration result that is sustainable and inflammation-free can be achieved by inserting the implant in healthy bone.⁴

For an overview of CTUs and their interpretation, see the table below:

CTU	Colour	Consistency	Anatomy/suspicion
0,24	Grey	Hollow Cavity	Fault?
0,23	Dark red	Dissolved/liquid	Osteolysis
0,62	Light red	Soft/fatty	Osteonecrosis
1,18	Orange	Partially soft	Ostitis
1,68	Yellow-orange	Increasingly soft	Ischemia
1,85	Light yellow	Nerve structure	N. Infraalveolaris
1,96	Light green	Reduced hardness	Healthy Spongiosa
3,98	Green	Dense/solid	Cortical bone/linea obliqua



Three-dimensional radiographic imaging

The findings in ultrasound are validated by significant chronic inflammation apical to the endodontically treated teeth 11, 23, and 26 (post-endodontic inflammation) and decreased Hounsfield values in bone regions with previous extractions.

Toxicological examination

Increased local expression of the toxicologically active bacterial metabolite thioether/mercaptan, which originates from remaining bacteria in endodontically treated teeth and is detected locally on the tooth using paper points that colours a particular test liquid more or less intensely depending on its exposure time.⁵

Immunological examination

Following blood samples showed, that the protein metabolites thioether and mercaptan that are toxicologically active were immunologically sensitised. And therefore, the clinical necessity for the surgical revision of the incompletely healed bone wounds with elevated cytokine expression (FDOJ/FDOJ) and removal of the endodontically treated teeth was given.

Clinical image/aesthetic planning

Special consideration was also necessary in this case because the patient was also dissatisfied with her smile aesthetics. The aesthetic reconstruction has to include the different length and shade relationships as well as the additional high smile line. Immediate ceramic implants were designed for aesthetic purposes in addition to immunological benefits in order to reliably and sustainably avoid the appearance of metallic margins and to protect as much bone volume as possible.⁶ In order to extend the clinical crowns aesthetically and create a harmonious appearance, a minimally invasive gum lift was also planned.

Surgical reconstruction

All chronic inflammatory lesions in the upper jaw were to be surgically removed using minimally invasive and defect-focused techniques especially in the aesthetically critical regions. The periapical osteitides and the chronically inflamed teeth 11, 22, and 23 were carefully removed. Fatty degenerated osteolysis (FDOJ/FDOJ) in surrounding bone regions was checked for and carefully removed. The toothless jaw areas underwent the same process. Tissue samples were collected to confirm increased RANTES/CCL5 cytokine expression. When compared to healthy bone tissue, cytokine expressions were found to be 14 times higher.⁷

Clinical Immunology			
Reactivity Mercaptans/Thioether			
INFg-stimulated	< 0.1	pg/ml	< 0.2
IL10-stimulated	66.6	pg/ml	< 10

Fig. 5: Periradicular osteolysis tooth 11. **Fig. 6:** Periradicular osteolysis tooth 23. **Fig. 7:** Periradicular osteolysis tooth 26. **Fig. 8:** Bone density (HU) measurement in region 18/19. **Fig. 9:** Immunological sensitisation to thioethers/mercaptans.

WE CAN WORK IT OUT.

These implant systems were awarded the CleanImplant “Trusted Quality” seal after an unbiased and peer-reviewed quality assessment.

See what’s new:



UnicCa
BTI

Inverta
SOUTHERN
IMPLANTS

Patent
CHAMPIONS IMPLANTS

ICX-Premium
MEDENTIS MEDICAL

whiteSKY
BREIDENT MEDICAL

Prama
SWEDEN & MARTINA

SDS 2.2
SWISS DENTAL
SOLUTIONS

T6
NUCLEOSS

Astra Tech EV
DENTSPLY SIRONA

AnyRidge
MEGAGEN

(R)Evolution
CHAMPIONS IMPLANTS

BlueDiamond
MEGAGEN

SuperLine
DENTIUM

In-Kone
GLOBAL D

Contact S
BIOTECH DENTAL

- Find out more. Join in and support the charitable initiative.
- Receive quality information about your implant in use.
- Provide more safety for your patients and avoid negligence claims.
- Win new patients as a CleanImplant Certified Dentist.

Visit us at
EAO BERLIN!
Booth C 06



More information about this non-profit initiative:
www.cleanimplant.com/dentists

CLEAN IMPLANT
FOUNDATION