

## Inside this issue

### Doing it his way

Dr. Barry Matza sits down with Ortho Tribune to talk about the events that led him to orthodontics and interdisciplinary dentistry.

Page 4

### Stop running scared

The economy is down. We know that. But instead of panicking and making classic business mistakes with your practice, there are four tips you need to understand.

Page 16

### What's new



American Tooth reveals its new bracket and Amazing Animation shows off its newest cell that will look good in every orthodontist's office.

Page 22

# Treating deep anterior overbite in adult patients

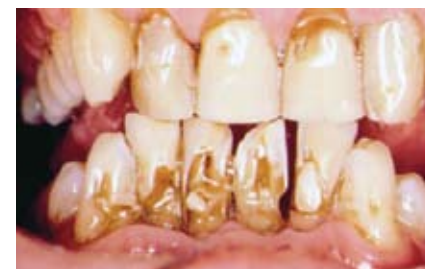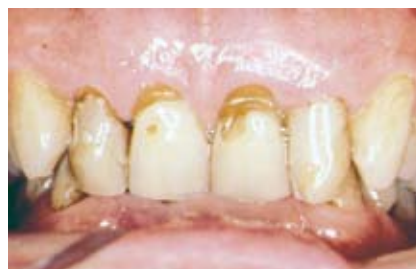By Dr. Julia Harfin

**T**he treatment of deep anterior overbite in adults is a real challenge. It is important to know the different etiological factors and their influence on the malocclusion. In general, these patients have the lower third of the face diminished and a tendency to have a concave profile with good lip closure.

The presence or absence of growth is another issue to take into account when deciding the treatment plan. When there is a potential path of growth, the results are more controlled and effective; this is the reason why treatment in mixed dentition or early permanent dentition is recommended.

Deep overbite can be observed in Class I, II or III patients, but is most common in Class II Division II brachyfacial patients.

One of the most frequent characteristics is the presence of an increased interincisal angle.



Figs. 1a, 1b: A 58-year-old patient was sent by the prosthodontist to the orthodontic department in order to improve esthetics and normalize the position of the upper incisors to make room to reconstruct the labial side of the lower anterior incisors.



Figs. 2a, 2b: A 26-year-old who wants a change in the position of her upper left lateral incisor.

## Overbite

OT see page 6

# Symposia, ortho day at Greater N.Y. Dental Meeting

**T**he New York University College of Dentistry and NYU Orthodontic Alumni Society will jointly present their third annual full-day orthodontic seminar on Wednesday, Dec. 3 at the Greater New York Dental Meeting (GNYDM).

Featured speakers include Drs. R.G. "Wick" Alexander, Anthony Gianelly, Lionel Sadowsky and Jack Fisher on such topics as "When Does A Non-Extraction Orthodontist Extract?," "Evidence Based Analysis of Current Controversies," "Avoiding Orthodontic Errors and Management of These Errors" and "The Use of Temporary Skeletal Anchorage in Orthodontics."

The GNYDM is the largest dental meeting in the United States and has included a number of orthodontic programs for the orthodontist specialist.

The NYU program has been particularly successful and this year



Dr. Roberto Justus kicks off the morning session of Orthodontic Specialty Day with a presentation of treatment options for the anterior open bite during the 2007 Greater N.Y. Dental Meeting.

promises to be well attended as well.

Six C.E. credits will be awarded to attendees of this program. The full program and a registration form (look for course 6060) are available

at [www.gnydm.com](http://www.gnydm.com). For more information, contact Elliott Moskowitz at [typodont@aol.com](mailto:typodont@aol.com).

## Discover new specialties

This year, Dental Tribune America has partnered with the GNYDM organizers to offer four days of symposia in various areas of dentistry. Each day will feature a variety of

lectures on topics, which will be led by experts in that field. The afternoon sessions introduce attendees to Dental Tribune America's educational concept of "Getting Started in ...".

## Symposia

OT see page 22

PRSR STD  
U.S. Postage  
PAID  
Permit # 306  
Mechanicsburg, PA

# Running an office utilizing human resources management

By Dennis J. Tartakow, DMD, MEd, PhD  
Editor in Chief



## Part 3

According to Dr. James Caraway, differentiating between person-centered and task-intensive organizations, and between I-Thou and I-It relations, the Sixth Discipline provides guidance for the discipline that members can assess, separately or collectively, to the extent that the group or community is functioning for the individual's welfare. That includes all workers from the temporary worker to the CEO or Board of Trustees member.

Thus, the Sixth Discipline — "Relational Reality" — is more than an effort of a "fit" among workers, tasks or even the organization and refers to the best possible fit of management. It consistently confirms the primary resource of any organization is its people; the organization only exists to provide some good to the individual.

Relationships are the basis for reality. The Sixth Discipline explains: (a) the two types of individual relationships — the I-Thou relations of At-onement and the I-It relations of estrangement; and (b) the two types of organizational relationships — the community and the collective.

The importance of "Rational Reality" is that it relates to something we can study, master or accomplish. According to Dr. Caraway, Martin Buber said that 25 centuries of philosophers were wrong — we have never experienced aloneness; we have always experienced relationships! That is things, people, etc.

There are two basic relationships: (a) I-It, and (b) I-Thou. All things and people have shape, parts, etc., but our relationship between It (things) and Thou (people) can be summed up as follows:

- things you can use, people you cannot;
- things are not responsive, people are; and
- things you know about, people you know.

The scientific method occurs by observation; the epistemology is about knowledge. "It" depends on observation. "Thou" depends on what he or she reveals ... but this is not observation. Therefore, to summarize

Caraway's concept, describing the resource management dimension of an organization, it is relationships that permeate all organizations and institutions, and therefore without the Sixth Discipline, the other five would not reach fulfillment.

## Team learning

According to Senge, team learning has four critical dimensions that people must think about: (a) complex issues, (b) developing innovative and coordinated actions in order to provide an "organized trust" to complement the actions of all, (c) playing a role on other learning teams, although they are on one team, ensuring that real knowledge transference occurs, and (d) spreading knowledge and openness throughout the organization. It is important to ensure that team learning is about positive learning and overcoming opposing forces.

Senges suggested three dimensions for team learning: (a) dialogue, (b) discussion and (c) analysis of "current reality." A dialogue does not operate as a win-lose position but allows people to realize the collective nature of thought, as well as developing a "kind of sensitivity," so that we can reflect on our own concepts, realizing the collective nature of thinking and language itself.

Collective learning is the basis of team learning and has three basic conditions: (a) all people must suspend their assumptions, (b) all people must look at each other as colleagues, and (c) a facilitator must be included to maintain the context of dialogue.

Therefore, in the realm of social sciences, the orthodontic office and its staff offer social arrangements that pursue collective goals, which controls its overall performance. Social science researchers often examine organizational theory and practice from several different modalities, the most common of which are: sociology, psychology, economics, political science, human resources management and communication.

For purposes of this discussion, the orthodontic office has been referred to as an organization by its relationship to human resources management because the structure, function and productive ends were virtually the same. The organizational structure is directly related to the function and mission, as well as the rules and regulations for controlling activities in either a boutique practice or the larger office. Therefore, the office structure is a means to an end in order to achieve its goals and create focus on its objectives, requiring the effort of all employees.

## Summary

1. Organizations are the strategies of individuals created to achieve certain objectives, and they require the effort of many individuals. Most orga-

nizations follow a particular strategy whose roots are found in military theory, industrial economics, public administration or scientific management.

2. The strategy from these roots lead to a pyramid-shaped, formal organization that can be defined by such principles as a chain of command, span of control or task specialization. If the strategy works as intended, the analysis would end here. However, the formal organizational strategy typically hits some snags due to the human influence.

3. Mutual adaptations occur when an organization changes the individual's personality and the individual in turn modifies the formal organization, which become part of the organization.

4. A total organization is more than the formal organization. The concept is that as a behavioral system, it might be concluded that the organization is a composite of four different but interrelated subsystems that have behavior that results from the (a) formal organizational demands, (b) demands of the informal activities, (c) individual's attempt to fulfill his idiosyncratic needs, and (d) unique patterning for each organization of the three levels above.

5. In the organization's resources management dimension, it is relationships that permeate all organizations and institutions.

6. The development of the individual in our culture is the most important factor for all offices or organizations.

References are available from the publisher.

## OT Corrections

Ortho Tribune strives to maintain the utmost accuracy in its news and clinical reports. If you find a factual error or content that requires clarification, please report the details to Kristine Colker, Managing Editor, at k.colker@dtamerica.com.



Image courtesy of Dr. Earl Broker.



Publication Member of the American Association of Dental Editors

## ORTHO TRIBUNE

The World's Orthodontic Newspaper - U.S. Edition

### Publisher

Torsten Oemus, t.oemus@dtamerica.com

### President

Eric Seid, e.seid@dtamerica.com

### Group Editor

Robin Goodman  
r.goodman@dtamerica.com

### Editor in Chief Ortho Tribune

Prof. Dennis Tartakow  
d.tartakow@dtamerica.com

### International Editor Ortho Tribune

Dr. Reiner Oemus  
r.oemus@dtamerica.com

### Managing Editor/Designer Ortho Tribune

Kristine Colker  
k.colker@dtamerica.com

### Managing Editor Endo Tribune

Fred Michmershuizen  
f.michmershuizen@dtamerica.com

### Managing Editor Implant Tribune

Sierra Rendon  
s.rendon@dtamerica.com

### Product & Account Manager

Humberto Estrada  
h.estrada@dtamerica.com

### Product & Account Manager

Greg Anderson  
gregory.anderson2@comcast.net

### Marketing Manager

Anna Wlodarczyk  
a.wlodarczyk@dtamerica.com

### Marketing & Sales Assistant

Lorrie Young  
l.young@dtamerica.com

### C.E. Manager

Julia Wehkamp  
j.wehkamp@dtamerica.com

### Design Support

Yodit Tesfaye  
y.tesfaye@dtamerica.com

Dental Tribune America, LLC

213 West 35<sup>th</sup> Street, Suite 801

New York, NY 10001

Phone: (212) 244-7181, Fax: (212) 244-7185



Published by Dental Tribune America

© 2008, Dental Tribune International GmbH. All rights reserved.

Dental Tribune makes every effort to report clinical information and manufacturer's product news accurately, but cannot assume responsibility for the validity of product claims, or for typographical errors. The publishers also do not assume responsibility for product names or claims, or statements made by advertisers. Opinions expressed by authors are their own and may not reflect those of Dental Tribune International.

## OT Editorial Advisory Board

Jay Bowman, DMD, MSD  
(Journalism & Education)

Robert Boyd, DDS, MEd  
(Periodontics & Education)

Earl Broker, DDS  
(T.M.D. & Orofacial Pain)

Tarek El-Baily, BDS, MS, MS, PhD  
(Research, Bioengineering & Education)

Donald Giddon, DMD, PhD  
(Psychology & Education)

Donald Machen, DMD, MSD, MD, JD, MBA  
(Medicine, Law & Business)

James Mah, DDS, MSc, MRCD, DMSc  
(Craniofacial Imaging & Education)

Richard Masella, DMD (Education)

Malcolm Meister, DDS, MSM, JD  
(Law & Education)

Harold Middleberg, DDS  
(Practice Management)

Elliott Moskowitz, DDS, MSd  
(Journalism & Education)

James Mulick, DDS, MSD  
(Craniofacial Research & Education)

Ravindra Nanda, BDS, MDS, PhD  
(Biomechanics & Education)

Edward O'Neil, MD (Internal Medicine)

Donald Picard, DDS, MS (Accounting)

Howard Sacks, DMD (Orthodontics)

Glenn Sameshima, DDS, PhD  
(Research & Education)

Daniel Sarya, DDS, MPH (Public Health)

Keith Sherwood, DDS (Oral Surgery)

James Souers, DDS (Orthodontics)

Gregg Tartakow, DMD (Orthodontics)  
& Ortho Tribune Associate Editor

# Applications in for Levin Makeover contest

This past summer, Levin Group and Ortho Tribune embarked on the first Levin Group Orthodontic Practice Power Makeover contest. Applications streamed in until the Sept. 30 deadline. The response was overwhelming with just over 100 applications from orthodontists all vying for the chance to win a free year-long Levin Group Total Ortho Success management and marketing consulting program. Check out next month's issue of Ortho Tribune to find out the winning practice!

The applicants ranged from orthodontists just starting their own practice to seasoned veterans. One message came through loud and clear: A makeover will be necessary at different points during the life of your practice. Evaluating your practice on a regular basis to determine strengths, weaknesses, opportunities and threats is critical to a practice's ability to reach its growth potential.

It is important to take a close look at your systems and make sure they are helping the practice run efficiently and profitably. Every orthodontist wants to reach financial independence, and your practice is the best investment to get you there. The Levin Group Orthodontic Practice Power Makeover applicants recognized the need for a makeover and shared their reasons for wanting one.

Many had interesting stories to tell. Some were experiencing serious challenges. One orthodontist is the new guy in town. He bought the 25-year old practice from someone

## Levin Group Orthodontic Practice Power MAKEOVER

who did very little to help him establish relationships with his best referral sources. Competition is fierce, and he is seeing an alarming decline in new patients coming through the door.

Another doctor discovered his office manager had embezzled money from the practice for a full year, forcing him to borrow money

just to keep the practice going. Now he is concerned his practice is at risk of completely falling apart.

A number of orthodontists with concerns over family friction in the practice applied for the makeover. A father and son or daughter working together to build a practice can be a wonderful experience, but it also poses challenges.

Others who applied are doing quite well, even enjoying practice growth, but as one doctor eloquently put it, "We are an example of doing all of the right things the wrong way." Another high-powered practice says it has a great team but is "stuck" in a smaller practice model inherited from the practice's previous owner.

Across the board, the applicants listed the following as their top goals of the makeover:

- practice growth and increased profitability
- less stress
- more cohesive team
- higher conversion rate

Stay tuned for continuous coverage on the Levin Group Orthodontic Practice Power Makeover in Ortho Tribune. In addition to regular updates on how the winning orthodontic practice progresses over 2009, we also will share some of the common threads as noted on the applications as well as Levin Group's Total Ortho Success strategies for jumpstarting your own makeover.

AD



### 'Marvelous Mouth' reveals tooth truths

Discover the wide world of braces, brushing and beautiful teeth in a hands-on exhibition targeted to pre-teens at the National Museum of Dentistry on the campus of the University of Maryland Baltimore.

Marvelous Mouth explores how to take care of braces, how mouth guards protect teeth during sports, how tobacco use can lead to tooth trouble and what careers are possible in the world of dentistry.

The exhibition features a central interactive computer station where visitors can explore the Marvelous Mouth animated game guided by a friendly tooth who takes on the guise of game show host, stealth Mission Impossible spy and hazmat crew member to illustrate the world of pre-teen oral health care.

## Improve dental and facial development for growing children.





Mouth breathing, tongue thrusting, incorrect swallowing and other myofunctional habits cause MALOCCLUSION and POOR FACIAL DEVELOPMENT. Research has proven the T4K™ can effectively develop arch form and alleviate crowding by correcting these habits. **Used by Orthodontists and Dentists in over 60 countries.**



**Pre-Orthodontic Trainer for Kids™ (T4K™)**

- TOOTH GUIDANCE SYSTEM**  
ALIGNS ANTERIOR TEETH  
TOOTH CHANNELS AND ANTERIOR DENTITION ALIGNERS.
- MYOFUNCTIONAL EFFECT™**  
RETRAINS TONGUE AND ORAL MUSCULATURE  
TONGUE TAG, TONGUE GUARD, AND LIP BUMPERS.
- JAW DEVELOPMENT**  
CLASS II CORRECTION  
AEROFOIL SHAPED BASE AND CLASS I RELATION ASSISTS CORRECTION OF JAW POSITION. DUAL ARCH ENCOURAGES NOSE BREATHING.

ALL APPLIANCES IN THE TRAINER SYSTEM™ FEATURE THE THREE PRIMARY BENEFITS OF THE MYOFUNCTIONAL EFFECT™: TOOTH ALIGNMENT, MYOFUNCTIONAL TRAINING, AND JAW POSITIONING.



**MYOFUNCTIONAL RESEARCH CO.**  
[www.myoresearch.com](http://www.myoresearch.com)  
MRC a BETTER way

CALL MRC FOR FREE EDUCATIONAL AND PROMOTIONAL MATERIAL, PATIENT BROCHURES & CD-ROMS

**1 800 531 4599**  
[www.myoresearch.com](http://www.myoresearch.com)



839 ENG 07/08

# 'Timing in life is everything'

*Dr. Barry Matza talks about the events that led him to orthodontics and interdisciplinary dentistry*

By Dennis J. Tartakow, DMD, MEd, PhD  
Editor in Chief

*Please introduce yourself to our readers and tell us about your background in orthodontics.*

I graduated from Tufts University, School of Dental Medicine in 1973 and worked as a general dentist for a maxillofacial prosthodontist. While teaching at Tufts the following year in the Oral Diagnosis Department, I met Dr. Everett Shapiro, chair of postgraduate orthodontics, and two years later received a certificate in orthodontics.

*What is the name of the institution with which you are affiliated?*

Nova Southeastern University, School of Dental Medicine, Department of Postgraduate Orthodontics, where I am an adjunct assistant professor.

*What motivated you to become an orthodontist?*

When I was in dental school, my first interest was in oral pathology as a result of being fortunate to have an exceptional teacher, Dr. Gerald Sklar.

However, I wanted more patient contact, and my next thought was specializing in oral and maxillofacial surgery. I spent a week of my spring vacation at Boston City Hospital and decided that this was not for me either.

I then pursued a career in orthodontics and enjoyed the challenge immensely: the age of the typical orthodontic patient, the thought process requiring biomechanics as an integral part of treatment and the challenge of "full mouth reconstruction in enamel on every patient."

Occlusion has always interested me. In my opinion, the complexity and variability of the stomatognathic system is a lifelong pursuit of the knowledge, and applying its principles to treat a patient's malocclusion really appealed to me.

*When and how did you open your orthodontic practice?*

After working a couple of years in New England, I moved to South Florida and opened my office in Boca Raton in 1979. I specifically remember the patient who paid for treatment up front as it was the first month I was able to pay the rent without drawing on my loan. This took five years, and as the saying goes: Patience is a virtue!

*What special areas of education, research or clinical activities are you most interested in and why?*

Although the interest in children



Dr. Matza with his residents at Nova Southeastern University.

motivated me to pursue orthodontics, timing in life is everything. When I first opened my office, the referral patterns did not allow me to build the adolescent patient referral. I was getting adult patients more and more. This forced me into an arena I knew little about as I had not treated many adults during my training.

I was later introduced to the Seattle Study Club Network where my interest in interdisciplinary dentistry began. After practicing orthodontics for 10 years, I began to interact with restorative dentists and the other dental specialists in a different manner. The adult dentition that was worn, mutilated and in need of a team approach became my focus.

It was 15 years after graduating dental school, and now I had the need to re-educate myself. I began taking courses that had little to do with orthodontics. If I was to communicate with my dental colleagues, I needed to learn and communicate in their language as well as understand current concepts of reconstruction.

Prior to teaching at NSU, I became involved with the craniofacial team at the University of Miami School of Medicine, where I was a clinical instructor in the Department of Plastic Surgery.

I had the privilege to be on the craniofacial team with Dr. Ralph Millard. I spent 10-plus years on that team and had the opportunity to learn the orthodontic needs of the craniofacial patient.

Not only did I get back to treating the adolescent, but I was taking impressions on infants to fabricate appliances in order to move alveolar segments in patients with cleft lip and palate deformities prior to the initial surgery to close the cleft.

*As an educator, what are your most important educational responsibilities to your post-graduate orthodontic residents?*

My role as educator has changed over the past 10 years at NSU; I review the literature with the orthodontic residents in adult treatment, periodontics, smile esthetics, interdisciplinary treatment, aligner therapy and craniofacial anomalies.

*In your opinion, is there a need to change the way higher educational programs in this country educate their orthodontic residents?*

We need more educators. However, in order to attract them, the pay scale needs to be attractive, especially today with the debt incurred by a new dentist as soon as he or she graduates.

*As an educator and clinician, what orthodontic techniques do you teach?*

I teach with a bidimensional edgewise technique. However, it is not the appliance that makes a case excellent; it is the diagnosis and implementation of a treatment plan using sound biomechanical principles, as well as understanding how the face grows and how that differs from the non-growing patient, that is omnipotent.

*Regarding the American Board of Orthodontics Certification, in your opinion*

- *Will more certified orthodontists benefit the specialty, the patient or both?*
- *What are some positive and/or negative effects of these changes?*
- *Is American Board Certification as important today as it was in the past?*

For me, becoming board certified was a very positive learning experi-

ence. The process of reflection on treated cases was enlightening and made me become a better orthodontist.

*Looking back at your career, would you do anything differently?*

I have been extremely fortunate. "I've done it my way!"

*Do you have any final comments for our readers?*

Orthodontics is a great profession. We can make a difference in our patients' lives. What a pleasure it is to go home at the end of the day when a patient thanks you for your help and you can say to yourself, "A job well done."

## OT About the doctor



Dr. Barry Matza is an adjunct assistant professor in the Department of Postgraduate Orthodontics, Nova Southeastern University, College of Dental Medicine. His professional accomplishments and academic appointments include: diplomate, American Board of Orthodontics; clinical instructor, Department of Diagnosis, Tufts School of Dental Medicine; consultant, South Florida Cleft Palate Clinic, University of Miami, School of Medicine, Division of Plastic Surgery; clinical attending instructor, University of Miami, School of Medicine, Department of Oral and Maxillofacial Surgery and Department of Plastic Surgery; and visiting lecturer, Post-Graduate Department of Orthodontics, Tufts University, School of Dental Medicine. Dr. Matza is a graduate of Tufts School of Dental Medicine and its postgraduate orthodontic residency program (DMD and Certificate). He has a private practice in Boca Raton, Fla.

## OT Contact

5100 Town Center Circle, Suite 106  
Boca Raton, Fla. 33486  
Phone: (561) 368-3480  
Fax: (561) 368-2380  
info@bmatza.com

waterpik®

# Flossing and braces. Right.

Now there's an easier and more effective solution for Mr. Non-Compliant.

Clinically proven more effective than floss for cleaning around braces



With a new ergonomic design that's perfect for kid's hands and a patented orthodontic brush tip, the Ultra Cordless dental water jet is the ultimate braces cleaning machine.

Goodbye threaders. The Ultra Cordless is so easy and so effective that your patients will enjoy using it every day. So if you have patients who struggle with flossing around their braces, recommend the new Waterpik® Ultra Cordless. But be prepared. You might just win over Mr. Non-Compliant.

Waterpik® **ULTRA Cordless**

**New!**

## PLAQUE REMOVAL\*

More Than

**3X**

As Effective as Floss

BRUSHING & FLOSSING

vs BRUSHING & WATERPIK®

## Overbite

OT from page 1

The lower incisors lose the stopper on the palatal side of the upper incisors and continue growing until they reach the gingival palatal tissue.

Because of the retroinclination of the upper and lower incisors, a shortening of the arches is observed but is more common in the upper than in the lower arch. In general, the arches are more square in shape because of the influence of the muscular pull (Fig. 1a).

In addition, the labial mental sulcus is very pronounced, and the lower lip covers the middle third and often the upper third of the upper incisors. The lips can appear retrognathic.

Another important issue is to determine if the deep overbite is located in the anterior region, in the posterior region or in both.

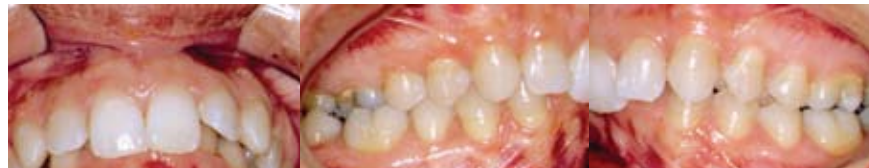In general, these patients come to the office looking for an esthetic improvement in order to normalize the position of the central and lateral incisors. Others are recommended by prosthodontists to normalize the position of the anterior teeth in search of more room for a normal restoration (Fig. 1b).

Usually in these patients the muscles are very well developed and the occlusal plane is altered with a very pronounced Spee's curve. The normal path of mastication would be changed.

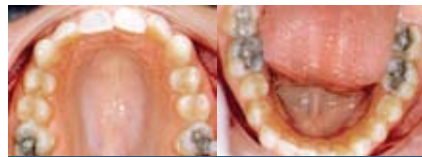Because they are non-growing patients, no orthopedic alterations can be expected. The treatment is limited to an orthodontic correction with or without orthognathic surgery.

It is very important to observe the presence or absence of a gingival smile because this issue determines the biomechanics that will be employed.

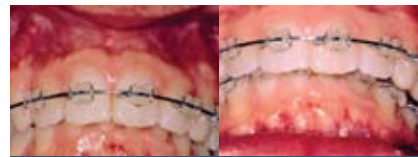
When the upper incisors are not visible during normal speech, the solution is to intrude the lower incisors in order to correct the deep overbite. If not, the result will be the typical smile of an older person.



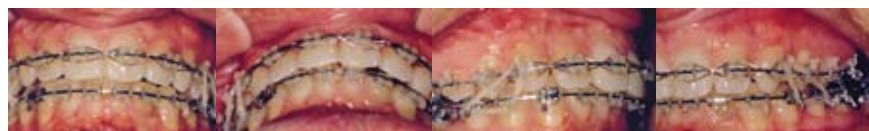Figs. 3a-3c: The overbite before treatment is at nearly 100 percent at the central incisors. A Class I canine and molar present on the right side and a Class II on the left side.



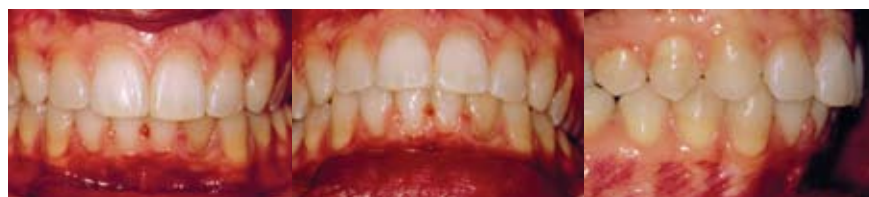Figs. 4a, 4b: The upper arch is a little straight in the anterior region. The upper right lateral incisor is in labial position, and a 2.5 mm discrepancy at the lower arch is present.



Figs. 6a, 6b: The major objectives of the treatment plan are to correct the position of the left lateral upper incisor, normalize overjet and overbite, achieve a Class I molar and canine and improve the smile.



Figs. 7a-7d: 0.022-inch pre-programmed esthetic brackets with metal slot are used with a 0.016-inch NiTiCu wire to begin the alignment. The brackets on the lower arch are bonded with a NiTi reversed curve.



Figs. 8a-8f: The results at the end of 20 months of active treatment.

In these cases we must consider the option to extrude the lateral sides or intrude the lower incisors.

Some patients will need temporary reconstruction of the occlusal surfaces in the posterior region, and on the palatal and labial surfaces in the anterior region, during treatment. At the end of the orthodontic treatment, a definitive reconstruction is necessary in order to maintain the results achieved.

Corrected deep overbite in adults requires an individualized treat-

ment plan, especially in the vertical plane. A bite plane is effective in retaining the overbite correction, and long-term use is recommended. As brachyfacial patients have more tendencies to relapse than mesofacial ones, the same type of retention is not possible.

Figures 2a and 2b show a 26-year-old patient who came in search of a second opinion regarding a change in the position of her upper left lateral incisor. She had been treated twice before, between ages 8 and

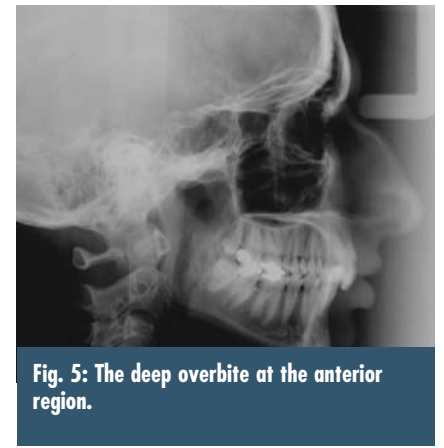


Fig. 5: The deep overbite at the anterior region.

10 with a removable appliance and between ages 14 and 16 with fixed appliances. She admitted she hadn't used the retention appliances as was indicated.

When we observed the facial photograph, we could see that the chin was slightly deviated to the left. She had a gingival smile, and the gingival line was not parallel to the lower lip as was described by Bjorn Zachrisson some years earlier.

The overbite was nearly 100 percent at the central incisors. She presented a Class I canine and molar on the right side and a Class II on the left side. The right first molar was in crossbite and the midline was slightly deviated (Figs. 3a-3c).

The upper arch was a little straight in the anterior region. The upper right lateral incisor was in labial position, and a 2.5 mm discrepancy at the lower arch was present (Figs. 4a, 4b).

Looking at the lateral X-ray, we can confirm the magnitude of the deep overbite in the anterior region (Fig. 5).

The major objectives of the treatment plan were to correct the position of the left lateral upper incisor, normalize overjet and overbite, achieve a Class I molar and canine and improve her smile (Figs. 6a, 6b).

0.022-inch pre-programmed esthetic brackets with a metal slot were used with a 0.016-inch NiTiCu wire to begin the alignment.

Overbite  
OT see page 8

AD

## ORTHO BANC. THE GOLD STANDARD IN PAYMENT MANAGEMENT

Visit us at these  
fall meetings.

SAO 2008 Annual Meeting  
Orlando, Florida  
November 6-8, 2008  
Booth# 508

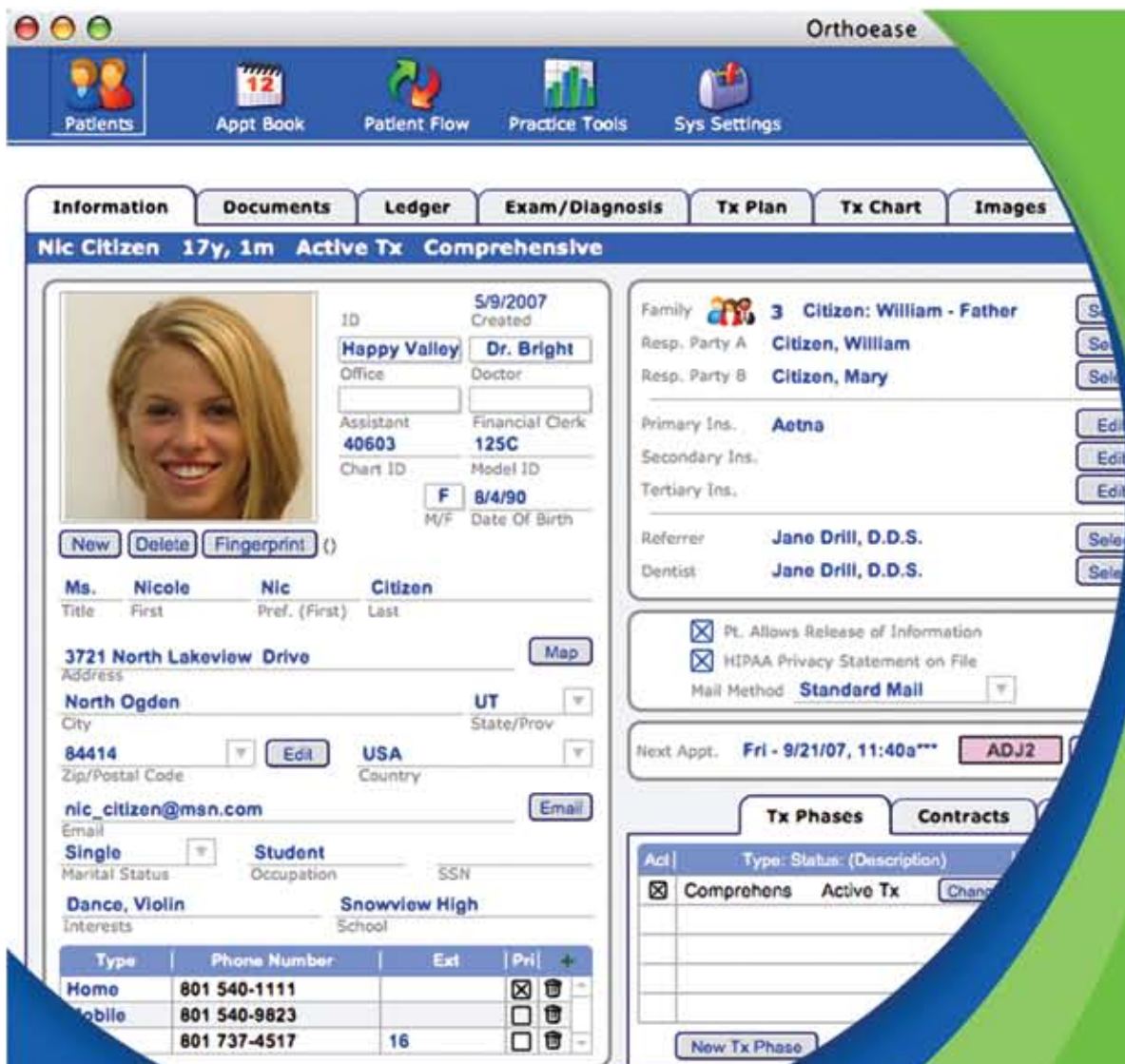
PCSO 72nd Annual Meeting  
Palm Springs, California  
November 14-15, 2008  
Booth # 315

- ACH Draft and Credit Card Payment Option
- Credit Analysis with Recommendation
- Complete Management of Your Accounts
- Credit Bureau Reporting and Collection Service Integration
- Integrated with Leading Technology Companies

OrthoBanc

PROFESSIONAL PAYMENT MANAGEMENT

Why would you do it any other way? Call 888-758-0585 or visit [www.orthobanc.com](http://www.orthobanc.com) to learn more.



# Orthoease

The most **intuitive** practice management software program yet!

## Featuring:

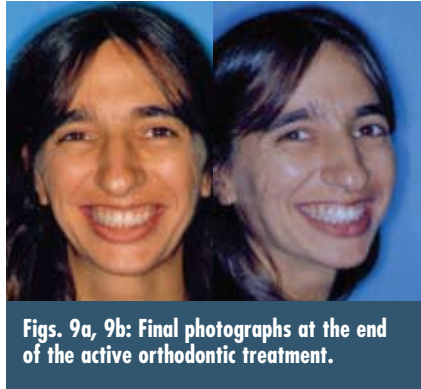
- Paperless Charting • Comprehensive Imaging & Analysis
- Ready-To-Use Scheduling Templates
- Automated Data Backup • World Class Support
- Industry's Best Financial and Management Reporting

**Improve your case acceptance  
and manage your practice with ease.**

**www.orthoease.com**  
**1-800-217-2912**

## Overbite

OT from page 6



Figs. 9a, 9b: Final photographs at the end of the active orthodontic treatment.

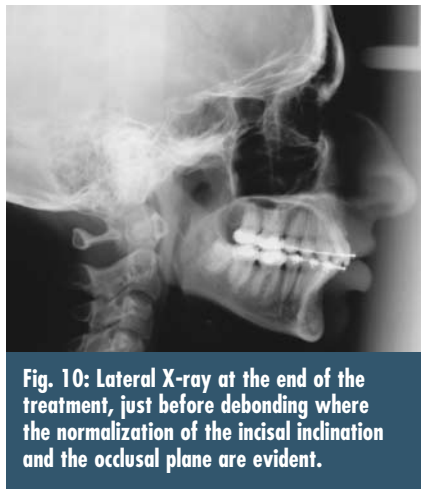


Fig. 10: Lateral X-ray at the end of the treatment, just before debonding where the normalization of the incisal inclination and the occlusal plane are evident.

After the alignment of the upper arch was completed, the brackets on the lower arch were bonded with a NiTi reversed curve in order to correct the retroinclination of the lower incisors (Figs. 7a–7d).

After eight months of treatment, and when the alignment and levelling of the arches was attained, full-time Class II elastics were recommended in conjunction with 0.016-inch by 0.022-inch stainless steel (SS) wires.

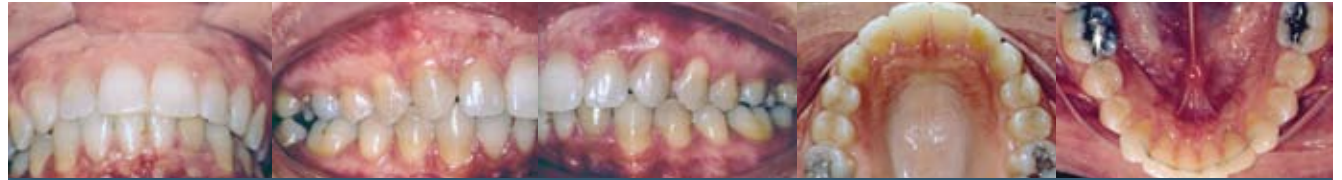Some over-correction of the deep overbite is advisable. After that, triangular elastics with a Class II component on the right and left side were suggested with individualized SS wires.

Figures 8a–8f and 9a and 9b show the results at the end of 20 months of active treatment. The midline is corrected, and the overjet and overbite are normalized. The occlusal plane is parallel to the gingival line. Class I molar and canine are obtained. The gingivo-periodontal tissues are almost normal.

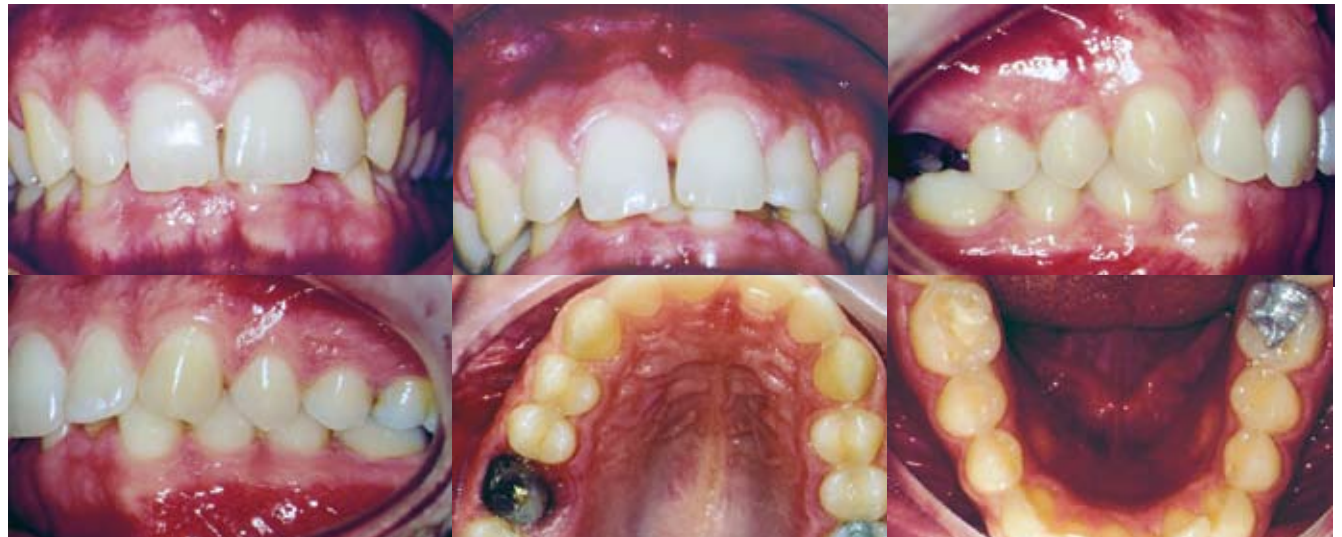To maintain the results, a fixed retention was recommended on the lower arch and a Hawley appliance with a bite plane was suggested for the upper arch. It is advisable that the patient uses them for a long period of time.

Figure 10 shows panoramic and lateral X-ray at the end of the treatment, just before debonding, where the normalization of the incisal inclination and the occlusal plane are evident.

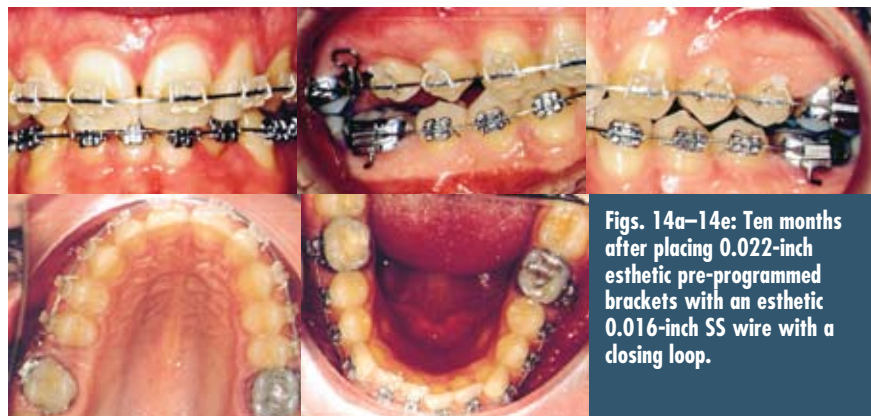
Three years later, the results continue to be stable (Figs. 11a–11e), not only from the occlusal point of view but at the gingival tissues too. At night the patient continues to use the bite plane.



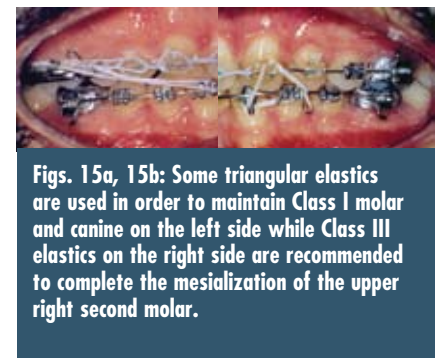
Figs. 11a–11e: Three years later, the results continue to be stable, not only from the occlusal point of view but at the gingival tissues.



Figs. 12a–12f: This is a 42-year-old patient who was in search for a second opinion regarding the correction of his anterior deepbite.



Figs. 14a–14e: Ten months after placing 0.022-inch esthetic pre-programmed brackets with an esthetic 0.016-inch SS wire with a closing loop.



Figs. 15a, 15b: Some triangular elastics are used in order to maintain Class I molar and canine on the left side while Class III elastics on the right side are recommended to complete the mesialization of the upper right second molar.

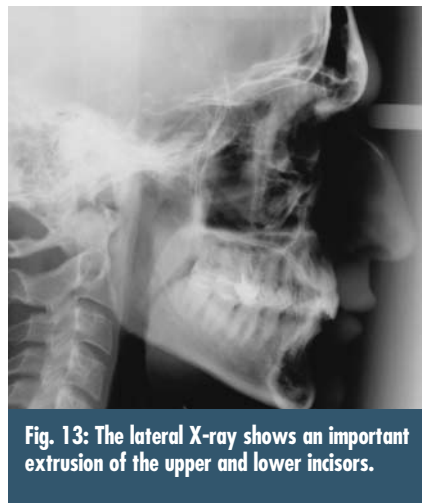


Fig. 13: The lateral X-ray shows an important extrusion of the upper and lower incisors.

We have to remember that the normalization of the position and inclination of the upper and lower incisors are critical when we have to treat these patients. To obtain a normalized anterior and posterior disocclusion, it is fundamental to maintain a healthy and long-lasting stomatognathic system.

Of course, the type of biomechanics depends on the patient's problem. It is completely different when you have to intrude the upper incisors versus the lower ones or extrude the molars in your treatment plan.

Figures 12a–12e show a 42-year-old patient who was sent in search of a second opinion regarding the correction of his anterior deepbite. He had a Class I molar and canine with

5 mm of crowding in the lower arch. His dentist advised him to have the upper right first molar extracted because it had problems with the root canal.

The overbite at the anterior region was nearly 95 percent. No gingival problems were present, and the oral hygiene was fair.

The lateral X-ray (Fig. 13) showed extrusions of the upper and lower incisors.

The treatment plan included not only the normalization of the overjet and overbite, but also the closing of the space of the upper right first molar that was extracted two months before the orthodontic treatment began.

0.022-inch esthetic pre-programmed brackets with an esthetic 0.016-inch SS wire with a closing loop were placed to begin phase one of treatment (Figs. 14a–14e).

Ten months later, a rectangular 0.016-inch by 0.022-inch SS wire with an omega loop was placed in the upper arch while pre-programmed SS brackets were placed in the lower arch.

Some triangular elastics were used in order to maintain a Class I molar and canine on the left side while Class III elastics on the right side were recommended to complete the mesialization of the upper right second molar (Figs. 15a, 15b).

Figures 16a–16e show the results

at the end of the treatment. The anterior deepbite is completely corrected. The Class I canine and molar are maintained, and on the right side the second molar occupies the space where the first molar originally was. The third molar is in the position of the second molar. Lower anterior crowding is totally corrected, and a fixed retention wire is recommended for a long period of time.

Figure 17 shows the panoramic X-ray at the end of the treatment just before debonding.

Three years later (Figs. 18a–18d), the overjet and overbite continue to be stable, but a little diastema between the upper central incisors is visible. The Class I molar and canine are maintained, and the lower retention wire is still in place.

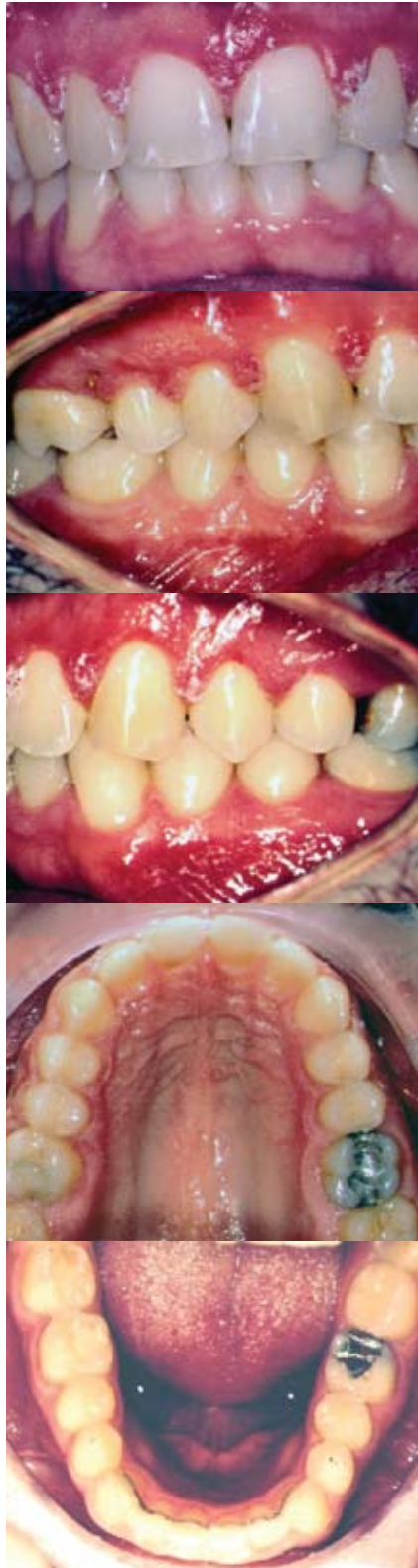### Conclusion

The treatment of deepbite in adult patients requires a careful diagnosis, prognosis, treatment and retention plan. The type of biomechanics we decide to use is determined according to the labiodental relationship the patient has when he or she is speaking and smiling.

In order to achieve objectives ahead of time, the use of new types of alloys should be considered. The amount of periodontal attachment is another determining factor when the treatment objectives are planned.

The maintenance of the results is





Figs. 16a–16e: Results at the end of the treatment.

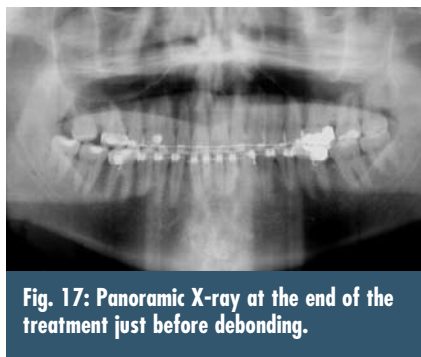
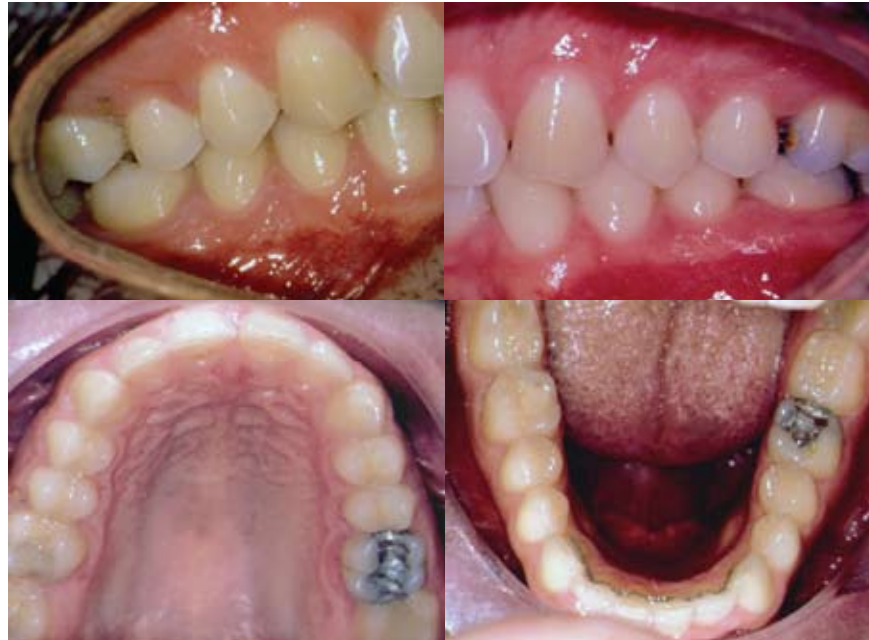
Fig. 17: Panoramic X-ray at the end of the treatment just before debonding.



Figs. 18a–18d: Control three-years later.

**OT** About the author

Prof. Dr. Julia Harfin is chairman and head of the orthodontics department at Maimónides University in Buenos Aires, Argentina, where she also is director of the post-graduate orthodontic program. She is president of the Latin American Association of Orthodontists and a member of the WFO Executive Committee. Harfin is author of “Adult Orthodontic Treatment: Editorial Médica Panamericana” and has written 15 chapters in other orthodontic books. She lectures around the world, including in Brazil, Uruguay, Chile, Perú, Paraguay, Bolivia, Colombia, Ecuador, Venezuela, the United States, Canada, Panama, Santo Domingo, Spain, Portugal, France, Egypt, Israel, Poland, Ukraine, Taiwan and Hong Kong.

AD

# HOW

[Discover your potential]

# WHO

# ORTHO II

*Efficiency comes standard* – and with Ortho II, that’s just the beginning. Our cutting edge software includes the comprehensive features you need to help grow your practice and quickly maximize profitability. With over 25 years of experience, focus, and stability, you can’t go wrong. To learn more, visit [www.orthoii.com](http://www.orthoii.com) or give us a call. We’ll show you the Ortho II difference.

## Practice Management Evolved

ORTHO II

1107 Buckeye Avenue • Ames, IA 50010  
800 678-4644 • [www.orthoii.com](http://www.orthoii.com) • © 2008

directly related to the fulfillment of the retention plan. The musculature plays an important role and affects the stability of the results.

Event though the treatment of deep overbite malocclusion in patients without growth is a challenging one, excellent results can be achieved when an individualized treatment plan is considered.

*References are available from the publisher.*

LIMITLESS MANAGEMENT • SCHEDULING • IMAGING • TREATMENT CHART • PATIENT FLOW CONTROL •

APPOINTMENT REMINDERS • PAPERLESS DOCUMENT MANAGEMENT • IN-OFFICE MESSAGING • WEB ACCESS • CEPH TRACING AND

ANALYSIS • CREDIT CARD PROCESSING • CORRESPONDENCE • COMPREHENSIVE FINANCIALS • ELECTRONIC INSURANCE •

AUTOMATIC BANK DRAFT (ACH) ACCEPTANCE • TIME CLOCK • EMPLOYEE TO-DO LISTS • FINGERPRINT RECOGNITION • ELECTRONIC

SIGNATURES • OFFSITE HOSTED BACKUPS • CUSTOM REPORTS • AUTOMATED UPDATES • MULTIPLE INTEGRATIONS