

# DENTAL TRIBUNE

The World's Dental Newspaper • India Edition

PUBLISHED IN INDIA

www.dental-tribune.com

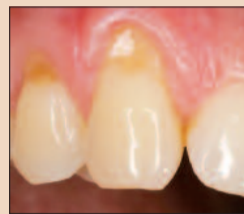VOL. 2 No. 2

## News in brief

### Genes control early tooth development

Several genes affect tooth development in the first year of life, according to the study conducted at the Imperial College London, the University of Bristol, & the University of Oulu in Finland. The research found that the babies' teeth with certain genetic variants tend to appear later & that these children have a lower number of teeth by the age of one. In addition, those children whose teeth develop later have a 35 percent increased likelihood of requiring orthodontic treatment.

Some of the genes identified have been linked, in previous studies, with the development of the skull, jaws, ears, fingers, toes, and heart. The discovery may lead to innovations in the early treatment and prevention of congenital dental and occlusion problem.



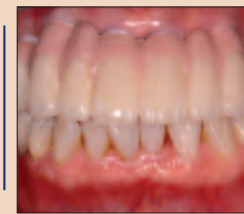**Trends & Applications**  
Does dentine hypersensitivity affect oral health-related quality of life?

▶ Page 4



**Interview**  
"Evolution of mini-implants"

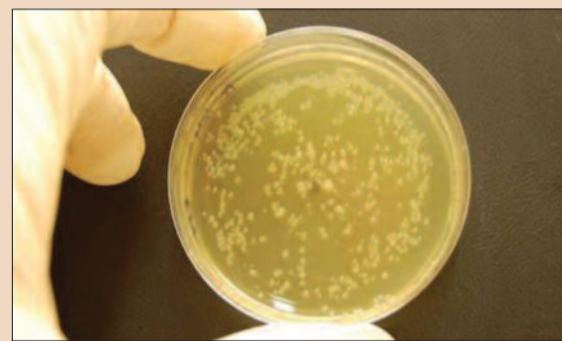
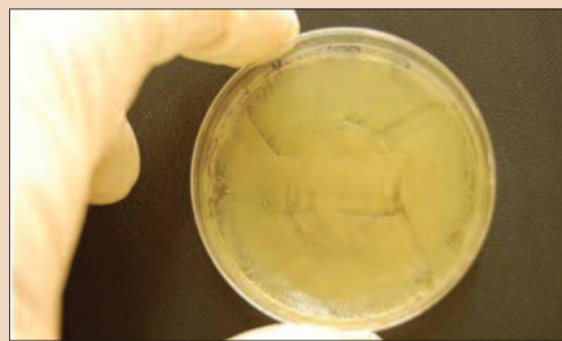
▶ Page 12



**Technology**  
CAD/CAM-fixed prosthesis

▶ Page 22

## Prozone confirms effectiveness of ozone dental therapy



These pictures show agar plates with bacterial strain *Escherichia coli*. The left plate was treated with Prozone for 24 seconds and shows areas that are visibly bacteria-free. (DTI/Photo courtesy of Salzburg University, Austria)

Daniel Zimmermann  
DTI

**LEIPZIG, Germany:** Clinical tests from the Department of Molecular Biology at the University of Salzburg in Austria have confirmed that dental treatment with Prozone, a next-generation ozone generator by Austrian manufacturer W&H, is highly effective against bacteria strains that are responsible for orodental infections and the development of dental caries. In the control study conducted in

2009, samples of *Streptococcus mutans* and *Escherichia coli* were gassed immediately and after 1.5 hours with ozone for 24 seconds and several times.

The results demonstrated that treatments with 24 seconds ozone had visible effects on the treated area. In all tests immediate treatment was more effective than treatment after 1.5 hours. When the duration of the treatment was increased, the areas which contain no bacteria or

have a low bacterial count also increase.

W&H's ozone generator has been available to dentists worldwide since 2008. Despite its sterilizable ergonomically hand-piece, it features preset predefined treatment times which make it easy to manage, the company states. Prozone is suitable for a wide range of dental applications including cavity and surgical disinfection as well as periodontal and endodontic

treatment. Treatment with ozone, a reactive three-oxygen molecule also found in earth's atmosphere, is a relatively new concept in dentistry. Earlier studies indicate that it only takes a few seconds of therapy to kill 99 percent of bacteria making it a thousand times more powerful than other bacteria killing agents. The new study shows that in order to reach the total potential, treatment has to be performed immediately. Delayed treatment also results in reduced bacteria count but the visible effects are less significant.

Devices utilizing ozone technology such as Prozone expose filtered air to a highly electrical voltage which is directly applied to the treatment area where it destroys bacteria and viruses through oxidation. [DTI](#)

Dental Tribune  
The World's Dental Newspaper  
India Edition

Published by

JAYPEE BROTHERS  
MEDICAL PUBLISHERS (P) Ltd.

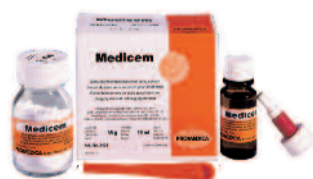## PROMEDICA

Highest quality made in Germany

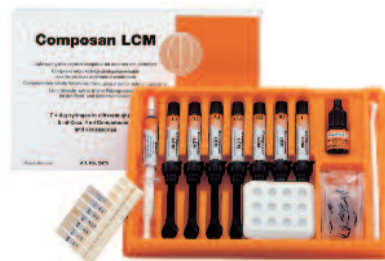All our products convince by

- ▶ excellent physical properties
- ▶ easy handling
- ▶ perfect aesthetical results
- ▶ more information:

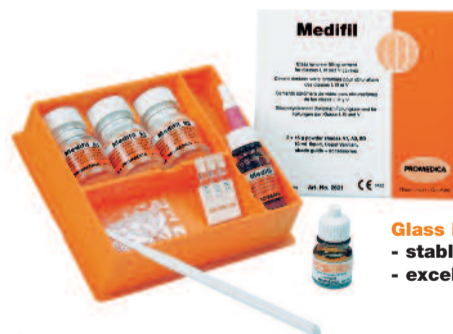[www.promedica.de](http://www.promedica.de)



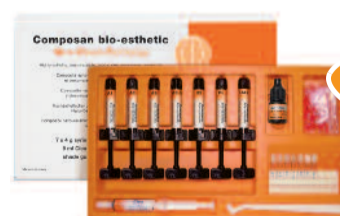**Glass ionomer luting cement**  
- very low film thickness  
- perfect occlusal accuracy



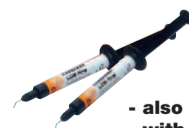**Light-curing micro-hybrid composite**  
- excellent handling facilities  
- universal for all filling classes



**Glass ionomer filling cement**  
- stable and abrasion resistant  
- excellent durable esthetics



**Light-curing nano-ceram composite**  
- highly esthetic and biocompatible  
- universal for all cavity classes  
- comfortable handling, easy modulation  
- also available as flow version



- also available as flowable version  
- with good flow and wetting capability

**PROMEDICA Dental Material GmbH**

Tel. + 49 43 21 / 5 41 73 · Fax + 49 43 21 / 5 19 08

Internet: <http://www.promedica.de> · eMail: [info@promedica.de](mailto:info@promedica.de)

PROMEDICA

## News in brief

**No more dental colleges in the country**

The Dental Council of India (DCI) has decided not to sanction new dental colleges, anywhere in the country for the next five years, to regulate dental education and the dental profession. This announcement was made by DCI chief Dr Anil Kohli, who was in Mangalore to attend the silver jubilee celebration of A B Shetty Memorial Institute of Dental Sciences.

"It is imperative to maintain quality in every sphere of life," Dr Kohli said. "The field of medical sciences assumes far greater importance than ever before in this age of change," he said, adding that "preserving quality of education is of paramount importance." "Rather than sanctioning new dental colleges, DCI will focus its energy on ensuring that quality dental education is imparted to students in existing dental colleges in India," he added.

**Indigenous implants will be a lot cheaper**

A report, published in *The Times of India* says that the Maulana Azad Institute of Dental Sciences (MAIDS), under the New Millennium Indian Technology Leadership Initiative by the Ministry of Science and Technology, has successfully developed a new indigenous dental implant, which will cost between Rs 2,000 and 5000.

Dr Mahesh Verma, principal investigator of the project, said that a team of doctors, from MAIDS, conceptualized & designed the outline for the implant which has been fabricated by IIT Delhi engineers. "Five human trials of the indigenous implant, fabricated in India, have been successfully completed," he added. The micro CT analysis, to assess the percentage and quality of osseointegration of implant in the trial, conducted on rabbits was done at Trivandrum-based research institute have also shown positive results.

The dental implants, imported from countries like US and Israel, cost up to Rs 20,000. The indigenous implants are expected to provide a cheaper solution to wider loser implants in India.

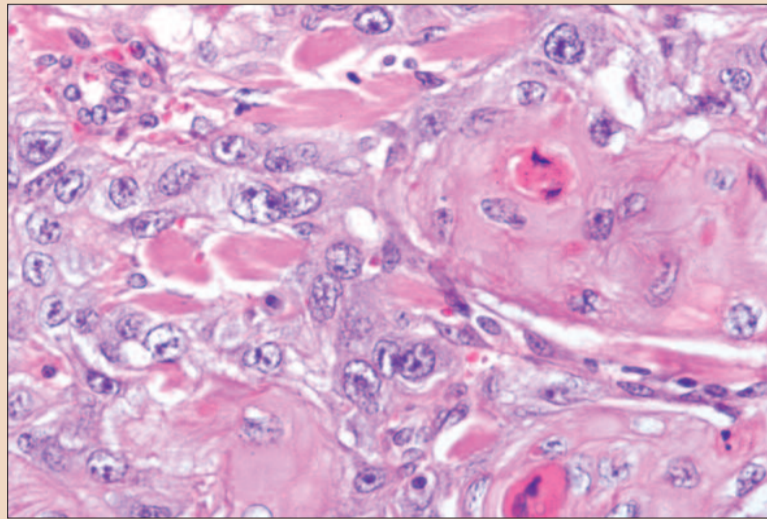
**Nano-Bio-Chip detects oral cancer**

Photo courtesy of Textbook of Oral Pathology by Harsh Mohan.

Isha Goel  
DT India

**New Delhi, India:** A team of scientists at the Bio Science Research Collaborative, at Rice University, in Houston, US, has developed a nano-bio-chip (NBC) sensor technique that analyzes specimens from brush biopsies of lesions to detect oral cancer. The nano-bio-chip integrates multiple laboratory processes into

a single microfluidic platform: cell separation/capture on the membrane filter, biomarker immunolabeling and cytochemical staining, and fluorescent imaging and analysis. According to this pilot study, published in the *Journal Cancer Prevention Research*, the researchers compared results of traditional diagnostic test, and those obtained with the NBC, to find that the

diagnostic NBC had comparable success rate with 97 percent sensitivity in detecting oral cancer, and 95 percent specificity in detecting which patients had malignant or premalignant lesions. The device will undergo a more extensive clinical trial involving 500 patients in Houston, San Antonio, and the U.K., which could lead to an application for FDA approval in two to five years.

Oral cancer is among the ten most common cancers worldwide with a high mortality rate. According to a WHO survey report, India has the highest number of oral cancer cases in the world, out of which 90 percent were due to tobacco related diseases, leading to 2,200 deaths each day. The 5-year survival rate of 50 percent, among patients with oral cancer, has remained unchanged for

the past 50 years as most cases are diagnosed in the advanced stages.

This minimally invasive procedure requires just a little brush of the lesion with a toothbrush-like instrument instead of an invasive, painful biopsy, and can deliver results with in 15 mins. "One of the key discoveries in this paper is to show that the miniaturized, noninvasive approach produces about the same result as the pathologists do," study leader John McDevitt said in a statement.

The Rice University has received a US \$2 million grant from the National Institute for Dental & Craniofacial Research Division of the National Institutes of Health for their work. □

**Brain unable to localise tooth pain**

Claudia Salwiczek  
DTI

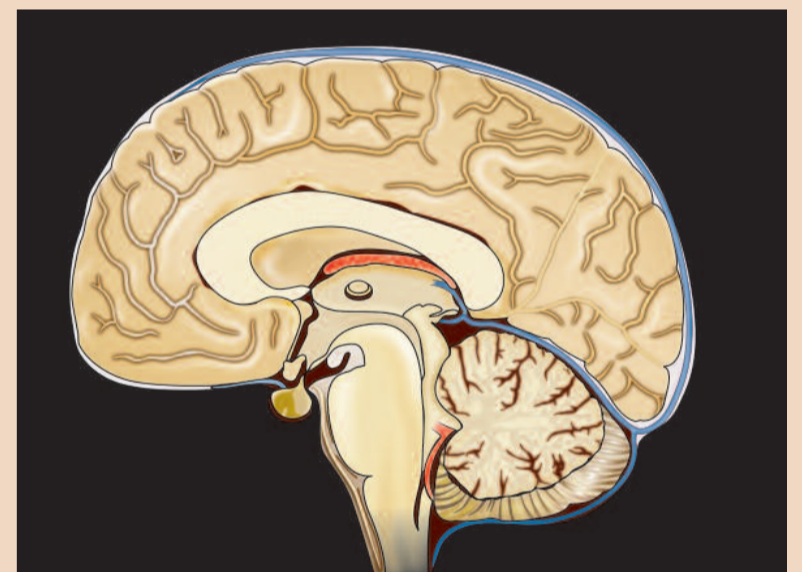**ERLANGEN/LEIPZIG, Germany:** The brain is not able to discriminate between a painful upper tooth and a painful lower tooth, researchers found. The results of a new imaging study, which will be published in the journal *Pain*, may help devise better treatments for acute tooth pain, such as cavities or infections, and more chronic conditions like phantom pain of a tooth after it has been removed.

The researchers led by Prof Clemens Forster of the University of Erlangen-Nuremberg in Germany analysed the brain activity in healthy volunteers as they experienced tooth pain. By delivering short electrical pulses to either the upper left or the lower left canine tooth, a painful sensation similar to that felt when biting into an ice cube was triggered. To see how the brain responds to pain emanating from different teeth, the researchers used functional magnetic resonance imaging (fMRI) to monitor changes in activity when the upper or the lower tooth was stimulated.

"At the beginning, we expected a good difference, but that was not the case," Forster stated.

Many brain regions responded to top and bottom tooth pain—carried by signals from two distinct branches of a fibre called the trigeminal nerve—in the same way. The maxillary branch (V2) carries pain signals from the upper jaw, and the mandibular branch (V3) carries pain signals from the lower jaw.

The researchers found that regions in the cerebral cortex, including the somatosensory cortex, the insular cortex and the cingulate cortex, all behaved similarly for both toothaches. These brain regions are known to play important roles in the pain projection system, yet none showed major differences between the two toothaches. "The activation was more or less the



same," Forster said, although, he added, "their experiments might have missed subtle differences that could account for why some tooth pain can be localised."

Because the same regions were active in both toothaches,

the brain—and the person—couldn't tell where the pain was coming from. "Dentists should be aware that patients aren't always able to locate the pain", Forster says. "There are physiological and anatomical reasons for that." □

**International Imprint****DENTAL TRIBUNE**

The World's Dental Newspaper • India Edition

Published by Jaypee Brothers Medical Publishers (P) Ltd., India

©2010, Dental Tribune International GmbH. All rights reserved.

Dental Tribune India makes every effort to report clinical information and manufacturer's product news accurately, but cannot assume responsibility for the validity of product claims, or for typographical errors. The publishers also do not assume responsibility for product names or claims, or statements made by advertisers. Opinions expressed by authors are their own and may not reflect those of Dental Tribune International.

Publisher  
Torsten Oemus  
t.oemus@dental-tribune.com

Chairman DT India  
Jitendar P. Vij  
jaypee@jaypeebrothers.com

Director  
P. N. Venkatraman  
venkatraman@jaypeebrothers.com

Chief Editor  
Dr. Naren Aggarwal  
naren.aggarwal@jaypeebrothers.com

Editor  
Dr. Isha Goel  
isha.goel@jaypeebrothers.com

Editorial Consultants  
Dr. Gurkeerat Singh  
Dr. Amit Garg

**Dental Tribune India**  
Published by: Jaypee Brothers Medical Publishers (P) Ltd.  
4858/24, Ansari Road, Daryaganj,  
New Delhi 110002, India  
Phone: +91 11 45574357  
e-mail: jaypee@jaypeebrothers.com  
Website: www.jaypeebrothers.com

# IDEM confirms role as major APAC meeting

Organiser announces plans for 2012/More variety in the scientific programme

Daniel Zimmermann  
DTI

**SINGAPORE/LEIPZIG, Germany:** With final participation numbers having been announced, the International Dental Exhibition and Meeting (IDEM) confirmed its position as a major dental meeting for the Asia Pacific region. An improved scientific programme & a higher number of exhibitors again drew more than 6,000 dental professionals to Singapore. Exhibitors and the organiser said that they were satisfied with the number and type of visitors this year.

IDEM, which is organised by Koelnmesse Singapore Ltd, is held biannually in cooperation with the Singapore Dental Association and the FDI World Dental Federation.

This year's scientific programme focused on implantology and aesthetics—two of the most successful sectors in the Asia Pacific dental market. Although sales figures were significantly



Singapore's Health Minister Khaw Boon Wan (third from left) pays a visit to IDEM 2010. (DTI/Photo courtesy of Koelnmesse)

affected by the global financial crisis in 2008/09, growth rates are expected to pick up once the economy begins to recover, a May 2009 industry report stated. According to the same report, sales figures of dental implants in the Asia Pacific region experienced doubledigit growth rates back in 2008.

Implantology was a significant part of this year's trade

exhibition, which saw increased numbers of dental surgical equipment and bone-grafting tools to aid dental implant procedures on display. Besides classical equipment like instruments, units or fillings, digital dentistry specialists also presented 3-D imaging systems that aim to streamline communication between dentists and laboratories, and thus improve long-term treatment outcomes.

For the first time, manufacturers from the republics of Slovenia & Colombia showcased their portfolio in Singapore. The British Dental Trade Association hosted their first national pavilion at the show alongside trade participations from Australia, Taiwan, Singapore, Korea, France and Switzerland. The US and German dental industry were the most well represented, with more than 20 companies

representing all sectors in dentistry.

Michael Dreyer, Vice-President Asia Pacific of Koelnmesse Pte Ltd, told Dental Tribune Asia Pacific that despite organisational changes and the economic downturn, IDEM 2010 was in line with IDEM 2008. He said that his company will aim to improve the meeting further in order to make it available to further professional groups like dental assistants.

Singapore Dental Association President Dr Lewis Lee said that the decision to hold pre-congress courses and master classes this year was well received by most congress attendees. He announced plans to broaden the scientific programme in 2012, incorporating more topics like dental materials, orthodontics or oral medicine. A larger number of hands on workshop will be offered as well, he added.

→ DT page 6

## Dentists crucial for detecting mouth breathing symptoms

Daniel Zimmermann  
DTI

**NEW YORK, USA/LEIPZIG, Germany:** Medical and dental problems associated with mouth breathing often go unnoticed by health professionals, a new study from the US suggests. The habit, which is caused by abnormalities of the upper respiratory tract, usually occurs in spring when many people suffer from pollen and seasonal allergies. Dentist are advised to regularly check for mouth breathing symptoms and swollen tonsils especially in children as young as 5 years of age, the author recommends.


If untreated, mouth breathing can cause a wide range of medical issues such as poor oxygen concentration in the blood, high blood pressure or sleep apnoea. In addition, it has been found to be responsible for abnormal facial growth primarily in the upper and lower jaw shape of children, leading to

Long Face Syndrome, gummy smiles or other malocclusions. Moreover, poor sleeping habits that result from the condition can adversely affect growth and academic performance.

Dentists may be the first to identify the symptoms of mouth breathing, as they typically request that their patients return every six months, which means that some people see their dentist more frequently than they see their physician.

Treatment for mouth breathing can be beneficial for children's medical and social conditions if caught early. Swollen tonsils and adenoids can be surgically removed by an ear-nose-throat specialist & dentists can use expansion appliances to help widen the sinuses and open nasal airway passages if the face and mouth are narrow. DT

### In Pericoronitis / Tooth Abscess<sup>1</sup>



Rx

# BIDANZEN<sup>®</sup> FORTE


Serratiopeptidase Tablets 10 mg

## OPENS WAY FOR SPEEDY HEALING

- Significantly reduces post-surgical cheek swelling and pain<sup>2,\*</sup>

\* Dosed along with 1000 mg of paracetamol in surgical extraction of 3<sup>rd</sup> molar.  
 Ref. 1. Prescribing Information Bidanzen, India  
 2. Al-Khateeb TH, Nusair Y. Effect of the proteolytic enzyme serrapeptase on swelling, pain and trismus after surgical extraction of mandibular third molars. Int J Oral Maxillofac Surg. 2008 Mar;37(3):264-8.

**BIDANZEN & BIDANZEN FORTE : Abbreviated Prescribing Information:**  
 Active Ingredient: Enteric film coated tablets containing Serratiopeptidase 5 mg (10,000 units) and 10 mg (20,000 units) respectively. Indications: Remission of swelling after operation, trauma, chronic sinusitis and galactostasis; Difficulty to expectorate (bronchitis, pulmonary tuberculosis, bronchial asthma, post anesthesia); pericoronitis of wisdom tooth, alveolar abscess; cystitis.  
 Dosage and Administration: **Adults:** Daily dose of 15-30 mg orally, in 3 divided doses after each meal, appropriately adjusted according to patient's age and symptom. **Children:** One 5 mg tablet 2-3 times daily after meals, depending on degree of severity of disease. Contraindications: Hypersensitivity. Warnings and Precautions / Interactions / Effects on Ability to drive and Use machines / Pregnancy and Lactation: No specific data available. Adverse Reactions: Skin - Stevens-Johnson syndrome, toxic epidermal necrolysis, rash, pruritus; Hypersensitivity - Shock, anaphylactic symptoms; Hepatic - Hepatitis, jaundice.



GlaxoSmithKline  
 Refer to full prescribing information before use.  
 For full prescribing information please contact : GlaxoSmithKline Pharmaceuticals Ltd., Dr. Annie Besant Road, Worli, Mumbai 400 030.  
 © Registered Trademark

For the use only of a registered medical practitioner or a hospital or a laboratory  
 BDZ090905

# Does dentine hypersensitivity affect oral health-related quality of life?

Dr Katrin Bekes  
Germany

Dentine hypersensitivity is an oral complaint frequently reported in clinical dental practice. While many individuals do not seek treatment to desensitise their teeth because they do not perceive dentine hypersensitivity to be a severe oral health problem, a substantial number of patients experience discomfort to the extent that it interferes with their eating, drinking, oral hygiene habits and sometimes even breathing. These symptoms often have a considerably adverse impact on their daily quality of life (QoL). This article reviews the impairments of oral health related quality of life in patients seeking care for dentine hypersensitivity.

Traditionally, dentists have been trained to recognise & treat oral diseases & to describe them by using dental indices. Dental indices provide a quantitative method for measuring, scoring, and analysing dental conditions in individuals and groups. They describe the status of individuals or groups with respect to the condition being measured. However, important as these objective measures are, they only reflect the end-point of the disease processes. They give no indication of the impact of the disease process, especially oral disorder, on function or psychosocial well being, and only provide little insight into the impact on daily living and QoL.

Therefore, QoL research in medicine & dentistry has attracted increasing attention over the past years. QoL is defined as an individual's perception of his or her position in life, in the context of the culture and value systems in which he or she lives and in relation to his or her expectations, goals and concerns. QoL has multiple dimensions (such as cultural factors, social integration, socioeconomic status, quality of environment and personal autonomy). One dimension of QoL is health. The real impact of health and disease on QoL is known as health related quality of life (HRQoL). Oral health related quality of life (OHRQoL) is that part of HRQoL that focuses

on oral health and orofacial concerns (Fig. 1). The concept of OHRQoL facilitates studying the impact of a disease on a person's total oral health because it can be used across conditions. It describes the way in which oral health affects a person's ability to function, his or her psychological status, social factors and pain or discomfort.

## How to measure OHRQoL

OHRQoL is a multidimensional construct that cannot be observed directly. It needs to be visualised by means of suitable indicators. In order to comprehend a construct like this, target persons, that is patients, have to be asked pertinent questions. For example, some questions focus

handicap. Examples of some OHIP questions are:

- Have you had trouble pronouncing words because of problems with your teeth, mouth or dentures?
- Have you found it uncomfortable to eat any foods because of problems with your teeth, mouth or dentures?
- Have you felt that your sense of taste has worsened because of problems with your teeth, mouth or dentures?

For each of the 49 OHIP questions, subjects are asked how frequently they have experienced the oral problem. Responses are according to a Likert-type scale: 0 = never, 1 = hardly ever, 2 = occasionally, 3 = fairly often, and 4 = very often.

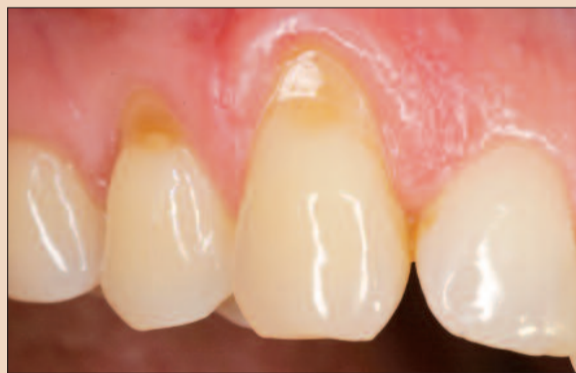

Fig. 1. OHRQoL is one dimension of quality of life.

on function, some are concerned with pain and discomfort, and others evaluate self-image and social interaction. The Oral Health Impact Profile (OHIP) is amongst the most widely used instrument in studies evaluating OHRQoL. It attempts to measure both the frequency and severity of oral problems on functional & psychosocial well being. This tool was developed by Slade and Spencer in Australia in 1994.

The OHIP is a 49-item measure, with statements grouped into seven theoretical domains, namely functional limitation, pain, psychological discomfort, physical disability, psychological disability, social disability and

A summary score of between 0 & 196 results from the 49 questions, with 5 scoring steps each, which provides a good impression of the extent to which OHRQoL is affected. A score of 0 indicates the absence of any oral health related problem. Higher scores represent an OHRQoL that is more impaired. The most extensive impairment of the OHRQoL is expressed by a score of 196. This is termed the problem index and demonstrates that all oral problems are frequently encountered. A table of standard values representative of different populations is provided, according to which the patient's score can be compared and evaluated.

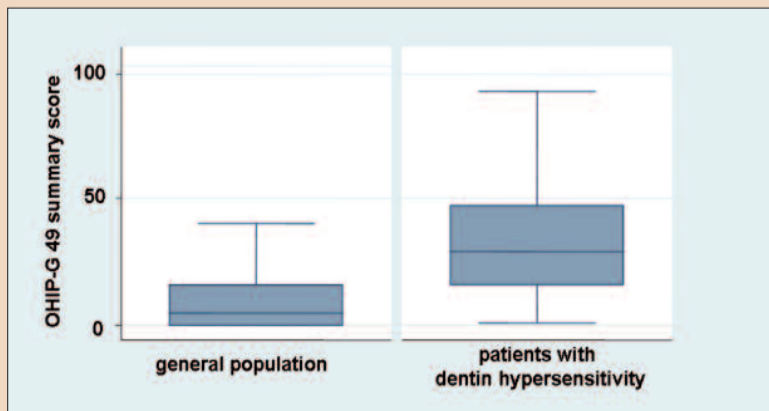


Fig. 5. Differences in OHRQoL measured with the OHIP questionnaire in patients with dentine hypersensitivity and in a general population sample.

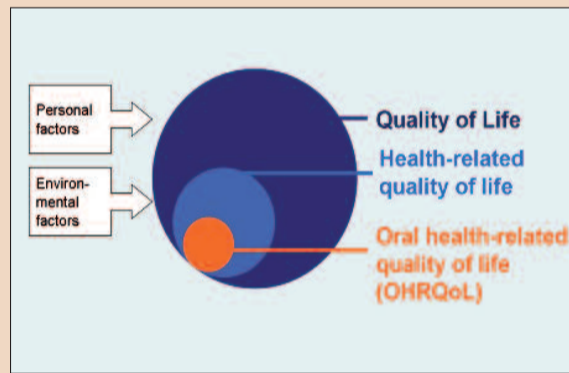


Fig. 2. Hypersensitive cervical dentine surfaces.

To be able to assess levels of OHRQoL in non-English speaking populations, cross-culturally adapted translations of the original English-language version of the OHIP into Chinese, Dutch, Hungarian, Italian, Japanese, Portuguese, Spanish & Swedish has been achieved in several countries. The demand for an internationally comparable German tool led to the development of a German version of the OHIP (OHIP-G), which determines the OHRQoL of German speaking persons. OHIP-G includes the 49 items of the English original, as well as four additional items that were regarded as important for the German population specifically. OHIP-G can be applied to patients of 16 years and older.

## OHRQoL in patients seeking care for dentine hypersensitivity

Dentine hypersensitivity is a common oral complaint that is frequently reported in dental practice. It is characterised by a short and sharp pain arising from exposed dentine and occurring in the presence of thermal, chemical, tactile or osmotic stimuli (Fig. 2). From the relatively few studies that investigate the prevalence of dentine hypersensitivity, it can be concluded that it is a frequent condition. Studies have reported a prevalence of dentine hypersensitivity in the adult dentate population ranging from 4 to 57 per cent. However, figures as high

as 60 to 98 per cent have been reported in patients with periodontitis. While many individuals do not seek treatment to desensitise their teeth because they do not perceive dentine hypersensitivity to be a severe oral health problem, 10 to 25 per cent of patients experience discomfort to the extent that it interferes with their eating, drinking (hot & cold beverages), oral hygiene habits and sometimes even breathing. The degree of discomfort depends on individual pain perception, pain tolerance, and emotional and physical factors. These symptoms are highly relevant from the patient's point of view and often have a considerably adverse effect on daily QoL.

A study was conducted at the Martin Luther University, Halle-Wittenberg, Germany to describe and evaluate OHRQoL in patients with dentine hypersensitivity. Data was collected through a questionnaire as part of a larger study targeting several areas of oral health beyond hypersensitive teeth, such as oral hygiene, prevention efforts, and oral behaviours and habits.

There were 724 patients (mean age:  $42.8 \pm 13.0$  years) who participated in the study, presenting at 161 German dental offices because of hypersensitive teeth and reacting positively to an air stimulus applied by the dentist. Patients with removable partial dentures & patients with missing answers in the OHIP questionnaire were excluded. After these exclusions, 656 patients remained in the study for analysis. These patients were compared with 1,541 subjects without removable partial dentures from a national, general German population sample (mean age:  $57.7 \pm 15.4$  years). OHRQoL was assessed using OHIP-G. The patients completed the OHIP-G questionnaire in the dental office.

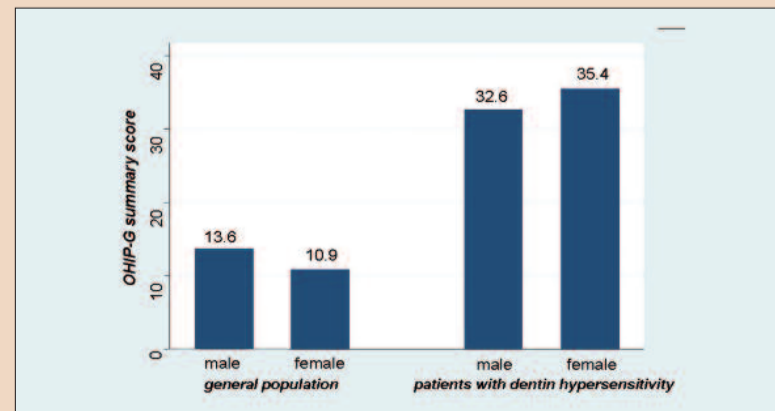


Fig. 4. OHRQoL in patients with dentine hypersensitivity and in a general population grouped by gender.



# The legacy of a lifelong bond continues... with Sun Medical

*Pierre Fauchard*  
Father of Modern Dentistry

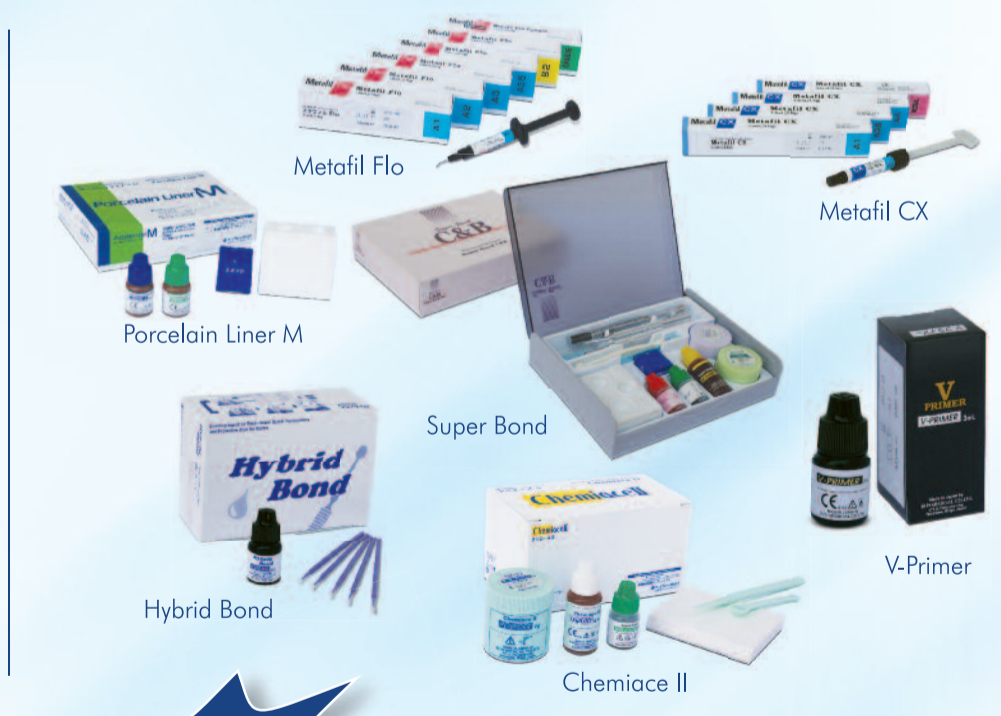*“Considering the circumstances and limitations of his era, he will always be remembered as a pioneer and as someone who was always ahead of his time.”*

We at **Sun Medical** started our journey from where he left. His revolutionary approaches for teeth restoration inspired us to forward this golden dental excellence in today's time through our research based and innovative dental materials.

**Sun Medical, the future of modern restorative dentistry.**

### Presenting Futuristic Dental Care in India

- ⊙ **Super Bond** – Dental adhesive system with 4-META/MMA-TBB
- ⊙ **Hybrid Bond** – Bonding agent for resin-based dental restorations and protective coat for dentin
- ⊙ **Chemiace II** – 4-META adhesive resin cement
- ⊙ **Metafil Flo** – Hybrid resin-based dental restorative material
- ⊙ **Metafil Cx** – Composite resins with TMPT fillers chemically bonded to matrix
- ⊙ **V-Primer** – Adhesive Primer for metals /precious metals
- ⊙ **Porcelain Liner M** – Adhesive Primer for Porcelain Bonding



Visit us at  
**Stall No. B-14**  
at Famdent show, Mumbai

**A Sincere  
Company**

**Sun Medical is one of the strongest dental adhesives manufacturing companies in the world.**



The OHIP-G summary score characterised the OHRQoL construct as a whole. The OHIP-G summary score of patients with hypersensitive teeth was 34.5 ( $\pm 22.6$ ), while the general population sample had a score of 12.2 ( $\pm 18.4$ ). The 22.3 difference was statistically significant. The general population subjects had an OHIP-G median score of 5, while the patient group had an OHIP-G median

score of 30 (Fig. 5). Ten percent of the subjects with the highest OHI P-G summary scores had scores of 36 (general population) and 66 (patients).

Differences according to gender were minimal. Although the difference between gender of a mean 2.8 points was statistically significant ( $p < 0.01$ ), it was regarded as negligible. Amongst the patient group,

women reported more problems with the condition of dentine hypersensitivity than men, which is in contrast to the general population, in which men had higher OHIP scores than women (Fig. 4).

### Conclusions

QoL has been established as an important outcome for evaluating the impact of a disease and for assessing the efficacy

of treatment. The impact of oral disorders and interventions on patients' perceived oral health status and OHRQoL is increasingly recognised as an important component of health. Dentine hypersensitivity is a frequent problem that can be observed in adults of all ages. In this study, patients with sensitive teeth reported substantial OHR QoL impairment, which may have an influence

on whether or how patients should be treated. The extent of this effect is comparable to that of other oral diseases and conditions, such as temporomandibular disorders. The present investigation is the first study that evaluates the impact of this condition using a widely used patient-centred outcome measure to characterise the broader influence of this condition on patients' perceived oral health.<sup>[4]</sup>

## 8th World Congress on Oral Implantology & AAID Global Conference - 2010

Theme : Engineering for Success in Implant Dentistry - Revision & Renewal Procedures

20-22 November 2010

Hotel Le-Meridien New Delhi, INDIA

Meet the **Masters** &  
magnificent opportunity to know recent trends in  
**Dental Implants**

### About the author



**Dr Katrin Bekes** is Assistant Medical Director at the Department of Operative Dentistry and Periodontology, University School of Dental Medicine, Martin Luther University Halle-Wittenberg, Halle/Saale Germany. She can be contacted at [katrin.bekes@medizin.uni-halle.de](mailto:katrin.bekes@medizin.uni-halle.de).

← DT page 3

Delegates that joined the first pregress sessions on Thursday morning confirmed that the programme was a large improvement to the offerings in 2008. Most of the people interviewed said that because of these changes they were able to attend most of the sessions held during the course of the meeting. "I think the congress was pretty well organised and there was less overlapping which made it easier to get into more sessions," said one dentist from Singapore.

According to Mr Dreyer, preparations for the next edition of IDEM in 2012 have already begun and the first speakers have been announced. Amongst others, there will be sessions on the management of endodontic disasters, the biological effects of current restorative materials on the pulp-dentine complex and current concepts on posts and cores.

The next meeting is scheduled to be held 20-22 April 2012.<sup>[4]</sup>



online registrations are open  
[www.wcoiindia2010.com](http://www.wcoiindia2010.com)

## REGISTRATION FORM

Paste your  
recent picture  
here

### A. PARTICIPANT INFORMATION (Please write in capital letters)

#### Personal Information

Title  Dr.  Prof.  Mr.  Ms.

First Name \_\_\_\_\_

Middle Name \_\_\_\_\_

Last Name \_\_\_\_\_

Tel. \_\_\_\_\_ Mobile \_\_\_\_\_

E-mail \_\_\_\_\_ Fax \_\_\_\_\_

Designation \_\_\_\_\_

Organization \_\_\_\_\_

#### Mailing Address

Address \_\_\_\_\_

\_\_\_\_\_

City / State \_\_\_\_\_

Postal Code \_\_\_\_\_ Country \_\_\_\_\_

#### Accompanying Person(s)

Mr.  Ms.  First Name \_\_\_\_\_ Last Name \_\_\_\_\_

Mr.  Ms.  First Name \_\_\_\_\_ Last Name \_\_\_\_\_

### B. REGISTRATION FEES

#### Congress Registration

Categories	Upto 31 Aug 2010	Upto 15 Oct 2010	Spot Registration
International Delegate	250 USD	295 USD	350 USD
Indian Delegate	7500 INR	8500 INR	9500 INR
Student	6500 INR	7500 INR	NA
Accompanying Person	7000 INR	8000 INR	9000 INR
Accompanying Person Overseas	225 USD	270 USD	325 USD
AAID Maxicourse Aluminous	7000 INR	8000 INR	9000 INR

#### Accompanying Person(s) Registration

US\$ / INR (Upto 31st Aug 2010) x \_\_\_\_\_ person(s) = US\$ / INR \_\_\_\_\_

US\$ / INR (Upto 15th Oct 2010) x \_\_\_\_\_ person(s) = US\$ / INR \_\_\_\_\_

US\$ / INR (Spot Registration) x \_\_\_\_\_ person(s) = US\$ / INR \_\_\_\_\_

Total = US\$ / INR

\* In training attendees (Medical Student, interns, residents and fellows) must provide a written verification on official letter signed by their program director.

### C. PAYMENT

#### Demand Draft

(in favor of 8th WCOI and AAID Global Conference 2010 payable at New Delhi)

Demand Draft No. \_\_\_\_\_

Dated \_\_\_\_\_

Amount \_\_\_\_\_

Drawn on Bank \_\_\_\_\_

#### Mail Form to Congress Secretariat

Prof. (Dr.) Mahesh Verma  
Director-Principal  
Maulana Azad Institute of Dental Sciences  
MAMC Complex, Bahadur Shah Zafar Marg, Delhi, India  
Email : [wcoidelhi@gmail.com](mailto:wcoidelhi@gmail.com)  
Phone : + 91-11-23233925  
Fax : + 91-11-23217081

#### For office use only

Date Received \_\_\_\_\_

Person Received \_\_\_\_\_

Receipt No. \_\_\_\_\_

Registration No. \_\_\_\_\_

#### CONFERENCE MANAGER

**SUMMIT-Alpcord Network**,  
A - 422/423, Somdutt Chamber 1,  
Bhikaji Cama Place, New Delhi  
E-mail : [summit@alpcord.net](mailto:summit@alpcord.net),  
[event.alpcord@gmail.com](mailto:event.alpcord@gmail.com)  
Website : [www.conferenceindia.in](http://www.conferenceindia.in)  
Phone : +91-11-26165026 / 41658517  
Fax : +91-11-26165024

# A case report: Unusual anatomy of maxillary second molar

Dr P D Joshi  
India

## Introduction

The main objectives of an endodontic treatment are the elimination of microorganism from the root canal system and prevention of subsequent reinfection of the system.<sup>1</sup> Inability to find and properly treat the canal may cause failure.<sup>2</sup>

This case report presents an unusual maxillary right second molar with four roots (mesiobuccal, distobuccal, mesio-palatal, and distopalatal). The unusual morphology of roots of the maxillary second molar may be a challenge in diagnosis and treatment execution.<sup>3-5</sup>

Diamond, in his textbook on dental anatomy, has shown two cases of maxillary first molars with two distinct palatal roots.<sup>6</sup>

Sabala, et al, in a radiographic survey, found that the most common aberration of maxillary molars involved the fusion of 22 percent of the facial roots of second molars.<sup>7</sup> They discovered that aberrations occurred in less than 1 percent of the cases and that of 90 percent of such aberrations were bilat-

eral. Libfeld and Rostein also examined 1200 teeth radiographically, and reported that four rooted maxillary second molars occurred in 0.416% of cases.<sup>8</sup> The four roots in maxillary molar is more frequent in second molars, the conclusion made by Christie, et al.<sup>9</sup>

This case report illustrates the importance of knowledge about unusual variations in morphology of root and canal, proper access opening, gaining straight line access, proper cleaning and shaping of canals, and obturation.

## Case report

A 34-year-old female reported to the clinic with the chief complaint of pain in relation to upper left back tooth region since two days, and pain usually occur after stimulation with hot and cold liquids. The patient gave the history of pain getting worse on lying down, and waking up with pain in the middle of the night. The clinical examination showed a large carious lesion on the buccal surface of the maxillary left second molar (#27). Vitality test with cold stimulant revealed severe, rapid, and long-lasting pain from maxillary left second molar. Pre-operative periapical radi-

ograph revealed a large carious lesion on buccal surface of #27 involving the pulp (Fig. 1). Based on clinical and radiographical evidence, it was diagnosed as irreversible pulpitis.

The careful observation of periapical radiograph shows that the second molar has unusual root morphology, i.e., it has four separate roots. The unusual two separated palatal roots are long and diverging like horns.

The non-surgical endodontic therapy was planned for tooth #27. The treatment was started with administration of local anesthesia using 2% lignocaine with 1:200000 adrenaline. Caries was removed, and then the missing buccal surface of the tooth was build up using glass ionomer cement fuji type II, to facilitate the isolation of tooth using Rubber Dam (Hygienic Corp., USA).

A usual triangular access cavity (Fig. 2) was modified to square-shaped (rhomboidal) (Fig. 3) using cavity access set (by Dentsply Maillefer, Ballagues), and was further refined with tip #2 of Start X ultrasonic kit (by Dentsply Maillefer, Ballagues) (Fig. 4). After access opening, the four orifices were explored,

namely mesiobuccal (MB), distobuccal (DB), mesio-palatal (MP), and distopalatal (DP). Two distinct palatal orifices related to two separate palatal roots were identified.

The extensive search with Ultrasonic tip #2 of Start X was carried out for second MB, but could not be located. They were further straightlined with X-Gates of cavity access set (by Dentsply Maillefer, Ballagues) (Fig. 5 & 6). The working length (WL) was determined using Root ZX electronic apex locator (EAL), (by Dentaport ZX, J. Morita, Japan).

Files were placed in the canals (Fig. 7) according to WL determined by EAL, and then one more periapical radiograph was taken to confirm the WL (Fig. 8).

The cleaning and shaping of canals were carried out with rotary NiTi Protaper instruments series (by Dentsply Maillefer, Ballagues), according to the manufacturer's instructions. The final instrumentation was carried out with sizes S1 to F3 of NiTi Protaper instruments (Fig. 9). For irrigation, 3% sodium hypochlorite was used during instrumentation and as

well as after completion of the preparation. Conefit was carried out with non-standardized gutta-percha of medium size (Sure-endo, Korea) with the help of gutta-percha gauge (Dentsply Maillefer, Ballagues) (Fig. 10 & 11).

Now, the canals were dried using paperpoints of size F3 (by Dentsply Maillefer, Ballagues) and then obturated with selected cone, using down pack with system B and back pack with obtura II device (Fig. 12). A periapical radiograph (Fig. 13) was taken to confirm the quality of obturation. Permanent restoration was done on the next appointment.

## Discussion

Incidence of four rooted maxillary second molar is very rare. Etienne Deveaux<sup>10</sup> presented a case report in Vol. 25, No. 8, *JOE* Aug. 1999, and Peter M Di Fiore<sup>11</sup> presented first molar in Vol. 25, No. 10, *JOE* Oct. 1999. Hartwell and Bellizi<sup>12</sup> reported that 9.6% of maxillary molars, they examined, had four canals, but had not mentioned about any case with four roots.

Christie, et al,<sup>9</sup> have proposed a classification system for four rooted maxillary second molar abnormalities.

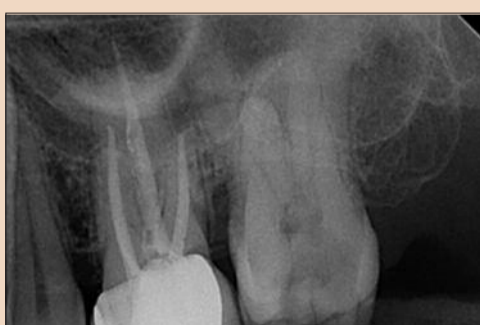

Fig. 1: Pre-operative radiograph

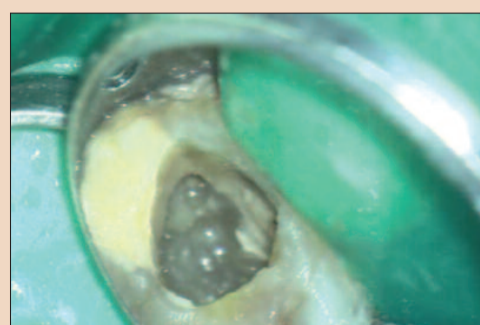


Fig. 2: Triangular access opening

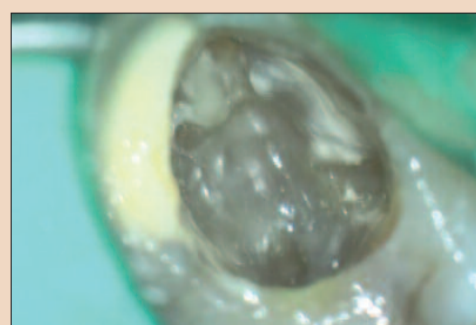


Fig. 3: Modified (Rhomboidal) access opening

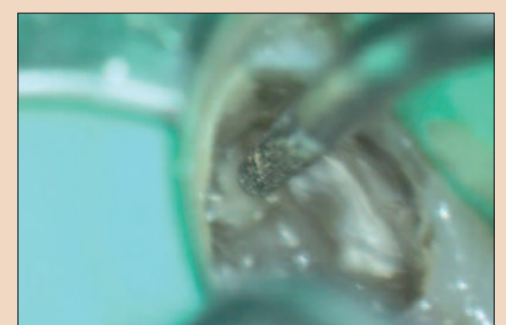

Fig. 4: Ultrasonic Tip

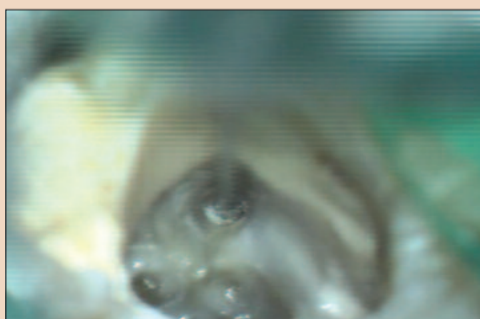


Fig. 5: X-Gates being used for straight lining of access

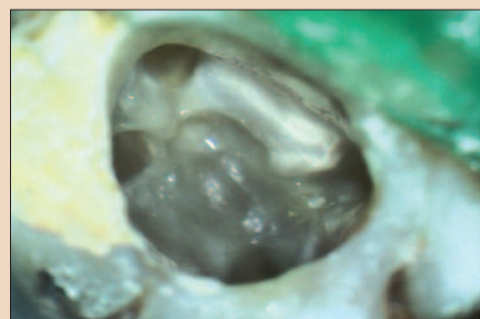


Fig. 6: Access after orifice enlargement



Fig. 7: Files in position for WL

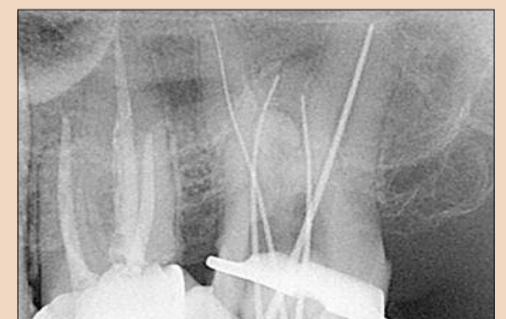

Fig. 8: WL radiograph

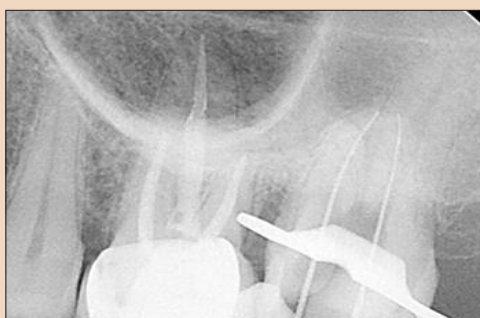

Fig. 9: WL radiograph for buccal canals

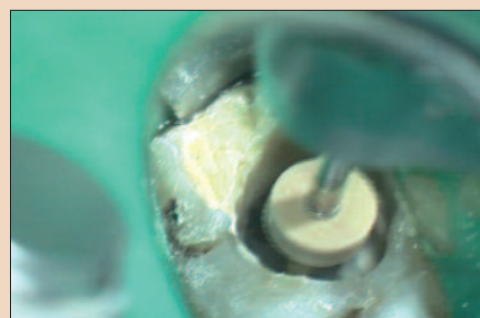

Fig. 10: Shaping with Protaper Instruments

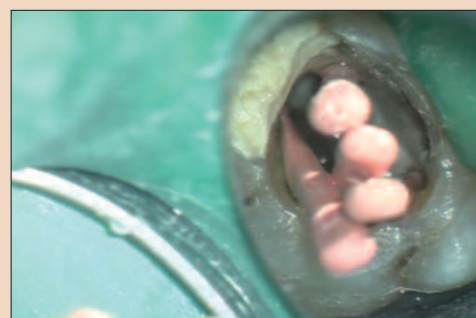

Fig. 11: Conefit

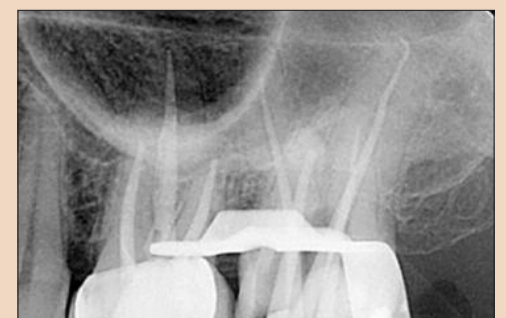

Fig. 12: Conefit Radiograph

**Type I** with long tortuous divergent separate palatal roots

**Type II** with short blunt and parallel roots

**Type III** those with three convergent roots and distinctly divergent fourth distobuccal root.

The tooth treated in this case appears to be of Type I variety according to the

Christie's classification. According to literature, it occurs bilaterally, but in this patient it was unilateral.

**References**

1. De Deus QD. Endodontia, 5th ed. Medsi: Rio de Janeiro. 1992.
2. Zeigler PE, Serene TP. Failures in therapy. In: Cohen S, Burns RC, eds. Pathways of the pulp. 4th ed. St Louis: CV Mosby 1987: 725-753.

3. Thompson BH. Endodontic therapy of an unusual maxillary second molar. *J Endodontics* 1988; **14**: 143-146.
4. Fahid A, Taintor JF. Maxillary second molar with three buccal roots. *J Endodontics* 1988; **14**: 181-185.
5. Malagnino V, Gallotni L, Passariello P. Some unusual clinical cases on root anatomy of permanent maxillary molars. *J Endodontics* 1997; **23**: 127-128.
6. Diamond M. Dental anatomy including anatomy of the head

and neck. New York: MacMillan 1952: 205-205.

7. Sabala CL, Benenati FW, Neas BR. Bilateral root or root canal aberrations in a dental school patient population. *J Endodontics* 1994; **20**: 38-42.
8. Libfeld H, Rotstein I. Incidence of four-rooted maxillary second molars: literature review and radiographic survey of 1, 200 teeth. *J Endodontics* 1989; **15**: 129-131.
9. Christie WH, Peikoff MD, Fogel HM. Maxillary molars with two palatal roots: a retrospec-

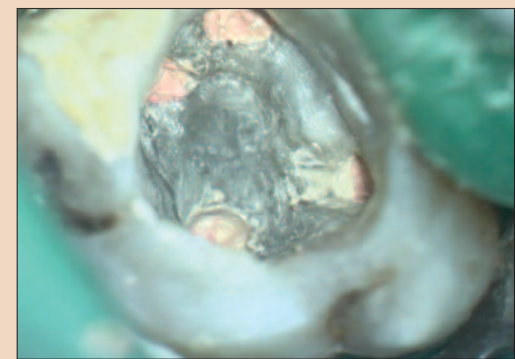


Fig. 13: Post-obturation view

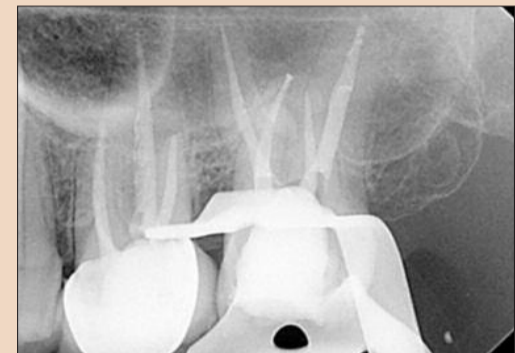


Fig. 14: Post-obturation radiograph

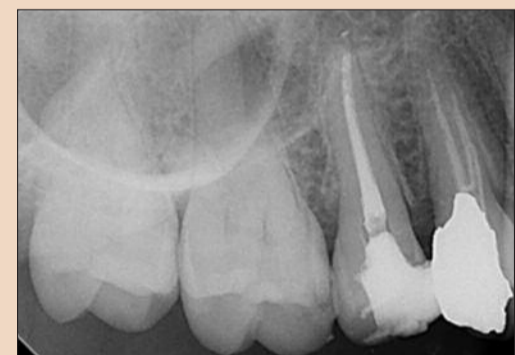

Fig. 15: Radiograph of contralateral side

tive clinical study. *J Endodontics* 1991; **17**: 80-84.

10. Etienne Deveaux: Maxillary second Molar with Two Palatal Roots; Vol. 25, No. 8, *JOE*. 1999 Aug.
11. Peter M.Di. Fiore: A Four-Rooted Quadrangular Maxillary Molar Vol. 25, No. 10, *JOE*. 1999 Oct.
12. Hartwell G, Bellizzi R. Clinical investigation of *in vivo* endodontically treated mandibular & maxillary molars. *J Endodontics* 1982; **8**: 555-557. [4]

**About the author**



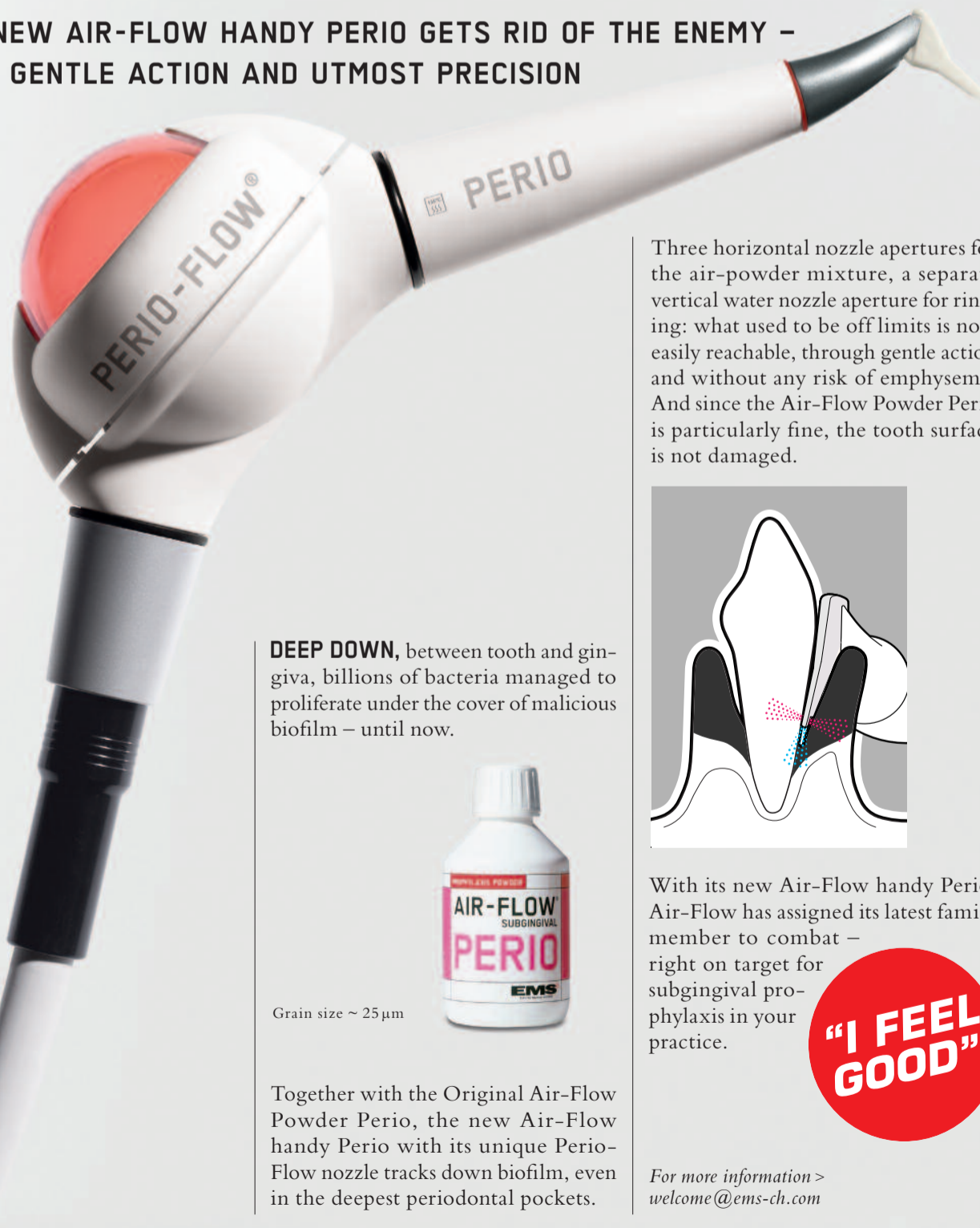Dr PD Joshi graduated in dentistry from Nair Dental College, Mumbai in 1980, and has specialized in conservative dentistry & endodontics. He has a private practice specializing in endodontics in Mumbai. In addition, he has taken specialized training in microscopic endodontics from the University of Pennsylvania, USA, and in implant dentistry from Germany. He is an instructor in the department of micro-dentistry at Government Dental College, Mumbai. He lectures & demonstrates extensively in India and abroad on endodontics and micro-dentistry. He can be contacted at drjoshi01@gmail.com.

EMS-SWISSQUALITY.COM

**EMS**  
ELECTRO MEDICAL SYSTEMS

# AIR-FLOW KILLS BIOFILM

THE NEW AIR-FLOW HANDY PERIO GETS RID OF THE ENEMY - WITH GENTLE ACTION AND UTMOST PRECISION

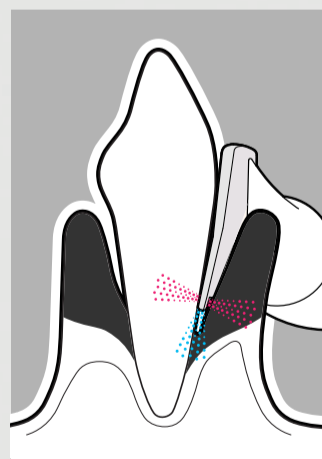


**DEEP DOWN**, between tooth and gingiva, billions of bacteria managed to proliferate under the cover of malicious biofilm – until now.

Grain size ~ 25µm

Together with the Original Air-Flow Powder Perio, the new Air-Flow handy Perio with its unique Perio-Flow nozzle tracks down biofilm, even in the deepest periodontal pockets.

Three horizontal nozzle apertures for the air-powder mixture, a separate vertical water nozzle aperture for rinsing: what used to be off limits is now easily reachable, through gentle action and without any risk of emphysema. And since the Air-Flow Powder Perio is particularly fine, the tooth surface is not damaged.



With its new Air-Flow handy Perio, Air-Flow has assigned its latest family member to combat – right on target for subgingival prophylaxis in your practice.



For more information > welcome@ems-ch.com



# Treating a peri-radicular abscess

Dentist Nicolai Orsteen presents a clinical case study looking at the treatment of a maxillary left lateral front tooth

The patient is a 24-year old white Northern European male. His chief complaint was pain from the maxillary left lateral front tooth, with periodic swelling of the left anterior palatal.

The patient's dental history indicated previous problems in this region, documenting an emergency appointment in March 2007 due to pain and swelling from tooth 22. He was prescribed a seven-day course of Penicillin V tablets (660mg qds\*4) for acute apical periodontitis tooth 22. Following this appointment, the patient was

referred for examination and treatment of tooth 22.

## Diagnosis

The extra-oral examination on 30 January 2008 was within normal limits, shown in Figures 2 and 3.

However, as is visible in Table one, the intra-oral examination revealed gingival bleeding on prodding, no sinus tract and fluctuant swelling of the palate mucosa in the area of teeth 21, 22 and 23. The periodontal pockets however, were within normal limits.

Table 1: Clinical findings

	21	22	23
Sensitivity to Cold	Yes	No	Yes
Percussion	No	Yes	No
Palpation	No	Yes	No
Mobility	No	No	No
Probing Depth (mm)	2	2	2
Restoration	None	Composite (Pal)	None

Further radiographic investigation in April 2008 revealed that the patient was suffering from a discontinuation of the lamina dura on tooth 22, as well as a large circumscribed apical radiolucency (Ø 15mm). The radiographic findings in the coronal part of the root were diagnosed as dens-in-dente (see Figure 4).

Following the investigations, the diagnosis showed that a peri-radicular abscess was related to non-vital tooth 22. The problems associated with the diagnosis were a wide root canal, and an open apex with large apical lesion.

The structured treatment plan involved conventional root canal treatment, and to be assessed for surgery after six months.

## The treatment plan

Treatment commenced on 3 April 2008. Following an initial clinical examination, the tooth was diagnosed with & apical abscess (no sinus present). Access was gained under a rubber dam and the canal was filled with exudate.

The root canal length was determined both by apex locator (RootZX) and a periapical radiograph. The root canal disinfection

was completed mechanically using Hedstroms files (size 90/20 mm/incisal edge).

Particular care was taken during irrigation due to the open apex, & ultrasonics were used for the further cleaning of the canal. A formula of one per cent NaOCl, two per cent CHX and 17 per cent EDTA were used for chemical root canal disinfection. The canal was dressed with Ca(OH)<sub>2</sub> and IRM was applied as a temporary filling.

Five days after the completion of the treatment, the patient sought an emergency consultation because of severe pain and swelling from tooth 22. He was prescribed an eight-day course of clindamycin (500 mg x 3\*3) to ease the discomfort.

Following the surgery, on May 29, tooth 22 was asymptomatic and still sensitive to per-

cussion. The temporary filling was removed and the root canal disinfected again with Irrisafe, as well as a formula of one per cent NaOCl, two per cent CHX and 17 per cent EDTA. A long-term intra-canal dressing with Ca(OH)<sub>2</sub> was placed, and IRM was applied as a temporary filling.

## Preparing for root treatment

The patient missed the following three appointments, but returned on October 14. On this date the tooth was still sensitive to percussion and palpation. As there were no real signs of improvement, it was decided that the tooth should be root filled & an appointment for apical surgery was made. To ease discomfort, the root canal was filled with an 8mm length of white MTA, & a wet cotton pellet was placed over the MTA. On top of the cotton pellet, a temporary filling with IRM was placed.

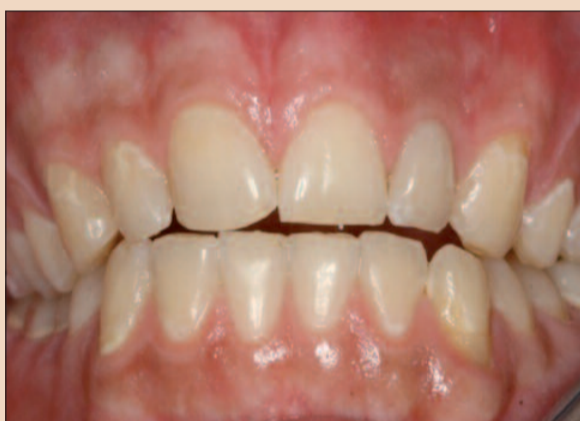

Fig. 1: Frontal view

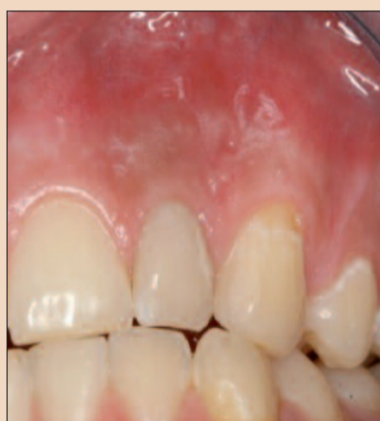

Fig. 2: Frontal view

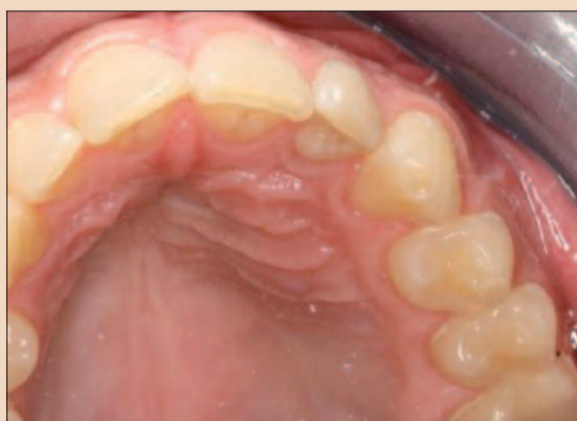

Fig. 3: Occlusal view

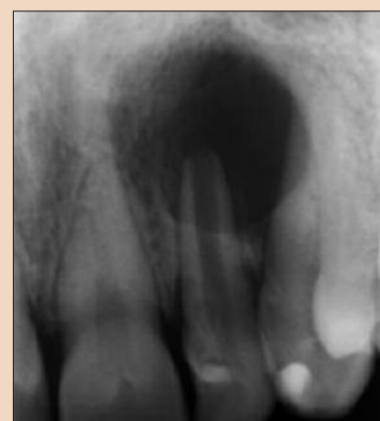

Fig. 4: Pre-operative periapical radiograph

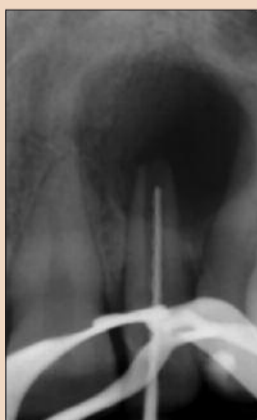

Fig. 5: Working length radiograph

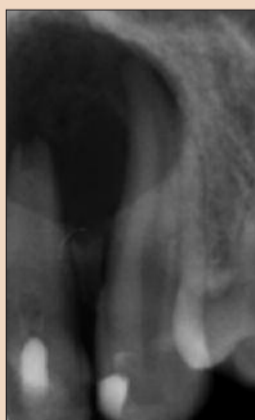

Fig. 6: MTA in the canal

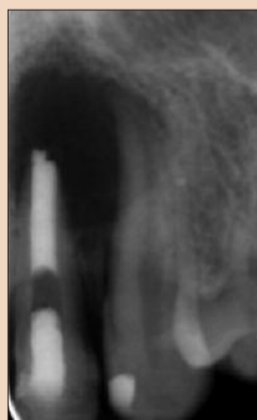


Fig. 7: MTA in the canal

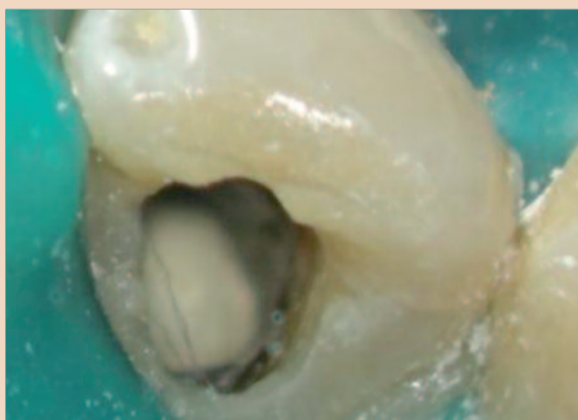

Fig. 8: MTA, wet cotton pellet and IRM

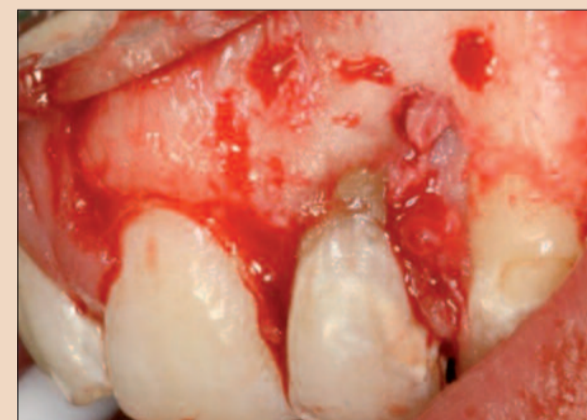

Fig. 9: White MTA in the canal

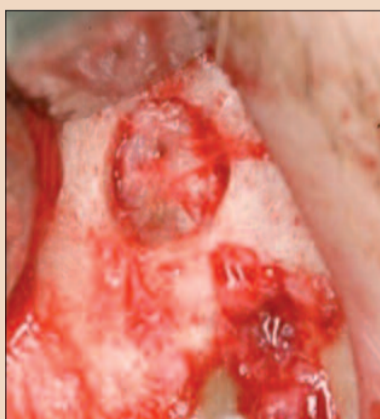


Fig. 10: Elevation of surgical flap

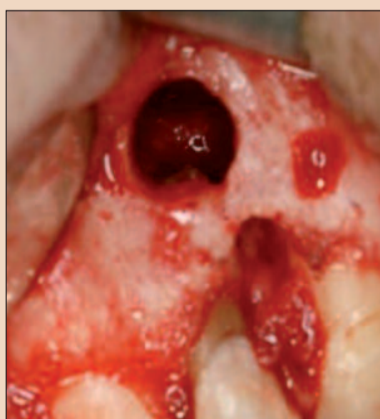

Fig. 11: Granulation osteotomy

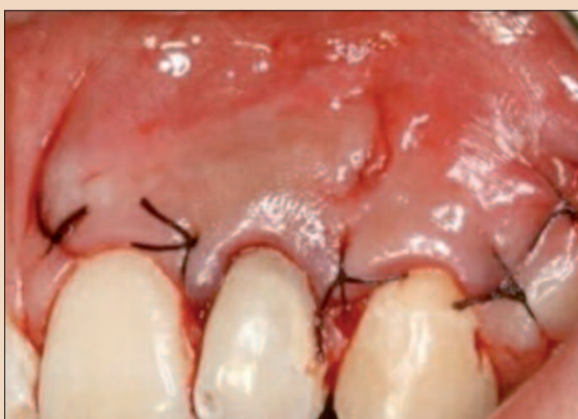

Fig. 12: Granulation tissue removed & root-end resection performed

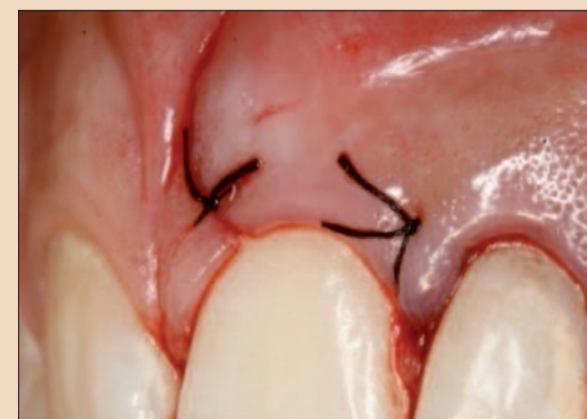


Fig. 13: Flap sutured with 6-0 silk sutures