

## MASO can help you 'Chart a Course'

*Middle Atlantic  
Society of  
Orthodontists to  
host annual session*

By Sierra Rendon, Managing Editor

**T**he Middle Atlantic Society of Orthodontists (MASO) will host its annual session from Sept. 20–23 at the Hilton Baltimore on Baltimore's inner harbor. During this time, you and your colleagues will be "Charting a Course for the Future."

Annual session speakers include: Drs. David Sarver, Roger Levin, Neal Kravitz, Jeffrey Posnick, Normand Boucher, Jeff Behan and Chris Bentson. MASO's staff program will include Char Eash and Tina Byrne.

At this annual session, MASO will present its Lifetime Achievement Award to Dr. David Paolini. Paolini graduated from La Salle College in Philadelphia and the University of Pittsburgh School of Dental Medicine in 1964. He received a three-year fellowship in orthodontics at the start

► See MASO, page 7



The Hilton Baltimore on Baltimore's inner harbor will be the site of the Middle Atlantic Society of Orthodontists annual session from Sept. 20–23.  
(Photo/Provided by MASO)

AD

PRSRF STD  
U.S. Postage  
PAID  
San Antonio, TX  
Permit #1396

Dental Tribune America  
116 West 23rd Street  
Suite #500  
New York, N.Y. 10011

**ORTHOVOICE®**  
Vegas Orthodontic International  
Conference & Exposition

Explore, Engage,  
Experience

**LAS VEGAS OCT. 11-13 2012**

visit **orthovoice.com**

# Part One



Basically, research is story telling; it is a methodical and organized inquiry into a theoretical subject or practical understanding of a subject. Research is used to (a) establish or confirm facts, (b) reaffirm results of previous studies, (c) solve new or existing problems, (d) support statements, and/ or (e) develop new theories regarding the hypothetical or practical milieu. A research project may also be an expansion on past work in order to test the validity of instruments,

I Quantitative research  
II Qualitative research

- Phenomenology
- Ethnography
- Case Study
- Grounded theory
- Historical

III Mixed research

A quantitative approach is helpful to develop and employ mathematics, statistics and hypotheses pertaining to a problem. It uses measurements to provide the primary connection and expression of the quantitative relationships. A qualitative research approach is appropriate when gathering in-depth understanding of human and social behavior and the reasons for such behavior. It investigates the how and why rather than the when, what, or where of decision-making, as well as various re-

Please look for Part Two in the next edition of Ortho Tribune.

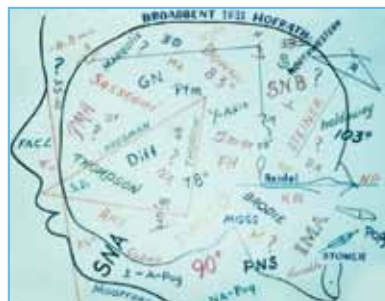


Image courtesy of Dr. Earl Broker.

# ORTHO TRIBUNE

Published by Dental Tribune America  
© 2012 Dental Tribune America, LLC  
All rights reserved.

Dental Tribune strives to maintain the utmost accuracy in its news and clinical reports. If you find a factual error or content that requires clarification, please contact Managing Editor Sierra Rendon at [s.rendon@dental-tribune.com](mailto:s.rendon@dental-tribune.com).

Dental Tribune cannot assume responsibility for the validity of product claims or for typographical errors. The publisher also does not assume responsibility for product names or statements made by advertisers. Opinions expressed by authors are their own and may not reflect those of Dental Tribune America.

## EDITORIAL BOARD

Jay Bowman, DMD, MSD (*Journalism & Education*)  
Robert Boyd, DDS, Med (*Periodontics & Education*)  
Earl Broker, DDS (*T.M.D. & Orofacial Pain*)  
Tarek El-Bialy, BDS, MS, PhD  
(*Research, Biomechanics & Education*)  
Donald Giddon, DMD, PhD (*Psychology & Education*)  
Donald Machen, DMD, MSD, MD, JD, MBA  
(*Medicine, Law & Business*)  
James Mah, DDS, MSC, MRCD, DMSc  
(*Craniofacial Imaging & Education*)  
Richard Masella, DMD (*Education*)  
Malcolm Meister, DDS, MSM, JD (*Law & Education*)  
Harold Middleberg, DDS (*Practice Management*)  
Elliott Moskowitz, DDS, MEd (*Journalism & Education*)  
James Mulick, DDS, MSD  
(*Craniofacial Research & Education*)  
Ravindra Nanda, BDS, MDS, PhD  
(*Biomechanics & Education*)  
Edward O'Neil, MD (*Internal Medicine*)  
Donald Picard, DDS, MS (*Accounting*)  
Howard Sacks, DMD (*Orthodontics*)  
Glenn Sameshima, DDS, PhD (*Research & Education*)  
Daniel Sarya, DDS, MPH (*Public Health*)  
Keith Sherwood, DDS (*Oral Surgery*)  
James Souers, DDS (*Orthodontics*)  
Gregg Tartakow, DMD (*Orthodontics*) & Ortho  
Tribune Associate Editor

Member Publication  
**AADE**  
American Association  
of Dental Editors



# How to avoid extractions when treating malocclusions using MRC's Bent Wire System and Trainer System for arch development

By German O. Ramirez-Yañez, DDS, PhD, and Chris Farrell, BDS

## Abstract

Maxillary and mandibular expansion has been proposed to increase the arch perimeter and to avoid extractions during orthodontic treatment. Although controversy has persisted over the stability of expansion techniques, there is an increasing trend toward "non-extraction."

This paper describes a novel method to produce expansion of the dental arches, and at the same time, to treat muscular dysfunctions that may be the etiological factor of the malocclusion. The system has been developed by Myofunctional Research Co. (MRC), Queensland, Australia, as a simpler method of phase one expansion, which may produce improved stability because of simultaneous habit correction in selected cases. Two cases treated with the Farrell Bent Wire System™ (BWS™) are described and the advantage of this method of treatment is discussed.

## Introduction

Expansion of the jaws has been increasingly performed in orthodontics to achieve better occlusal and maxillary relationship and, in doing so, improving oral functions. Maxillary and mandibular expansion has been proposed since Edward Angle to avoid extractions (Dewel, 1964). This paper presents a novel method to produce dental arch development in the maxilla and the mandible, while at the same time correcting or maintaining the inter-maxillary relationship either if a sagittal and/or vertical problem exists or a Class I malocclusion with normal overjet and overbite is present at the beginning of treatment.

There is a controversy regarding the ideal time for performing the expansion. Sari and co-workers reported that rapid maxillary expansion by means of a fixed screw (eg. Hyrax) produces better results when it is performed in the early permanent dentition (Sari, 2003). Although this statement appears to be supported by other studies (Chung; Housley, 2003; Spillane, 1995), maxillary expansion may also be successfully done in older adolescents and adults (Stuart, 2003; Iseri, 2004; Lima, 2000). In the maxilla, rapid and semi-rapid expansion produce an increase of the lower nasal and maxillary base widths, with the maxilla moving forward and downward (Chung, 2004; Sari, 2003; Iseri, 2004).

These changes in the maxilla produced by the expansion are accompanied by a spontaneous mandibular response, which increases the dental arch perimeter (Lima, 2004; McNamara, 2003) and rotates the mandible posteriorly (Sari, 2003; Chung, 2004). Mandibular displacement is associated with an increase in facial height (Sari, 2003; Chung, 2004).

Net gain in the arch perimeter may be calculated accordingly with the ex-

pansion performed. Motoyoshi and co-workers reported that 1 mm increase in arch width results in an increase in arch perimeter of 0.37 mm (Motoyoshi, 2002). Akkaya and collaborators determined that arch perimeter gain through expansion could be predicted as 0.65 times the amount of the posterior expansion when treatment is performed with rapid maxillary expansion, and 0.60 times the amount of posterior expansion when treatment is performed with semi-rapid maxillary expansion (Akkaya, 1998). This

is also supported by Adkins and co-workers, who determined that arch perimeter may increase 0.7 times the expansion produced at the premolars.

An expected relapse in the amount of expansion has been reported by some authors (Hime, 1990; Housley, 2003), which appears to be the result of that pressure delivered by the cheeks on the maxillary arch and the resistance to deformation of maxillary sutures and surrounding tissues to maxillary expansion.

Nevertheless, maxillary and mandibu-

lar expansion rises up as one of the important phases of orthodontic treatment, producing arch perimeter increase, and thus, avoiding extraction of teeth. Increasing numbers of multi-banded techniques using passive self-ligating brackets have become popular, but few address the challenges of adapting the soft tissues to this new dental position. Long-term retention is the recommended solution to stability. Thus, the aim

► See MRC, page 4

AD

THE WORLD'S LEADING MYOFUNCTIONAL ORTHODONTIC SYSTEM JUST GOT BETTER

# myobrace®

GET RESULTS

BEFORE AFTER BEFORE AFTER BEFORE AFTER BEFORE AFTER

FOR JUNIORS FOR KIDS FOR TEENS FOR ADULTS

BECOME A MYOBACE® PROVIDER

- Treat a wider range of patients.
- Increase patient flow in your practice.
- Less chair-side time required.
- Financial benefits for you and your patients.

Visit: [www.myoresearch.com/courses](http://www.myoresearch.com/courses)

FIND OUT HOW AT [WWW.MYORESEARCH.COM](http://WWW.MYORESEARCH.COM) OR PHONE 1866 550 4696



◀ MRC, Page 3

of the current paper is to present a new method to produce maxillary and mandibular expansion and, at the same time, to treat the soft-tissue dysfunction that may be responsible for treatment relapse (Ramirez-Yañez, 2005). Two example cases treated with the BWS Orthodontic System developed by Myofunctional Research Co (MRC) in Australia are presented to explain the proposed treatment.

### The BWS Orthodontic System

The BWS Orthodontic System discussed in this article is composed of two different appliances: the Trainer™ and the BWS. These two appliances combined may simultaneously produce arch development and treat poor myofunctional habits. The Trainer, a pre-fabricated functional appliance, has amply demonstrated an ability to relocate the mandible (Usumez, 2004) to correct improper forces produced by the muscles of the cheek and lips (Quatrelli, Ramirez-Yañez, 2005a) and to change the dimensions of the dental arches (Ramirez-Yañez, 2005b). Further research (Yagci 2011) showed that treatment using the Trainer produced a positive influence on the masticatory and peri-oral musculature.

However, in those cases where more maxillary and mandibular expansion is required to avoid teeth extractions, the Trainer combined with the BWS produces higher amounts of expansion and, therefore, a higher increase in arch perimeter. It is also proposed that by utilizing the Trainer in conjunction with the arch expansion, the force of the tongue activates further alveolar changes that other techniques may not achieve because of the bulk of the appliance being located in the palate where the tongue should naturally position.

The BWS is typically composed of a lingual arch, which follows the lingual surfaces of the teeth crowns at the gingival third and ends in a loop at the interproximal space between the second premolar and the first molar at both sides. The distal end engages a tube (0.7 Farrell tube by MRC) welded to a cemented band on the first molars (Fig. 1). Additionally, the BWS is maintained in place, facing the gingival third of teeth's crown, by two begg premolar brackets cemented on the first premolars with the slot directed toward gingival or alternately composite stops bonded to the premolar or anterior dentition (Fig. 2). The wire component is 0.7 mm spring wire and is fabricated to the arch form of the starting models either by the laboratory or the orthodontist. The simple nature of the BWS makes it possible to assemble in-house, avoiding the fees that accompany laboratory-constructed appliances.

An advantage of this system is that it does not involve using acrylic in the palatal vault. A functional appliance designed with acrylic on the palate and that is not properly built may lower the tongue, encouraging tongue thrusting, and, thus, either worsening the malocclusion or producing a relapse (Fig. 3). The Trainer is a prefabricated functional appliance, which means no laboratory involvement, and the BWS can be entirely constructed "in office." The BWS is not made of acrylic, nor does it occupy the palate. It allows the tongue to position correctly and the patient to speak normally.

The BWS is also suitable for use in the

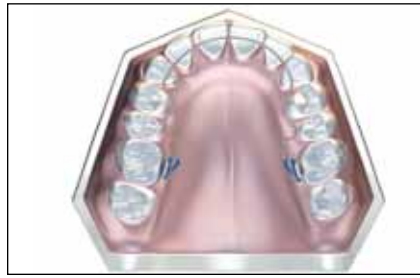


Fig. 1: Photos/Provided by Drs. German O. Ramirez-Yañez and Chris Farrell.

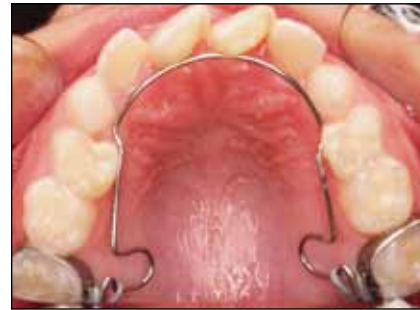

Fig. 2

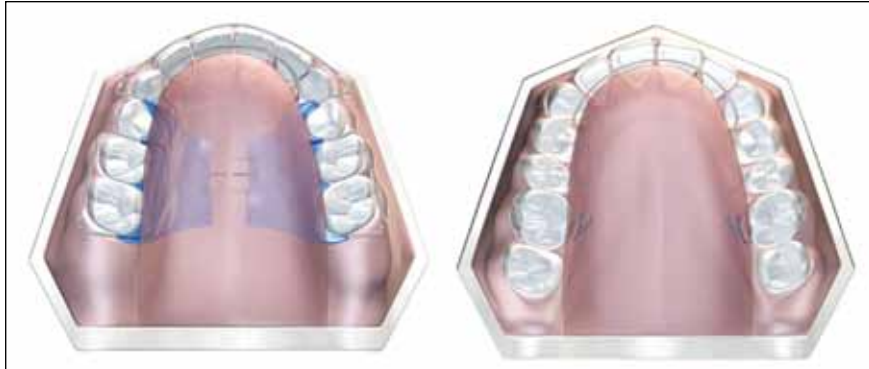

Fig. 3

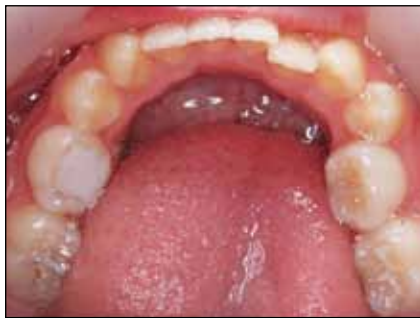

Fig. 4a

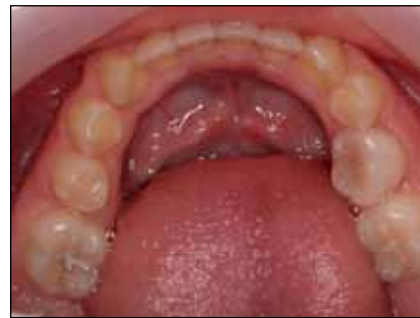

Fig. 4b

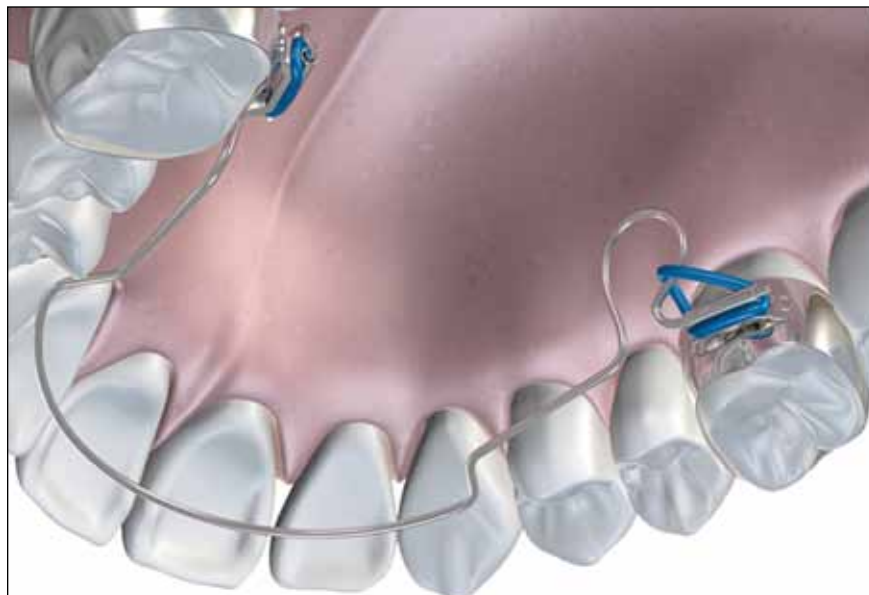

Fig. 5

lower arch. Typical treatment tends to use only upper expansion for three to four months, after which time the wire component of the BWS is removed (the bands are kept for later use of the BWS). The i-2 Trainer (with the inner-cage that produces arch expansion) is then used to maintain the initial arch expansion gained using the BWS. Lower alignment is re-evaluated throughout this stage of i-2 Trainer use. Often, as can be demonstrated in the cases selected, lower alignment and arch form improves because of the maxillary expansion and peri-oral musculature functional improvement (Fig. 4).

The BWS is held in place using standard ligatures placed around the BWS tube as pictured (Fig. 5).

The following two cases show the effect of the BWS Orthodontic System on arch development.

### Case No. 1

This 10-year-old female patient consulted because of a crowded dentition involving unusually misaligned upper central incisors with a midline shift of 10 mm and with lost "c" space on the lower left side. The parents requested that the treatment be non-extraction, although they had previously been advised that future orthodontic treatment might require this option (Fig. 6).

The occlusion was classified as Class I with normal slight overjet and with normal overbite. No skeletal alteration was found on cephalometric measurements and analysis of cast models reported a lack of arch development. This case was diagnosed as a Class I malocclusion with underdevelopment of both dental arches. Midline shift was primarily as a result of the lost lower "c" space. Soft-tissue analy-

sis showed a mouth-open posture and hyperactive peri-oral musculature. It was considered the myofunctional habits were a contributing factor to the malocclusion and, thus, a suitable case for the BWS and Trainer combination prior to fixed appliances once the permanent dentition was fully erupted.

The plan of treatment involved a first phase with a BWS for the upper arch combined with an I-2n Trainer — "n" for no core or cage for increased flexibility and use with the BWS. The i-2n Trainer was used one hour daily plus overnight while sleeping. Monthly adjustment to the activating loops of the BWS were made in increments of 1-2 mm per month.

This treatment was continued for four months, after which time the upper BWS was removed and i-2 Trainer was used to maintain the expansion achieved by the BWS. The i-2 Trainer also encouraged the tongue to assist in maintaining the maxillary expansion without retainers. At this stage, the lower arch form and dental alignment was assessed and showed considerable improvement. It was noted the space for the lower left permanent canine had increased — an effect thought to be produced by the combination of maxillary arch expansion and correction of myofunctional habits. The midlines were also self-correcting.

Space for the lower canines was ultimately achieved without a lower BWS.

The case is further improved by continued use of the i-2 Trainer and the Myobrace Regular™ to exploit the eruption stage prior to treatment finalization with fixed appliances as required.

The observation of the effects and benefits of the BWS Orthodontic System are evident from this case, and the concepts are not new to orthodontics. Maxillary expansion tends to also improve the lower arch length and assists the orthodontist in achieving non-extraction outcomes with more stable results because of simultaneous correction of tongue position and retraining of the peri-oral musculature. The second phase of treatment did not require the BWS on the lower arch as arch development during the treatment period sufficiently opened the space for the lower permanent canine. The lower anterior dentition did not require the use of fixed appliances (Fig. 7). Thus, this case was treated in a 2-year period, required minimal chair side time and a difficult extraction case was converted to a simple, non-extraction case.

### Case No. 2

This 12-year-old female patient consulted because of very underdeveloped maxillary arch form and ectopic erupting canines (Fig. 8). This is far from an ideal stage to be considering non-extraction treatment; however, the parent insisted that the case was attempted non-extraction. The lower anterior teeth were also considerably crowded, and it would regularly be justified in extracting the first four premolar teeth and going into upper and lower straight wire fixed appliances.

It could be argued that treating non-extraction will prolong the treatment and certainly incur greater expense on the parent. However, there is a growing demand from parents who have had extraction orthodontics in the past to

▶ See MRC, page 5



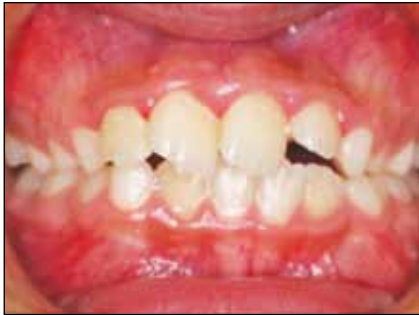

Fig. 6a

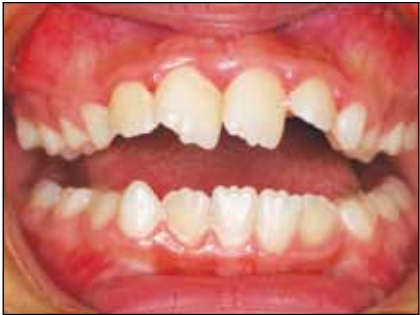

Fig. 6b

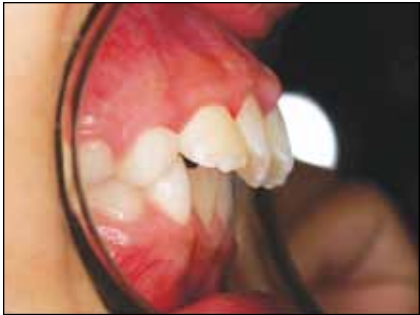

Fig. 6c

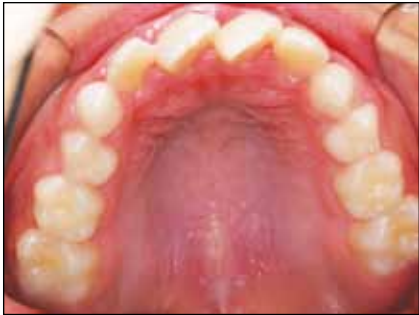

Fig. 6d

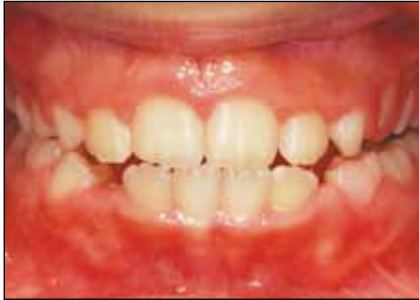

Fig. 7a

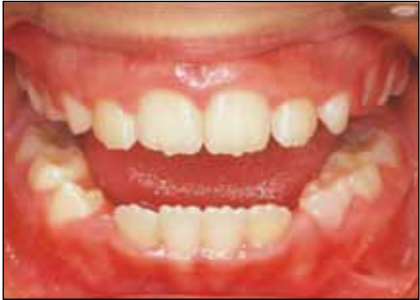

Fig. 7b

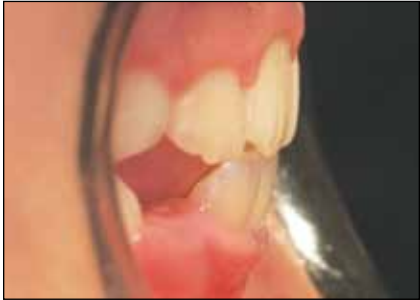

Fig. 7c

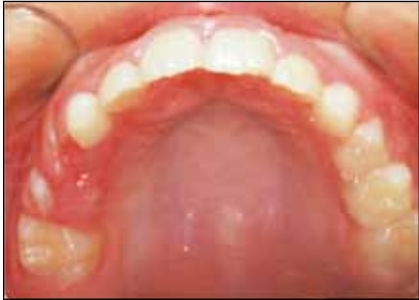

Fig. 7d

◀ MRC, Page 4

avoid this approach for their children. Therefore, the BWS Orthodontic System can be a beneficial technique that the orthodontist can use in these exceptional cases.

Treatment was similar to case 1. An upper BWS was fitted and combined with the use of the i-2n Trainer initially for four months, after which time the BWS wire was removed, leaving the molar bands in place. The i-2 Trainer was introduced at this stage for a further three months to maintain the expansion prior to a second phase of treatment using the BWS and i2n Trainer for three months (as mentioned earlier in this article).

This allows the dentition to “catch up” and prevents excessive tooth mobility. It is thought that much of the expansion achieved by this system is dento-alveolar rather than sutural, as with a rapid maxillary expander and other acrylic expanders. Also, there is more development in the anterior arch form, which is an effect previously found in the research on the Trainer (Ramirez-Yañez, 2005b).


The difficulty in cases like this, requiring large amounts of expansion to achieve a non-extraction result, is a tendency to create an open bite. Although this occurs to some extent, the BWS Orthodontic System does not open the bite as much as more conventional techniques because the tongue position is favorably altered by use of the Trainer. This conjecture may require further investigation to ratify.

Once again, spontaneous alignment of the lower anterior dentition has occurred without the requirement for an additional BWS for the lower arch. This effect is not just restricted to these two cases but is a routine observation of the BWS Orthodontic System. This case also illustrates the stability achieved in the lower dentition as no retainers were used apart from night use of the Trainer.



Although this patient is not at the ideal age, the pictures show that it was possible to obtain space for all permanent canines, without extractions and with good stability.

The bite opening is minimal and tends to decrease with further dental development. Although this case was finalized

▶ See MRC, page 6



ALL-SECURE  
ALL-ACCESSIBLE  
ALL-EDGE




Edge Cloud. It's all you really need.

Edge practice management, imaging, and communication system provides all-convenient private and secure cloud computing, with an off-site data hosting option that eliminates costly and complex onsite network servers. With 35%-44% hardware cost savings, a world-class firewall, reliable backups, and full access anywhere from mobile devices, you'll discover the sky's the limit in practice efficiency, profitability, and innovation.

Above all, EDGE.

(800) 678-4644  
sales@ortho2.com | www.ortho2.com

Practice Complete Management.



ORTHO2

Edge, Ortho2, Practice Complete Management, and the Ortho2 logo are trademarks of Ortho Computer Systems, Inc. ©2012 Ortho Computer Systems, Inc. All rights reserved.



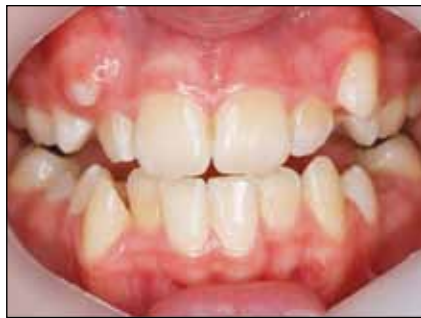

Fig. 8a

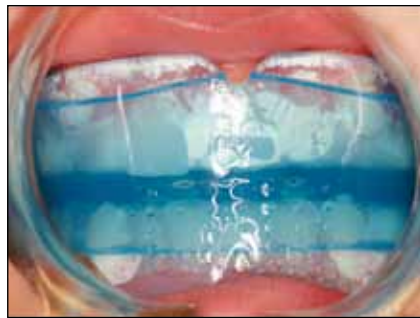


Fig. 8b

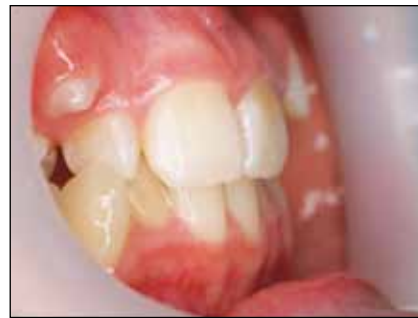

Fig. 8c

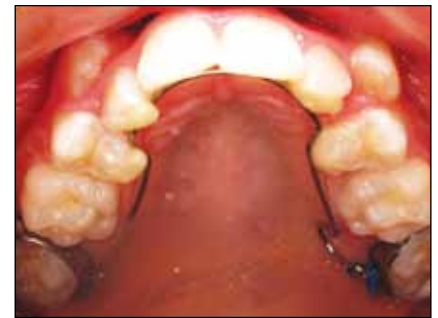

Fig. 8d

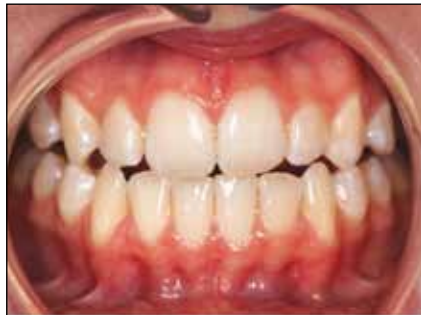

Fig. 9a

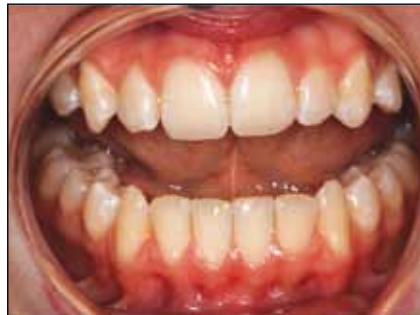

Fig. 9b

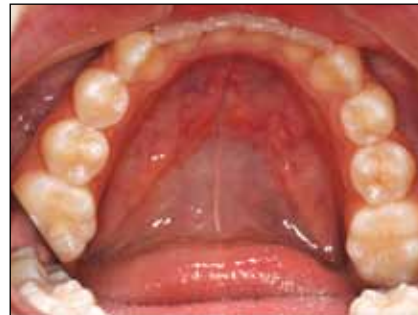

Fig. 9c

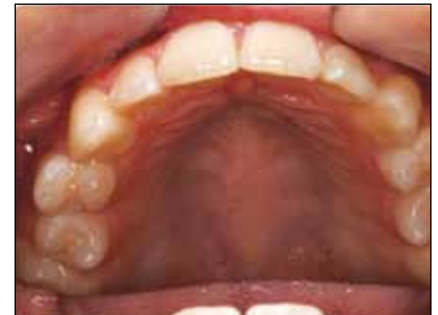

Fig. 9d

#### ◀MRC, Page 5

with the Myobrace Regular™ from MRC, fixed appliances on the upper arch would possibly have delivered quicker results following the BWS Orthodontic System. The assistance of correcting the forces delivered by the muscles of the cheek (buccinator) and lips (orbicularis oris) at swallowing cannot be ignored and is a key part of the *modus operandi* of this expansion system.

After two years of treatment and observation, along with night-time retention using the i-2 Trainer for 12 months after treatment, the BWS produced enough upper arch development to not only accommodate the erupting canines, but also achieve lower anterior alignment with minimal intervention and minimal retention (Fig. 9). This case was a more extreme example that orthodontists will face in the future as more parents demand the non-extraction option with minimal use of multi-bracket systems.

#### Conclusions

Maxillary and mandibular expansion has been shown to be an excellent alternative to increase the arch perimeter and, thus, to avoid the need for extractions to properly align teeth. This paper has presented two cases treated using the BWS Orthodontic System, which involves the combination of two appliance systems: the Trainer, a pre-fabricated functional appliance, and the BWS.

Both appliances, Trainer and BWS, have to be used in order to get the results reported in this paper. The BWS Orthodontic System showed in these two cases and in many cases treated by the authors is an excellent means to produce arch development in both upper and lower dental arches in a short time.

The effect of the BWS Orthodontic System on arch development does not change the inter-maxillary relationship when a Class I occlusion exists at the beginning of treatment.

However, when a Class II malocclusion associated to a crowded dentition is present the BWS Orthodontic System pro-

duces arch development and, at the same time, the mandibular relocation effect is produced by the Trainer (Usumez, 2004; Ramirez-Yañez, 2005a; Quadrelli, 2002), which treats the distal position of the mandible.

Additionally, the BWS Orthodontic System has shown to improve the overjet and overbite but to maintain them when they are correct at the beginning of treatment. This system treats muscular dysfunctions that may be the cause of crowding and malocclusion and may cause relapse after treatment is finished.

Thus, the BWS Orthodontic System may be proposed as an excellent alternative form of treatment in those cases where arch development is required to align teeth, patients want to minimize or even avoid brackets and extractions, the mandible needs to be relocated, soft tissue dysfunction is present and treatment needs to be performed in a reasonable period of time.

#### References

1. Adkins MD, Nanda RS, Currier GF. Arch Perimeter changes on rapid palatal expansion. *Am J Orthod Dentofacial Orthop* 1990; 97:194-199.
2. Akkaya S, Lorenzon S, Ucem TT. Comparison of dental arch perimeter changes between bonded rapid and slow maxillary expansion procedures. *Eur J Orthod* 1998; 20:255-261.
3. Chung CH, Font B. Skeletal and dental changes in the sagittal, vertical and transverse dimensions after rapid palatal expansion. *Am J Orthod Dentofacial Orthop* 2004; 126:569-575.
4. Dewel BF. Serial extraction: its limitations and contraindications in orthodontic treatment. *Am J Orthod* 1967; 53:904-921.
5. Hime DL, Owen AH 3rd. The stability of the arch expansion effects on Frankel appliance therapy. *Am J Orthod Dentofacial Orthop* 1990; 98:437-445.
6. Housley JA, Nanda RS, Currier GF, McCune DE. Stability of transverse expansion in the mandibular arch. *Am J Orthod Dentofacial Orthop* 2003; 124:288-293.
7. Iseri H, Ozzoy S. Semirapid maxillary expansion – a study of long term transverse effects in older adolescents and adults. *Angle Orthod* 2004; 74:71-8.
8. Lima RM, Lima AL. Case report: Long-term outcome of Class II, division 1 malocclusion treated with rapid palatal expansion and cervical traction. *Angle Orthod* 2000; 70:89-94.
9. Lima AC, Lima AL, Filho RM, Oylen OJ. Spontaneous mandibular arch response after rapid palatal expansion: a long term study on Class I malocclusion. *Am J Orthod Dentofacial Orthop* 2004; 126:576-582.
10. McNamara JA Jr, Baccetti T, Franchi L, Herberger TA. Rapid maxillary expansion followed by fixed appliances: a long-term evaluation of changes in arch dimensions. *Angle Orthod* 2003; 73:344-353.
11. Motoyoshi M, Hirabayashi M, Shimazaki T, Nawra S. An experimental study on mandibular expansion: increases in arch width and perimeter. *Eur J Orthod* 2002; 24:125-130.
12. Quadrelli C, Gheorgiu M, Marchetti C, Ghiglione V. Early Myofunctional approach to skeletal Class II. *Mondo Orthod* 2002; 2:109-122.
13. Ramírez-Yañez GO, Farrell C. Soft tissue dysfunction: A missing clue when treating malocclusions. *Int J Jaw Func Orthop* 2005; 5.
14. Ramírez-Yañez GO, Junior E, Sidlauskas A, Flutter J, Farrell C. The effect of a pre-fabricated functional appliance on arch development. 2005 (in preparation).
15. Sari Z, Uysal T, Usumez S, Basciftci FA. Rapid maxillary expansion. Is it better in the mixed or in the permanent dentition? *Angle Orthod* 2003; 73:654-661.
16. Spillane LM, McNamara JA Jr. Maxillary adaptation to expansion in the mixed dentition. *Semin Orthod* 1995; 1:176-187.
17. Stuart DA, Wilshire WA. Rapid palatal expansion in the young adult: Time for a paradigm shift? *J Can Dent Assoc* 2003; 69:374-377.
18. Usumez S, Uysal T, Sari Z, Basciftci FA, Karman AI, Guray E. The effects of early pre-orthodontic Trainer treatment on Class II, division 1 patients. *Angle Orthod* 2004; 74:605-609.

#### About the authors



**CHRIS FARRELL, BDS**, graduated from Sydney University in 1971 with a comprehensive knowledge of traditional orthodontics using the BEGG technique. Through clinical experience, he took an interest in TMJ/TMD disorder and, after further research, Farrell discovered that the etiology of malocclusion and TMJ disorder was myofunctional, contradicting the current views of his profession. Farrell founded Myofunctional Research Co. (MRC) in 1989 and has become the leading designer of intra-oral appliances for orthodontics, TMJ and sports mouthguards.



**GERMAN O. RAMÍREZ-YAÑEZ, DDS, PhD**, is a dentist from Colombia (South America) with more than 20 years of experience in guiding craniofacial growth and development. He is a specialist in pediatric dentistry (Mexico) and functional maxillofacial orthopedics (Mexico and Brazil), and is trained in orthodontics (Mexico). Ramirez has a master's in oral biology and a PhD in dental sciences (Australia). He has published more than 20 articles about early orthodontic treatment and about craniofacial biology in peer-reviewed international journals.

*'The simple nature of the BWS makes it possible to assemble in-house, avoiding the fees that accompany laboratory-constructed appliances.'*



# OrthoVOICE 2012 on slate for October

Enhanced social events and a focus on presenting outstanding clinical and entrepreneurial ideas in a fresh environment have attendees and the event organizers preparing for another dynamic "social meeting" experience at the OrthoVOICE 2012, which takes place Oct. 11-13 at Paris & Bally's Resort in Las Vegas.

Leading off with an entertaining and educational talk with Dr. Lysle Johnston, OrthoVOICE attendees are in for a wild ride of mind-stretching ideas for practice growth, according to organizers.

With a unique take on building the speaker lineup and creative social events, OrthoVOICE is set to be orthodontics' most innovative and socially

interactive meeting of the year, its organizers say.

"For OrthoVOICE, it's about education, fun and giving back," according to the event organizers.

Plan to attend the meeting's second charity golf event on Thursday morning, Oct. 11. This year's event will be held at Desert Pines Golf Club to benefit Smile for a Lifetime Foundation (S4L).

The \$229 registration is open online at [www.orthovoice.com](http://www.orthovoice.com) and includes a donation to S4L, breakfast and lunch, round-trip transportation, green fees, carts and range balls.

To learn more about the full range of events and lectures at OrthoVOICE 2012, visit [www.orthovoice.com](http://www.orthovoice.com).



The OrthoVOICE 2012 will take place Oct. 11-13 at Paris & Bally's Resort in Las Vegas.

Twelve C.E. credits are offered and doctor/team registration is only \$399 per

person, through Sept. 30. Registration is open now at [www.orthovoice.com](http://www.orthovoice.com).

◀ MASO, Page 1

of his sophomore year in dental school, which started him on the career path of this specialty. After completing dental school, Paolini married his wife, Caroline, and began his orthodontic training at Pitt. He received his certificate in orthodontics and his master's in dentistry, and then entered military service, spending two years at Fort Benning, Ga.

In 1972, he established his first office in Gettysburg, Pa., and opened a satellite office in Waynesboro a year later. He retired in 2010. During his 38 years of practice, Paolini has served as president of both the Pennsylvania State and Middle Atlantic Society of Orthodontists. During his service on, and chairmanship of, the AAO's Council on Insurance, he achieved the highlight of his AAO career when he was instrumental in establishing the current malpractice program. He served on the council for an additional five years. He has served two eight-year terms in the AAO House of Delegates and eight years on the Council on Orthodontic Practice.

## Session schedule

Thursday, Sept. 20

- 7-11 a.m.: MASO Board Meeting (invitation only)
- 1-5:30 p.m.: Golf outing at the Country Club of Maryland
- 1-6 p.m.: Registration/exhibitor set-up

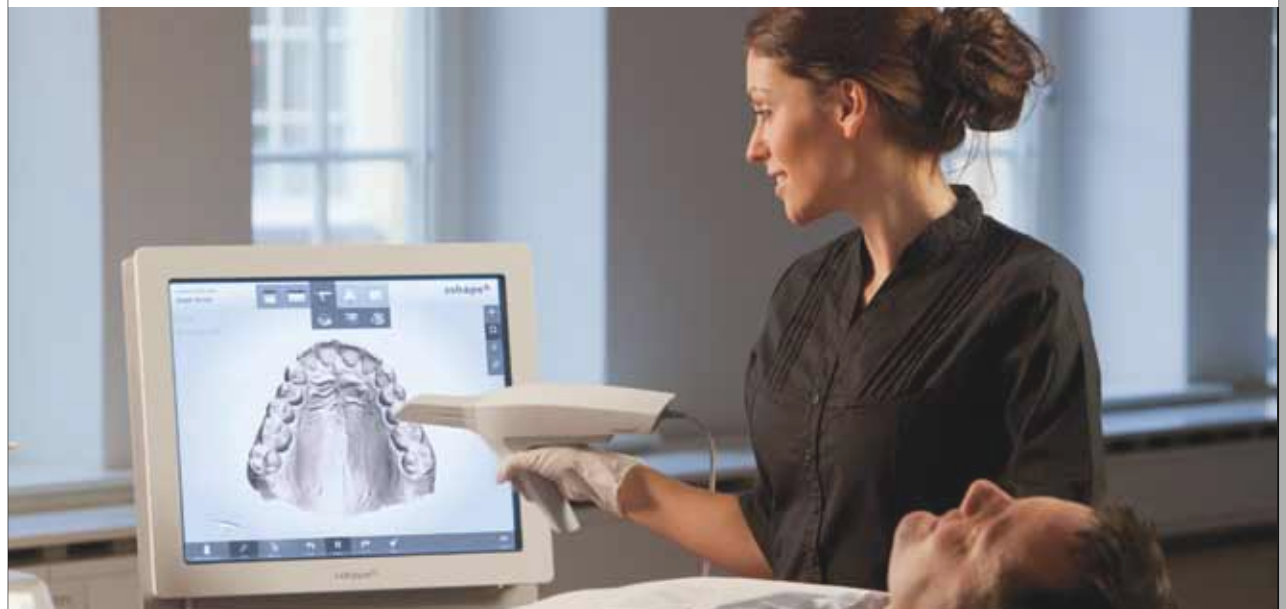Friday, Sept. 21

- 7:30-8:30 a.m.: Continental breakfast in exhibit hall (complimentary)
- 7:30 a.m.-4 p.m.: Registration/exhibit hall open
- 7:30 a.m.-4 p.m.: ABO case displays
- 8-9:30 a.m.: Staff session, Dr. Neal Kravitz, "Developing the 'Dream Team': 10 Characteristics of an Elite and Irreplaceable Orthodontic Team Member"
- 8:30-10 a.m.: Doctor session, Dr. Roger Levin, "Create the Ideal Ortho Practice, Part One" (co-sponsored by Levin Group)
- 9:30-10:30 a.m.: Beverage break in exhibit hall (complimentary)
- 10 a.m.-noon: Staff session, Tina Byrne, "Navigating as Part of the Ortho Crew: Winning May Be As Simple As Adjusting Your Sails, Part One" (co-spon-

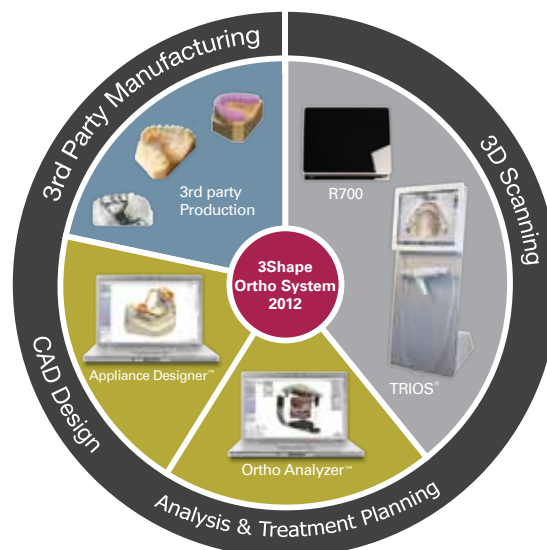
▶ See MASO, page 8

AD

**3shape**  
Technology designed the way you work



## Closing the digital loop The first open CAD/CAM system for orthodontics



3Shape TRIOS® is the new ultra-fast and easy to use chairside scanner to create accurate digital impressions in open format.

### 3Shape Ortho System

- Intraoral scans, impression/model scanning, open format STL
- Customizable analysis workflows
- Full treatment simulation, including virtual setups
- Virtual articulators for easy validation
- CAD design of any orthodontic appliance
- Free choice of manufacturing equipment and materials

See the full digital loop at an exhibition near you



Scan the QR code  
& sign up for our newsletter

Note: TRIOS® will be available in North America in 2012



# ClearCorrect reaches new milestone with charitable clean water project

ClearCorrect, a leading manufacturer of clear aligners, recently reached a milestone in its charitable project, Phase Out. Since the launch of its first initiative with "charity: water" (phase out unsafe drinking water) on Jan. 1, ClearCorrect has raised more than \$60,000, which will help about 3,000 people gain access to clean and safe drinking water.

Of the \$60,000 raised so far, \$36,555 has been allocated to funding the first five projects with charity water in the Democratic Republic of the Congo. The funding will help create spring protections, rainwater catchments and large-scale gravity-fed water systems that will have dozens of distribution points to serve a large population. These projects are planned for a mix of villages, schools and clinics with a strong focus on hygiene, sanitation training and community buy-in to ensure sustainability and prevention of water-borne diseases.

"It is hard to believe that there are still people out there that don't have safe drinking water. Phase Out is an amazing effort and an amazing project, and I'm proud to be a part of it," said Dr. Annette Murphy, ClearCorrect provider.

When asked how long the company intends to run the Phase Out project, Jarrett Pumphrey, ClearCorrect CEO, responded, "For as long as we can make a difference."

To see the video, please visit [www.clearcorrect.com/phaseout](http://www.clearcorrect.com/phaseout).



Photo/Provided by ClearCorrect

## About ClearCorrect

ClearCorrect works with more than 11,000 clinicians, making it a leading manufacturer of clear aligners. The com-

pany offers an affordable and doctor-friendly approach, including a phase-

based system to enhance flexibility and control for clinicians. For more informa-

tion, visit [www.clearcorrect.com](http://www.clearcorrect.com) or call (888) 331-3323.

## • MASO, Page 7

sored by Byrne Consulting Group)

- 10:30 a.m.–noon: Doctor session, Dr. Roger Levin, "Create the Ideal Ortho Practice, Part Two" (co-sponsored by Levin Group)

- Noon–1:30 p.m.: Box lunch in exhibit hall (complimentary)

- Noon–1 p.m.: MASO delegates meeting with MASO Board (invitation only)

- 12:15–1:30 p.m.: ABO certification information meeting

- 1–2 p.m.: Doctor session, Dr. Neal Kravitz, "Creating an Elite Orthodontics Office: A comprehensive review on how to increase case-starts, brand your office and develop a reputation within your community"

- 1:30–3 p.m.: Staff session, Tina Byrne, "Navigating as Part of the Ortho Crew: Winning May Be As Simple As Adjusting Your Sails, Part Two" (co-sponsored by Byrne Consulting Group)

- 2–3 p.m.: Doctor session, Dr. Normand Boucher, "Diagnosis and Management of Joint Related Malocclusion"

- 3–4 p.m.: Beverage break in exhibit hall (complimentary)

- 4–5 p.m.: MASO member/business meeting (all members welcome)

- 6–7 p.m.: Welcome reception in exhibit hall (complimentary; co-sponsored by Maryland State Society of Orthodontists)

## Saturday, Sept. 22

- 6:30–7:30 a.m.: Fun run and historical walking tour of Baltimore Harbor

- 7:30–8:30 a.m.: Continental breakfast in exhibit hall (complimentary; sponsored by Invisalign/OrthoCAD)

- 7:30 a.m.–4 p.m.: Registration/exhibit hall open

- 7:30 a.m.–4 p.m.: ABO case displays

- 8–9:30 a.m.: Staff session, Char Eash, "Taking Back the Specialty — Game On! Part One" (co-sponsored by Profit Marketing Systems)

- 8:15–8:30 a.m.: AAOF presentation

- 8:30–10 a.m.: Doctor session, Dr. David Sarver, "Goal-Oriented Treatment Planning and Technological Advancements, Part One"

- 9:30–10:30 a.m.: Beverage break in exhibit hall (complimentary)

- 10 a.m.–noon: Staff session, Char Eash, "Taking Back the Specialty — Game On! Part Two" (co-sponsored by Profit Marketing Systems)

- 10:30 a.m.–noon: Doctor session, Dr. David Sarver, "Goal-Oriented Treatment Planning and Technological Advance-

ments, Part Two"

- Noon–1:30 p.m.: Box lunch in exhibit hall (complimentary)

- Noon–1:30 p.m.: Component roundtable discussions

- Noon–1:30 p.m.: Educators luncheon (invitation only)

- 1:30–3 p.m.: Staff session, Char Eash, "Marketing — No Gimmicks, Just a Lesson in Building the Network from Within, Part One" (co-sponsored by Profit Marketing Systems)

- 1:30–3 p.m.: Doctor session, Dr. David Sarver, "Goal-Oriented Treatment Planning and Technological Advancements, Part Three"

- 3–3:30 p.m.: Beverage break in exhibit hall (complimentary)

- 3:30–4:30 p.m.: Staff session, Char Eash, "Marketing — No Gimmicks, Just a Lesson in Building the Network from Within, Part Two" (co-sponsored by Profit Marketing Systems)

- 3:30 p.m.–4:30 p.m.: Doctor session, Dr. Jeffrey Posnick, "Contemporary Management of Chronic Upper Airway Obstruction in a Dentofacial Deformity"

- 4:30–5:30 p.m.: Resident session, (mandatory to receive grant), Chris Bentson, "The Process of Locating a Practice to Build, Join, Partner or Purchase" (co-

sponsored by Bentson, Clark & Copple, LLC)

- 4:30–5:30 p.m.: Component business meetings/Delaware, District of Columbia, Maryland

- 6–10 p.m.: President's party — Geppi's Museum of Pop Culture (Sponsored by 3M Unitek)

## Sunday, Sept. 23

- 7–8 a.m.: MASO board meeting (invitation only)

- 7:30–8:30 a.m.: Continental breakfast in exhibit hall (complimentary)

- 7:30 a.m.–noon: Registration/exhibit hall open

- 7:30 a.m.–noon: ABO case displays

- 8:30–9:45 a.m.: Doctor session, Chris Bentson, "Benchmarking the Orthodontic Practice" (co-sponsored by Bentson, Clark & Copple)

- 9:45–10:30 a.m.: Beverage break in exhibit hall (complimentary)

- 10:30 a.m.–12:30 p.m.: Doctor/staff session, Jeff Behan, "Using the Power of Story to Grow Your Members" (co-sponsored by VisualTrust Communications)

## Information/registration

Go to [www.MASO.org](http://www.MASO.org) to register or to seek out additional information.



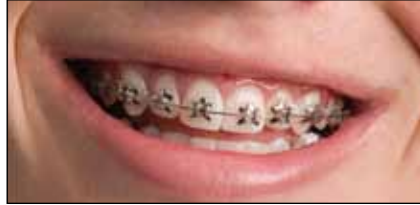# Creating a win-win in the changing landscape of orthodontic treatment

By Davin Bickford, VP for practice development, WildSmiles Braces

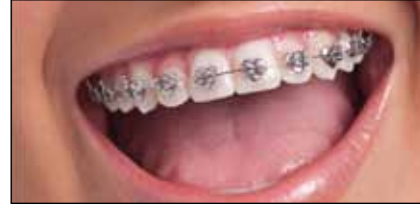Today, braces are a must-have for tweens and teens. The fact that getting braces is a big step, and often daunting for most kids, can easily get lost in the conversation. Statistics from many of the industry's leading organizations show that providing treatment focused on patient participation and "buy in" leads to happier and more compliant patients throughout treatment.

Take, for example, your expectation for personal life outside of orthodontics. Society demands a choice in the cars we drive, clothes we wear and shoes we sport. Everyone desires to be different and unique. Body art and piercing have become more and more popular in the past decade and are prime examples of societal beliefs to be different and unique.

In orthodontics, it is important to create a win-win experience for the patient and the practice. Popular choices of mini twins, clear brackets, WildSmiles Braces and clear aligners are an expression of these societal beliefs taking hold in ortho-



WildSmiles offers unique options for children and adults. (Photo/Provided by WildSmiles Braces)



odontic treatment.

Just like Nike, Lexus, Louis Vuitton, Walt Disney or Titleist, you are an orthodontic brand in your community. These brands have learned how to create a win-win experience for their customers, offering options that create customer loyalty and brand ambassadors. The company wins through brand loyalty and referrals. The customers win because they have choice to build a customized user experience with a quality brand. Simply, they get what they want!

You are a service provider, and you should be exploring every opportunity to build your brand as the go-to practice. This is only achieved through offering options that create win-win experiences, thus cre-

ating positive brand ambassadors. Patients seek out the opportunity to customize and participate in their treatment in a caring, full-service environment.

Imagine going to a high-end car dealer and being told the features you desire (leather seats, CD or DVD player, etc.) were not available. Additionally, the salesperson suggests the base model offered on the lot should sufficiently meet your needs. While it might meet your need, getting you from point A to point B, choosing the base model is not what you desired. This experience almost definitely would encourage you to continue your search for your next new car, right?

Well, the patient expectation for his or her orthodontic experience is no differ-

ent from this scenario.

In the new economy, consumers demand options, such as clear braces, WildSmiles Braces and clear aligners. As a service provider, you must be willing to create these win-win situations. Offering these options in your practice does not cost you anything but gives you the ability to meet customer expectations and create brand loyalty. It's a win-win.

Brands offering great customer experiences and a wide variety of choice seldom worry about cost on the front end, often sparing little expense to enhance the customer experience. These investments allow the brand to charge higher prices for products, retain a higher percentage of customers and facilitate greater customer loyalty and referrals.

Orthodontic customer expectations and demands are changing with the new economy. What kind of brand are you building in your community? Are you cultivating a win-win experience by offering your patients a variety of choices with a full-service experience?

To learn more, visit [wildsmilesbraces.com](http://wildsmilesbraces.com) or call (402) 334-7171.

AD

## Rock your smile.

**WildSMILES®**  
braces that rock



Stars



Football



Hearts



Flowers



Soccerballs



Super Diamonds®

Order our esthetic designer brackets online at [wildsmilesbraces.com](http://wildsmilesbraces.com) or call 402-334-7171

