

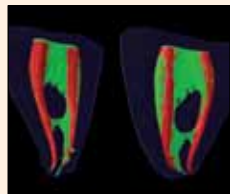
# DENTAL TRIBUNE

The World's Dental Newspaper • Indian Edition

Published in India

www.dental-tribune.com

Vol. 1 No. 1



## Trends & Applications

Endodontic retreatment  
Achieving success the  
second time around

Page 3



## World News

British researchers discover  
the origin of teeth in fish

Page 18



## Business

EAO celebrates successful  
anniversary event in  
Copenhagen

Page 22

# Titanium implants may carry risk of corrosion, study finds

DTI

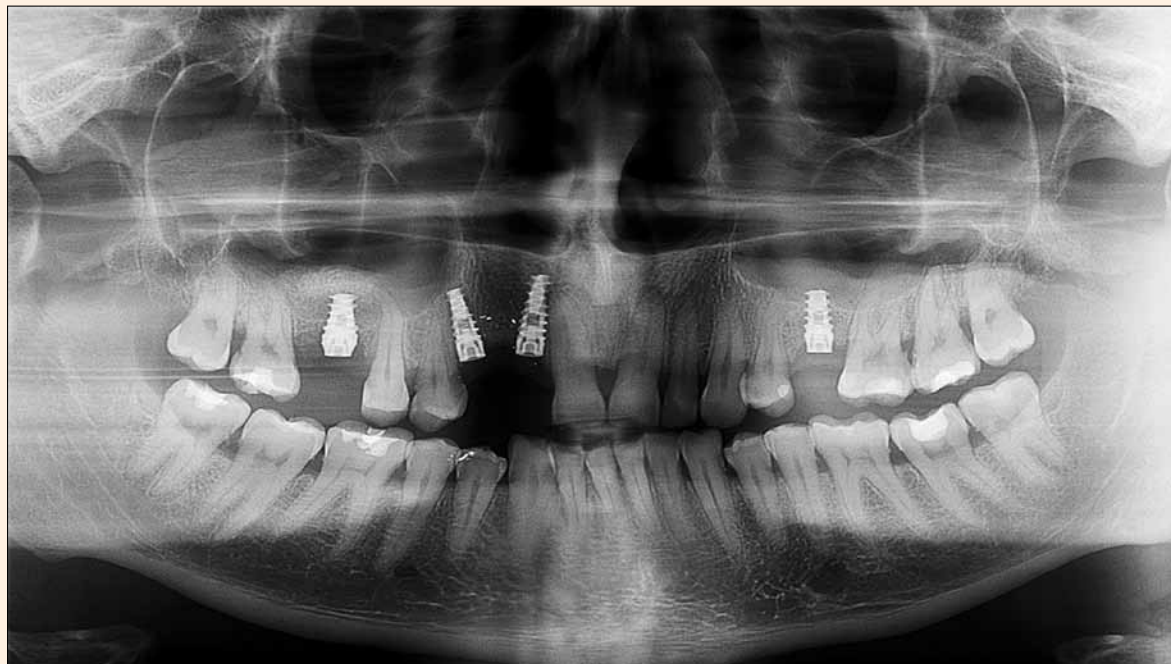**BIRMINGHAM, UK:** Titanium medical implants used in dental prostheses and bone-anchored hearing aids may be less robust than commonly believed. Researchers from the UK have recently discovered evidence to suggest that in environments where there is no significant wear process, microscopic particles of titanium can be found in the surrounding tissue, which may have a negative impact on the devices.

For the study, Dr Owen Addison in the Biomaterials unit of the University of Birmingham's School of Dentistry and his team obtained tissue from patients undergoing scheduled revision surgery associated with bone-anchored hearing aids (BAHA) at University Hospitals Birmingham NHS Foundation Trust. Soft tissue surrounding commercially pure titanium anchorage devices was examined using micro-focus synchrotron X-ray spectroscopy at the Diamond Light Source, Oxford, UK.

"The results showed, for the first time, a scattered and heterogeneous distribution of titanium in inflamed tissue taken from around failing skin-penetrating titanium implants," the authors reported. "Wear processes and implant debris were unlikely to be major contributors to the problem. In the absence of obvious macroscopic wear or loading processes, we propose that the titanium in the tissue results from micro-motion and localised corrosion in surface crevices."

Globally, more than 1,000 tonnes of titanium are implanted into patients in the form of biomedical devices every year. Metallic prostheses, fixation and anchoring devices are used extensively for dental, orthopaedic, and craniofacial rehabilitation and their effects on the body are widely perceived to be predictable following initial implantation.

The development of peri-implant inflammation may result in the premature loss of the implanted device or the requirement for revision/rescue surgery, which are scenarios that can



Panoramic dental X-ray showing several fixed tooth replacements. Microscopic particles of titanium have been found in the surrounding tissue of medical implants. (DTI/Photo Natasha Spiridonova, Ukraine)

"impact on patients' well-being and economically on the health service provider," the authors concluded in the study. "Our results emphasise the need to understand further both the physical and chemical mechanisms leading to the dispersal of titanium

species in tissue around implants and their potential to exacerbate inflammation."

Addison commented that while the findings pose no alarm to those with BAHA implants or similar devices, they demonstrate that impro-

vements in materials like titanium can be sought. Research is currently being conducted to look at the biological consequences and to understand the mechanisms by which the debris is produced. [DTI](#)

## Study links bisphosphonates to osteonecrosis of the jaw

Cumulative incidence of ONJ significantly higher among patients who had received BP

DT Asia Pacific

**KYOTO, Japan:** A new study has shown that bisphosphonates (BP), a class of drugs commonly used to treat bone diseases such as osteoporosis, is associated with an increased risk of developing severe bone disease of the maxilla and the mandible. The researchers found that especially elderly patients who had received intravenous BP had an increased risk of osteonecrosis of the jaw (ONJ).

The study was conducted among 3,216 male and female patients aged 20 or older mostly diagnosed with osteoporosis and various types of

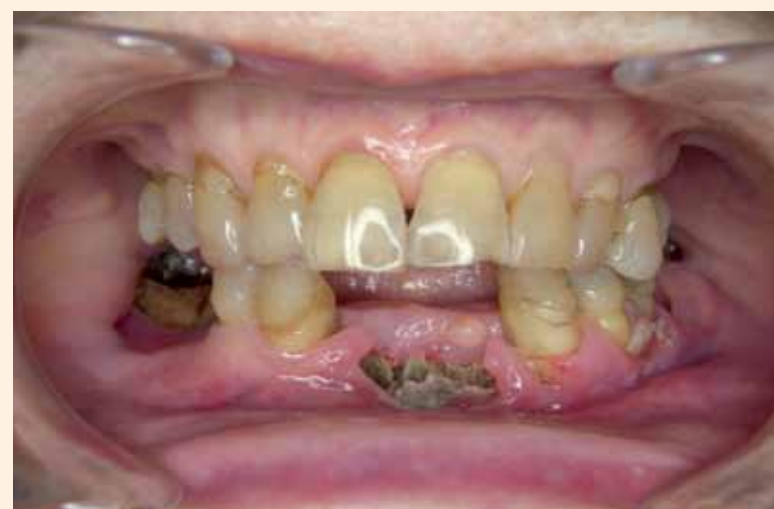cancer. They had undergone tooth extraction at the Kyoto University Hospital's Department of Oral and Maxillofacial Surgery between April 2006 and June 2009. About 4 per cent (126) had received either oral BP (99) or intravenous BP (27), while 96 per cent (3,090) had not received such treatment.

Researchers from the institute found that at 42 months following tooth extraction the cumulative incidence of ONJ was significantly higher among patients who had received BP. According to the study, five patients to whom BP had been administered developed ONJ, compared with only

one patient in the control group.

They observed a significant difference with regard to age and prevalence of cancer or osteoporosis between the two groups. The risk ratio for ONJ was particularly elevated in patients aged over 65 who had received intravenous BP, according to the researchers.

In addition, they found that alveolar bone loss could be a risk factor for BP-induced ONJ after tooth extraction. Thus, they suggested that inflammation of the periodontal tissue might predispose people to the condition, and preventive treatment of oral bacteria might be essential for a favourable



Osteonecrosis of the jaw is associated with bisphosphonate therapy, required in some cancer and bone disorder treatments. (DTI/Photo courtesy of Masashi Yamori, Department of Oral and Maxillofacial Surgery, Kyoto University, Japan)

outcome of tooth extraction.

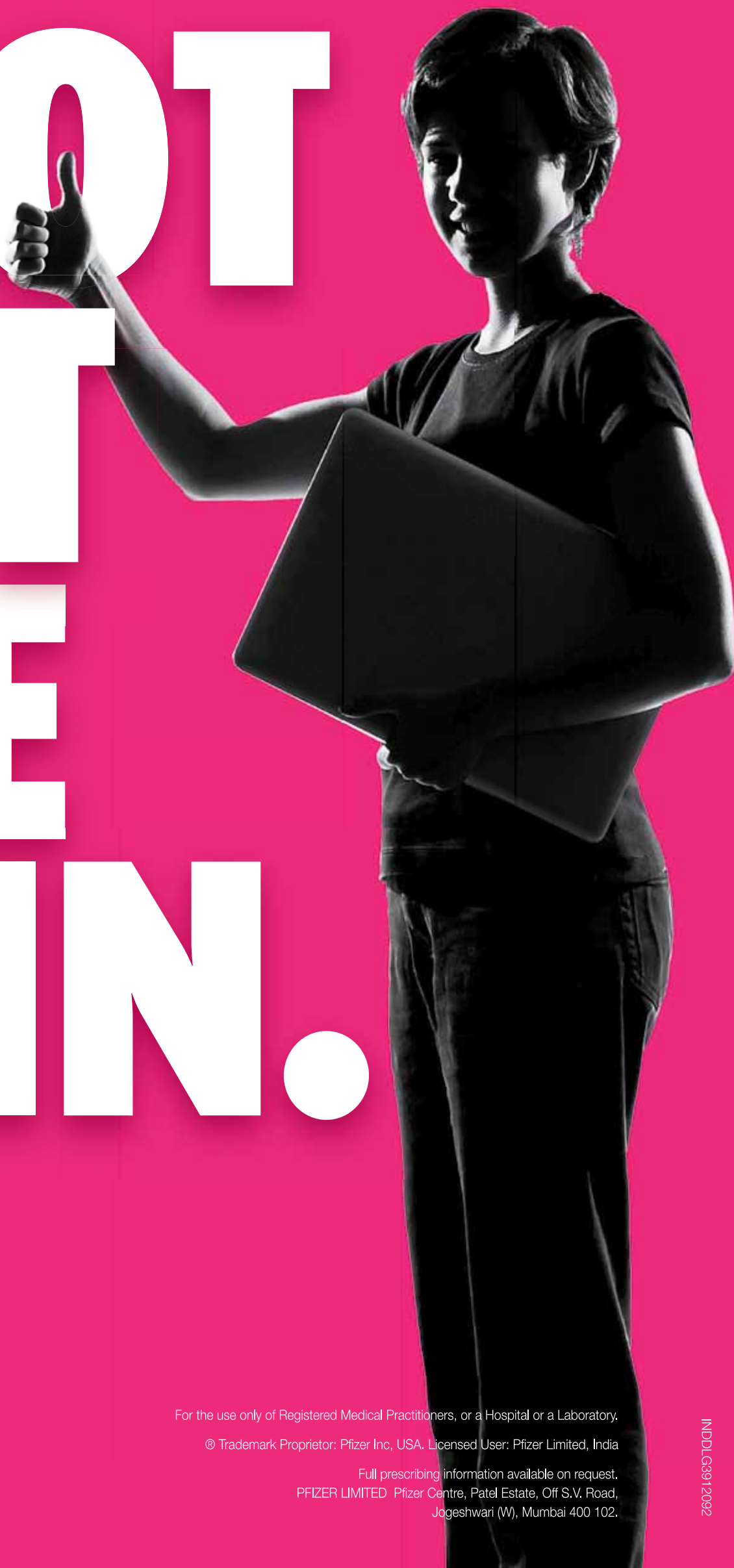BP is usually administered to prevent further bone loss, reduce pain and increase bone mineral density in patients with bone disorders. A study published in the September 2003 issue of the International Journal of Oral

and Maxillofacial Surgery was the first to suggest osteonecrosis as a side effect of bisphosphonate treatment. In the current literature, the estimated incidence of BP-induced ONJ ranges from 8.3 per cent to 40 per cent. [DTI](#)

Dolonex<sup>®</sup> piroxicam<sup>®</sup> | **IM** 40 mg/2 ml  
**DT** 20 mg  
**Gel** 5 mg/gm

HELP YOUR PATIENTS

ROOT  
OUT  
THE  
PAIN.



Working together for a healthier world™

For the use only of Registered Medical Practitioners, or a Hospital or a Laboratory.

© Trademark Proprietor: Pfizer Inc, USA. Licensed User: Pfizer Limited, India

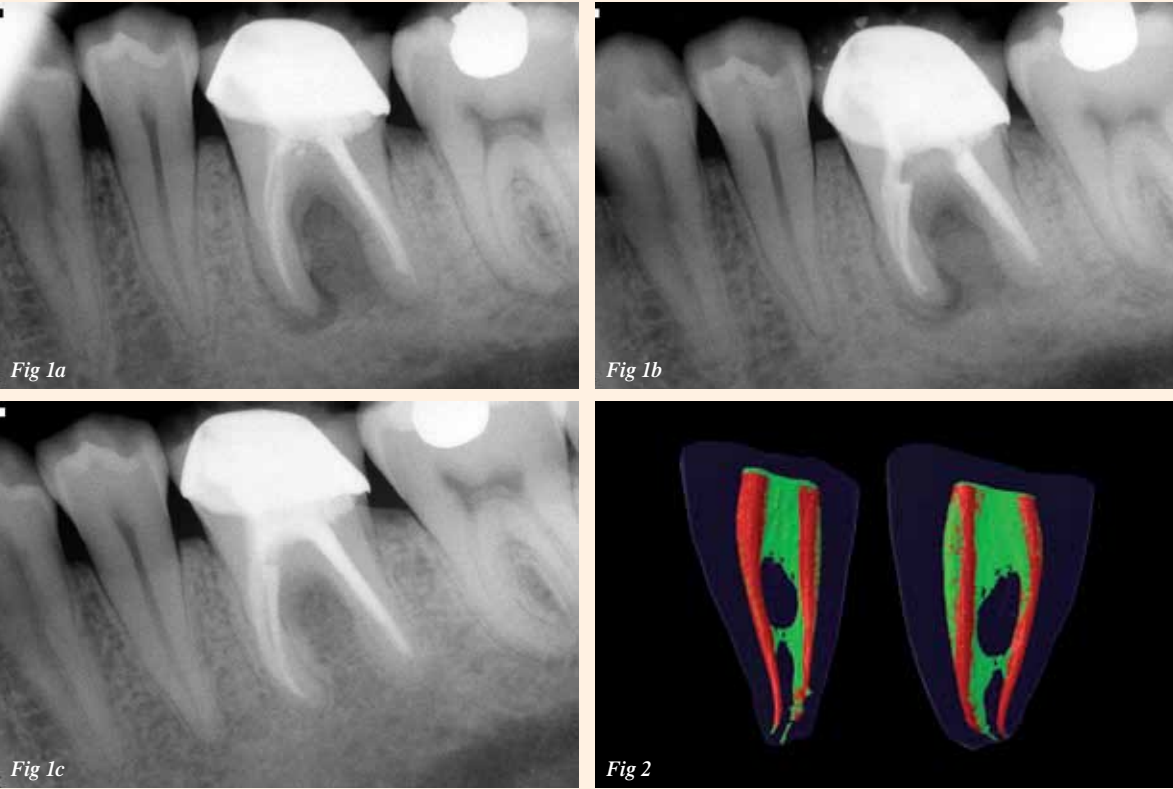
Full prescribing information available on request.  
PFIZER LIMITED Pfizer Centre, Patel Estate, Off S.V. Road,  
Jogeshwari (W), Mumbai 400 102.

INDDLG912092



# Endodontic retreatment

## Achieving success the second time around



**Fig. 1a:** Tooth #19 shows a radiolucent periapical lesion around the mesial root apex and into the furcation.—**Fig. 1b:** Post-op radiograph.—**Fig. 1c:** One-year follow-up radiograph. (Courtesy of Dr Brett E. Gilbert)—**Fig. 2:** The unprepared pulp tissue (green) and the post-op prepared or instrumented areas (red), showing the complexity of the root-canal anatomy and the difficulty in completely cleansing the root-canal system. (Courtesy of rootcanalanatomy.blogspot.com)

Dr Brett E Gilbert  
USA

Root-canal treatment has been shown to have a success rate of 92%.<sup>1</sup> However, as research methodologies move towards higher levels of substantiation, clinicians must rely on the best current evidence available to gain insight into the expected outcomes of their treatment. The highest level and best current evidence we have on the clinical success of endodontic treatment comes from a meta-analysis of the literature.

A meta-analysis done in 2007 by Ng et al provides a thorough review of endodontic success rates from a variety of classical outcome studies. They found a weighted pooled success rate of 68 to 85%, with at least one year of follow-up.<sup>2</sup> This review considers the strictest of criteria for determining that a tooth has healed, and includes many studies that were completed prior to the clinical use of dental operating microscopes and other advanced armamentaria.

When considering treatment for a tooth that has not healed successfully with root-canal therapy, there are significant challenges to address to be able to attain complete healing of the diseased tooth. The armamentarium and techniques available today allow us the ability to disinfect the root-canal system properly after initial treatment has led to post-treatment disease.

The success rate of retreatment has been shown to be in the range of 80% healing. Phases III and IV of the Toronto Study showed such a healing rate four to six years after non-surgical retreatment.<sup>3</sup> In a systematic review by Torabinejad et al comparing non-surgical retreatment to endodontic surgery,

it was demonstrated that non-surgical retreatment had a success rate of 83% versus 71.8% for endodontic surgery after four to six years.<sup>4</sup>

The presence of pretreatment apical periodontitis is one factor that has been shown to decrease the success rate. Without apical periodontitis, a ten-year success rate of 92 to 98% has been shown for both initial and retreatment root-canal therapy. With the preoperative presence of apical periodontitis, there is a decrease in the success rate from 74% to 86% over the ten years.<sup>5</sup> From this, it is evident that endodontic healing is attainable through retreatment procedures, allowing us to maintain our patients' natural teeth (Figs 1a–c). Although the alternative clinical treatment option of implant placement can provide an effective method for replacing a missing tooth, healthy maintenance of the natural tooth should remain the overall goal.

Post-treatment disease is, inevitably, a result of bacteria and the host response of the patient to the bacteria. These microorganisms are the most critical aetiology of post-treatment disease, as they are present within the root-canal system of a previously endodontically treated tooth owing to a combination of substandard endodontic techniques, iatrogenic treatment issues and restorative failure.

Intra-radicular bacteria are the primary aetiology of post-treatment disease<sup>6</sup> and eradication of these bacteria is the primary goal of retreatment procedures. The intra-radicular bacteria present in the previously treated tooth are persistent and resist removal methods. Bacteria are able to hide and survive in canal ramifications, deltas, irregularities (fins) and

dentinal tubules.<sup>7</sup>

Figure 2 shows the complex root-canal anatomy preoperatively (green areas) and the minimal amount of canal-wall cleansing that was accomplished during canal instrumentation (red areas). The remaining green areas illustrate the space that might be left untreated, thereby providing a source of bacteria and supporting substrate for intra-canal infection. The potential substrates that are found inside the canal and help the bacteria survive can include untreated pulp tissue, the presence of a biofilm and tissue fluid. This may be present in the canal owing to a poor coronal or radicular seal and microbial proliferation. The presence of a poor seal, bacteria and substrate for their growth results in ideal conditions for persistent inflammation and disease.<sup>9</sup>

The bacteria present in the initial infection of a root canal differ markedly from the bacteria infecting a previously treated tooth. Pretreatment flora is polymicrobial with equal numbers of Gram-negative and -positive bacteria. Post-treatment bacteria are predominantly Gram-positive<sup>10</sup> and they have been shown to be able to survive in harsh environments and to be resistant to many treatment methods.

There are high numbers of *Enterococcus species*.<sup>11</sup> *Enterococcus faecalis*, for example, has been shown to be a common isolate in 27 to 77% of teeth with post-treatment disease.<sup>12</sup> A contaminated canal space may result from incomplete cleansing initially or subsequent leakage into root-canal spaces following root-canal treatment. Once present inside the canals, *E. faecalis* has a variety of characteristics that allow it to evade our best efforts to eradicate it from

the root-canal system, including the ability to invade dentinal tubules and adhere to collagen.<sup>13</sup> It is also resistant to calcium hydroxide application inside the canal system, which is an inter-appointment treatment technique used to help remove microorganisms and their by-products, such as lipopolysaccharides, from the canal space.<sup>14,15</sup> *E. faecalis*'s resistance of calcium hydroxide action arises from its ability to pump hydrogen ions from a proton pump. The hydrogen combines with the hydroxyl ions of calcium hydroxide and neutralises the high pH value.<sup>16</sup>

*E. faecalis* is also able to resist calcium hydroxide by being part of a biofilm. The protection of bacteria within a biofilm matrix prevents the contact of the bacteria with irrigants and medicaments, and allows communication between bacteria to aid in survival capabilities.<sup>17,18</sup> The presence of *E. faecalis* is well documented;

however, its role in post-treatment disease has yet to be proven definitively.<sup>19</sup> Its survival mechanisms, however, shine a light on the persistent capabilities of these bacteria, and our clinical techniques must be focused on the challenge of eliminating them.

Iatrogenic issues encountered during the initial root-canal treatment may be the cause of intra-canal bacterial infection. These issues may include perforation, incomplete cleansing and shaping, inadequate canal enlargement, missed canals, ledging, canal transportation, over-instrumentation, as well as obstruction of the canal by debris or separation of instruments. Failure to use or using too small a volume of an appropriate irrigant solution, such as sodium hypochlorite, is an iatrogenic error.

Full-strength 6% sodium hypochlorite has been shown to be highly antimicrobial and able to dissolve tissue and disrupt bacterial biofilm.<sup>20,21</sup> These qualities in an irrigant are ideal for the debridement of residual bacteria and tissue debris. The use of a rubber dam to isolate the treatment field is the standard of care for endodontic treatment. Failure to use a rubber dam

### International Imprint

Licensing by Dental Tribune International Publisher Torsten Oemus

**Group Editor**  
Daniel Zimmermann  
newsroom@dental-tribune.com  
+49 341 48 474 107

**Clinical Editor**  
Magda Wojtkiewicz

**Online Editor**  
Yvonne Bachmann

**Editorial Assistant**  
Claudia Duschek

**Copy Editors**  
Sabrina Raaff  
Hans Motschmann

**Publisher/President/CEO**  
Torsten Oemus

**Director of Finance & Controlling**  
Dan Wunderlich

**Media Sales Managers**  
Matthias Diessner  
Peter Witteczek  
Maria Kaiser  
Melissa Brown  
Vera Baptist

**Marketing & Sales Services**  
Esther Wodarski

**License Inquiries**  
Jörg Warschat

**Accounting**  
Karen Hamatschek

**Business Development Manager**  
Bernhard Moldenhauer

**Executive Producer**  
Gernot Meyer

**International Editorial Board**  
Dr Nasser Barghi, USA – Ceramics  
Dr Karl Behr, Germany – Endodontics

Dr George Freedman, Canada – Aesthetics  
Dr Howard Glazer, USA – Cariology  
Prof Dr I. Krejci, Switzerland – Conservative Dentistry  
Dr Edward Lynch, Ireland – Restorative  
Dr Ziv Mazor, Israel – Implantology  
Prof Dr Georg Meyer, Germany – Restorative  
Prof Dr Rudolph Slavicek, Austria – Function  
Dr Marius Steigmann, Germany – Implantology

© 2013, Dental Tribune International GmbH. All rights reserved.

Dental Tribune makes every effort to report clinical information and manufacturer's product news accurately, but cannot assume responsibility for the validity of product claims, or for typographical errors. The publishers also do not assume responsibility for product names or claims, or statements made by advertisers. Opinions expressed by authors are their own and may not reflect those of Dental Tribune International.

**Dental Tribune International**  
Holbeinstr. 29, 04229 Leipzig, Germany  
Tel.: +49 341 4 84 74 302 | Fax: +49 341 4 84 74 173  
www.dental-tribune.com | info@dental-tribune.com

**Regional Offices**

**Asia Pacific**  
Dental Tribune Asia Pacific Limited  
Room A, 20/F, Harvard Commercial Building,  
111 Thomson Road, Wanchai, Hong Kong  
Tel.: +852 3113 6177 | Fax: +852 3113 6199

**The Americas**  
Dental Tribune America  
116 West 23rd Street, Ste. 500, New York, N.Y.  
10011, USA  
Tel.: +1 212 244 7181 | Fax: +1 212 224 7185

## Dental Tribune India Edition

Published by Jaypee Brothers Medical Publishers (P) Ltd., India

© 2013, Dental Tribune International GmbH. All rights reserved.

Dental Tribune India makes every effort to report clinical information and manufacturer's product news accurately, but cannot assume responsibility for the validity of product claims, or for typographical errors. The publishers also do not assume responsibility for product names or claims, or statements made by advertisers. Opinions expressed by authors are their own and may not reflect those of Dental Tribune International.

**Chairman DT India**  
Jitendar P Vij  
jaypee@jaypeebrothers.com

**Director**  
P N Venkatraman  
venkatraman@jaypeebrothers.com

**Dental Tribune India**  
Published by: Jaypee Brothers Medical Publishers (P) Ltd.  
4838/24, Ansari Road, Daryaganj  
New Delhi 110002, India  
Phone: +91 11 43574357  
e-mail: jaypee@jaypeebrothers.com  
Website: www.jaypeebrothers.com



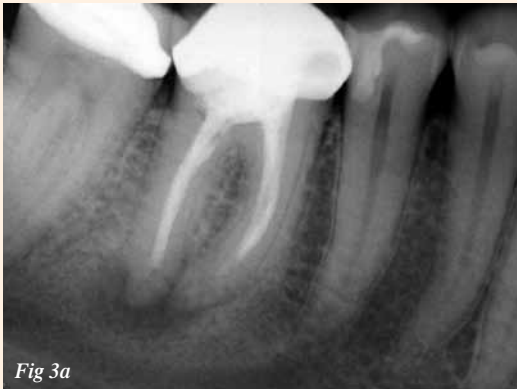

Fig 3a

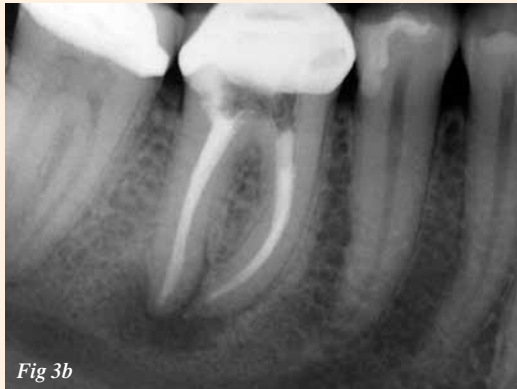

Fig 3b

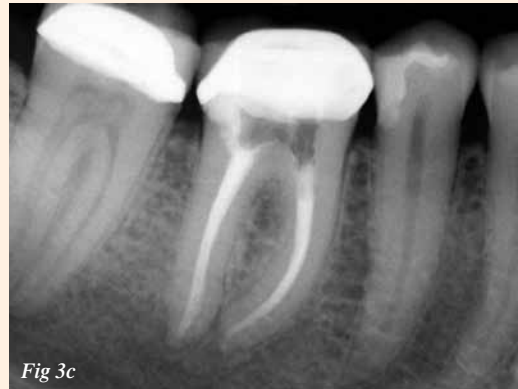

Fig 3c

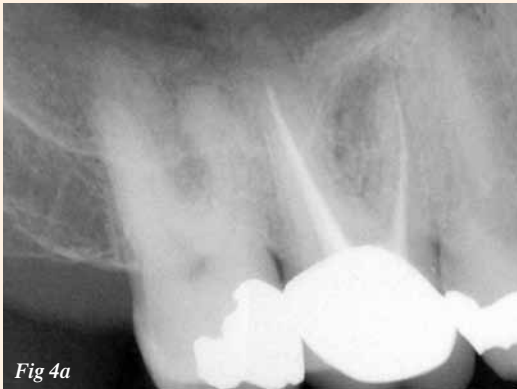

Fig 4a

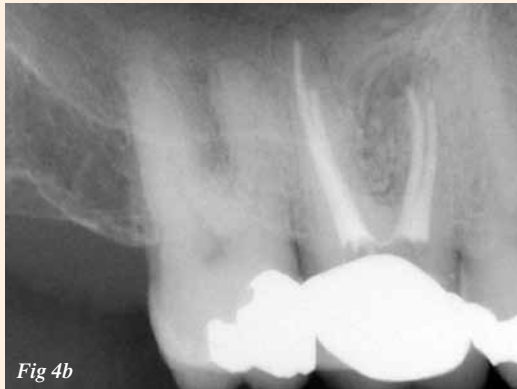

Fig 4b

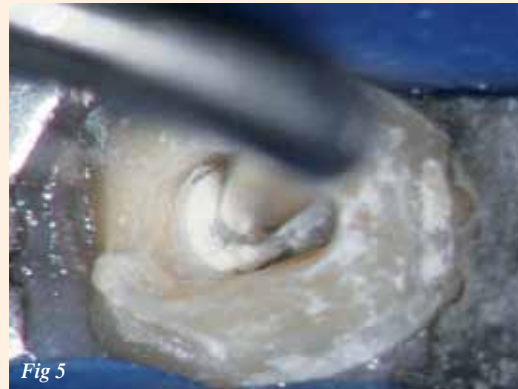


Fig 5

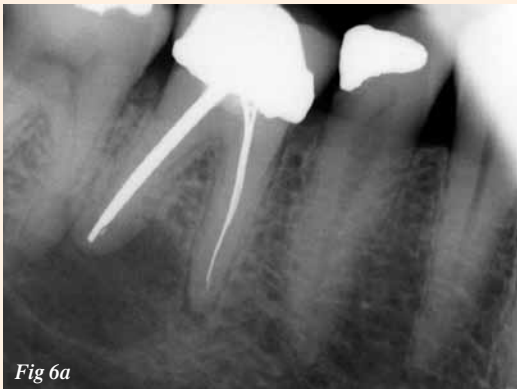

Fig 6a

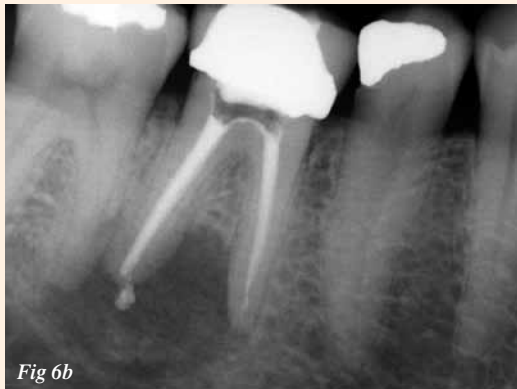

Fig 6b

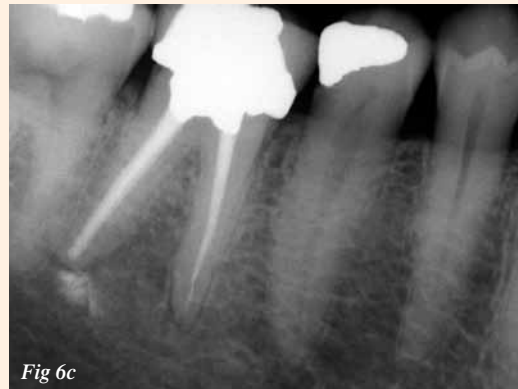

Fig 6c

**Fig. 3a:** Tooth #30 with a radiolucent periapical lesion with evidence of incomplete cleansing, shaping and obturation.—**Fig. 3b:** Post-op radiograph.—**Fig. 3c:** Thirteen-month follow-up radiograph. (Courtesy of Dr Brett E Gilbert)—**Fig. 4a:** Tooth #3 with a radiolucent periapical lesion on the mesiobuccal root apex.—**Fig. 4b:** Post-op radiograph showing treatment of the second mesiobuccal canal and appropriate lengths on retreatment of the distobuccal and palatal canals. (Courtesy of Dr Brett E Gilbert)—**Fig. 5:** Photograph displays excellent visibility and magnification of the pulp chamber with the use of an ultrasonic tip. (Courtesy of Dr Scott Bentkover, USA)—**Fig. 6a:** Tooth #3 with silver-point fillings in the mesial root and a large post in the distal root. A large radiolucent periapical lesion is evident on the distal root.—**Fig. 6b:** Post-op radiograph.—**Fig. 6c:** Thirteen-month follow-up radiograph. (Courtesy of Dr Brett E Gilbert)

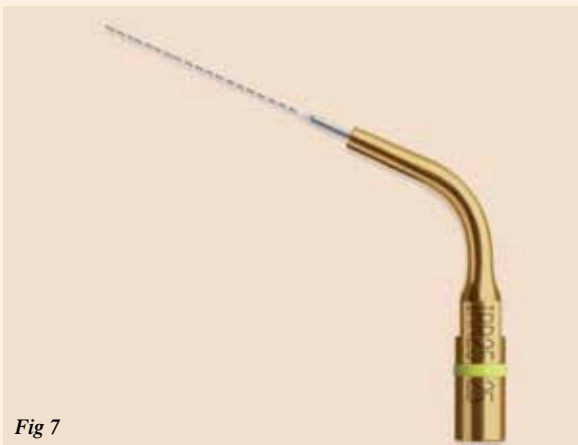

Fig 7

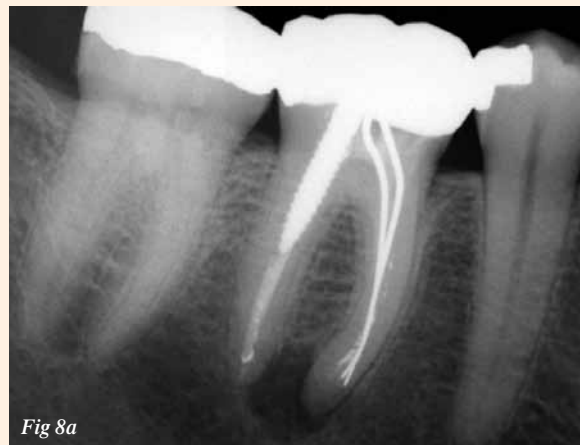

Fig 8a

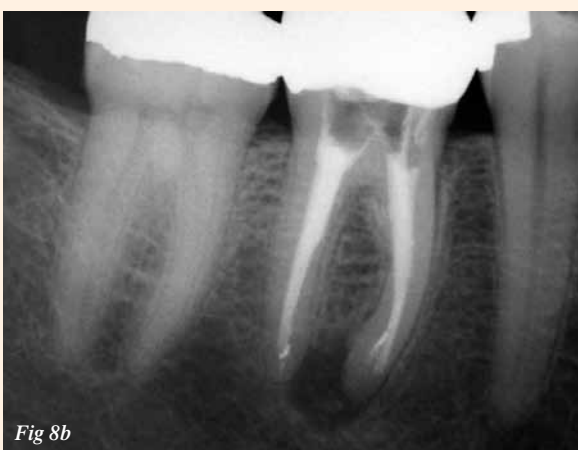

Fig 8b

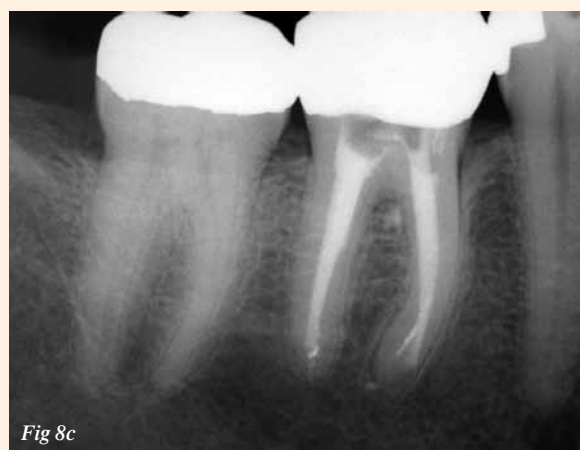

Fig 8c

**Fig. 7:** IrriSafe tip from Satelec. (Courtesy of Acteon Group, France)—**Fig. 8a:** Tooth #30 with silver-point fillings in the mesial root and a post in the distal root. The mesial root canal preparations are transported towards the mesial. There is a radiolucent periapical lesion.—**Fig. 8b:** Post-op radiograph.—**Fig. 8c:** Fifteen-month follow-up. (Courtesy of Dr Brett E Gilbert)

may be a fundamental contributor to post-treatment disease. The following case illustrates the ability to overcome prior incomplete treatment to achieve successful healing (Figs 3a–c).

### Clinical example

Restorative failure is a common cause of post-treatment disease. Failure to place an effective permanent access restoration in a timely manner can allow for bacterial entry into the root-canal system by coronal leakage. Submar-

ginal leakage on a crowned tooth can also allow bacterial entry to occur.

Decay in a previously treated tooth is another source of bacterial contamination. Structural damage to a tooth by trauma, cracking or fracture may provide an entry point for bacterial contamination of the canals. Our patients are responsible for their own oral health and must commit to effective oral hygiene techniques. Failure of the patient to perform effective

oral hygiene can result in the failure of even the most well-executed root-canal and restorative treatments.

With the bacterial challenges clinicians have to face, retreatment techniques must be capable of effective elimination of bacteria and their substrates. The use of a dental operating microscope and ultrasonic instruments allows clinicians to uncover all existing canal anatomy properly to ensure that they are able to cleanse

the root-canal system completely. The following clinical case (Figs 4a & b) illustrates the extent of the canal space left untreated in the initial root-canal therapy by not opening the mesiobuccal canal adequately and not locating and cleansing the hidden second mesiobuccal canal.

Endodontic ultrasonic tips are highly efficient at removing core build-up material, paste fills, posts and silver-point fillings, as demonstrated in Figure 5. These instruments allow clinicians to conserve root dentine by providing excellent visibility under a dental operating microscope, thereby greatly improving the ability to retreat canals (Figs 6a–c). A heat source such as a System B tip (Axis, SybronEndo) is efficient for the removal of gutta-percha and resin materials from the coronal third. Hand and rotary files can remove root fillings and shape canals to appropriate working lengths. Current NiTi rotary files are highly flexible and resistant to separation and allow us to mechanically enlarge the apical third of root canals safely and efficiently without alteration of the natural canal morphology, which allows effective irrigation to reach the complex apical root-canal anatomy where bacteria are able to hide and resist debridement.

Once the canals have been located and instrumented, the ability to irrigate becomes essential to successful treatment. The irrigant solutions target the bacteria we are trying to eliminate. While sodium hypochlorite is a potent and proven antimicrobial and tissue dissolver,<sup>22</sup> 2% chlorhexidine

has been shown to prevent the adhesion of *E. faecalis* to dentine.<sup>23</sup> EDTA 17% is often used as an effective smear layer removal agent.<sup>24</sup> Therefore, mechanical debridement and canal instrumentation provide a pathway for copious chemical irrigation deep into the canal.

Passive ultrasonic irrigation allows clinicians to place an irrigant solution into the pulp chamber and activate it as it is carried down to the apical end of the root canal. The IrriSafe tip from Satelec (Acteon; Fig 7) is a non-cutting ultrasonic file that is placed into each canal and is moved up and down in the canal for three cycles of 20 seconds. Passive ultrasonic irrigation has been shown to irrigate lateral canals better at 4.5 and 2 mm from the working length of canals as compared with needle irrigation alone.<sup>25</sup> It has been demonstrated that passive ultrasonic irrigation can remove dentine debris in a canal up to 3 mm in front of where the tip extends apically in straight or curved canals.<sup>26</sup> This evidence shows that an effective flow of irrigation can assist in the cleansing of teeth in which canal alteration occurred during the initial root-canal treatment.

The following silver-point case (Figs 8a–c), with a large distal post and apical transportation in the mesial root, demonstrates the successful healing of post-treatment disease when proper disinfection has been accomplished. This case illustrates the reason that retreatment is the primary treatment option for post-treatment disease.

Once debridement and disinfection have been completed, appropriate obturation methods are used to seal the canal spaces. The warm vertical technique using gutta-percha or resin with an appropriate sealing agent provides a thorough seal of the well-cleansed and shaped canal spaces. The final restoration must provide a proper seal of the pulp chamber to prevent coronal micro-leakage.

Current evidence has demonstrated that we can retreat previously endodontically treated teeth properly and successfully. The literature has also shown that specific bacteria, such as *E. faecalis*, are able to survive inside a previously filled canal. The use of a dental operating microscope, ultrasonic instruments, irrigants, rotary NiTi files and appropriate obturation materials increases our ability to attain healing after retreatment. As we continue to strive to maintain healthy natural teeth for our patients, endodontic retreatment should be the primary option for patients with post-treatment disease.

*A complete list of references is available from the publisher.*<sup>DT</sup>



### Contact Info

Dr Brett E Gilbert has a full-time private practice specialising in endodontics in Niles, Illinois, USA. He also lectures nationally and internationally on clinical endodontics. He can be contacted at [kingendo@kingendo.com](mailto:kingendo@kingendo.com).



# Silane coupling agents and surface conditioning in dentistry

Dr Christie Ying Kei Lung,  
Jukka Pekka Matinlinna  
Hong Kong & Finland

**In dental restorations, it is desirable to have durable and strong bonding between resin composite and dental restorative materials. Weak bonding at the interface can be dramatically enhanced with a coupling agent.**

Silane coupling agents, which are synthetic hybrid inorganic-organic compounds, are used to promote adhesion between dissimilar materials. They are good at promoting adhesion in silica-based materials such as porcelain. However, adhesion in non-silica-based restorative materials such as zirconia, metals and metal alloys is not satisfactory.

A solution to this problem may be surface conditioning of the restorative materials. Currently, a widely used surface-conditioning method in dentistry is tribochemical silica coating. After this treatment, a silica layer is formed on the surface so that the silane coupling agent can react chemically to form a durable bond with non-silica-based materials. Moreover, this treatment increases surface roughness, which will enhance micromechanical interlocking for bonding.

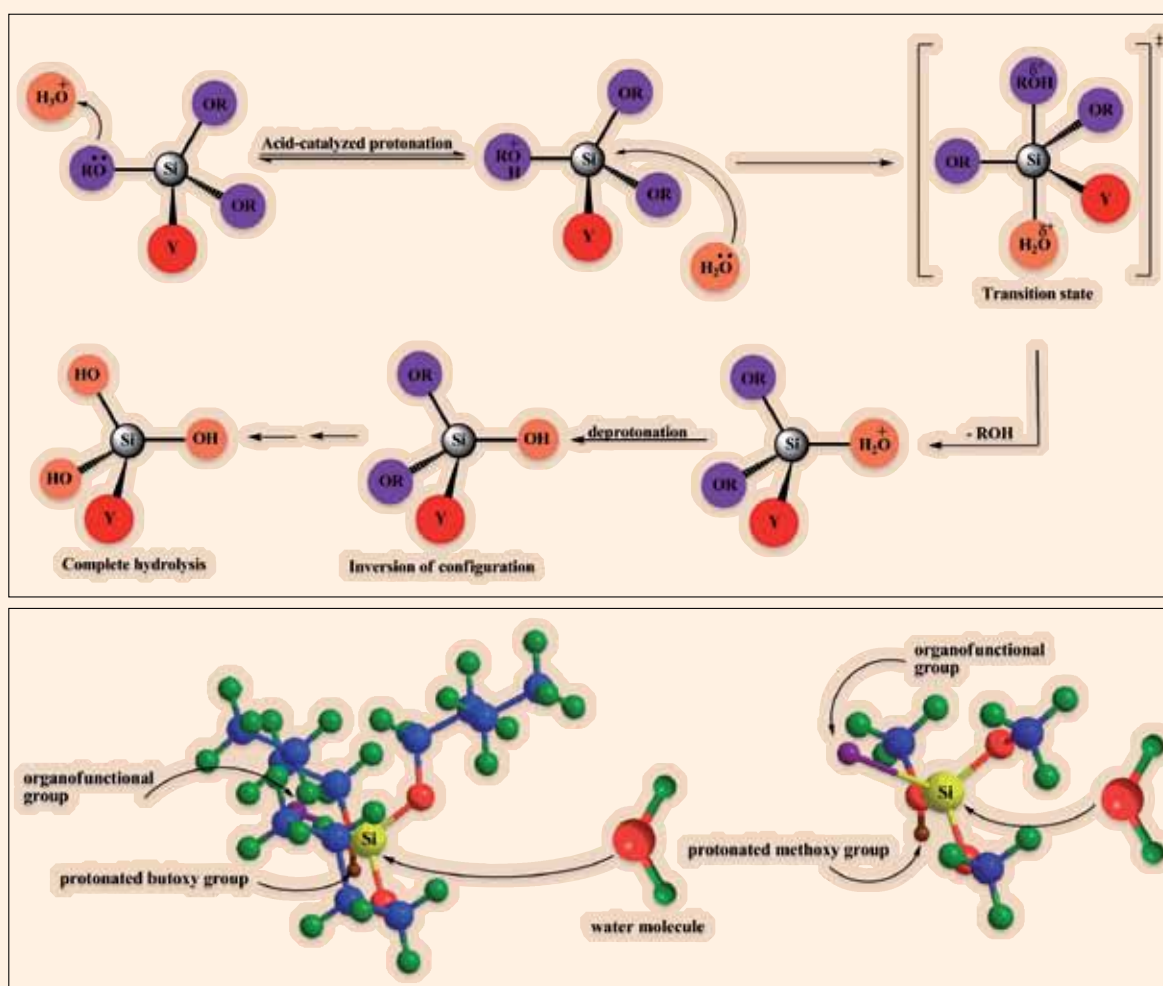
This review will discuss surface-conditioning methods and some new surface-conditioning techniques, silane chemistry, silane application in dentistry, and the limitations of silanes in adhesion promotion.

The silane monomer most commonly used in clinical commercial products is 3-methacryloxypropyltrimethoxysilane. This is pre-hydrolysed in a solvent mixture usually consisting of ethanol and water that is acidified with acetic acid.

The shelf life for a single-bottle silane solution is relatively short. The solution will turn cloudy over time and cannot be used for adhesion. Two-bottle silane systems have been developed to offer a more stable system. One bottle contains an unhydrolysed silane in ethanol and the other one contains an aqueous acetic acid solution.<sup>1</sup> The two solutions are mixed for silane hydrolysis before use.

## Surface-conditioning methods

The surface conditioning of restorative materials is an important preliminary step in clinical practice to modify surface properties for durable and hydrolytically stable adhesion. The surface pretreatment methods widely used in dental technology are grit blasting, tribochemical silica coating and hydrofluoric acid etching, which will be discussed briefly in the following section.



**Fig. 1:** The silane hydrolysis mechanism.—**Fig. 2:** The steric effect of alkoxy groups on silane hydrolysis using ball-and-stick models between butoxysilane and methoxysilane.

### Grit blasting

The surface of materials such as metals, alloys and some ceramics is sand-blasted with alumina particles of 110  $\mu\text{m}$  in size at a perpendicular distance of 10 mm under an air pressure of 380 kPa for ten to 15 seconds.<sup>2</sup> This process is intended to increase the surface roughness of the materials. It also enhances micromechanical retention for bonding.<sup>3</sup>

### Pyrochemical silica coating

Over the years, several silica-coating systems have been used in dental laboratories. Briefly, they are Silicoater Classical, Silicoater MD and Siloc (all Heraeus Kulzer) and PyrosilPen (SURA Instruments).<sup>2</sup> In these systems, a tetraethoxysilane solution is injected into a flame and burned with butane in oxygen. The silane decomposes and forms reactive  $\text{SiOx-C}$  fragments, which are deposited on the substrate surface. A glass-like silica layer is thereby formed on the surface.<sup>4</sup> The use of this surface treatment is not popular in clinical practice.

### Tribochemical silica coating

The tribochemical Rocatec system (3M ESPE) that uses silica-coated alumina particles was introduced in 1989. It is indicated for silica coating of ceramic and metal surfaces.<sup>5</sup> It enhances the adhesion of a silane coupling agent to a silica-coated material by forming a durable siloxane  $\text{Si-O-Si}$  bond. This surface treatment also increases the surface roughness that provides micromechanical retention

for resin bonding, that is, for the resin to penetrate pores on the surface.<sup>6,7</sup>

### Hydrofluoric acid etching

Hydrofluoric acid is normally used to etch porcelain veneers and for intra-oral repair of fractured porcelain restorations before cementation.<sup>1</sup> Low concentrations of 4 to 10 % hydrofluoric acid are used in clinical practice. When a porcelain surface is etched with hydrofluoric acid etching gel, the acid dissolves the glassy matrix of the porcelain. A microscopically porous and micro-retentive surface is thus produced and micromechanical interlocking for resin bonding is enhanced.<sup>9</sup>

## New surface-conditioning methods

The quest for enhanced and durable bonding continues. Several new surface-conditioning methods are currently under investigation globally. These include laser surface treatment<sup>9,10</sup> selective infiltration etching<sup>11</sup> nanostructured alumina coating<sup>12</sup> internal coating<sup>14</sup> chemical vapour deposition<sup>14</sup> and plasma fluorination.<sup>16</sup>

### Laser surface treatment

Laser stands for light amplification by stimulated emission of radiation and the technology was introduced in the 1950s. Er:YAG, Nd:YAG, and  $\text{CO}_2$  lasers are used in dentistry for soft-tissue surgery and hard-tissue treatment and surface treatment.<sup>10</sup> Laser irradiation of a ceramic surface produces irregularities on the surface,

which increase the surface roughness for mechanical retention.<sup>16</sup> The main problem, however, of this surface treatment method is the formation of surface cracks owing to thermal effects of laser irradiation at high power settings.<sup>10,16</sup> Therefore, appropriate laser settings for different ceramic surfaces is important to prevent formation of surface cracks.

### Selective infiltration etching

In this method, a thin layer of a glass conditioning agent is coated on to the zirconia surface and is then heated to above the glass transition temperature. The molten glass particles may infiltrate between the surface grains. After this process, the specimens are allowed to cool at room temperature. The conditioning agent is then removed by applying hydrofluoric acid and rinsing it off. This creates a new retentive surface for resin-zirconia bonding.<sup>17</sup>

### Nanostructured alumina coating

In this coating method, the zirconia is immersed in a suspension of aluminium nitride. Aluminium nitride undergoes hydrolysis to form boehmite, which is deposited on to the zirconia surface. A heat treatment at 900°C is carried out. Boehmite undergoes a phase transition to  $\alpha$ -alumina. Through this treatment, a micro-retentive surface area is created that may increase mechanical interlocking for resin bonding.<sup>13</sup>

### Internal coating with porcelain

The zirconia surface is sand-bla-

sted with alumina particles of 70  $\mu\text{m}$  in size. Then, the surface is coated with high fusing porcelain, which is prepared by stirring the porcelain powder into an excess amount of distilled water. The porcelain is fired at a high temperature in a vacuum. After the firing process, the surface is sand blasted again. A silica-containing layer forms on the zirconia surface. This enhances adhesion with a silane coupling agent, that is, siloxane linkage formation.<sup>14</sup>

### Chemical vapour deposition

In a chemical vapour deposition system, the zirconia surface is exposed to a vapour mixture of tetrachlorosilane and water. The silane hydrolyses and a  $\text{SixOy}$  seed layer is deposited as a coating on the surface. The thickness of the seed layer is controlled by deposition time. This silica seed layer provides the reactive sites for the silane coupling agent.<sup>15</sup>

### Plasma fluorination

In a plasma reactor, the zirconia surface is exposed to sulphur hexafluoride plasma. An oxyfluoride layer is formed on the surface. This layer may increase the reactivity of zirconia towards a silane coupling agent. However, the exact mechanism of the bonding formation between the zirconium oxyfluoride layer with silane is still unclear.<sup>15</sup>

## Silane chemistry

### Functional and non-functional silanes

Functional silanes contain two different functional groups that can react with inorganic matrices, for example ceramics, and organic materials, for example resins. Therefore, they can be used as coupling agents to connect dissimilar materials.

There is also a group of silanes called the non-functional silanes. They contain one reactive functional group that can react with inorganic materials. They are widely used for some specific surface modification of materials. In addition, there are bis-functional/cross-linking/dipodal silanes that possess two silicon atoms with three hydrolysable alkoxy groups. Cross-linking silanes are used in the steel and tyre industries.<sup>18</sup> Such silane is also incorporated with functional silane to increase the bonding and hydrolytic stability of resin composite to titanium.<sup>19</sup>

### Silane activation mechanism

Silanes can create a bond between inorganic and organic materials. A general formula for a functional silane coupling agent is  $\text{Z-(CH}_2\text{)}_n\text{-Si(OR)}_3\text{-Z}$  is an organo-functional group that reacts with organic resin,  $(\text{CH}_2)_n$  is a linker group, and OR is an alkoxy group. The alkoxy groups

are activated by hydrolysis ( $\text{SiOR} \rightarrow \text{SiOH}$ ) before they react with the surface hydroxyl groups of the substrate.<sup>20</sup>

The first step of silane hydrolysis is the fast and reversible protonation of the alkoxy group at a low pH (3–5). Next, a bimolecular nucleophilic substitution ( $\text{SN}_2$ ) reaction at the silicon atom takes place. A nucleophile, a water molecule, attacks backside to the silicon atom, an electrophile, to form a penta-coordinate transition state. A new bond is formed between the silicon and the nucleophile, and a bond is cleaved between the silicon and the leaving group, alcohol. This yields the product with an inversion of the configuration.<sup>21</sup> A suggested mechanism for silane hydrolysis is shown in **Figure 1**.

The silane hydrolysis rate depends on the steric (size) and inductive (electronic) effects of alkoxy groups on the silane. The steric effect is the dominant factor that affects the silane hydrolysis rate.<sup>22</sup> This effect is best illustrated using a ball-and-stick model (**Fig. 2**).

As shown in **Figure 2**, the steric repulsion increases when the size of the alkoxy group is changed from a methoxy to butoxy group. The approach of a water molecule, a nucleophile, to the silicon atom is more difficult for the bulky butoxy groups. This may explain why ethoxysilanes are employed in commercial dental products because of fast hydrolysis of small ethoxy groups. Methoxysilanes are not used, as the by-product methanol is very toxic.

The organo-functional groups of silane coupling agents consist of,

for example,  $\text{>C=C<}$ , a vinyl double bond that can react with the functional groups of resin composite consisting of  $\text{>C=C<}$  bonds. The reaction is initiated by the initiators in the resin composite, which are decomposed by visible blue light to form free radicals. These free radicals react with the  $\text{>C=C<}$  bond in the resin composite monomer or in the silane molecule to generate another free radical species. The reaction of these free radicals with resin composite monomers and silane molecules forms new C-C single bonds. Therefore, the silane coupling agents connect the resin composite and the inorganic substrate surface.<sup>23</sup>

### Application of silanes in dentistry

#### Ceramic restorations and repairs

Silane coupling agents are used in dental restoration, such as ceramic repairs of onlays, inlays, crowns and bridges. For most patients, repair is more economical and time-saving than the fabrication of new restorations, unless damage due to a fracture is beyond repair. The clinical procedure for repairing ceramic restoration usually involves the following steps: roughening the surface with diamond burs, sand-blasting the surface, acid etching, silanisation and finally bonding to resin composite.<sup>24</sup>

#### Glass fibre-reinforced composites

A relatively new group of dental biomaterials, the glass fibre-reinforced composites, is used in fixed partial dentures, removable prosthodontics, periodontal splints and retention splints.<sup>25</sup> The adhesion between the glass fibre and resin composite is improved by adding a silane coupling

agent. The silane forms siloxane linkages with the surface hydroxyl groups of glass fibre. The organo-functional groups of silane react with the functional group in the resin composite. Thus, the bonding strength is increased between resin composite and glass fibre.<sup>27</sup>

#### Resin composite filling materials

Nowadays, dental resin composites are composed of a resin matrix that contains monomers and cross-linking monomers, as well as a free-radical initiator, an inhibitor, colouring pigments, filler materials such as barium glass, silica, apatite and a silane coupling agent.<sup>27, 28</sup> The latter enhances the bonding between the filler particles and the resin matrix.<sup>29</sup> The filler particles added to the resin matrix also improve the physical and mechanical properties of the resin composite. Moreover, the addition of fillers reduces volume shrinkage after polymerisation, and improves the aesthetic appearance and radiopacity.<sup>30</sup>

#### Titanium, noble metal and base metal alloys

Titanium, noble metals and cobalt-chromium (base metal) alloys are commonly used for removable partial and complete dentures with a metal frame incorporated and metal-resin cement restorations.<sup>31,32</sup> For these metal and metal alloys, surface conditioning by sand-blasting using silica-coated alumina particles produces a silica-coated layer on the surface. Application of a silane coupling agent to the silica-coated surfaces forms a durable siloxane linkage. This is followed by cementation.

#### Limitations of silanes as adhesion promoters

Silanes are good at promoting adhesion between resin composites and dental restorative materials but there are some limitations to silane coupling agents.

The adhesion of silane coupling agents and non-silica-based restorative materials such as alumina, zirconia or metals is weaker than the silica coating of these materials.<sup>33,34</sup> Therefore, a surface pretreatment with silica coating is required so that durable bonds (siloxane bonds) are formed between silane and silica-coated restorative materials. For noble metals or noble metal alloys, thione or thiol-based coupling agents are used to promote adhesion.<sup>35</sup> These coupling agents have different bonding mechanisms with various dental restorative materials.

### Current trends and future development of coupling agents in dentistry

Nowadays, other coupling agents (such as phosphate ester) are added to self-adhesive resin cements and adhesive primers, metal and alloy primers, and carboxylic acid primers used in dental restoration.<sup>36,37</sup> Phosphate esters can bond directly to non-silica-based ceramics such as zirconia.<sup>38</sup> It has been reported that using this phosphate ester can enhance the hydrolytic stability of bonding more than using silane coupling agents can.<sup>39</sup>

The main problem of resin composites bonded to silica-coated restorative materials with the application of commercial silane coupling agents is the bond degradation over time under artificial ageing.<sup>40, 41</sup> In order to increase the hydrolytic stability of the

bonding at the interfacial layer, novel surface treatments of restorative materials and the design of novel silane monomers can solve this problem. Silane coupling agents with long hydrocarbon chains are more hydrophobic than those with short hydrocarbon chains. The bonding at the interfacial layer is more resistance to water ageing. These two approaches could resolve the problem.

It could be said that silane coupling agents can fulfil the clinical requirements for dental restorations. Nowadays, a standard laboratory protocol for dental restorations entails surface conditioning of dental materials, silanisation and cementation. The problem of hydrolytic stability of the siloxane linkage formed from silane coupling agents with resin composites and dental restorative materials is currently being addressed. It is not an exaggeration to claim that silane coupling agents have wide application in industry, dentistry and medicine and will play an important role in biomaterials science.

*This review is based on the article "Aspects of silane coupling agents and surface conditioning in dentistry: An overview", Dental Materials, 28 (2012): 467–77. A complete list of references is available from the publisher.<sup>[1]</sup>*



#### Contact Info

Dr Christie Ying Kei Lung is a postdoctoral fellow in Dental Materials Science at the Faculty of Dentistry at the University of Hong Kong. He can be contacted at [cyklung@hku.hk](mailto:cyklung@hku.hk).


# Novel biosensor for use on teeth

Daniel Zimmermann  
DTI

**PRINCETON, NJ, USA:** Princeton University researchers have successfully tested a special kind of biosensor that could help to prevent disease by detecting even small amounts of harmful bacteria more quickly than conventional methods. Using a "tattoo" made from silk and gold and attached to a cow's tooth, they were able to transmit a signal wirelessly to a nearby receiver.

With the method, developed in collaboration with the US Air Force and the American Asthma Foundation, the researchers hope one day to be able to detect not only bacteria but also DNA or particular viruses. In lab tests conducted at Princeton's School of Engineering and Applied Science this year, they were able to detect pathogens responsible for surgical infections and stomach ulcers, among others.

The signals are received from a gold antenna on a tattoo that is attached to an array of graphene—very small particles of carbon—that triggers a signal when in contact with bacteria through attached proteins



*The sensor consists of a graphene layer printed on to a bioresorbable silk substrate. (DTI/Photo Princeton University, USA)*

called peptides. Therefore, the device does not require any power supply, the researchers said.

The sensor is held in place by a water-soluble silk base derived from insect cocoons. In this way, the researchers said, the sensor can be used on different kinds of biomaterials, like teeth or skin, and washed away

or dissolved by body enzymes after use.

According to the researchers, there is still a long way to go before such a biosensor could be in regular use, since the sensor is still too large to fit on human teeth and its lifetime and transmission distance are short. They

admitted, however, that a few modifications to the design of the sensor could increase its transmission distance in the future.

Most traditional biosensors are based on substrates like silicon, which makes them heavy and uncomfortable to wear.<sup>[1]</sup>

## India council under scrutiny

A new report issued by the Comptroller and Auditor General of India has painted a poor picture of how the country's Dental Council is managing dental education. Among other misconducts, it found that a significant amount of dental institutions have not been inspected by the governmental body for years and that fees worth more than US\$1, 3 million to be paid by these colleges for the recognition and renewal of certain dental courses are outstanding. In addition, more students were admitted in some of the colleges than actually allowed by the 1948 Dentists Act.

Dental colleges have mushroomed in India over the last few years, now adding 30,000 new dentists annually to an already massive dental workforce of 1.3 million. <sup>[1]</sup>



# 35th ASIA PACIFIC DENTAL CONGRESS



fdi



Synergizing Practice Excellence  
with  
Modern Technological Advances

 **LOG ON**  
[www.35thAPDC2013.com](http://www.35thAPDC2013.com)  
for updates

**Date : 7-12 May 2013**

**Venue : Kuala Lumpur Convention Centre, Kuala Lumpur, Malaysia**

*Bringing together international dental experts and leaders at a world-class venue...  
Discover Malaysian hospitality, endless opportunities to enjoy nature-based adventures, enriching cultural experiences and fabulous shopping sprees...*

**Come join us for an unforgettable experience!**

Main / Platinum Sponsor:

**Colgate®**

Supported by:



MINISTRY OF HEALTH MALAYSIA

**MALAYSIA™**  
CONVENTION & EXHIBITION BUREAU

Speaker sponsors:

**BIOMET 3i**  
PREMIER DENTAL TECHNOLOGY - A DENTSPLY BRAND

**3M ESPE**

**LISTERINE®**  
Johnson & Johnson

**ULTRADENT**  
PRODUCTS, INC.



# Extending the boundaries of feasibility in direct restorative procedures

*A clinical case combining a high-performance material and clearly defined protocol*

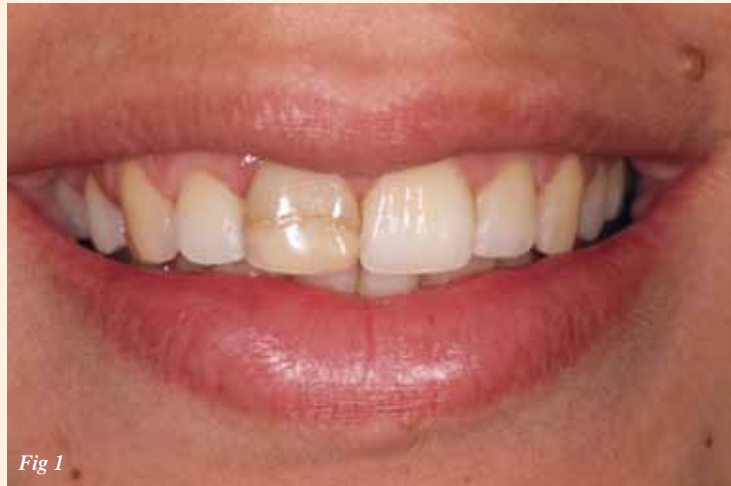

Fig 1

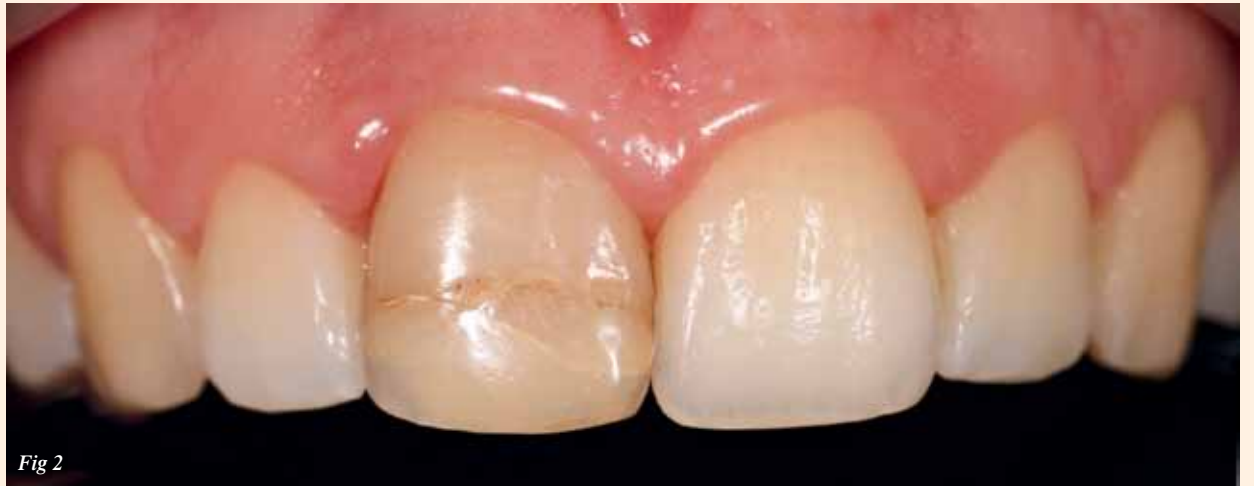

Fig 2

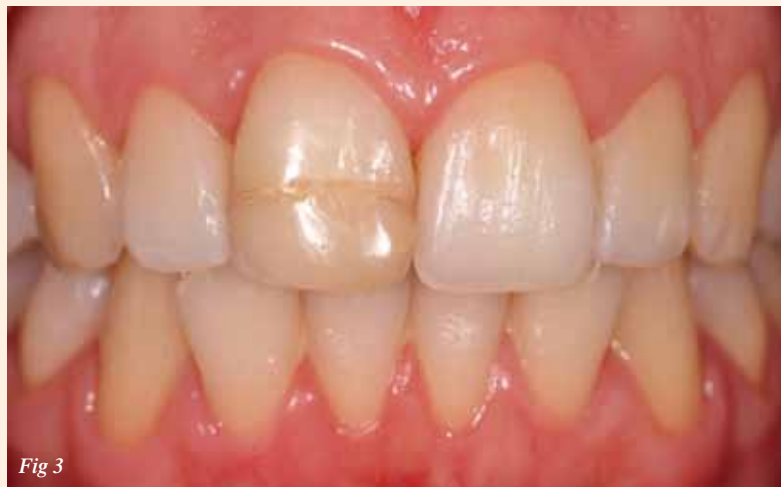

Fig 3

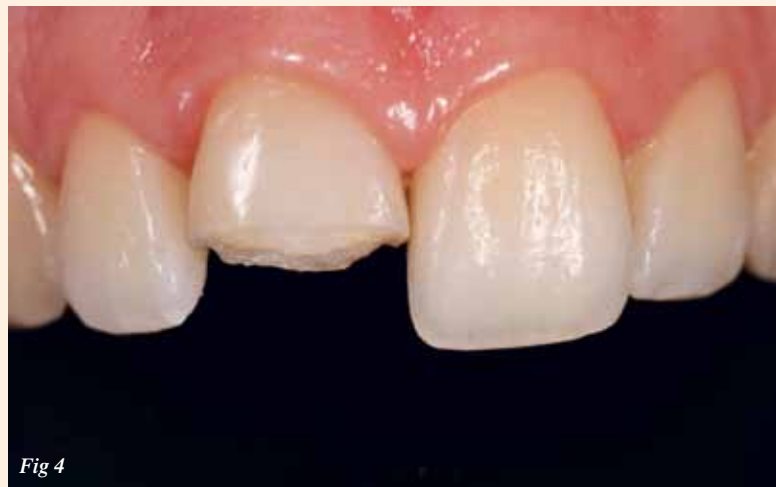

Fig 4

**Fig. 1:** Severely discoloured tooth #11.—**Fig. 2:** The shape of tooth #11 appeared to be harmonious with tooth #21. The substance loss amounted to somewhat less than half of the tooth.—**Fig. 3:** After the bleaching procedure, the shade of tooth #11 was optimal.—**Fig. 4:** Prepared tooth #11 with vestibular chamfer and straight, right-angle palatal margin.

Dr Gauthier Weisrock  
France

Modern high-performance composite materials and standardised treatment protocols have led to more direct composite restorations being fabricated in the anterior region than ever. Even extremely challenging cases may now be treated chairside with predictable results and minimal loss of tooth structure.

A 24-year-old female patient presented at our practice with a request regarding aesthetics. She disliked the appearance of tooth #11, which showed severe discoloration after endodontic treatment. A clinical examination revealed that the root had been extirpated after an accident and that a fractured piece had been reattached with a composite material (Figs 1 & 2). Upon radiological examination, it was found that the root-canal treatment had been performed correctly. However, a post had not been used.

Owing to the fact that approxima-

tely half of the original tooth structure had been lost, we opted for a direct composite restoration, provided that a tooth-whitening procedure could be successfully completed. Along the spectrum of possible treatments, this approach is located between "conventional" composite restoration and ceramic veneering and, therefore, appeared to be clinically appropriate.

The patient, whose primary concerns were a natural tooth shade and minimal loss of tooth structure, agreed to the recommended procedure. We decided to use the nano-hybrid composite IPS Empress Direct (Ivoclar Vivadent) to fabricate the restorations. In addition to dentine and enamel materials, this product is also available in an opalescent material version.

## Preliminary treatment

First, internal bleaching was performed on the tooth, on which the success of treatment would depend.

Access to the endodontic chamber was created through the old restoration. The gutta-percha increment was removed up to 3 mm below the cemento-dentinal junction. At the bottom of the cavity, a plug with a thickness of 2 mm made of glass ionomer cement was inserted to prevent the bleaching agent from accessing the sensitive areas. We used a mixture of sodium perborate and distilled water for the bleaching procedure. The access to the cavity was then sealed with a temporary material.

Since the desired tooth shade was not achieved upon initial bleaching, the entire procedure had to be repeated after one week. After another week, the result was finally optimal (Fig 3). In order to neutralise the bleaching agent, calcium hydroxide was placed into the cavity and left in place for at least one week. (An adhesive may only be applied 15 days after conclusion of the bleaching procedure, in order to ensure optimum adhesion and stable shade.)

## Aesthetic diagnosis and shade determination

After tooth-shape analysis, we concluded that the proportions were harmonious compared with tooth #21. In order to avoid a misinterpretation of the shade owing to dry adjacent teeth, the tooth shade was determined prior to any intervention and in daylight. The IPS Empress Direct shade guide was used for the determination of the enamel and dentine materials. We determined the dentine shade based on the cervical third and the enamel material based on the incisal third of the adjacent tooth. Particular attention was paid to the anatomical structure of the adjacent tooth and the various opalescent reflections visible on the incisal surface, since it was our aim to imitate these features. A layering diagram detailing all the materials that we planned to use was prepared. In this case, only four shades were used: A3/A2 Dentine, A2 Enamel and Trans Opal.

Subsequently, we created a palatal

silicone key on tooth #11 with the appropriate shape and occlusion. Once in place intra-orally, this key helped to create the palatal wall of the restoration in one step. The key included the teeth adjacent to the tooth that needed to be restored and covered the incisal area.

## Preparation and application of the adhesive

The existing restoration was removed with the help of both rotary and ultrasonic instruments and with care to prevent any damage to the adjacent teeth. During the preparation of the tooth, the mechanical properties of the material used and the aesthetic integration needed to be taken into account. In the case of IPS Empress Direct, the ideal preparation design involved a vestibular chamfer and a straight, right-angle proximal and palatal margin (Fig. 4).

Before proceeding with the adhesive cementation, it was necessary to protect the operatory field from saliva or blood in the oral cavity. Therefore, we isolated the anterior teeth, including the canines, with a rubber dam. The expanded treatment area allowed us to assess the incisal line, and the size and shape of the adjacent teeth.

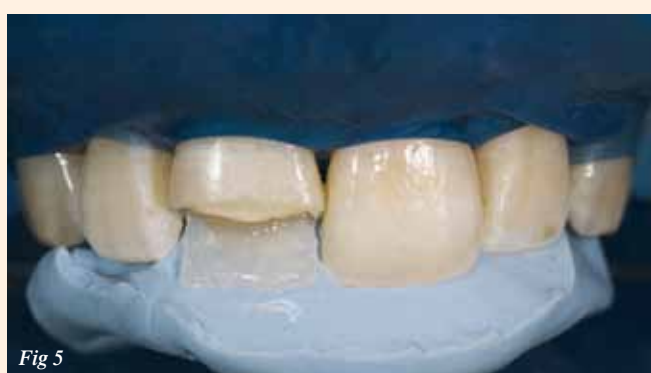

Fig 5

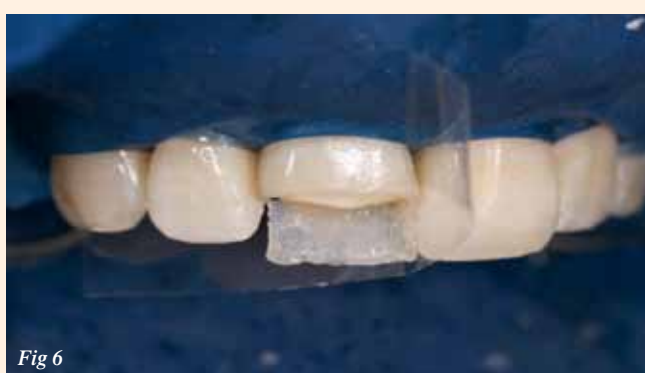

Fig 6

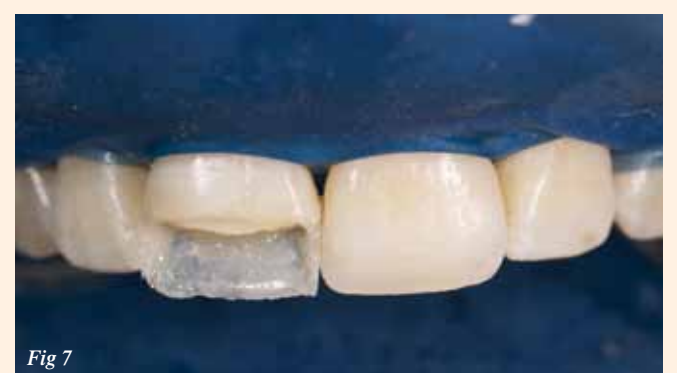

Fig 7

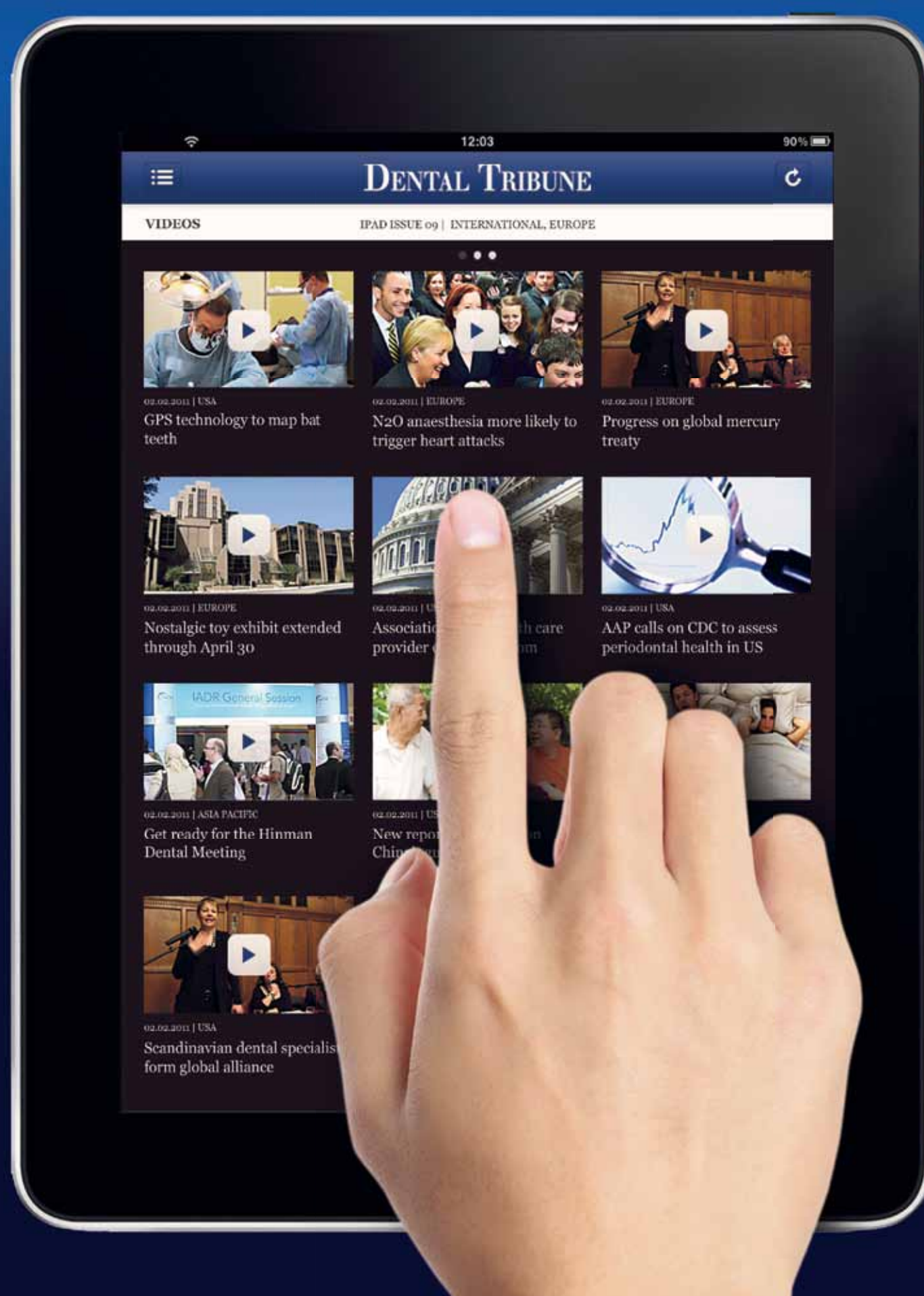
**Fig. 5:** Creating the palatal wall with enamel material (A2 Enamel).—**Fig. 6:** Designing the proximal area and the transition lines.—**Fig. 7:** Building up the palatal and proximal areas, or transforming a complex preparation into a simple one.



# Dental Tribune for iPad – Your weekly news selection

Our editors select the best articles and videos from around the world for you every week. Create your personal edition in your preferred language.

[ipad.dental-tribune.com](http://ipad.dental-tribune.com)



## DENTAL TRIBUNE

— The World's Dental Newspaper —