

# roots

the international C.E. magazine of endodontics

**1** 2017

**C.E. article**

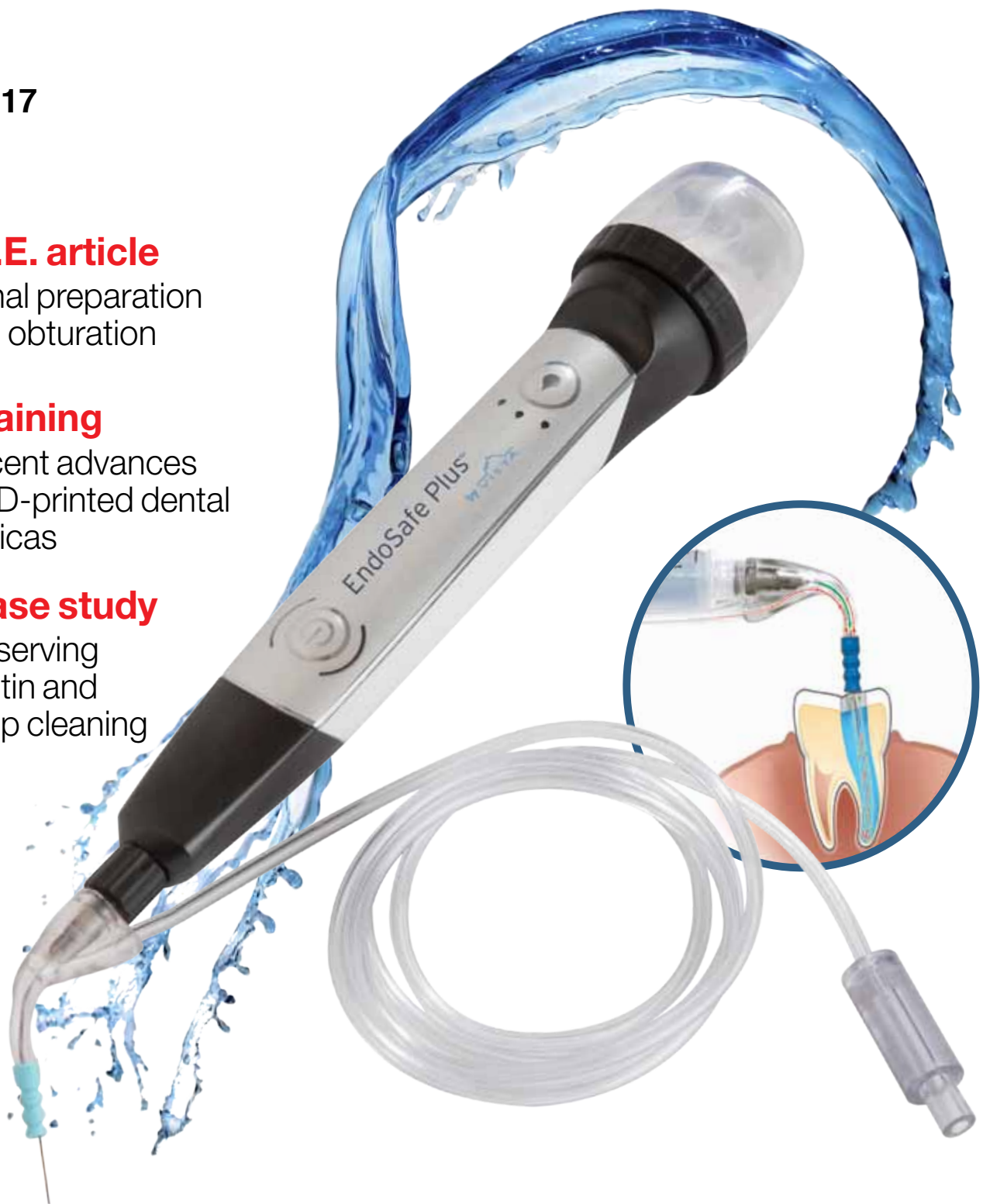Canal preparation and obturation

**training**

Recent advances in 3D-printed dental replicas

**case study**

Preserving dentin and deep cleaning







# Spring into AAE17 Savings!

Promotion on files, reamers, hedstroms, paper points, gutta percha, gates glidden drills, peeso reamers, and barbed broaches

Purchase	Receive	Code
1000 Packs	<b>\$1200 Rebate Check</b>	RHO
600 Packs	<b>\$725 Rebate Check</b>	RHP
450 Packs	<b>\$550 Rebate Check</b>	RHQ
200 Packs	<b>\$250 Rebate Check</b>	RHR
100 Packs	<b>\$125 Rebate Check</b>	RHS
50 Packs	<b>\$50 Rebate Check</b>	RHT
25 Packs	<b>\$25 Rebate Check</b>	RID

**Hurry! Offer ends May 31!**  
**Earn your \$1200 Rebate Check today!**



The boutique brand you've come to love & trust.

roydent.com | 1.800.992.7767 |

REDEMPTION Details: In lieu of a rebate check free goods are allowable. Please call for details. To receive rebate check or free product, please email or fax qualified invoices to Roydent Dental Products at (888)769-3368 or [promos@roydent.com](mailto:promos@roydent.com). Please note relevant promotional code (s) and if you prefer a rebate check or free goods. Free goods requests must include which free product is desired (including size, length, etc), Invoices must be dated April 1, 2017 - May 31, 2017 and sent to Roydent Dental Products before June 30, 2017. File quantities must come from one invoice. Rebate checks will be made payable to Doctor or Practice Name on the Roydent Account. Please call for details. Mix-and-match permitted. Offer is available to contract and formulary customers. Please allow 4-6 weeks for delivery of rebate checks/free goods.

# The annual **AAE** meeting is our time to shine



Fred Weinstein, DMD, MRCD(C),  
FICD, FACD

It's likely that you picked up this copy of *roots* at AAE17, the annual session of the American Association of Endodontists, held this year in New Orleans, and you are reading this on your flight home. That's good, because this issue includes many helpful articles, including information on some of the latest topics— from cleaning and shaping to new technology used for disinfection.

If you are like me, you look forward to the AAE meeting each year, not only for the camaraderie but also because of the knowledge that is shared among compatriots. How many of the lectures and hands-on workshops did you attend at this year's meeting? Which was your favorite? No matter what course or speaker inspired you, it's all part of the greater knowledge about our specialty.

A small part of that knowledge base is contained on the pages that follow. Chief among them is an article by Dr. L. Stephen Buchanan, titled "Recent advances in 3D-printed dental replicas for procedural training and board exams," and an article by Dr. Khang T. Le, "18-month case study of a C-shaped mandibular molar: Preserving dentin and deep cleaning utilizing an innovative procedure." There's also a report on the newly opened Dentsply Sirona Endodontic Suite at NYU College of Dentistry.

The centerpiece of this publication is an article by Dr. Ove A. Peters. "Canal preparation and obturation: An updated view of the two pillars of nonsurgical endodontics," which originally appeared in AAE's *ENDODONTICS: Colleagues for Excellence* newsletter, is being made available in this issue of *roots* with the permission of the AAE. By reading this article, and then taking a short online quiz at [www.DTStudyClub.com](http://www.DTStudyClub.com), you will gain one ADA CERP-certified C.E. credit. Remember that with *roots*, you can always earn C.E. credit without lost revenue and time away from your practice.

To learn more about how you can take advantage of this C.E. opportunity, visit [www.DTStudyClub.com](http://www.DTStudyClub.com). You need only register at the Dental Tribune Study Club website to access these C.E. materials free of charge. You may take the C.E. quiz after registering.

You can also access the vast library of C.E. articles published in the AAE's clinical newsletter by visiting [www.aae.org/colleagues](http://www.aae.org/colleagues).

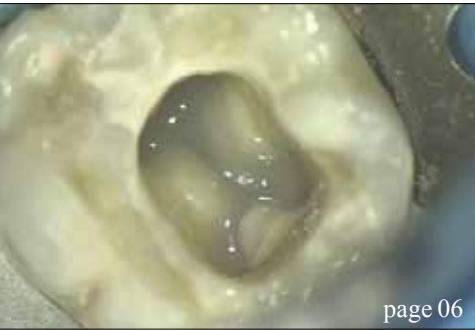I know that taking time away from your practice to pursue C.E. credits is costly in terms of lost revenue and time, and that is another reason *roots* is such a valuable publication. I hope you will enjoy this issue and that you will take advantage of the C.E. opportunity.

As always, I welcome your comments and feedback.

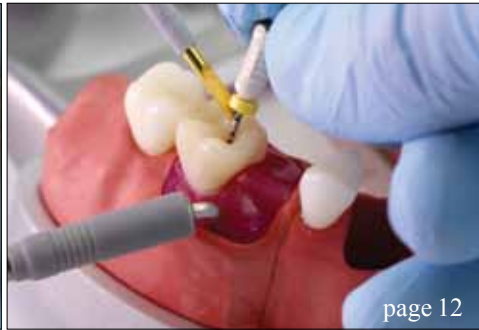A handwritten signature in cursive script that reads "Fred Weinstein".

Fred Weinstein, DMD, MRCD(C), FICD, FACD  
Editor in Chief

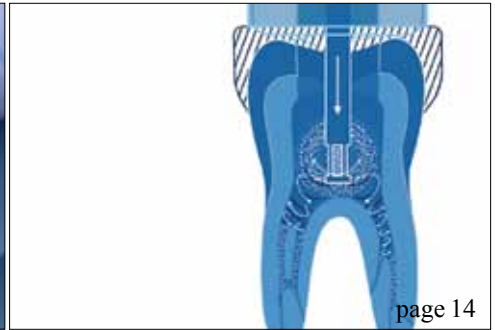




page 06



page 12



page 14

### | C.E. article

- 06 **Canal preparation and obturation:**  
An updated view of the two pillars  
of nonsurgical endodontics  
\_Ove A. Peters, DMD, MS, PHD

### | training

- 12 Recent advances in **3D-printed dental replicas** for procedural training and board exams  
\_L. Stephen Buchanan, DDS, FACD, FICD

### | case study

- 14 18-month case study of a C-shaped mandibular molar: **Preserving dentin and deep cleaning** utilizing an innovative procedure  
\_Khang T. Le, DDS

### education

- 17 **Dentsply Sirona Endodontic Suite** opens at NYU College of Dentistry

### industry education

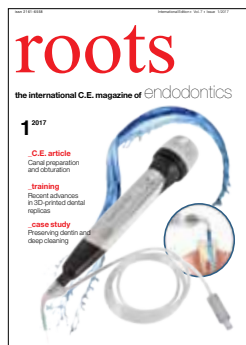
- 18 There is a **better way** (and LVI can show you how to get there)  
\_Mark Duncan, DDS, FAGD, LVIF, DICOI, FICCMO

### industry

- 20 Safe and effective irrigation with Directa's double-side-vented **Calasept Irrigation Needle**

### | about the publisher

- 22 **\_imprint**



### | on the cover

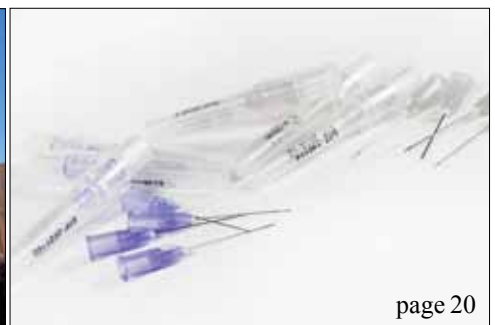*The EndoSafe Plus™, available from Vista Dental Products, provides apical negative pressure irrigation. Simultaneous irrigation and evacuation provides a continuous, controlled flow of irrigating solutions and flushing of debris, while minimizing the risk of apical extrusion.  
(Photo/Provided by Vista Dental Products)*



page 17



page 18



page 20

DENTAL  
ENGINEERING  
LABORATORIES



Dr. L Stephen Buchanan Presenting  
CT Guided Endodontics  
AAE New Orleans 2017  
Morial Convention Center, Room 244  
April 29, 2017, 12:45PM.



**TrueVision**  
3D • SURGICAL

Heads-Up Display Solutions.



Predictable Broken File Retrieval.



Find solutions at the 2017 AAE Annual Conference.  
Visit Dental Engineering Laboratories at AAE Booth #825.  
Enter Code 'AAE17' for 20% OFF TFRK online, 4/21-5/1.

[www.DELengineeringlab.com](http://www.DELengineeringlab.com)

# Canal preparation and obturation: An updated view of the two pillars of nonsurgical endodontics

Author\_Ove A. Peters, DMD, MS, PHD

## \_c.e. credit

This article qualifies for C.E. credit. To take the C.E. quiz, log on to [www.dtstudyclub.com](http://www.dtstudyclub.com). Click on 'C.E. articles' and search for this edition (Roots C.E. Magazine — 1/2017). If you are not registered with the site, you will be asked to do so before taking the quiz. You may also access the quiz by using the QR code below.



The ultimate goal of endodontic treatment is the long-term retention in function of teeth with pulpal or periapical pathosis. Depending on the diagnosis, this therapy typically involves the preparation and obturation of all root canals. Both steps are critical to an optimal long-term outcome. This article is intended to update clinicians on the current understanding of best practices in the two pillars of nonsurgical endodontics, canal preparation and obturation, and to highlight strategies for decision making in both uncomplicated and more difficult endodontic cases.

Prior to initiating therapy, a clinician must establish a diagnosis, take a thorough patient history and conduct clinical tests. Recently, judicious use of cone-beam computed tomography (CBCT) has augmented the clinically available imaging modalities. Verifying the mental image of canal anatomy goes a long way to promote success in canal preparation. For example, a missed canal frequently is associated with endodontic failures.<sup>1</sup>

As most maxillary molars have two canals in the mesiobuccal root, case referral to an endodontist for microscope-supported treatment should be considered. Endodontists are increasingly using CBCT and the operating microscope to diagnose and treat anatomically challenging teeth, such as those with unusual root anatomies, congenital variants or iatrogenic alteration. The endodontic specialist, using appropriate strategies, can achieve good outcomes even in cases with significant challenges (Fig. 1).

## \_Preparation of the endodontic space

The goal of canal preparation is to provide adequate access for disinfecting solutions without making major preparation errors such as perforations, canal transportations, instrument fractures or unnecessary removal of tooth structure. The introduction of nickel-titanium (NiTi) instruments to endodontics almost two decades ago<sup>2</sup> has resulted in dramatic improvements for successful canal preparation for generalists and specialists. Today there are more than 50 canal preparation systems; however, not every instrument system is suitable for every clinician and not all cases lend themselves to rotary preparation.

Several key factors have added versatility in this regard, for example, the emergence of special designs such as orifice shapers and mechanized glide path files. Another recent development is the application of heat treatment to NiTi alloy, both before and after the file is manufactured. Deeper knowledge of metallurgical properties is desirable for clinicians who want to capitalize on these new alloys. Finally, more recent strategies such as minimally invasive endodontics have emerged.<sup>3</sup>

## \_Basic nickel titanium metallurgy

What makes NiTi so special? It is highly resistant to corrosion and, more importantly, it is highly elastic and fracture-resistant. NiTi exists reversibly in two conformations, martensite and austenite, depending on external tension and ambient temperature. While steel allows 3 percent elastic deformation, NiTi in the

austenitic form can withstand deformations of up to 7 percent without permanent damage or plastic deformation.<sup>4</sup> Knowing this is critical for rotary endodontic instruments for two reasons. First, during preparation of curved canals, forces between the canal wall and abrading instruments are smaller with more elastic instruments, hence less preparation errors are likely to occur.

Second, rotation in curved canals will bend instruments once per rotation, which ultimately will lead to work hardening and brittle fracture, also known as cyclic fatigue. Steel can withstand up to 20 complete bending cycles, while NiTi can endure up to 1,000 cycles.<sup>4</sup>

Recently manufacturers have learned to produce NiTi instruments that are in the martensitic state and even more flexible than previous files. Figure 2 shows how instrument conditions (austenite vs. martensite) are determined in the testing laboratory, using prescribed heating and cooling cycles.<sup>5</sup> Heat-treated files with high martensite content typically do not have a silver metallic shade but are colored due to an oxide layer, such as gold or blue.

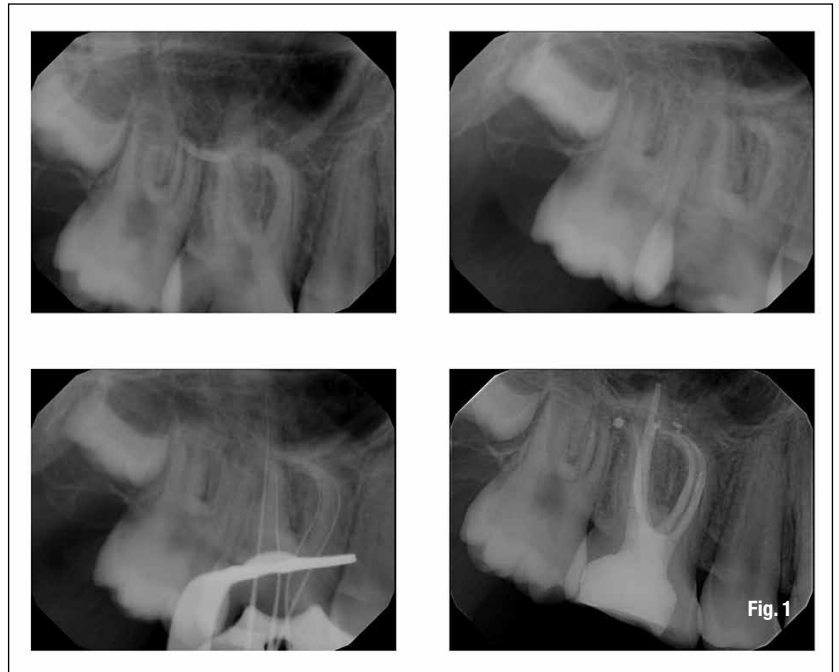
It is important to note that CM files frequently deform; however, with a delicate touch, cutting is adequate and often even superior to conventional NiTi instruments.<sup>6</sup> It is imperative for clinicians to retrain themselves prior to using these new instruments to avoid excessive deformation and subsequent instrument fracture.

### Preparation strategies

Experimental and clinical evidence suggests that the use of NiTi instruments combined with rotary movement results in improved preparation quality. Specifically, the incidence of gross preparation errors is greatly reduced.<sup>7</sup> Canals with wide oval or ribbon-shaped cross-sections present difficulties for rotary instruments and strategies such as circumferential filing and ultrasonics should be used in those canals.

Studies found that oscillating instruments recommended for these canal types did not perform as well,<sup>8</sup> particularly in curved canals. Specific instruments developed to address these challenges include the Self-Adjusting File (SAF) System (ReDentNOVA, Raana, Israel), TRUShape® (Dentsply Sirona, Tulsa, Okla.) and XP Endo® (Brasseler, Savannah, Ga.). However, there is no direct clinical evidence that these instruments lead to better outcomes.

Canal transportation with contemporary NiTi rotaries, measured as undesirable changes of the canal center seen in cross-sections of natural teeth, is usually very small. This indicates that canal walls are not excessively thinned and apical canal paths are only minimally straightened (Fig. 1), even when



preparing curved root canals. While preparation usually removes dentin somewhat preferentially toward the outside of the curvature,<sup>9</sup> current NiTi instruments, including reciprocating files, can enlarge the canal path safely while minimizing procedural errors.

Almost all current rotaries are non-landed, meaning they have sharp cutting edges, and they can be used in lateral action toward a specific point on the perimeter. This "brushing" action allows the clinician to actively change canal paths away from the furcation in the coronal and middle thirds of the root canal<sup>10</sup> but may create apical canal straightening when taken beyond the apical constriction. Circumferential engagement of canal walls by active instruments may lead to a threading-in effect, but contemporary rotaries are designed with variable pitch and helical angle to counteract this tendency.

An important design element for all contemporary rotaries is a passive, non-cutting tip that guides the cutting planes to allow for more evenly distributed dentin removal. Rotaries with cutting, active tips such as dedicated retreatment files should be used with caution to avoid preparation errors.

### NiTi instrument usage

As a general rule, flexible instruments are not very resistant to torsional load but are resistant to cyclic fatigue. Conversely, more rigid files can withstand more torque but are susceptible to fatigue. The greater the amount and the more peripheral the distribution of metal in the cross section, the stiffer the file.<sup>11</sup> Therefore, a file with greater taper and larger diameter is more susceptible to fatigue failure;

**Fig. 1** Root canal treatment of tooth #3 diagnosed with pulp necrosis and acute apical periodontitis. The mesio Buccal root has a significant curve and two canals with separate apical foramina. Case courtesy of Dr. Jeffrey Kawilarang. (Photos/Provided by American Association of Endodontists)



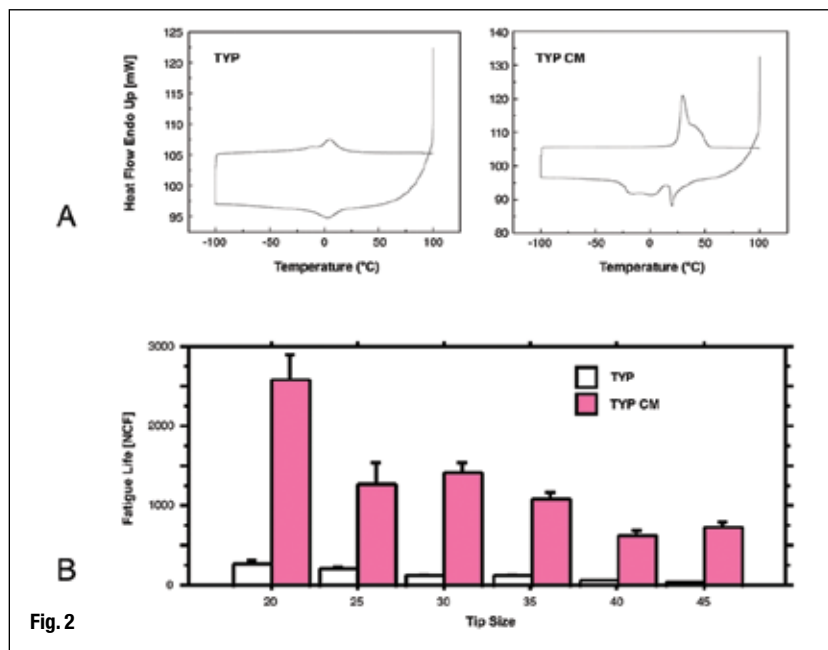


Fig. 2

**Fig. 2** Behavior of controlled-memory nickel-titanium rotaries compared with standard instruments. Shown are data from Typhoon Differential scanning calorimetry, which document the transition between austenite and martensite at about 5 degrees C for standard NiTi and at about 25 degrees C for controlled-memory (CM) alloy (A). At room temperature, this results in a drastically increased fatigue lifespan (B). Image A modified and reprinted with permission from Shen *et al.* J Endod 2011; 37:1566-1571.

moreover, a canal curvature that is more coronal is more vulnerable to file fracture.

Instrument handling has been shown to be associated with file fracture. For example, a lower rotational speed (~250 rpm) results in delayed build-up of fatigue<sup>12</sup> and reduced incidence of taper lock.<sup>13</sup> Material imperfections such as microfractures and milling marks are believed to act as fracture initiation sites.<sup>14</sup> Such surface imperfections after manufacturing can be removed by electropolishing but it is unclear if this process extends fatigue life.<sup>15</sup>

Manufacturers' recommendations stress that rotaries should be advanced with very light pressure; however, the recommendations differ with regard to the way the instruments are moved. A typical recommendation is to move the instrument into the canal gently in an in-and-out motion for three to four cycles, directed away from the furcation, then withdraw to clean the flutes.

It is difficult to determine exactly the apically exerted force in the clinical setting; experiments have suggested that forces start at about 1 Newton (N) and range up to 5 N.<sup>16</sup> Precise torque limits have been discussed as a means to reduce failure. Most clinicians use torque-controlled motors, which are based on presetting a maximum current for a DC electric motor.

To reduce friction, manufacturers often recommend the use of gel-based lubricants in dentin; however, such lubricants have not been shown to be beneficial and actually did increase torque for radial-landed ProFile® instruments.<sup>17</sup> Therefore, it is recommended to flood the canal system with sodium hypochlorite (NaOCl) during the use of rotaries. The best way to do this is to create an access cavity that can act as a reservoir (Fig. 3).

There are several concerns about reusing NiTi instruments. The effectiveness of disinfection procedures is not clear. It has been shown that protein particles cannot completely be removed from machined nickel-titanium surfaces.<sup>18</sup> Moreover, it is clear that with additional usage, the chance for instrument fracture increases. Current recommendations advise that clinicians are judicious when reusing rotary instruments as there is no conclusive evidence of disease transmission occurring.

Recently, the term minimally invasive endodontics has been used to describe smaller-than-usual apical sizes and, perhaps more importantly, an understanding that the long-term success of root canal-treated teeth will improve by retaining as much dentin structure as feasible.<sup>3</sup> The thought process for this was the finding that most root-canal treated teeth survive 10 years and longer.<sup>19</sup> In studies, the reasons cited for the extraction vary but in many cases teeth are either fractured or non-restorable for other reasons.<sup>20,21</sup>

In consequence, a smaller coronal dimension of rotaries is considered while maintaining apical sizes to support antimicrobial efficacy. There currently is no direct clinical evidence to support this strategy but it is clear that root fractures pose problems in the long-term outcomes of our patients. Another recent development is the emergence of certain specialized rotaries, such as dedicated orifice shapers and so-called glide path files. The orifice shapers have larger tapers, such as .08, which means that they are not flexible and can overprepare at the canal orifice level. Glide path files, for example PathFiles® and ProGlider® (Dentsply Sirona), are delicate instruments and may fracture when used incorrectly. It is recommended to use a small K-file (size #10) before any rotary instrumentation and to use a delicate touch.

## Clinical results

While results from *in vitro* studies on rotary systems are abundant, clinical studies on these instruments are sparse. Comparing NiTi and stainless steel K-files, Pettiette *et al.*<sup>7</sup> found less canal transportation and fewer gross preparation errors such as strip perforations. Subsequently, using radiographic evaluation of the same patient group, they demonstrated better healing in the NiTi group.<sup>22</sup> An earlier outcome study with three rotary preparation paradigms did not show any difference between the three systems with an overall favorable outcome rate of about 87 percent.<sup>23</sup>

The most consistent clinical results are obtained when the manufacturer's directions are followed. While these vary by instrument, a set of common rules applies to root canal preparation. Root



canal systems are best prepared in the following sequence:

- Analysis of the specific anatomy of the case.
- Canal scouting.
- Coronal modifications.
- Negotiation to patency.
- Determination of working length.
- Glide path preparation.
- Root canal shaping to desired size.
- Gauging the foramen, apical adjustment.

### Obturation of the endodontic space

A well-shaped and cleaned canal system should create the conditions for intact periapical tissues. On the other hand, this root canal system is inaccessible to the body's immune system and therefore it cannot combat coronal leakage. Accordingly, best practices dictate that root canals should be filled as completely as possible to prevent ingress of nutrients or oral microorganism. None of the established techniques for root canal filling provides a definitive coronal, lateral and apical seal.<sup>24</sup>

### Basic strategies in root canal obturation

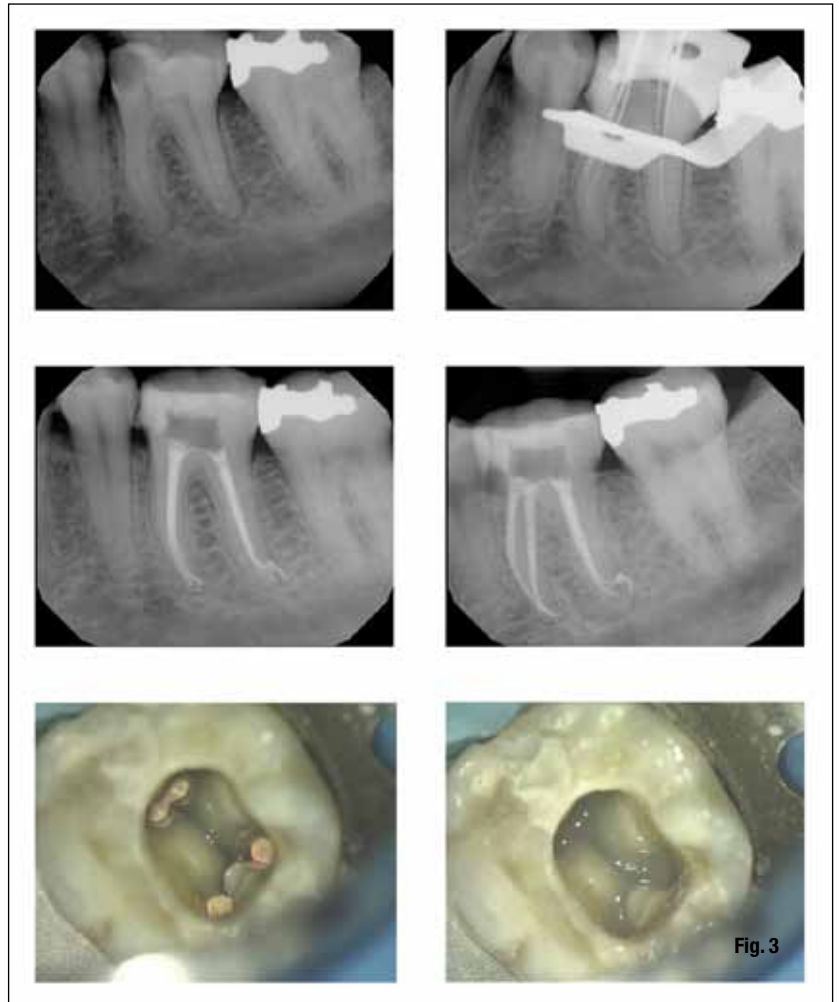
Ideally, root canal fillings should seal all foramina leading to the periodontium, be without voids, adapt to the instrumented canal walls and end at working length. There are various acceptable materials and techniques to obturate root canal systems, including:

- Sealer (cement/paste/resin) only.
- Sealer and a single cone of a stiff or flexible core material.
- Sealer coating combined with cold compaction of core materials.
- Sealer coating combined with warm compaction of core materials.
- Sealer coating combined with carrier-based core materials.

Several of these techniques have shown comparable success rates regarding apical bone fill or healing of periradicular lesions, so a clinician may choose from a variety of techniques and approaches that works best for him or her. Existing research directs clinicians toward preparation and disinfection of the root canal as the single most important factor in the treatment of endodontic pathosis, and no particular sealing technique can claim superior healing success.<sup>25</sup>

### Current developments in root canal obturation materials

After the introduction of MTA (mineral trioxide aggregate) as a material for perforation repair and



apical surgery more than two decades ago, materials with similar bioactive properties now are available as root canal sealers. Bioceramic root canal cement (BC Sealer™, Brasseler) has clinically acceptable radiopacity and flow.<sup>26</sup> Moreover, it is well-tolerated in cell culture experiments.<sup>27</sup> However, there is no clinical evidence that using this cement leads to better outcomes. In fact, most research has indicated the type of cement used has comparatively little impact.<sup>28</sup>

In contemporary practice, heat generators are used to plasticize gutta-percha. Additionally, cordless heating devices are available. Another recent addition is a carrier-based material, Guttacore® (Dentsply Sirona), which uses modified gutta-percha materials instead of plastic as its base. Early data indicate that obturation with this new material is similar to warm vertical compaction or lateral compaction.<sup>29</sup>

### Practical aspects of obturation

The main steps in the sequence of root canal obturation are:

- Choosing a technique and timing the obturation.
- Selecting master cones.
- Canal drying, sealer application.

**Fig. 3** Root canal treatment of tooth #19 with four canals diagnosed with irreversible pulpitis and acute apical periodontitis. A second canal in the distal root of a mandibular molar is not infrequent. Note multiple apical foramina in both the mesial and the distal apices. Prior to temporization, the orifices were protected with a barrier of light-curing glass ionomer. Case courtesy of Dr. Paymon Bahrami.