

IMPLANT TRIBUNE

PERIODONTISTS MEET IN LOS ANGELES

American Academy of Periodontology hosts 98th annual meeting.

► page B1



ENDO TRIBUNE

ADA OFFERS PLENTY FOR ENDODONTISTS

Annual American Dental Association session packed with endodontic advances.

► page C1



HYGIENE TRIBUNE

WHAT'S A PROBIOTIC?

Microbial supplement for oral health are being seen on the shelves at more dental practices.

► page D1




Salivary diagnostics redefining dentistry

UCLA researchers, others see expanding role for 'salivaomics'

Scientists from the UCLA School of Dentistry have been at the vanguard of research on human saliva in recent years, leading the way in the dynamic, emerging field of salivary diagnostics, which seeks to catalog the biological makeup of saliva to help screen for and detect both oral and systemic diseases.

The Journal of the American Dental Association has published a special supplement to its October issue in which Dr. David Wong, the UCLA School of Dentistry's associate dean of research, outlines the state of the science of salivary diagnostics, highlight-

► See SALIVARY, page A2



Greater New York Dental Meeting
Nov. 23-28

The Tribune America staff sends its sympathy to all of those who suffered losses to Hurricane Sandy. Our Manhattan-based office and staff came through relatively unscathed, and we appreciate all of the calls and emails. We join with the Greater New York Dental Meeting in deep appreciation of everyone's support and want to emphasize that New York City and the entire northeast coast remain open for business. We look forward to seeing everyone at the 2013 GNYDM, the largest health care and dental event in the U.S.

Photo/Robert Selleck, Dental Tribune

► See page A6

CLINICAL A3-A4

• Part 3 of 'Cosmetic periodontal surgery' looks at 'zones of symmetry'

MEETINGS A6-A14

- Greater New York Dental Meeting opening day is just days away
- Next American Academy of Implant Prosthodontics course is in January
- Yankee Dental Congress loaded up with no-extra-charge C.E. education
- Pacific Dental Conference includes 36 hands-on courses
- Smiles in the Sun combines idyllic locale with comprehensive education

INDUSTRY A15-A27

- ANEW Narrow Body Implant System from Dentatus mimics anatomy
- Quick work: Glidewell Laboratories Inclusive Tooth Replacement Solution
- DENTSPLY Caulk expands portfolios
- Air Techniques launches new digital imaging line
- Aribex celebrates 10,000th NOMAD
- Add pain-management to your clinical services with TruDenta
- For effective barrier protection in medical gloves: Malaysian rubber
- Milestone offers no-pain injections
- xpAPce class: Anterior endodontics
- 3Shape scans click directly through to ATLANTIS service centers
- Scheduling Institute training can stop losses you may not be seeing
- Eaglesoft 16 software eases your day

AD

Purchase \$500 of any EDS products ...
Get a FREE \$25.00 Gift Card

Visit www.edsdental.com for details

Dental Tribune America
116 West 23rd Street
Suite #500
New York, N.Y. 10011

PRSRPT STD
U.S. Postage
PAID
San Antonio, TX
Permit #1396

AD

IT'S GREAT TO BE ON TOP ...

... WITH THE MOST TOOTH-LIKE COMPOSITE EVER!

99% filler by weight
• Outstanding wear resistance
• Enhanced color stability

30-50% less resin compared to classic hybrid and pseudo resin composites
• Low shrinkage of only 1.8 wt %
• Non-sticky
• Prolonged working time under ambient light

Designer Nano particles
• Excellent polishability and polish retention
• Tooth-like modulus of elasticity
• Tooth-like thermal expansion and flexural strength

FOR SANBLENDED USE
\$58

99% filled universal Nano Hybrid Composite
The Combination of handling, aesthetics and performance.

Call 1-888-658-2584 · www.vocoamerica.com

← SALIVARY, page A1

ing advances made by researchers at UCLA and other institutions and charting a path for future research and clinical applications.

Actionable results from salivaomics

In the article, Wong's research findings show that saliva is made up of complex sets of molecules — including genes, proteins, DNA and RNA — that help paint a picture of an individual's biology. The study of the biological molecules in saliva is known as "salivaomics."

Findings show that by studying the "omics" in saliva — such as genomics, transcriptomics and proteomics — scientists can develop tests composed of many molecular measurements; the findings are then interpreted by a computational model to produce a clinically actionable result.

Through collaborative work with scientists at other institutions, UCLA researchers have developed several informatics and statistical tools to help interpret biomarkers in saliva; these biomarkers can then be used for early detection of disease, treatment monitoring, recurrence prediction and other translational assessments.

Just as useful as blood diagnostics

Research done at the UCLA School of Dentistry has shown that saliva, as a medium for health screening, is just as

useful as blood and other bodily fluids and has vast potential for the early detection of cancers, autoimmune diseases, diabetes and other disorders.

The ability to conveniently and inexpensively capture saliva samples in a clinical setting for diagnostic purposes would be a huge step forward for health care providers in the detection, treatment and prediction of recurrence of life-threatening diseases. Wong expects that future research in salivaomics will eventually translate into practical medical applications that will be administered in dentists' and doctors' offices.

Dentists positioned on front line

Because it has been shown that 20 percent more Americans visit their dentists more regularly than their physicians, there will be substantial opportunities for dentists to engage in primary health care by taking saliva samples from their patients and, based on the medical findings of those samples, developing individualized treatment plans.

Wong is a professor of oral biology and medicine and holds the Felix and Mildred Yip Endowed Chair in Dentistry at the UCLA School of Dentistry. His research has been funded by the National Institute of Dental and Craniofacial Research and the National Cancer Institute.

(Source: UCLA School of Dentistry)



Dr. David Wong is a professor of oral biology and medicine and holds the Felix and Mildred Yip Endowed Chair in Dentistry at the UCLA School of Dentistry. His 'salivaomics' research is featured in a supplement to the October issue of the Journal of the American Dental Association. Photo/Provided by UCLA School of Dentistry

AD

6 Reasons Why This Dentist Says...

“Getting this CD was the SINGLE BEST DECISION I’ve Ever Made for My Dental Practice!”

I won this Lamborghini!

This Single CD Will Change Your Practice and Your Life Too! Get Yours Today!!

SCHEDULING INSTITUTE

2 WAYS TO GET YOUR COPY

1. go to www.MyPracticeCD.com OR, 2. fax info below to 866.651.6445

Doctor's Name: _____
 Office Phone: _____
 Doctor's Email: _____

© 2012 Scheduling Institute. All rights reserved. This is a promotional offering. Some restrictions may apply. See website for details.

DENTAL TRIBUNE

The World's Dental Newspaper - US Edition

PUBLISHER & CHAIRMAN

Torsten Oemus t.oemus@dental-tribune.com

CHIEF OPERATING OFFICER

Eric Seid e.seid@dental-tribune.com

GROUP EDITOR

Robin Goodman r.goodman@dental-tribune.com

EDITOR IN CHIEF DENTAL TRIBUNE

Dr. David L. Hoexter feedback@dental-tribune.com

MANAGING EDITOR U.S. AND CANADA EDITIONS

Robert Selleck r.selleck@dental-tribune.com

MANAGING EDITOR

Fred Michmershuizen
f.michmershuizen@dental-tribune.com

MANAGING EDITOR

Sierra Rendon s.rendon@dental-tribune.com

MANAGING EDITOR SHOW DAILIES

Kristine Colker k.colker@dental-tribune.com

PRODUCT/ACCOUNT MANAGER

Mara Zimmerman
m.zimmerman@dental-tribune.com

PRODUCT/ACCOUNT MANAGER

Charles Serra c.serra@dental-tribune.com

MARKETING DIRECTOR

Anna Kataoka-Wlodarczyk
a.wlodarczyk@dental-tribune.com

C.E. DIRECTOR

Christiane Ferret c.ferret@dtstudyclub.com

ACCOUNTING COORDINATOR

Nirmala Singh n.singh@dental-tribune.com

Tribune America, LLC

116 West 23rd St., Ste. #500
New York, N.Y. 10011

(212) 244-7181

Published by Tribune America

© 2012 Tribune America, LLC
All rights reserved.

Dental Tribune strives to maintain the utmost accuracy in its news and clinical reports. If you find a factual error or content that requires clarification, please contact Managing Editor Robert Selleck at r.selleck@dental-tribune.com.

Dental Tribune cannot assume responsibility for the validity of product claims or for typographical errors. The publisher also does not assume responsibility for product names or statements made by advertisers. Opinions expressed by authors are their own and may not reflect those of Tribune America.

EDITORIAL BOARD

Dr. Joel Berg
Dr. L. Stephen Buchanan
Dr. Arnaldo Castellucci
Dr. Gorden Christensen
Dr. Rella Christensen
Dr. William Dickerson
Hugh Doherty
Dr. James Doundoulakis
Dr. David Garber
Dr. Fay Goldstep
Dr. Howard Glazer
Dr. Harold Heymann
Dr. Karl Leinfelder
Dr. Roger Levin
Dr. Carl E. Misch
Dr. Dan Nathanson
Dr. Chester Redhead
Dr. Irwin Smigel
Dr. Jon Suzuki
Dr. Dennis Tartakow
Dr. Dan Ward

Tell us what you think!

Do you have general comments or criticism you would like to share? Is there a particular topic you would like to see articles about in Dental Tribune? Let us know by e-mailing feedback@dental-tribune.com. We look forward to hearing from you! If you would like to make any change to your subscription (name, address or to opt out) please send us an e-mail at database@dental-tribune.com and be sure to include which publication you are referring to. Also, please note that subscription changes can take up to six weeks to process.

Cosmetic periodontal surgery (Part 3): Zones of symmetry

By David L. Hoexter, DMD, FACD, FICD,
Editor in Chief

In Part 3 of this series on cosmetic periodontal surgery, I again emphasize the necessity of a complimentary healthy background of the periodontia — with the goal of enhancing the desired smile. In Parts 1 and 2 of this series, we described what a healthy periodontia entailed — a complementary, healthy surrounding tissue and color — and keratinized attached gingival, appearing as a whitish-pink color, separated at the mucogingival junction from the movable nonkeratinized alveolar mucosa of a reddish-blue color.

This article will concentrate on the *symmetry* of the periodontal background's colors to afford the emphasis of the appearance of the teeth we wish to stand out to create that "smile." In this article, the *symmetry* of attention of the keratinized attached gingiva — needed to achieve the background support of the final image — should be measured by both the vertical and horizontal dimensions, and is often overlooked.

Healthy keratinized attached gingival is desirable to surround the natural tooth to aid in the hygienic maintenance of the natural tooth or the endosseous implant. The patient can rub the keratinized tissue with several choices of instruments to remove the localized biofilms to preserve the health of the area.

Healthy gingival color can vary

Healthy keratinized attached gingiva does not necessarily have to appear a pinkish-white color. It depends on the melanin pigmentation that the individual has in his or her epithelial basement membrane.

For example, people of Mediterranean origin appear to have areas of gingiva that vary with some darker and some lighter zones. It's just like the way some people have facial skin with freckles and some don't.

In normal epithelium, the color does not necessarily represent pathology, but rather healthy, natural epithelium.

However, when we discuss esthetic dentistry today, the culture that we are dealing with plays a factor too. For example, centuries ago in Japan, a woman's most desirable smile was one that showed black teeth.

In general today, we wish the appearance of bright-appearing teeth — framed by pinkish-white keratinized gingiva. The gingival should surround and protect our desired image, enhancing and attracting it. It certainly should not detract from our goal. Therefore the keratinized gingival should be the same homogeneous color. It should also be equal and symmetrical in vertical and in lateral size. This will not detract, but aid in the maintenance and appearance of our smile.

Many techniques can be used

There are many cosmetic periodontal surgical techniques that can be used to

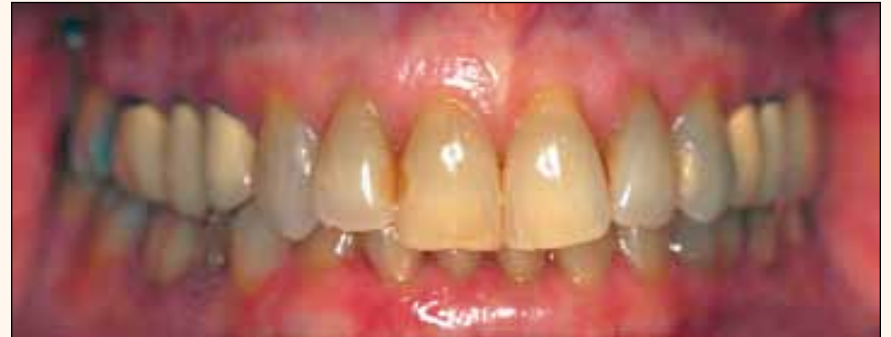

Fig. 1: Labial pretreatment view. Notice the uneven gingival horizontal lines, the crown's unpleasant color — as well as the dark, uneven gingival margins in the maxillary posteriors. Photos/Provided by Dr. David L. Hoexter

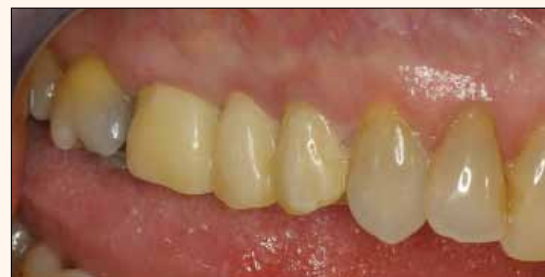

Fig. 2: Provisional replacements of the previous old crowns in the upper-right posterior. Notice the uneven zone of attached gingiva affording the vision of uneven, unattractive teeth.

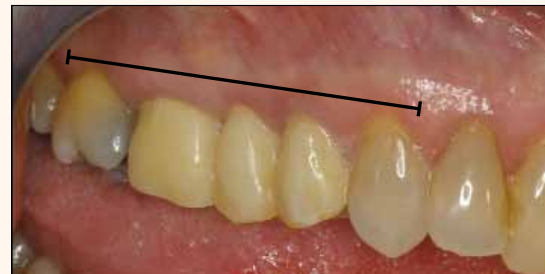

Fig. 3: The line shows our goal of symmetrical, horizontal-appearing teeth.

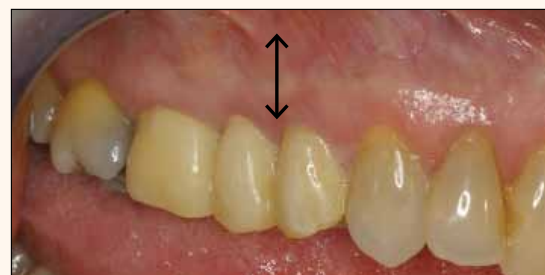

Fig. 4: A vertical line shows the more-than-adequate vertical zone — as well as desired color of attached gingival.

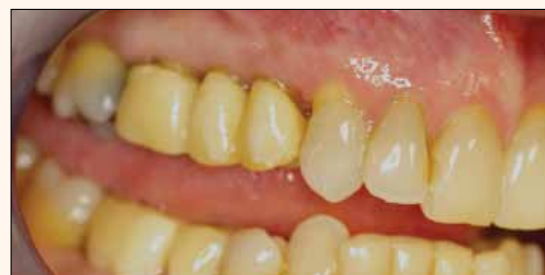

Fig. 5: The upper-right area now healed after cosmetic crown lengthening technique. Notice the preservation of the surgically manipulated attached gingival background and the lateral symmetry appearance of the future new restorations.

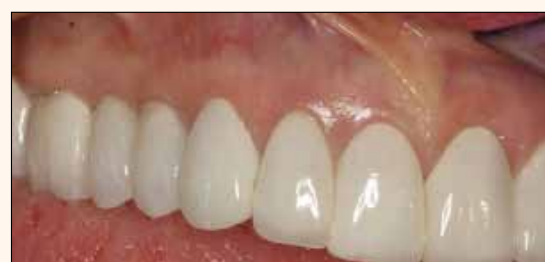

Fig. 6: Restored upper-right area. The new horizontal and vertical zone of healthy attached gingival allow the restorations to blend to a cosmetic healthy and maintainable smile.

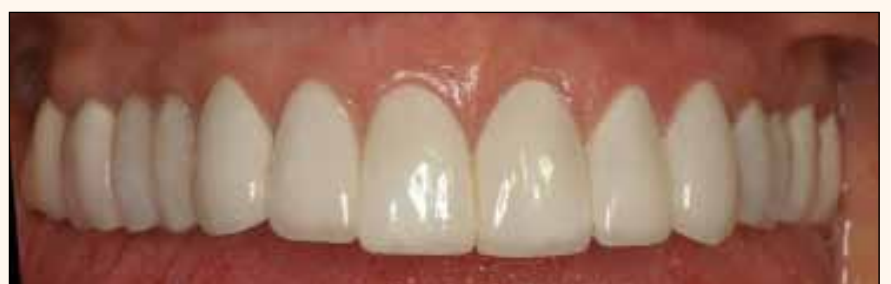

Fig. 7: Final treatment, labial view.

► See SYMMETRY, page A4

◀ SYMMETRY, page A3

achieve this symmetry and health. Several have been mentioned and described in this series. It must be stressed that it is the final goal that we should keep dominant in our sights — more so than any particular technique being used. The numerous techniques simply represent the various the paths to get there.

When we do not have enough keratinized gingiva, we can try to increase it. When we have too much (hyperplasia), we can remove it. If the color is not the desired color, we can change it.

There are many techniques available to achieve the desired goal.

The question of how much vertical keratinized attached gingiva is necessary has been discussed for years. The amount, if adequate, should be symmetrical to allow emphasis of the smile of the teeth, color and form that we wish to emphasize. But too often overlooked is the horizontal

aspect of the keratinized background. It should be symmetrical in width and height to provide a background that not only demonstrates health but enables our esthetic goal to be achieved — and maintained.

This case presentation will emphasize and demonstrate a team effort, in which I use several cosmetic periodontal surgical techniques, the skills of a very talented restorative dentist to visualize and then attain the patient's esthetic desires — as well as the patient herself, who is now able to maintain a healthy, attractive smile.

Case presentation

Mrs. S, a 62-year-old female, was referred to my office by an excellent cosmetic restorative dentist. (He has been awarded a fellowship in the International Academy for Dental Facial Esthetics.) Because of his exposure to different directives of treatment, including periodontal background

options and the required cosmetic periodontal surgical techniques that would be necessary, he referred Mrs. S to my office.

Mrs. S is a positive, cooperative, strongly opinionated woman. At her initial visit, she presented (Fig. 1) with a myriad of goals, all boiling down to the fact that she desired a bright, glowing smile. She emphatically did not wish to treat to cover her anterior maxillary centrals. She liked the length of her centrals. Her strongest desires were to correct the unevenness and the mélange of different colors appearing when she smiled. Obvious were the crowns with their exposed dark appearing margins, as well as the darker coloring of her natural teeth.

Through consultation, Mrs. S and I formulated a treatment plan: Initial periodontal therapy consisted of nonsurgical therapy, including scaling, curettage and oral hygiene instruction.

The next step was replacing the exist-

ing crown with physiological provisionals. Periodontal surgical techniques followed. Using the upper-right (UR) area as an example, we noted the uneven level of attached gingiva as well as periodontal pockets. I surgically manipulated the amount of keratinized gingiva and its placement vertically, in order to preserve the size of the zone of attached gingiva needed to ensure harmonious blending with the rest of the tissue mesiodistally.

The crown lengthening was basic, but the size — vertically and horizontally of the desired colored attached gingiva — was paramount to the final result (Figs. 4 and 5).

Letting the healing take its normal course with patience was next. However, we reinforced the need for constant oral hygiene — with supervised check-ups.

When the proper healing was completed, the area was re-prepped and the provisionals were extended on the recently clinically exposed roots towards the gingival.

This technique was done on all of her posterior sections. It was paramount to emphasize the preservation of the vertical and horizontal size of the attached gingiva, not only to create a healthy background for the desired smile — but to ensure a symmetrical, cosmetically appealing background.

Teeth may not be even, but the illusion of a smooth, glowing smile can still be portrayed. Success depends on the teamwork put into place by knowledgeable colleagues and the esthetic experiences they bring — blended with the patient's cooperation.

The final restorations were completed with full-coverage crowns on the posteriors. The anteriors were restored using porcelain laminates.

The vertical dimension, enhanced by a smooth, linear appearance and aided by the symmetrical background achieved through cosmetic periodontal surgery, enables the smile to be maintained and turned this patient's mouth into a glowing smile.

The author wishes to acknowledge the imaginative cosmetic and restorative dentistry seen in this case by Jerry Herman, DDS, New York, N.Y.

Editorial Note: Part 1 appeared in Dental Tribune U.S., Vol. 4, No. 13 & 14, and Part 2 in Vol. 6, No. 17.

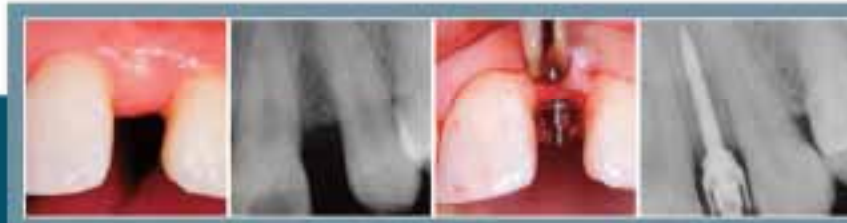

DAVID L. HOEXTER, DMD, FICD, FACD is director of the International Academy for Dental Facial Esthetics, and a clinical professor in periodontics at Temple University, Philadelphia. He is a diplomate of implantology

in the International Congress of Oral Implantologists as well as the American Society of Osseointegration, and a diplomate of the American Board of Aesthetic Dentistry. Hoexter lectures throughout the world and has published nationally and internationally. He has been awarded 11 fellowships, including FACD, FICD and Pierre Fauchard. He maintains a practice at 654 Madison Ave., New York City, limited to periodontics, implantology and esthetic surgery. He can be reached at (212) 355-0004 or drdavidlh@gmail.com.

AD

When you've considered all the options,
isn't it time to consider **ANEW**®



Courtesy of Dr. Stuart Fourn, 2001

Expanding implantology with more treatment options

ANEW implants provide gold-standard treatment options for many more patients. In areas of limited bone width, mesial-distal space or converging roots, ANEW is often an ideal solution. Available in 1.8, 2.2 & 2.4mm diameters and three thread lengths. With a tapered apical end, ANEW Implants can be placed in interdental spaces as narrow as 3.5mm without the need for bone augmentation or orthodontic interventions.

ANEW is the only narrow-body implant with a screw-retained prosthetic system and with over 10 years of clinical experience & research to support safe and reliable long-term use.

For more information visit www.DentatusUSA.com or call us at (800) 323-3138

Dentatus **ANEW**® Narrow Body Implants

visit GNYDM booth 1200
and see what's new

©2012 Dentatus USA, Ltd. Patent and Patents Pending

Dental Headache Care

The Fastest Growing Niche in Dentistry

Dentists can now predictably treat dental force related pain and dysfunction in the head, neck, face and jaw.



Practice Benefits

- + Advanced Patient Care
- + Increased Revenue
- + Increased Practice Value
- + 100% Financing
- + 100% Tax Deductible
- + New Patients
- + Team Mediated Treatments

Patient Benefits

- + Long Lasting Pain Relief
- + No Drugs
- + No Needles
- + 95% Clinical Success Rate
- + No Permanent Orthotic
- + Objective Digital Diagnosis

Opportunity

- + 80 Million U.S. Sufferers
- + MDs Refer Patients
- + State-of-the-Art Technology
- + Proven Science
- + Complete System
 - Hardware
 - Software
 - Training
 - Marketing

Training

- + Training at UNLV or NOVA
- + CE Credit for Dr. RDH, RDA
- + Hands-on Workshop
- + Full Program Manual in Print and eBook
- + One-on-One with TruDenta Instructors and Doctors



See dozens of patient, doctor and team member videos at DRSdoctor.com

To learn more, call 866-250-5657





The GNYDM boasts 1,500 exhibit booths with the industry's latest products and services from more than 600 companies. Photos/Provided by Greater New York Dental Meeting

Register now for Greater New York Dental Meeting

*Scientific meeting: Friday–Wednesday, Nov. 23–28;
exhibit floor: Sunday–Wednesday, Nov. 25–28*

The Greater New York Dental Meeting thanks everyone for their thoughts and concerns during and following Hurricane Sandy, and it sends the same to all those af-

ected. The Javits Convention Center and all the hotels are open, the roads and airports are operating and registration numbers in all categories are ahead of last year.

A full program of seminars, workshops, panel discussions, scientific poster sessions, "live" patient demonstrations, world-renowned speakers and the latest in dental-practice products and services await attendees at the Greater New York Dental Meeting. To view and register the courses and events, follow the links at www.gnydm.com.

In 2011, the Greater New York Dental Meeting registered 53,789 attendees from all 50 states and 127 countries. With its ever expanding exhibit floor, the GNYDM boasts its 1,500 exhibit booths including more than 600 companies. The continuous partnership with the U.S. Department of Commerce International Buyer Program provides the opportunity to meet many worldwide senior level volume buyers as well as receive export counseling from government specialists to increase sales.

The meeting is sponsored by the New York County Dental Society, representing the dentists of Manhattan and the Second District Dental Society, representing the dentists of Brooklyn and Staten Island.

Educational Highlights

- Friday, Nov. 23, kicks off the Meeting with Dr. Bernard Touati and Mr. Jean-Marc Etienne presenting "Anterior Implant Esthetics" at the New York Marriott Marquis Hotel in the Westside Ballroom 5th Floor
 - "Build Your Own Website for Your Dental Practice" is a new and unique three and a half hour hands-on workshop offered Saturday through Wednesday; the GNYDM will supply the computers, and attendees need to bring a USB flash drive with pictures and office information. You will leave this workshop with a fully functioning website
 - Don't miss the first ever "Smoking Cessation Seminar," which provides dental professionals an effective way to deliver tobacco-dependence treatment to patients. It is on Monday, Nov. 26.
 - "Botox, Dysport and Dermal Fillers" are the focus of unique hands-on workshops that introduce procedures on actual patients to teach dentists how to use Botox/Dysport and dermal fillers in their practices. The workshops are offered Saturday through Tuesday
 - More than 100 hands-on workshops feature the latest technological advances and the newest Dental materials
 - The "Sleep & Appliance Expo" features four days of the latest research and aware-

► See REGISTER, page A8

AD

No Pre-Registration Fee

The Largest Dental Meeting/Exhibition/Congress in the United States

MARK YOUR CALENDAR

**Scientific Meeting:
Friday - Wednesday,
November 23 - 28**

**Exhibit Dates:
Sunday - Wednesday,
November 25 - 28**

ATTEND AT NO COST
Never a pre-registration fee at the Greater New York Dental Meeting

MORE THAN 600 EXHIBITORS
Jacob K. Javits Convention Center 11th Ave. between 34-39th Streets (Manhattan)

HEADQUARTERS HOTEL
New York Marriott Marquis Hotel

LIVE DENTISTRY ARENA - NO TUITION

LATEST DENTAL TECHNOLOGY & SCIENTIFIC ADVANCES

MORE THAN 350 SCIENTIFIC PROGRAMS
Seminars, Hands-on Workshops, Essays & Scientific Poster Sessions as well as Specialty and Auxiliary Programs

EDUCATIONAL PROGRAMS IN VARIOUS LANGUAGES

SOCIAL PROGRAMS FOR THE ENTIRE FAMILY

ENJOY NEW YORK CITY AT ITS BEST DURING THE MOST FESTIVE TIME OF THE YEAR!

FOR MORE INFORMATION:
Greater New York Dental Meeting®
570 Seventh Avenue - Suite 800
New York, NY 10018 USA
Tel: (212) 398-6922 / Fax: (212) 398-6934
E-mail: victoria@gnydm.com

GREATER N.Y. DENTAL MEETING
WWW.GNYDM.COM

Sponsored by the New York County Dental Society and the Second District Dental Society

2 0 1 2

DO YOU HAVE A PLAN TO RETIRE YOUR DENTAL TOOLS?

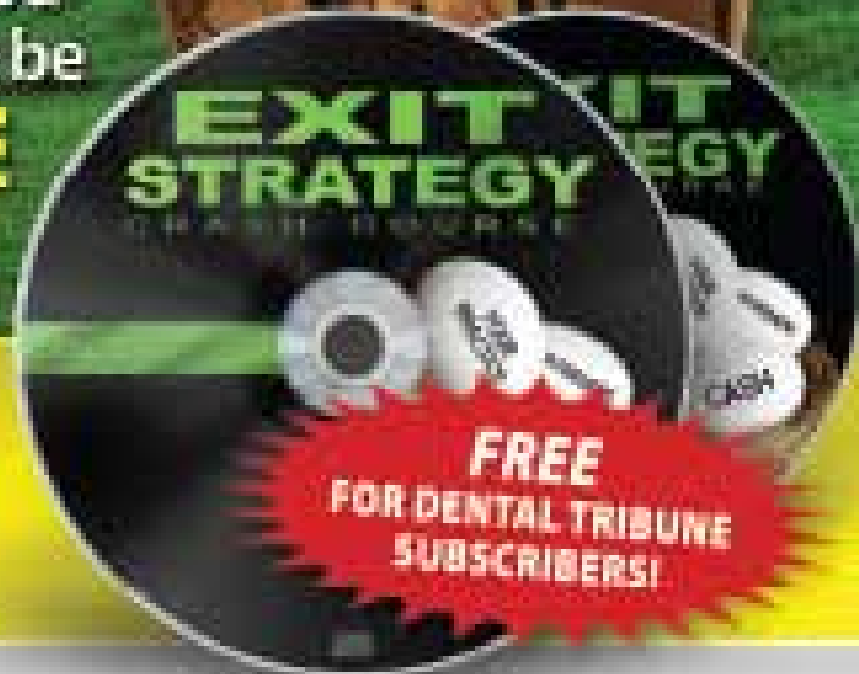Learn How to **CREATE**
YOUR EXIT STRATEGY

from Dentistry that will allow you
to Live the Lifestyle You Want and be

FINANCIALLY FREE

When You Retire!

**FREE 2-PART EXIT STRATEGY
CRASH COURSE ON CD** ➔



GO TO:

www.FreeMyPractice.com -OR-



FAX TO:

(866) 651-6445

Fill out the form below and fax back.

FILL OUT THIS FORM & FAX BACK


Doctor's Name _____

Office Address _____

City _____ State _____ Zip _____

Office Phone _____ Doctor Email _____

*Offer is subject to availability. Some restrictions may apply. See website for details. ©2010 Dental Tribune Group, Inc. All rights reserved.



The 430-seat high-tech "Live" dentistry arena, right in the exhibit hall, features four days of patient demonstrations every morning and afternoon — all at no charge.

• REGISTER, page A6

ness in dental sleep medicine. You'll learn how to establish dental sleep medicine protocols in your practice, identify patients at risk, integrate medical practice systems and treat patients successfully. Programs are offered every day.

- Be a part of the "Dentaverse Launch" with Dr. Larry Rosenthal's all-day seminar on Sunday, Nov. 25, and his "live" program all-day Wednesday, Nov. 28.

- "Learning and Lunch" is three days of programs on Sunday, Monday and Tuesday. Attendees receive C.E. credit and a free lunch at the close of the program. Space is limited.

- The "Invisalign Expo" is four days of Invisalign programming that will teach the entire dental team how to incorporate Invisalign into your practice.

- The "DentalXP" series offers headline speakers Dr. Henry Salama on Saturday, Nov. 24; Dr. Ronald Goldstein on Sunday,

Nov. 25; and Dr. David Garber on Monday, Nov. 26.

"Live" Dentistry Arena (Aisle 5,000)

The "Live" Dentistry Arena, a 430-seat high-tech patient demonstration area, offers revolutionary concepts of treating patients with new materials and applications. It takes place right on the exhibit show floor every morning and afternoon Sunday through Wednesday. There is no cost to attendees. Here is the schedule:

Sunday, Nov. 25

10 a.m.–12:30 p.m.

VOCO America presents "Everyday Esthetic Dentistry" with Dr. Franklin Shull. 2:30–5 p.m.

Philips Discus presents "Whitening Technology" with Dr. Marilyn Ward.

Monday, Nov. 26

10 a.m.–12:30 p.m.

VOCO America presents "Everyday Esthetic Dentistry" with Dr. Franklin Shull. 2:30–5 p.m.

OCO Biomedical presents "Simple Implant Placement" with Dr. Ara Nazarian.

Tuesday, Nov. 27

10 a.m.–12:30 p.m.

Benco Dental, COLTENE and Septodont present "Componers: a Live Demonstration" with Dr. Ross Nash. 2:30–5 p.m.

Millennium Dental presents "LANAP" Laser Assisted Periodontal Technique with Dr. Raymond Yukna.

Wednesday, Nov. 28

10 a.m.–12:30 p.m.

2:30–5 p.m.

DentaVerse presents "Anterior Esthetics" with Dr. Larry Rosenthal as well as other leading clinicians throughout the day.

Celebrity Speaker and Luncheon features Steven Forbes

The Celebrity Luncheon, sponsored by Henry Schein Dental, from noon to 2 p.m. on Monday, Nov. 26, features chairman and editor in chief of Forbes Media Steve Forbes. Forbes writes editorials for each issue of Forbes magazine under the heading of "Fact and Comment." A widely respected economic prognosticator, he is the only writer to have won the highly prestigious Crystal Owl Award four times. The prize was formerly given by U.S. Steel Corporation to the financial journalist whose economic forecasts for the coming year proved most accurate.

(Source: Greater New York Dental Meeting)



Scan this code to learn more about and register for the Dental Tribune Study Club C.E. Symposium at the Greater New York Dental Meeting. www.DTStudyClub.com



AD

3Shape Dental System™


A timeless solution that grows stronger rather than growing old

3shape



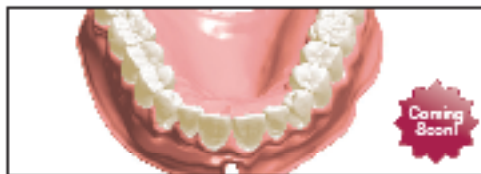Model Builder,

Create lab models directly from TRIOS® and 3rd party intraoral scans. Design implant models and all types of sectioned models ready for output on model-making machines.



An impression & model scanner for every lab

The D800 scanner, with two 5.0 MP cameras, provides high accuracy and captures textures and pencil markings. The fast and robust D700 is for productivity and the D600 for an easy entry into CAD/CAM.



Denture Design and more

Combine New Smile Composer™ with the unique Gingiva Creation tool to create highly esthetic and functional dentures. Enjoy also Implant Bridges, New Abutment Designer™, Post & Core, Orthodontic appliances and more.



TRIOS® Inbox & 3Shape Communicate™

Dental System™ includes free connectivity to TRIOS® systems in dental clinics so labs can receive impression scans directly. Smart communication tools enhance cooperation with the dentist.

Join us for 3Shape's Live events
Digital Solutions for
Dental Professionals



Scan the QR code to sign up, its free!
Or go to <http://3shapedental.com/Register>


Follow us on:



Join the Growing Number of Dental Practices



Embracing the Best Injection Technology



Now, you can have peace of mind knowing that the WAND® "All Injection Technology" will:

- ▶ Reduce patient chair time
- ▶ Increase patient referrals
- ▶ Increase production

THE WAND® "ALL INJECTION SYSTEM"

MILESTONE
SCIENTIFIC

WATCH US!!! IT ONLY TAKES 2 MINUTES!!!

STOP AT OUR BOOTH FOR A DEMO & RECEIVE A FREE BAG & STARBUCKS GIFT CARD.