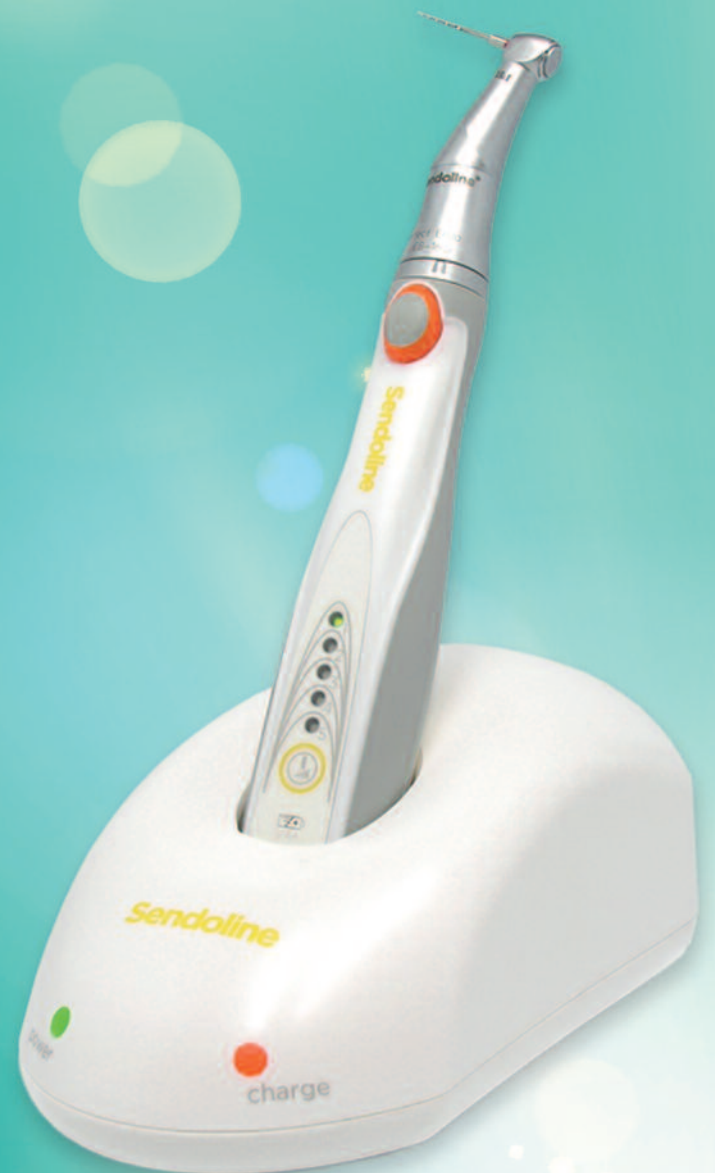

# roots

international magazine of endodontology

4<sup>2012</sup>



| **CE article**

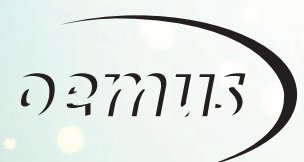
Invasive cervical resorption (ICR):  
A description, diagnosis and  
discussion of optional management

| **case report**

Iatrogenic errors before and after  
non-surgical root-canal treatment

| **research**

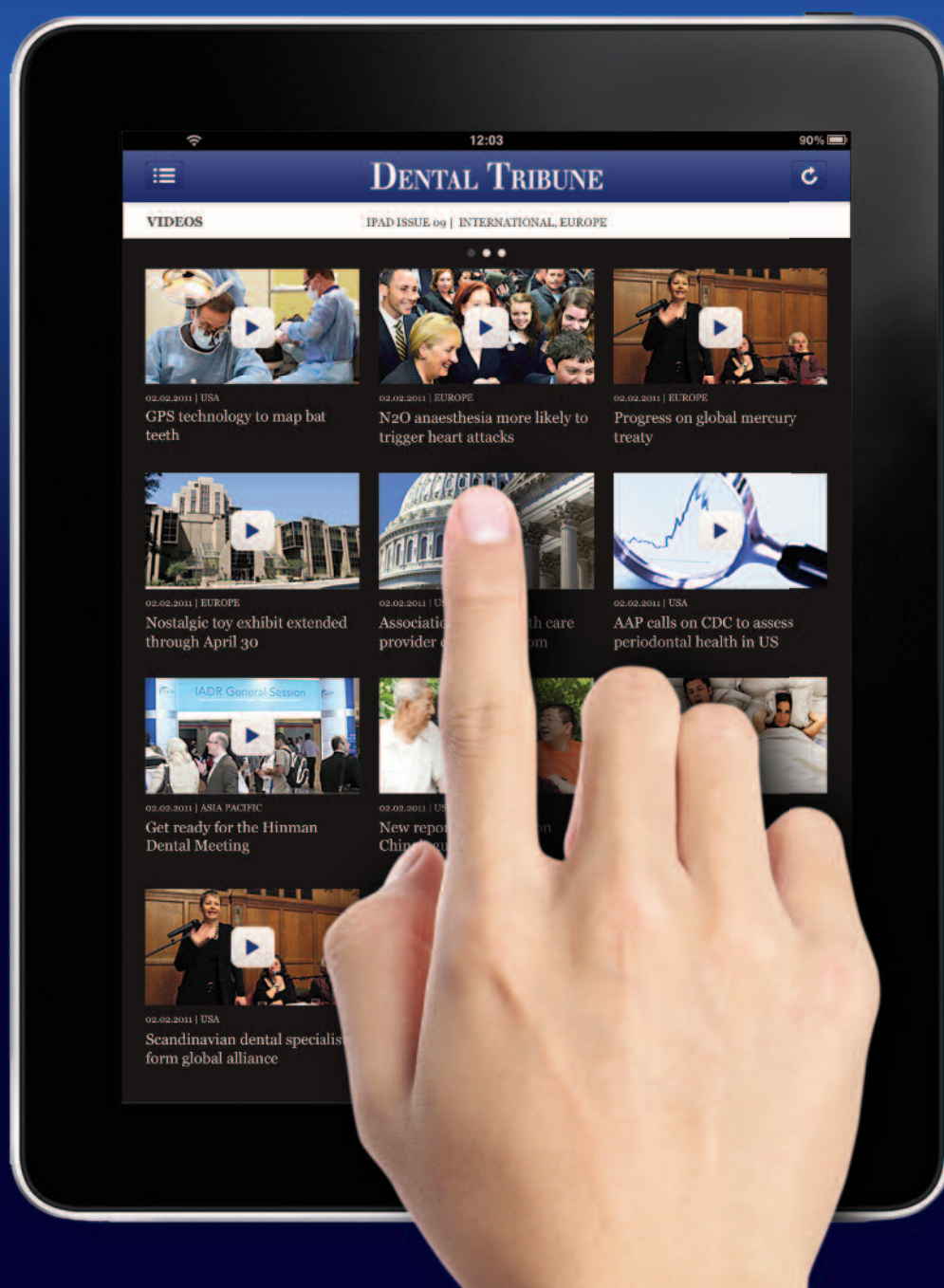Fluid dynamics of syringe-based irrigation  
to optimise anti-biofilm efficacy  
in root-canal disinfection



# Dental Tribune for iPad – Your weekly news selection

Our editors select the best articles and videos from around the world for you every week. Create your personal edition in your preferred language.

[ipad.dental-tribune.com](http://ipad.dental-tribune.com)



# DENTAL TRIBUNE

— The World's Dental Newspaper —

# Interdisciplinary dentistry: An absolute essential



Dr Gary Glassman

**We are fortunate to live** in a society in which we have access to comprehensive health care and in which the level of dental care is considered among the best in the world. Unfortunately, this is not the case for countless other regions in the world.

In an attempt to pay it forward, I have for many years now been doing charitable work for the people of Jamaica, in addition to teaching the local dentists there how to provide proper endodontic care to their patients. Recently, a new dental school was constructed at the University of Technology in Kingston, Jamaica, and I was appointed Adjunct Professor of Dentistry and was asked to construct an endodontic programme, which will produce its first graduates in 2015. Following the graduation of these well-trained individuals, for the very first time, the 2.6 million residents of Jamaica will finally have accessible to them the number of dentists per capita that is required.

This past weekend I had the good fortune to return to Kingston and speak at the Rosalie Warpeha Caribbean Institute for Strategic Planning and Research in Oral Health.

I spent the weekend with a restorative dentist, an oral radiologist, a cosmetic dentist, an orthodontist, an oral pathologist and a paediatric dentist. What started out as social events quickly became brainstorming sessions, during which we all soon realised how integrated *all* disciplines of dentistry need to be but are unfortunately lacking in many respects.

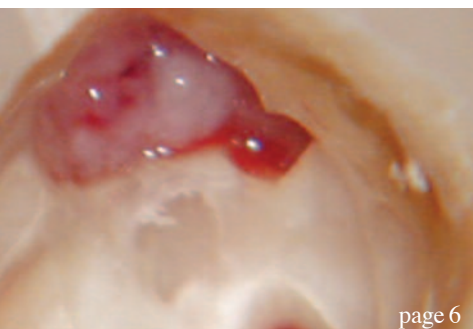
As specialists, we tend to pigeonhole ourselves into our specific areas of expertise and often lose perspective, unable to see the forest for the trees. Discussions of horizontal and vertical integration in dental school curricula soon became a topic of total agreement among our esteemed colleagues. A continuum of integration through case learning is both beneficial and essential. This allows students to be capable of using their acquired foundational knowledge to approach subject matter with critical thinking skills.

Case-based teaching has a long tradition in medicine, nursing, law and many dental programmes. It is an important method of distilling the basic knowledge learnt in texts and lectures and applying it to a patient in a practical manner. As practising dentists, many of us were not exposed to this type of learning, and were left alone with the skills that we acquired in dental school to figure it out on our own.

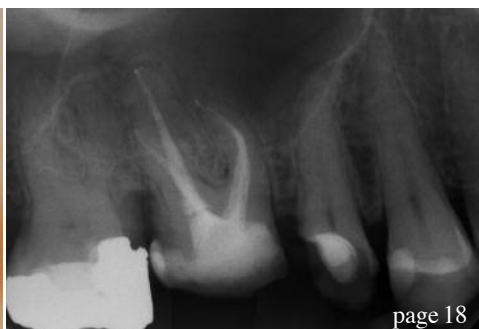Through properly structured continuing education programmes, we can return to the roots of education and combine our knowledge in an interdisciplinary manner by conferring intimately with members of other specialties, through panel discussions and case presentations. By approaching learning in this capacity, all of our patients in all of our respective countries will benefit from continued oral health, with successes that will be enjoyed at levels never seen before.

Dr Gary Glassman  
Doctor of Dental Surgery  
Fellow of Royal College of Dentists of Canada






page 6



page 18



page 22

| editorial

03 **Interdisciplinary dentistry: An absolute essential**  
| Dr Gary Glassman

| CE article

06 **Invasive cervical resorption (ICR): A description, diagnosis and discussion of optional management— A review of four long-term cases**  
| John J. Stropko

| case report

18 **Iatrogenic errors before and after non-surgical root-canal treatment**  
| Dr Rafaël Michiels  
34 **Endodontic management of a hypertaurodontic maxillary first molar— A case report with a two-year follow-up**  
| Drs Jojo Kottoor & Dr Anil Kishen

| research

22 **Fluid dynamics of syringe-based irrigation to optimise anti-biofilm efficacy in root-canal disinfection**  
| Dr Christos Boutsoukis et. al.

| special topic

32 **Irrigation for the root canal and nothing but the root canal**  
| Dr Philippe Sleiman

| industry news

38 **VDW Motors produced in Tuscany, Italy**  
| VDW

| meetings

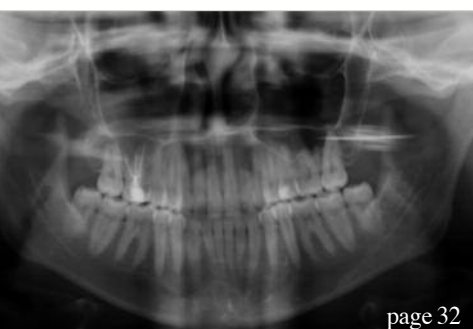40 **International Events**

| about the publisher

41 | submission guidelines  
42 | imprint



Cover image courtesy of Bisico, www.bisico.fr



page 32



page 38



page 40



Tribune CME

# Clinical Masters Program in Aesthetic and Restorative Dentistry

10-14 January 2013 and 24-27 April 2013 in Dubai, for a total 9 days

## Dubai, UAE

2 on location sessions with **live patient treatment** and **hands on** in each session!  
+ online live and recorded lectures, **online mentoring**



Didier Dietschi



Francesco Mangani



Panos Bazos

## Session I: 10 - 14 January 2013 (5 days)

- Direct/Indirect composite Artistry in the Anterior Segment
- Direct/Indirect composite Artistry in the Posterior Segment
- Photography and shade analysis

### Clinical Masters:

Didier Dietschi, Francesco Mangani, Panos Bazos



Mauro Fradeani



Urs Brodbeck

## Session II: 24 - 27 April 2013 (4 days)

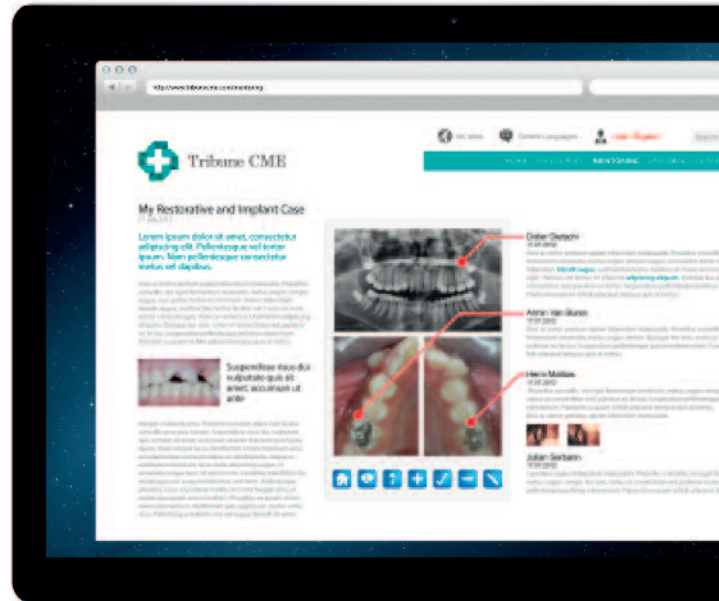- Full coverage Anterior/Posterior Restoration
- Partial coverage Anterior/Posterior Restoration, Ceramic Restoration

### Clinical Masters:

Mauro Fradeani, Urs Brodbeck

**ADA CERP®** | Continuing Education Recognition Program

Tribune America LLC is the ADA CERP provider. ADA CERP is a service of the American Dental Association to assist dental professionals in identifying quality providers of continuing dental education. ADA CERP does not approve or endorse individual courses or instructors, nor does it imply acceptance of credit hours by boards of dentistry.



Full access to our online learning platform: hours of premium video training and live webinars collaborate with peers and faculty on **your cases**

## Registration info

### Course fee: € 8,900

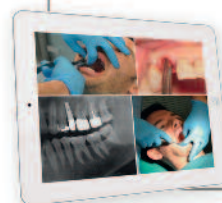Register by the end of October and you will receive a complimentary iPad preloaded with premium dental courses

Tribune CME

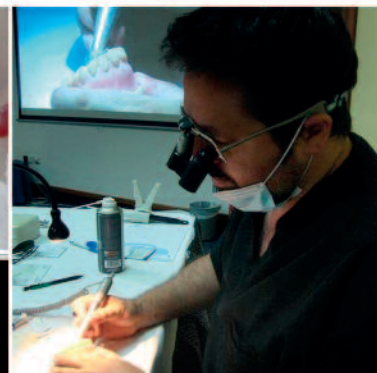
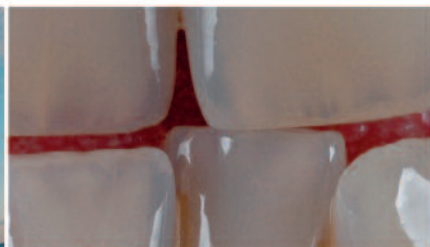
Tel.: +49-341-48474-302

email: [info@tribunecme.com](mailto:info@tribunecme.com)

[www.TribuneCME.com](http://www.TribuneCME.com)



## Discover the Master's secrets and Dubai's superlatives



# 100

C.E. CREDITS


ADA CERP



# Invasive cervical resorption (ICR): A description, diagnosis and discussion of optional management — A review of four long-term cases

Author\_ John J. Stropko, USA

\_ce credit
roots



By reading this article and then taking a short online quiz, you will gain one ADA CERP CE credit. To take the CE quiz, visit [www.dtstudyclub.com](http://www.dtstudyclub.com). The quiz is free for subscribers, who will be sent an access code. Please write [support@dtstudyclub.com](mailto:support@dtstudyclub.com) if you don't receive it. Non subscribers may take the quiz for a \$20 fee.

## \_Abstract

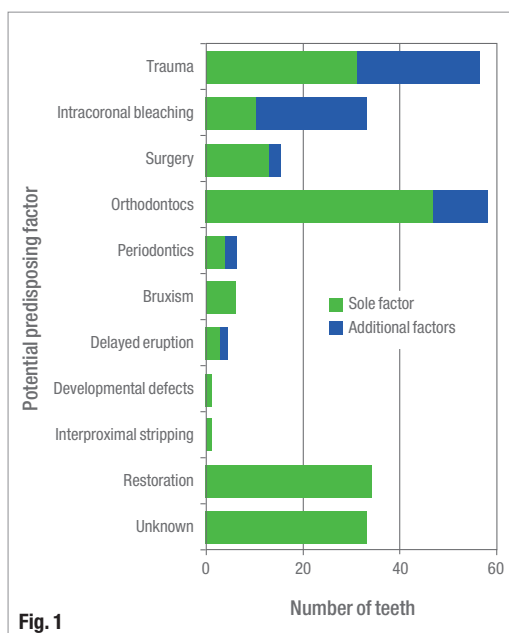
The external resorptive process of the permanent dentition referred to in this article has been given several different terms over the years, so therefore some confusion exists. Just a few popular labels are extra-canal invasive resorption (ECIR), invasive cervical resorption (ICR), external cervical resorption (ECR),

subepithelial external root resorption, and idiopathic external resorption. They all refer to a relatively uncommon form of dental resorption. If left undiagnosed, misdiagnosed, mistreated or untreated, it will usually be quite devastating for a tooth. An Australian dentist, Dr Geoffrey Heithersay, has contributed much to the literature regarding all facets of this type of dental resorption. His work has become the basis of research and treatment. With few changes over the past several years, the aetiology, predisposing factors, classification, clinical and radiological features, histopathology and the treatment of this resorptive process he described are still used in our practice today.<sup>1-4,6</sup> For this reason, this article will adopt the same nomenclature used in his numerous publications: invasive cervical resorption (ICR).

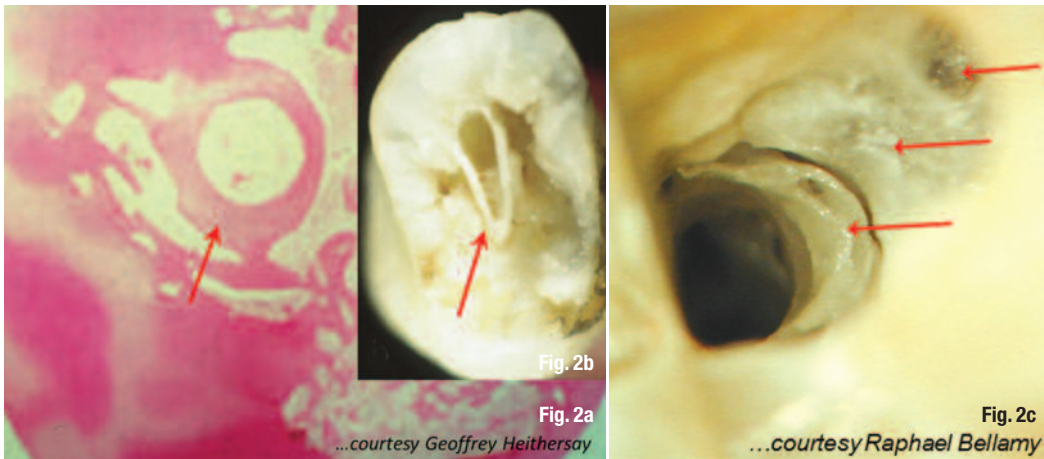
I will present treatment of four cases—two Class 2 cases, one Class 3 and a Class 4—in an attempt to share some experiences, both good and bad, over the years when dealing with ICR. Hopefully, the following article will be successful in removing some barriers that may currently prevent the doctor from accepting the challenge presented by the next case of ICR.

## \_Aetiology of invasive cervical resorption

ICR is not a common occurrence, is insidious and often an aggressive form of external tooth resorption, and can occur in any tooth in the permanent dentition.<sup>4</sup> External resorption can be divided into three broad groups: (a) trauma-induced tooth resorption; (b) infection-induced tooth resorption; and (c) hyperplastic invasive tooth resorption.<sup>5</sup> ICR is one form of hyperplastic invasive tooth resorption.<sup>6</sup> It results in the loss of cementum and dentine by an odontoclastic type of action.<sup>7</sup> The ICR lesion begins just apical of the epithelial attachment of the gingiva at the cervical area of the tooth, but can be found anywhere



**Fig. 1** Invasive cervical resorption: Distribution of potential predisposing factors for patients. (Reproduced with permission from Quintessence Publishing).<sup>2</sup>



**Figs. 2a & b\_** The pulp remains intact, encircled by a narrow band of dentine (red arrows). Histologically, the pulp remains intact and is protected from the extensive resorptive lesion by a narrow wall of dentine (a). A low powered photograph shows the walling off of the pulp by dentine, protecting it from the surrounding extensive resorptive process (b). (Slide adaptation reproduced with permission from Dr Geoffrey Heithersay.)

**Fig. 2c\_** High magnification of the distal orifice of a mandibular second molar being treated for ICR. The pulp remains intact encircled by a narrow band of dentine (bottom arrow). The affected dentine can be observed (middle arrow) and a possible distal penetration area (top arrow). (Slide adaptation reproduced with permission from Dr Raphael Bellamy.)

on the root.<sup>8</sup> Owing to its location, the beginning lesion is difficult or almost impossible to recognise. The exact mechanism of ICR is still not clearly understood. Microscopic analysis of the cervical region of teeth has shown that there appear to be frequent gaps in the cementum in this area, leaving the underlying mineralised dentine exposed and vulnerable to osteoclastic root resorption.<sup>9</sup> It is broadly accepted that either damage to or deficiency of the protective layer of cementum apical to the gingival epithelial attachment exposes the root surface to osteoclasts, which then resorb the dentine.<sup>7</sup> In general, an area of radicular dentine around the cervical area of the tooth may be devoid of the protective covering of cementum, exposing the root surface to colonisation by osteoclast-like cells, allowing the resorptive process to begin. Osteoclastic action in that area of the radicular dentine eventually results in a hyperplastic resorptive lesion containing fibro-osseous tissue. In order for dental resorption to occur, three conditions are necessary: a blood supply, breakdown or absence of the protective layer, and a stimulus. In the case of ICR, the external protective layer is the cementum, and the internal layer is the predentine of the pulp.

Several potential predisposing factors have been identified: trauma, intracoronal bleaching, surgery, orthodontics, periodontics, bruxism, delayed eruption, developmental defects, interproximal stripping and restoration. Heithersay studied a group of 222 patients with a total of 257 teeth with various degrees of invasive cervical resorption. From the subjects' dental histories, it was determined whether there was a sole predisposing factor, or a combination of factors. The results are shown diagrammatically in Figure 1.<sup>2</sup> The results indicated that a history of orthodontic treatment was the most common sole factor (found in 47 patients), while other factors, mainly trauma and/or bleaching, were present in an additional 11 subjects. Trauma was the second-most common sole factor, with 31 teeth. Intracoronal bleaching, combined with other factors, had the

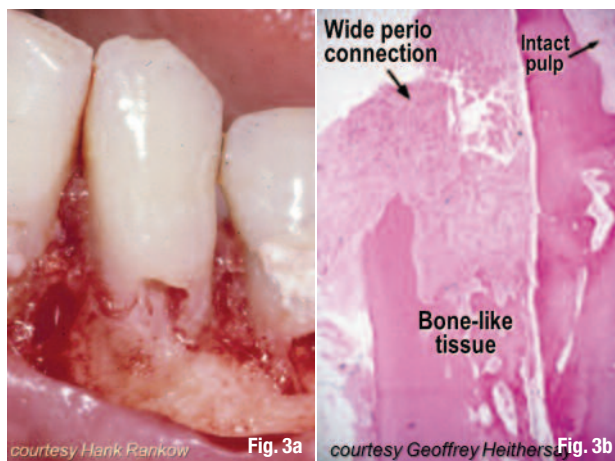
third-most affected teeth.<sup>2</sup> The pulp plays no role in the aetiology of ICR and remains normal until the ICR becomes very advanced.<sup>1,7,10</sup>

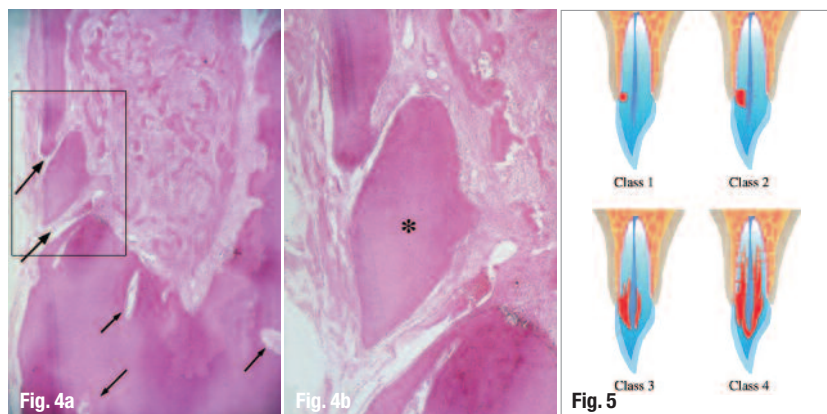
A recently published study has indicated there might be a connection between human and feline ICR. Four cases of multiple invasive cervical resorption (mICR) were presented. There was direct contact with cats in two cases, and indirect contact in the other two cases. Neutralised testing was done for feline herpes virus Type 1 (FeHV-1). Two of the cases were neutralised, and two were partly inhibited. The study indicates a possible transmission of FeHV-1 to humans and the possibility of its role as an aetiological (co)factor in ICR.<sup>11</sup>

### \_Histology

An interesting observation is that even in extensive lesions, the pulp is protected from the surrounding resorptive process by a narrow band of dentine (Figs. 2a–c). In some cases of ICR, the clinical and histological views of the lesion substantiate that bone-like tissue has replaced the fibro-vascular tissue located within the resorptive cavity (Figs. 3a & b). In the larger Class 3 and Class 4 lesions, communication channels

**Figs. 3a & b\_** Both the clinical view (a) and histological view (b) show how the dentine has been extensively replaced by a bone-like tissue. A mass of fibro-vascular tissue infiltrated with inflammatory cells is evident, located within a large resorptive cavity that has a wide connection with the periodontal tissue (large arrow). A small section of intact pulp can be seen on the superior aspect of the section (small arrow). Haematoxylin-eosin stain; original magnification X 30. (Reproduced with permission from Quintessence Publishing and Dr Henry Rankow.)<sup>1</sup>





**Figs. 4a & b** Histological appearance of an extensive ICR with radicular extensions. Masses of ectopic calcific tissue are evident both within the fibro-vascular tissue occupying the resorption cavity and on resorbed dentine surfaces. In addition, communication channels can be seen connecting with the periodontal ligament (large arrows). Other channels can be seen within the inferior aspect of the radicular dentine (small arrows). Haematoxylin-eosin stain; original magnification X 30. Higher magnification (b) shows communication channels from the periodontal ligament to the resorbing tissue. An island of hard tissue remains (\*), consisting of an external surface of cementum and cementoid with some residual dentine, but the bulk has been replaced with a bone-like material with a canalicular structure.

Although some red blood cells are evident near the deeper channel, no inflammatory cells can be seen. Haematoxylin-eosin stain; original magnification X 50. (Reproduced with permission from Quintessence Publishing.)<sup>1</sup>

**Fig. 5** Clinical classification of invasive cervical resorption. (Reproduced with permission from Quintessence Publishing.)<sup>2</sup>

can be seen connecting with the periodontal ligament. Other channels can also occur within the internal aspect of the radicular dentine (Figs. 4a & b). The larger, more advanced lesions can be described as consisting of granulomatous bone-like fibro-osseous material with a canalicular structure that has extensions into the radicular dentine and periodontal tissue. Osteoclasts might be observed on the resorbing surface within the lacunae.<sup>2</sup> Over varying amounts of time, the lesion expands apically and coronally, encircling the pulpal tissue that is protected by a thin wall of predentine and dentine.

### Clinical classification

Heithersay's clinical classification was developed as a guideline for treatment planning and comparative clinical research.<sup>2</sup> The classification is shown diagrammatically in Figure 5. The classification allows the operator to determine the probable extent of treatment more precisely. The more extensive the lesion, the more complex the treatment options become.

- \_Class 1: Small invasive resorptive lesion with shallow penetration into dentine.
- \_Class 2: Well-defined invasive resorptive lesion close to the coronal pulp chamber.
- \_Class 3: Deeper invasion extending into the coronal third of radicular dentine.
- \_Class 4: A large invasive lesion extending beyond the coronal third of the root.

Normally, a Class 1 lesion can be successfully treated without much difficulty. Class 2 lesions often require minor gingival flap surgery for retraction to achieve adequate access and removal of the affected dentine, and to restore the defect. Class 3 lesions usually involve a surgical approach and/or orthodontic extrusion. Class 1 and 2 lesions can be treated predictably, but the success rate in treating Class 3 and 4 lesions drops dramatically. Thus, in general, as the classification increases, the prognosis decreases.

### Diagnosis

The earlier the diagnosis, the more predictable the outcome of treatment will be. Owing to the nature of the lesion, treatment based on an incorrect diagnosis will usually result in continued progression of the resorptive process and eventual loss of the tooth.

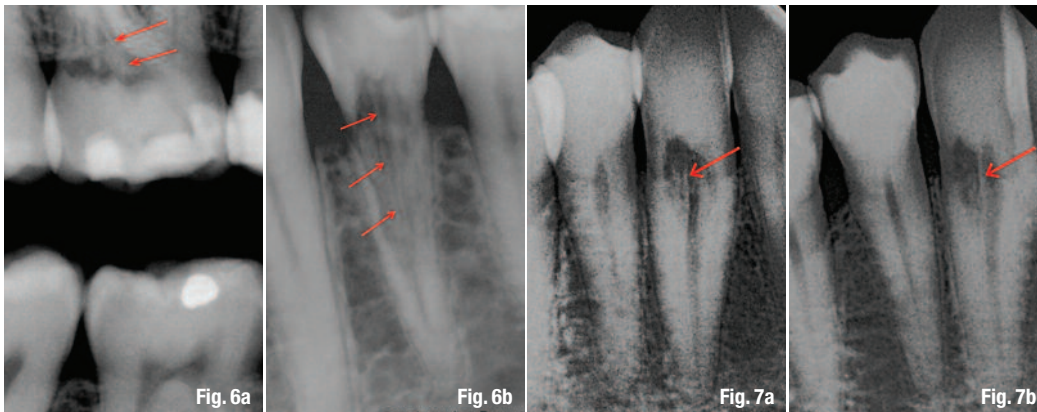
Unfortunately, the smaller Class 1 lesion is often not discovered owing to its location beneath the gingival attachment, but will usually show a small radiolucency on a radiograph. The dental examination may reveal a slight irregularity in the gingival contour, which will bleed upon probing.<sup>4</sup> It is my experience that Class 1 lesions are seldom found during routine dental examinations at this early stage.

One of the problems with early diagnosis is that the lesion is asymptomatic and can remain so even in the more advanced stages. Pulp testing will be of no value because the pulp remains unaffected until late in the process. However, the larger Class 2 lesion can present with more obvious clinical signs. For example, a patient notices a pinkish area on an anterior tooth. The discoloration is the result of osteoclastic activity replacing the radicular structure of the tooth with reddish granulation tissue that shows through the more translucent enamel.

Radiographically, the smaller Class 1 lesion can be confused with a carious lesion, internal resorption or adumbration (cervical burn-out) of the radiograph. If the lesion is a Class 2, Class 3 or Class 4, bitewing radiographs will often present an atypical radiolucency and the examining dentist will be more inclined to believe that it is not just a carious lesion. If the lesion is on the proximal surface of the tooth, the outline of the pulp can usually be observed. The larger lesions can also be misdiagnosed as caries or internal resorption. The usual indication that the lesion is not carious is the irregularity of the radiolucency and/or the radiopaque outline of the protective predentine layer of the pulp (Figs. 6a & b). By utilising varying angulation of the radiographs, internal resorption can be ruled out. If the lesion is due to internal resorption, it will remain centered what the direction, or "off-angle" the radiograph is taken. However, if the lesion is one of ICR, Clark's Rule, or SLOB Rule, can be used to determine the location of the lesion (the most lingual object moves with the direction of the X-ray head). (Figs. 7a & b).

With the advent of Cone Beam Computed Tomography (CBCT), the clinician is given the opportunity to view teeth and anatomical entities in three dimensions. Compare with the typical periapical radi-





**Figs. 6a & b** The outline of the pulp can usually be observed radiographically (a). The bitewing X-ray (b) will show the ICR lesion and the predentine layer (red arrows). The predentine protective layer can exist even in advanced Class 4 lesions (red arrows).

**Figs. 7a & b** A definitive way to avoid a misdiagnosis of ICR is to take the X-ray from varying angles, including at a normal position (a). However, when the X-ray is taken from a different, more distal angle (b), the radiograph clearly demonstrates that the lesion is not internal resorption and is positioned to the lingual surface. The protective predentine layer surrounding the pulp is clearly visible.

ographs (Fig. 8a). Even if numerous angles, a complete view of the extent of the lesion cannot be established with any definitive accuracy. The extracted tooth #16 was a hopeless Class 4 lesion involving most of the cervical half of the lingual surface and extending into the area (Fig. 8b). Three planes of sections can be evaluated with CBCT: the frontal/coronal (X), sagittal (Y) and axial (Z; Fig. 8c). The X plane moves anterior  $\leftrightarrow$  posterior (B  $\leftrightarrow$  L in the anterior teeth and M  $\leftrightarrow$  D in the posterior). The Y plane moves left  $\leftrightarrow$  right (M  $\leftrightarrow$  D in the anterior and B  $\leftrightarrow$  L in the posterior). The Z plane moves coronal  $\leftrightarrow$  apical for all teeth in the dental arch. Depending on the machine, up to 512 slices of the field of view can be visualised. The slice thickness is variable, again depending on the machine, from nearly 0.1 to several mm. However, generally speaking, the thinner the slice, the higher the spatial resolution.<sup>12</sup> When evaluating resorptive defects, higher resolution and 3-D images allow the experienced clinician to make a more definitive diagnosis and establish a confident and realistic plan for treatment, with a higher predictability of success.

In summary, the characteristic diagnostic signs that indicate that the lesion is a result of ICR are as follows:

- \_The tooth is asymptomatic.
- \_The pulp tests are within normal limits.
- \_The ICR defect moves with varying X-ray angulations.
- \_The protective pulpal wall is often intact and can be seen on the radiographs.
- \_The portals of entry are near the osseous crest.
- \_The portals of entry are difficult to locate clinically.<sup>13</sup>

I suggest that during the initial dental examination the patient be asked whether any of the three major predisposing factors have occurred in their dental history (bleaching, trauma or orthodontics). ICR can occur in any permanent tooth and once found in a patient, it is important to initiate regular follow-up visits to ensure no further lesions occur.

## \_Treatment

After the diagnosis of ICR has been confirmed, the treatment should be scheduled as soon as possible. If, for some reason this is not practical, the tooth should be monitored closely. The lesion can be very aggressive, so best not to wait for too long (Figs. 9a–c).

The Heithersay classification is of great help for advising the patient of the extent of treatment and gaining a better idea of the possible prognosis. The patient and doctor can decide on treatment together: (a) no treatment and extraction if the tooth becomes symptomatic; (b) extraction and possible replacement with an implant; or (c) to begin endodontic treatment in an attempt to eliminate the lesion and restore the tooth for as long as possible. In Class 1 and Class 2 cases, the patient must be advised that the treatment will probably be non-surgical but that the surgical approach may be necessary. In the more advanced Class 3 and Class 4 cases, the patient must be advised that both the non-surgical and surgical approaches will be necessary. Dental implants have become popular and, unfortunately, have led to a greater percentage of patients choosing the first two options.<sup>8</sup> However, there are still enough pa-

**Figs. 8a & b** Pre-op PAX for extraction of tooth #16 (a). The extracted tooth (b).

