




Video marketing
Now is the time to stand out in a crowd

▶Page 10



Easy money?
How one dentist turned \$6,000 into \$85,000

▶Page 12



New on the market
A better way to remove residual adhesive

▶Page 14



Washington, D.C. (Photo/stock.xchng)

AAO heads to Washington for its 110th annual session

Early registration for the American Association of Orthodontists' 110th annual session, taking place April 30–May 4 in Washington, D.C., is quickly coming up. Get your check in the mail or pay online (www.aaomembers.org) before Friday, March 26 to avoid late fees.

Also, for those who register by Thursday, April 1, make sure to sign up to participate in congressional office visits on Tuesday, May 4, including breakfast and transportation to and from Capitol Hill. The AAO and its legislative counsel will provide pre-arranged meetings

→ [OT](#) page 3

Harmonization of the dento-facial complex

Result is a combination of orthodontic and orthognathic surgical therapy

By Prof. Nezar Watted, Prof. Josip Bill and Prof. Jürgen Reuther, Germany

One of the main objectives of orthodontics, in addition to the diagnosis of dysgnathia, is to determine the status of indication for orthodontic treatment for which treatment necessity and prognosis are evaluated.

Occlusion, function and esthetics are considered equivalent parameters in modern orthodontics, particularly in combined orthodontic and orthognathic surgical treatment. This was achieved through the optimization of diagnostic tools and advancements and increasing experience in orthopedic surgery.

The objectives of orthodontic and orthognathic surgical treatments are:

- the establishment of a neutral, stable and functional occlusion with physiological condylar positioning;
- the optimization of facial esthetics;
- the optimization of dental esthetics, considering the periodontal situation;
- the assurance of the stability of

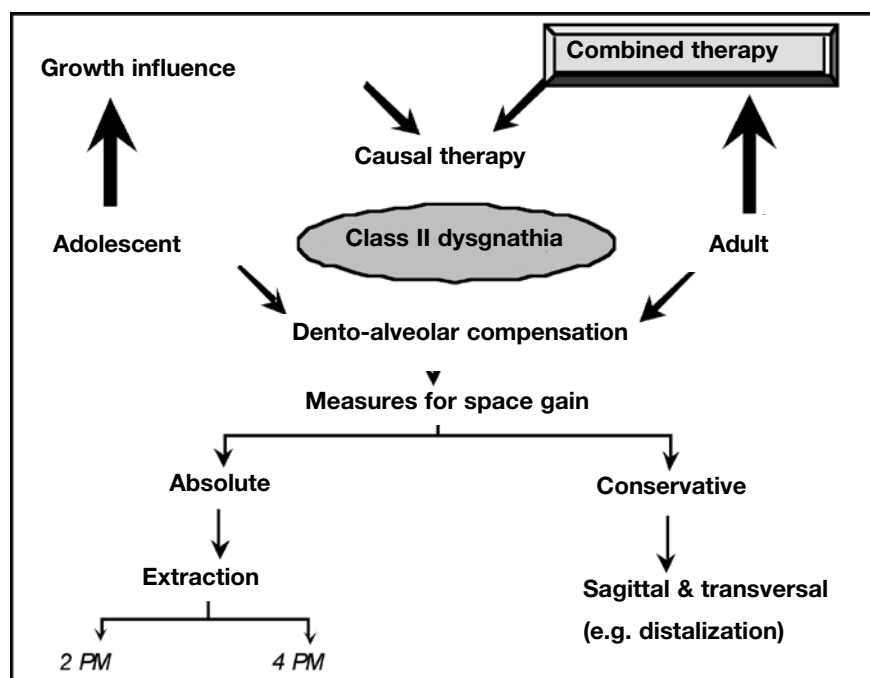


Fig. 1: Therapy options for the treatment of Class II dysgnathias.

- the results achieved; and
- the fulfilment of the patient's expectations.

The following factors are to be considered in assessing the prospects of success of orthodontic therapy:

- the degree of the dysgnathia;
- the growth configuration and potential;

- the individual reaction of the periodontal and skeletal structures;
- the general condition of the teeth;
- the patient's age;
- the patient's compliance;
- the patient's wishes and expectations; and
- the dentist's ability and experience.

→ [OT](#) page 4

PRSR STD
U.S. Postage
PAID
Permit # 306
Mechanicsburg, PA

Dental Tribune America
213 West 35th Street
Suite #801
New York, NY 10001

**POSTCARD
MARKETING
WORKS**

**\$135,000 in new cases in 2009
came from postcard marketing!"**
- Orthodontist from Johnstown, CO.

It's time to build your practice.

www.YourOrthoPostcards.com
www.Yourtown-Direct.com



855 780-2899

AD

Why orthodontists should be holistic

By Dennis J. Tartakow, DMD, MEd, PhD,
Editor in Chief



'People are likely to be best treated by doctors who treat them as whole and complete human beings'

In our world of dentistry, everything we know about alternative treatment modalities and the healing power of a listening bartender indicate that people are likely to be best treated by doctors who treat them as whole and complete human beings.

Not that I am Asklepios, the founder of medicine and reputed ancestor of the Asklepiades, the ancient Greek doctors' guild, but the ultimate answer to doctor-patient relationships and healing probably lies deep in a metaphysical labyrinth. It is rather obvious that patients have contexts, and the contexts matter and need to be understood.

Often the whole family of a young orthodontic patient will need to be in the mix of a patient's treatment for a successful result to occur; the orthodontist is the go-between to the whole nexus in which his or her patient is treated successfully or not.

We might have a duty only to the patient, but in order to properly fulfill that duty for legal purposes, the tentacles of understanding and enquiry must be ubiquitous.

Obviously, it is improper to treat only the symptoms of a disease. Practicing as holistic doctors, we acknowledge that malocclusion is most often a symptom of something

else, and our job as orthodontists is to track that problem to its source in order to accomplish effective and stable results.

This sounds almost mystical and, hopefully, exhilaratingly mystical. It makes every orthodontist a psychoanalyst, a detective, a shaman, a priest and a friend; it requires every doctor to be a whole human being, which is a highly romantic but essential calling.

Only whole human beings can treat whole human beings. Being a whole human being is not always easy to demand of anyone, but it is a particularly important demand of all clinicians whose training is so concentrated, who must be knowledgeable about so much and whose time per patient is so terribly limited — and now that is a problem.

How can orthodontists be made whole? How can we be equipped to deal effectively with the complex bundles of contradictions we call our patients? That is the quintessential essence and answer of doctoring! [OT](#)

(This editorial was inspired by an original essay: Foster, C. (2009). Why doctors should get a life. Journal of the Royal Society of Medicine, 102, pp. 518–520.)

Orthodontics is holistic dentistry. Surely that is correct. We, as prudent orthodontists, do not just treat a malocclusion; we treat a human being who happens to have a malocclusion.

This is a mind-body-spirit unity, and orthodontists are unique among professionals in this respect. Attorneys compose legal opinions while accountants get to the bottom line of a balance sheet. However, an orthodontist who does not treat the patient as a whole (holistically) misses the entire point of being a doctor.

These observations are not new concepts; the doctor-patient relationship is omnipotent. Bad relationships can do actual harm. Who would doubt that patients who trust their doctors are likely to do better than those who don't?

A sympathetic and compassionate doctor is more likely to be diagnostically and therapeutically accurate than one who imitates sympathy or has little compassion.

Tell us what you think!

Do you have general comments or criticism you would like to share? Is there a particular topic you would like to see more articles about? Let us know by e-mailing us at feedback@dental-tribune.com. If you would like to make any change to your subscription (name, address or to opt out) please send us an e-mail at database@dental-tribune.com and be sure to include which publication you are referring to. Also, please note that subscription changes can take up to 6 weeks to process.

AD

Dental Collab BETA
FINALLY A SOLUTION FOR GETTING THAT SECOND OPINION.
WWW.DENTALCOLLAB.COM
FIRST MONTH FREE
CODE: OTDC09
IT'S NEW

OT Corrections

The phone number and e-mail for the Axis Orthodontic Adhesive Removal Kit was incorrect in the February Supplement edition. The phone number is (800) 355-5065 and the e-mail is custserv@axisdental.com.

Ortho Tribune strives to maintain the utmost accuracy in its news and clinical reports. If you find a factual error or content that requires clarification, please report the details to Managing Editor Kristine Colker at k.colker@dental-tribune.com.



Image courtesy of Dr. Earl Broker.

Member Publication
AADE
American Association
of Dental Editors

ORTHO TRIBUNE
The World's Orthodontic Newspaper - U.S. Edition

Publisher & Chairman

Torsten Oemus
t.oemus@dental-tribune.com

Vice President Global Sales

Peter Witteczek
p.witteczek@dental-tribune.com

Chief Operating Officer

Eric Seid, e.seid@dental-tribune.com

Group Editor & Designer

Robin Goodman
r.goodman@dental-tribune.com

Editor in Chief Ortho Tribune

Prof. Dennis Tartakow
d.tartakow@dental-tribune.com

International Editor Ortho Tribune

Dr. Reiner Oemus
r.oemus@dental-tribune.com

Managing Editor/Designer

Ortho Tribune & Show Dailies
Kristine Colker
k.colker@dental-tribune.com

Managing Editor/Designer

Implant & Endo Tribunes
Sierra Rendon
s.rendon@dental-tribune.com

Online Editor

Fred Michmershuizen
f.michmershuizen@dental-tribune.com

Product & Account Manager

Humberto Estrada
h.estrada@dental-tribune.com

Product & Account Manager

Mark Eisen, m.eisen@dental-tribune.com

Marketing Manager

Anna Wlodarczyk
a.wlodarczyk@dental-tribune.com

Marketing & Sales Assistant

Lorrie Young, l.young@dental-tribune.com

C.E. Manager

Julia Wehkamp
j.wehkamp@dental-tribune.com

Dental Tribune America, LLC
213 West 35th Street, Suite 801
New York, NY 10001
Phone: (212) 244-7181, Fax: (212) 244-7185



Published by Dental Tribune America

© 2010, Dental Tribune International GmbH. All rights reserved.

Dental Tribune makes every effort to report clinical information and manufacturer's product news accurately, but cannot assume responsibility for the validity of product claims, or for typographical errors. The publishers also do not assume responsibility for product names or claims, or statements made by advertisers. Opinions expressed by authors are their own and may not reflect those of Dental Tribune International.

OT Editorial Advisory Board

Jay Bowman, DMD, MSD
(Journalism & Education)

Robert Boyd, DDS, MEd
(Periodontics & Education)

Earl Broker, DDS
(T.M.D. & Orofacial Pain)

Tarek El-Bialy, BDS, MS, MS, PhD
(Research, Bioengineering & Education)

Donald Giddon, DMD, PhD
(Psychology & Education)

Donald Machen, DMD, MSD, MD, JD, MBA
(Medicine, Law & Business)

James Mah, DDS, MSc, MRCD, DMSc
(Craniofacial Imaging & Education)

Richard Masella, DMD (Education)

Malcolm Meister, DDS, MSM, JD
(Law & Education)

Harold Middleberg, DDS
(Practice Management)

Elliott Moskowitz, DDS, MSd
(Journalism & Education)

James Mulick, DDS, MSD
(Craniofacial Research & Education)

Ravindra Nanda, BDS, MDS, PhD
(Biomechanics & Education)

Edward O'Neil, MD (Internal Medicine)

Donald Picard, DDS, MS (Accounting)

Howard Sacks, DMD (Orthodontics)

Glenn Sameshima, DDS, PhD
(Research & Education)

Daniel Sarya, DDS, MPH (Public Health)

Keith Sherwood, DDS (Oral Surgery)

James Souers, DDS (Orthodontics)

Gregg Tartakow, DMD (Orthodontics)

& Ortho Tribune Associate Editor

Baloul to receive AAO research award

Dr. Susan Baloul is the winner of the 2010 American Association of Orthodontists (AAO) Milo Hellman Research Award. The award will be presented at the Excellence Luncheon held during the annual session in May in Washington, D.C.

Baloul was chosen for this prestigious award based on her research, "Mechanism of Action and Morphological Changes in the Alveolar Bone in Response to Selective Alveolar Decortication Facilitated Tooth Movement." She chose this topic because of her interest and experience in both periodontics and orthodontics.

Baloul worked on this research during a three-year span while completing her DSc in orthodontics and dentofacial orthopedics at Boston University Henry M. Goldman School of Dental Medicine (GSDM).

Associate Professor of Periodontology and Oral Biology Dr. I. Alpdogan Kantarci mentored Baloul on the research project, which sought to test if corticotomy-induced osteoclastogenesis and bone remodeling underlie the orthodontic tooth movement and how selective alveolar decortication enhances the rate of tooth movement.

"This was an interesting area for us to get involved in and it was certainly a challenge to learn about bone biology in response to surgery-assisted orthodontic tooth movement," Kantarci said.

To better understand the mechanism, Baloul used 114 Sprague-

Dawley rats, which were separated into three treatment groups. The groups included corticotomy alone, tooth-movement alone and "combined" therapy.

Changes in each therapy group were assessed using faxitron analyses, microcomputed tomography, histomorphometric studies and quantitative-real time PCR (q-PCR) of expressed mRNAs.

Baloul "developed novel assays for alveolar bone structures of the rats, isolated sufficient amounts of RNA to study numerous markers by q-PCR, adapted micro-CT measurement for the three-dimensional changes in the alveolar bone and generated large amounts of samples

for future testing," Kantarci said.

"In order to complete such a thorough characterization of the alveolar bone response, [she] worked hard, spent weekends and evenings in the lab and evaluated her interim data very frequently, getting exposed to sophisticated statistical analyses."

The resulting data — which was consistent at all levels of analysis — suggested alveolar decortication enhances the rate of tooth movement during the initial tooth displacement phase. This results in a coupled mechanism of bone resorption and bone formation during the earlier stages of treatment, and this mechanism underlies the

rapid orthodontic tooth movement.

"It is an honor to be the recipient of the Milo Hellman Award," Baloul said. "I faced many obstacles and was challenged by many difficult decisions. Choosing to leave a prominent private practice was terrifying. However, it has proven to be one of my best decisions."

"My experience has been humbling yet rewarding. This confirms to me that I made the right decision and that pursuing a doctorate degree for a future career in academia is the correct path for me." **OT**

(Source: Boston University Henry M. Goldman School of Dental Medicine)

← **OT** page 1

with legislative staff as well as background materials and information.

Some of the other highlights of this year's meeting include:

- new course topics, including an examination of how stem cells and tissue engineering may impact the future of orthodontics, a look at current issues surrounding oral bisphosphonates and a discussion of the issue of access to orthodontic treatment.
- a special risk management program that will focus on common concerns at the beginning of an orthodontic career.
- live clinical procedures filmed and broadcast to both doctor and staff seminars. Topics include mini-implant insertion and application of laser technology.
- the music of Frankie Valli and the Four Seasons and a performance of the comedy "Defending the Caveman" during the opening ceremonies on Saturday, May 1.

For plenty more information on this year's AAO, plus a sneak peek of new products and other offerings you'll find on the exhibit hall floor, don't miss the April edition of Ortho Tribune. **OT**

Satisfy the growing demand for early treatment



Malocclusion in children is more prevalent than dental caries.

With the high demand from parents for early treatment now approaching, it is vital to learn how to arm yourself with the most cost effective treatment.

Take your business to the next level

MRC Clinics® – the latest innovation from MRC – aims to change the patient perception of modern dental practices.

Patients experience next-generation educational material, and receive interactive motivational assistance. These elements combine to assist and enhance long-term patient stability. Professionals will gain an easily integrated practice management system, designed to delegate key tasks away from the Doctor.

2010 MRC Lecture Series

The first step towards MRC Clinics® is to attend an Introductory Course. The course is presented with a clinical emphasis on myofunctional diagnosis and treatment. It also details how you can achieve better patient acceptance and profitability through enhanced education.

MRC Clinics® courses are held regularly in Europe, USA and Australia. Visit www.myoresearch.com for up-to-date course information.





MYOFUNCTIONAL RESEARCH CO.
www.myoresearch.com
a BETTER way

FOR MORE INFORMATION:

Call **1 866 550 4696**
Visit www.myoresearch.com

AD

← 01 page 1

In many cases, the objectives of dentoalveolar treatment measures — the achievement of the functional and esthetic optimum for the patient — can be achieved using modern treatment methods.

While minor dysgnathias can be treated using dentoalveolar measures only, successful treatment of prominent sagittal discrepancies, such as Class II dysgnathias, is far more difficult.

Correction can be achieved through dental movement if the jaw proportion is correct and if the dysgnathia is purely dentoalveolar. However, dental movements are possible only up to a certain degree and are thus limited.

A correction or stable dental compensation of a skeletal dysgnathia (for example, the correction of a frontal cross-bite in a Class III or the correction of an extremely enlarged sagittal overjet in a Class II) is doubtful in some cases and, in general, shows a compromise in esthetics and/or function.

In order to determine the options available for the therapy of a Class II dysgnathia, the remaining growth of the patient must be determined.⁵⁵ Functional orthodontic treatment is a therapy form that can influence growth and is considered a causal therapy in adolescents.^{8,51,57,67,70,71,79}

If there is no growth therapeutically, orthognathic surgery to correct the position discrepancy between both jaws is a causal therapy form (Fig. 1).

A premise for the successful realization of a combined therapy is that less invasive treatment options (for example, growth influence, as mentioned above) can no longer be used or do not achieve the treatment objectives or even worsen the situation (for example, extraction in a shallow mouth profile or distalization in a narrow overbite).^{55,54,77}

The second option for the causal therapy of a skeletal dysgnathia (Class II) using combined orthodontic and orthognathic surgical correction is discussed in this article, with a special focus on Class II dysgnathias with skeletal deep occlusion.

Case report: diagnosis

A 21-year-old female patient presented at our practice complaining of temporomandibular joint pain when chewing and poor esthetics,

Parameter	Mean	Before treatment	After treatment
G'-Sn/G'-Me'	50%	54%	50%
Sn-Me'/G'-Me'	50%	46%	50%
Sn-Stm/Stm-Me'	1:2 (33%:67%)	1:1.8 (37%:63%)	1:2 (34%:66%)
Sn-Li/Li-Me'	1:0.9	1:0.7	1:1

Table I: Proportions of soft-tissue structures before and after treatment.

Parameter	Mean	Before treatment	After treatment
SNA	82°	78.5°	78.5°
SNB	80°	73.5°	77°
ANB	2°	5° (incl. 1°)	1.5° (incl. 1.5°)
WITS-Wert	± 1mm	3.5mm	1mm
ML-SNL	32°	22°	27°
NL-SNL	9°	12°	12°
ML-NL	23°	10°	15°
Gonion-<	130°	111°	119°
SN-Pg	81°	76°	78°
PFH/AFH	63%	74%	70%
N-Sna/N-Me	45%	50%	46%
Sna-Me/N-Me	55%	50%	54%

Table II: Mean values or proportions of skeletal structures before and after treatment.

due to the malpositioning of her maxillary incisors.

The lateral image shows a frontal face oblique to the back, a deepened supramentale and, in comparison to the mid-face, a short lower face — 54:46 instead of 50:50 (Table I; Figs. 2a, b).

Owing to the enlarged overjet (15 mm), there was a malfunctioning of the lower lips in occlusion, owing to which lip closure was not possible without habitual, ventral positioning of the mandible.

Furthermore, the frontal image shows a Class II/1-dysgnathia angle, mesial deviation to the left, a deep occlusion (6 mm) with abrasion in the palatal mucous membrane and corresponding periodontal destruction palatal of the teeth Nos. 11 and 21, as well as anterior maxilla labial tilt.

In addition, there was clear crowding in the mandibular arch and slight crowding in the maxillary arch.

The maxilla was lowered while the mandible was raised, which was expressed by a difference in the

level of the distinctive Spee's curvature (Figs. 3a–c).

The FRS analysis (Tables I, II) clearly shows sagittal and vertical dysgnathia in the soft-tissue profile and the skeletal region.

The parameters indicated a skeletal deep occlusion with the typical extra-oral symptoms of the short-face syndrome: disto-basal jaw relation, small gonion angle, small interbase angle due to the anterior rotation of the mandible, large ratio between anterior and posterior facial height, and a growth pattern with an anterior course.

The vertical arrangement of the soft-tissue profile showed a disharmony between the mid-face and the lower face (G'-Sn:Sn-Me'; 54:46), which was expressed in the bony structures (N-Sna:Sna-Me; 50:50). Disharmony in the region of the lower face was also evident (Sn-Stm:Stm-Me'; 57:65).

These discrepancies in the ratio are the result of the deficient lower face, rather than the length of the upper lip.

An additional assessment of the lower face indicated that the ratio between the subnasal-labral inferius (Sn-Li) and the soft-tissue menton (Li-Me'), which should have been 1:0.9, was shifted in the favor of Sn-Li (1:0.7). This larger ratio was primarily caused by the short mandible (Figs. 4a, b).

Therapeutic objectives and treatment planning

An improvement of the facial esthetics, not only in the sagittal but also in the vertical axis, was a specific treatment objective. This was to be achieved through the elongation of

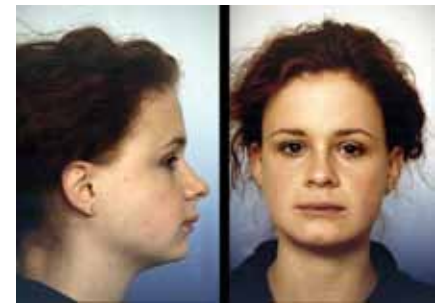

Fig. 2: Lateral view, left, of the 21-year-old patient, showing a posteriorly inclined upper face, short lower face and a deepened supramentale. Right, frontal view, showing the poor lip closure due to the anterior maxilla labial tilt and the enlarged sagittal overjet.

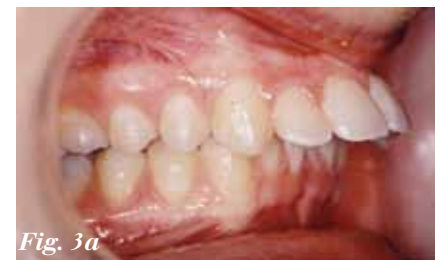

Fig. 3a

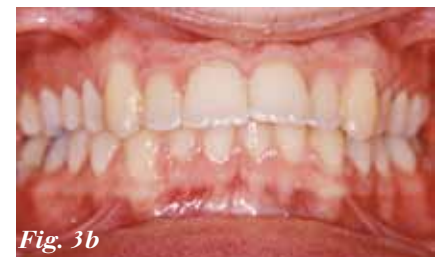

Fig. 3b

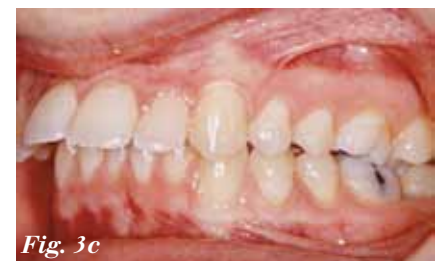

Fig. 3c

Figs. 3a–c: Clinical situation before the start of treatment.

the lower face without amplifying the prominence of the chin.

Elongation of the lower face as causal therapy and the subsequent effect on the facial esthetics could be achieved in the case of this patient using combined orthodontic and orthognathic surgical treatment. It would not have been possible to achieve the treatment objectives with respect to esthetics using orthodontic procedures alone.

The decisive step for the desired functional and esthetic results was taken during surgery. The surgical enlargement of the mandibular angle (gonion angle) was decisive for the improvement of the extra-oral appearance through a posterior rotation of the dentigerous segment.

The three-point support on the incisors and molars was a prerequisite for a stable enlargement of

AD

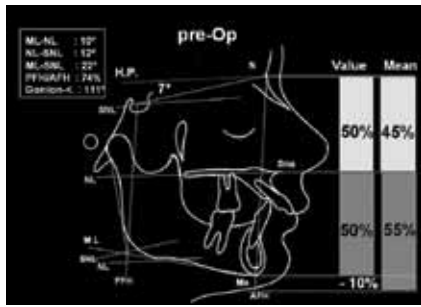


Fig. 4a: The cephalometric image shows the disharmonious skeletal arrangement in the vertical axis. The lower face shows a deficit of 10 percent in relation to the upper face. The mandibular angle and the interbase angle are small.

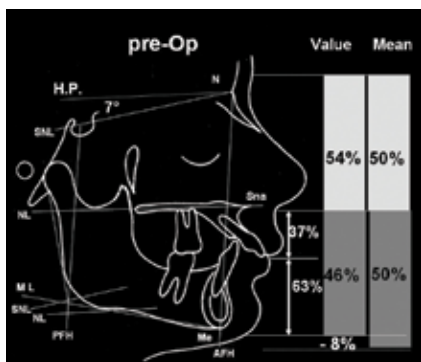


Fig. 4b: Disharmonious soft-tissue arrangement in the vertical axis: The lower face shows a deficit of 8 percent in relation to the upper face. Likewise, there is a disharmony in the division of the lower face.

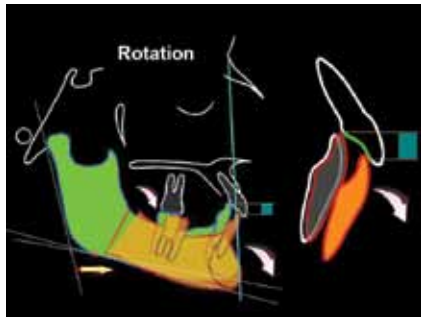


Fig. 5a: Simulation of a preliminary surgical translocation: An opening of the jaw angles is followed by the rotation of the mandibular segment during operation. The vertical blue line touches the pogonion of the initial situation: slight ventral shifting of the prominence of the chin. The anterior mandible glides along the palatal surfaces of the anterior maxilla (green line), which causes a posterior rotation (white arrow) and a vertical change (blue quadrangle).

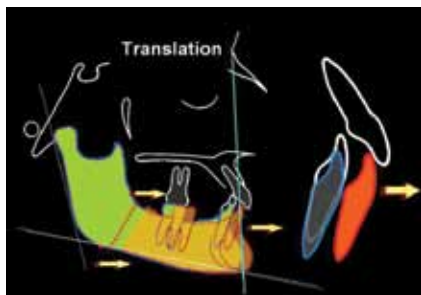
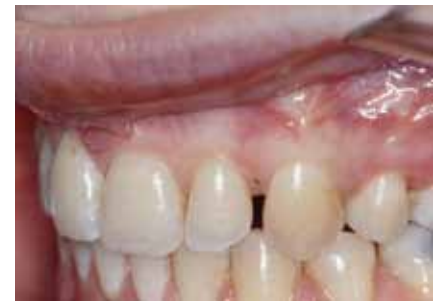
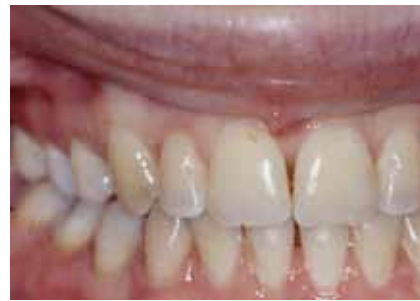
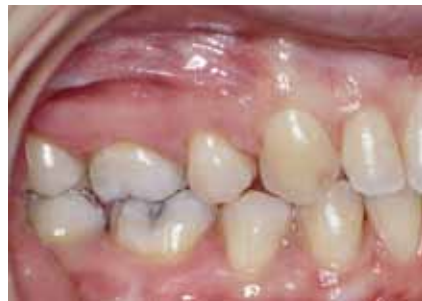Fig. 5b: Simulation of a preliminary surgical mandibular translocation: The correction in the sagittal disharmony was accomplished without changing the vertical ratio. The vertical blue lines touch the pogonion of the initial position: clear ventral shifting of the prominence of the chin.

(All photos: Provided by Prof. Nezar Watted)



Figs. 6a-c: Occlusion at the end of treatment: There is a neutral stable occlusion with physiological overjet in the sagittal axis and vertical axis, as well as a correct midline.

the jaw angle and thus a posterior rotation of the horizontal mandibular ramus.

Through the rotation, the menton was shifted caudally so that the skeletal situation and the soft-tissue profile of the lower face were improved in the vertical axis. Accordingly, the interbase angle was enlarged while

the ratio between the posterior and anterior facial height was reduced (Fig. 5a).

A translation of the dentigerous segment led to the correction of the sagittal dysgnathia without the improvement of the vertical axis. In addition, the translation resulted in an enhancement of the prominent

chin, which led to a flattened mouth profile and thus to a maturation of the patient's appearance (Fig. 5b).

Therapeutic procedure

The correction of the dysgnathia was done in six phases:

→ OT page 7

AD

THE REVOLUTION IS COMING!

The future of practice management success is coming in May.
www.TheEdgeRevolution.com

ORTHO2
 Practice Complete Management



UNIVERSITY OF MINNESOTA DIVISION OF ORTHODONTICS



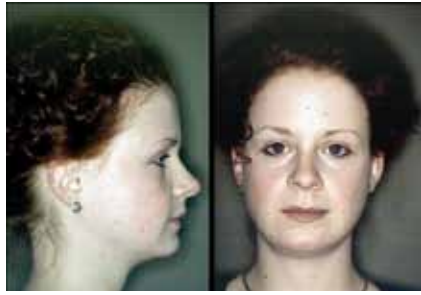



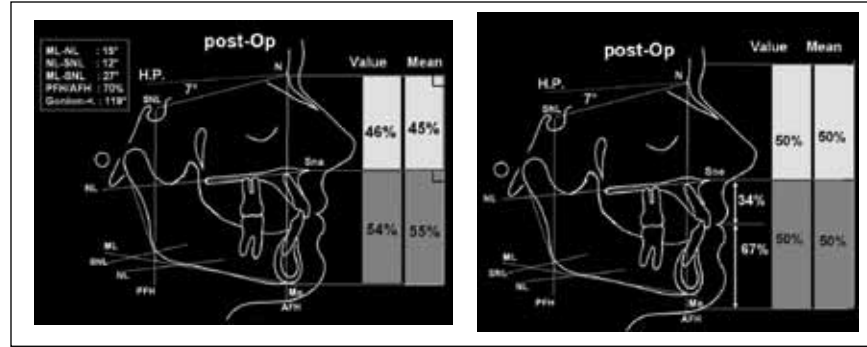
Fig. 7: The result of extra-oral treatment: The sagittal axis has been corrected without amplifying the prominence of the chin. At the same time, the vertical ratios have been harmonized, yielding a relaxed supramentale and competent lip closure.

← 01 page 5

- 1. Splint therapy:** An occlusal splint was inserted in the mandible for six weeks to determine the physiological condylar position or centric before the final treatment planning. The forced bite could thus be demonstrated to its full extent.
- 2. Orthodontic therapy:** Orthodontic therapy was used to form and adjust the dental arches relative to each other and to decompensate the skeletal dysgnathia. All first premolars were extracted to eliminate crowding and to align both fronts along the midline.
- 3. Splint therapy:** Four to six weeks prior to surgery, splint therapy was performed to determine the condylar centric and thus register the temporomandibular joint in a physiological position (centric).
- 4. Orthognathic surgery:** Orthognathic surgery was performed in order to correct skeletal dysgnathia. After a model operation, determination of the translocation path and production of the splint in the target occlusion, the preliminary surgical mandibular translocation was carried out by means of sagittal split according to Obwegeser–Dal Pont.
- 5. Orthodontic therapy:** Orthodontic therapy was used to close the lateral open occlusion and for fine adjustment of the occlusion. The open occlusion was to be closed only through the extrusion of the maxillary lateral incisors and not by the intrusion of the fronts.
- 6. Retention:** A 3–3 retainer was fixed in the mandible. A bimaxillary device was used for retention, allowing for the adaptation of the musculature in the new mandibular position.

Results

Figures 6a to 6c show the situation in occlusion and after closure of the lateral open bite, a neutral occlusion and correct midline with physiological sagittal and vertical overjet. The extra-oral photos show a harmonic three-way split of the face in the vertical axis, which was achieved through the surgical elongation of the lower face, and a harmonic profile in the sagittal axis. The mouth profile is harmonious, with relaxed lip closure and a well-



Figs. 8a, b: The cephalometric image after conclusion of treatment shows a harmonious ratio between the skeletal structures in the sagittal axis and in the vertical axis (a), as well as a harmonization in the soft-tissue profile between the upper and lower face (b).

balanced supramentale (Fig. 7).

The FRS shows the changes in the parameters that arose as a result of the enlargement of the gonion angle. The gonion angle was

increased surgically by 8 degrees. Accordingly, the mandibular slope was increased, which led to an enlargement of the interbase angle (around 5 degrees).

OT Contact




Prof. Nezar Watted
Wolfgangstrae 12,
97980 Bad
Mergentheim,
Germany
E-mail: nezar.watted@gmx.net

There is harmonization in the vertical arrangement of the bony and soft-tissue profiles. The disharmony of the lower face has been corrected, so that the ratio of Sn-Stm to Stm-Me' is nearly 1:2 and that of Sn-Li to Li-Me' is 1:1 (Figs. 8a, b; Tables I, II). 01

(Note: A complete list of references is available from the publisher.)

AD

Increase Production Now




Increased Production. More Starts. Proven Systems.

For more than 25 years, Levin Group has provided thousands of practices with the proven systems to increase orthodontic production. In this economy it is more important than ever before.

Take advantage of the opportunity to join Dr. Levin at his next breakthrough seminar, **The Principles of Maximum Ortho Production in Las Vegas on June 17 -18, 2010.**

Or Call **888.973.0000** to speak with a Senior Practice Analyst and determine your production potential.


Levin Group Inc.
www.levingrouppp.com

Copyright © 2010 by Levin Group, Inc. All rights reserved.

MONTRÉAL CANADA

CANADA'S LARGEST ANNUAL SCIENTIFIC AND DENTAL EXHIBITION

MAY 29th - JUNE 1st 2010
MONTRÉAL, QUÉBEC, CANADA

39th ANNUAL CONVENTION

ORDRE DES DENTISTES DU QUÉBEC
IS AN ADA CERP RECOGNIZED PROVIDER

FEATURING

- Over 75 scientific sessions in English and in French presented by top clinicians from around the world
- Over 240 exhibitors occupying more than 475 booths representing Canada's largest dental trade event
- Hands-on workshops and seminars covering all aspects of dentistry
- All scientific sessions and access to the exhibit floor included in one low registration fee
- CERP approved continuing dental education credits for all sessions
- Class reunions of the Quebec Dental Faculties
- Dental industry showcase presentations on the exhibit floor, featuring the latest developments in dentistry
- and much more

***All this under one roof at the Palais des congrès de Montréal
in the heart of downtown Montréal***



**Journées dentaires
internationales
du Québec**

JOINTLY WITH



**CANADIAN
DENTAL
ASSOCIATION**

For more information, please contact:

Journées dentaires internationales du Québec

15-625, boul. René-Lévesque Ouest, Montréal, QC H3B 1R2

Tel.: 514 875-8511 • Fax: 514 875-1561

E-mail: congres@odq.qc.ca • Website: www.odq.qc.ca

Please send me more information

Name _____

Address _____ City _____

State _____ Zip Code, Country _____

Telephone _____ E-mail _____

The power of goal setting

By Roger P. Levin, DDS

Every ortho practice should have clear and challenging performance goals. This is the first step in improving the practice and reaching the office's true production potential.

Without goals, the practice is often adrift and the team lacks a sense of true purpose. In such an orthodontic practice, the staff often experiences high stress and has one main objective — get through the day and go home.

Only by having goals and achieving those goals can orthodontists know the real meaning of total ortho success. This is truly the challenge of practicing orthodontics in the second decade of the 21st century.

Production potential

Like any business, orthodontic practices need to measure performance by establishing clear objectives. Levin Group recommends the following targets to clients to move them closer to their true production potential:

- Starts should grow by at least 10 percent or more annually.
- The close rate for new patient consults should be 85 percent or higher.
- Patient referrals from dentists should increase by 10 percent or more.
- The number of patients in observation should grow by at least 5 percent each year.
- The overdue debond rate should not exceed 2 percent.
- The collection rate should be 99 percent.
- The number of patients overdue for retainer checks should be less than 2 percent.

In the current economy, most orthodontic practices will have difficulty reaching these targets unless they have implemented document-

ed management and marketing systems. Once goals have been established, the next step is for practices to create the systems that allow the office to reach its targets.

Each ortho practice has a series of major business systems that include:

- Scheduling
- Treatment coordinator process
- Patient financial management
- Insurance management
- Case presentation
- Office communication
- Referral marketing

Effective systems set the foundation for attaining superior customer

service, outstanding productivity and increased production. The difference between high-performance orthodontic practices and others comes down to the efficiency of their business systems. Ortho practices with the best systems have managed — despite the economy — to meet their production targets and experience substantial growth.

Conclusion

Goal setting is critical to achieving success in your professional and personal life. Track goals weekly. Without a structured management approach in place, many practitioners are focused on day-to-day

operations and fail to see the true production potential within their practices. Goal setting can help you manage your practice instead of being managed by it.

To help you meet this year's production goals, get the proven solutions at Dr. Roger Levin's next Total Ortho Success™ Seminar being held April 8 and 9 in Chicago. Ortho Tribune readers are entitled to receive a 20 percent courtesy. To receive this courtesy, call (888) 973-0000 and mention "Ortho Tribune" or e-mail customerservice@levingroup.com with "Ortho Tribune Courtesy" in the subject line. [OT](#)

AD

OT About the author



Dr. Roger P. Levin is founder and chief executive officer of Levin Group, the leading orthodontic practice management firm. Levin Group provides Total Ortho Success™, the premier comprehensive consulting solution for lifetime success to orthodontists in the United States and around the world. Levin Group may be reached at (888) 973-0000 and customerservice@levingroup.com.

aesthetics
Virtually invisible on the tooth

strength
Three times greater fracture resistance than polycrystalline brackets*

safety
Debonds easily and safely with consistent and predictable bond strength

confidence
Radiance offers patients seeking aesthetic orthodontic treatment a better choice. Made from clear, translucent sapphire, Radiance enhances the patient experience while ensuring bracket integrity and safety for the patient.

Fused alumina particles embedded at the center of each tooth's bonding pad are engineered to release from the tooth within a range that is both safe for the patient, yet secure enough to hold firmly to the tooth throughout treatment.

radiance
...is confidence...

AO
AMERICAN
ORTHODONTICS

USA and Canada: 1-800-556-7687 www.americanortho.com

*Data on file