

DENTAL TRIBUNE

The World's Dental Newspaper · U.S. Edition

OCT. 20-26, 2008

www.dental-tribune.com

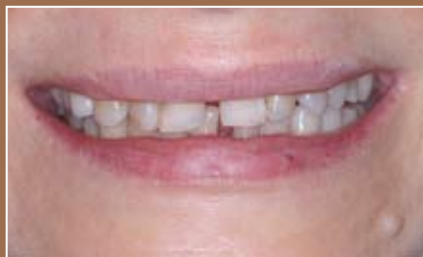VOL. 3, No. 37

Inside this week

Going to the Greater New York Dental Meeting?

If you are, you won't want to miss our "Getting started ..." Symposia, which are free for all attendees. If you've thought about getting started in endo, implants, cosmetic dentistry or digital dentistry then please join us! **Page 5**

Cosmetic Tribune: gingival health



As dentists, we can directly affect the esthetics of the teeth and gingiva. However, we can also indirectly affect the lips and face by how we design teeth to sit in the oral cavity. **Page 9**

Hygiene Tribune: smoking cessation, part 2

About 30 percent of patients in any given practice are current smokers. Although 70 percent of smokers say they are "interested" in quitting, only 10 percent to 20 percent plan to quit in the next month. **Page 13**

Are you a 'cutting edge dentist'?

By Robin Goodman
Group Editor

Dr. Martha Cortes, current president of the American Academy of Cosmetic Dentistry New York Chapter and former co-chair of dentistry with the American Society for Laser Medicine and Surgery, took some time to talk about lasers with Dental Tribune.

What is the state of lasers in dentistry today?

Dental lasers are state-of-the-art technologies. Every dentist should own one and use it as an integral part of his or her practice, especially as they are much more affordable than they were 15 years ago when I got my first laser; I had the the Duopulse by Excel Quantronix, which has two separate lasers in one unit: a holmium and neodymium laser. I still have this unit in my office and use

it as a backup laser to my newer ones. Lasers can be used by themselves or as an adjunct tool as they are versatile and precise. A simple diode laser can be used to disinfect tooth structure, in crown lengthening, frenectomy, biopsy, periodontal disease and gingival sculpting, etc.

There are lasers like the Perio-lase MVP-7, which are specifically built around a patented soft-tissue technique for periodontitis — laser assisted new attachment procedure [LANAP]. There are hard-tissue (modifies lasers) as well as soft-tissue (modifies lasers) and there are lasers available today that combine both a soft and hard tissue laser in one unit. It all depends on the practice one has, or the one that you want to develop. Bottom line is that you cannot consider yourself a dentist on the cutting edge if you do not have and use a laser as part of your daily regimen regardless of what

type of dentistry you practice.

How about lasers and soft tissue such as gum and pulp?

I have developed a direct pulp capping technique involving a laser and the immediate placement of a porcelain restoration [CEREC]¹, which has a great success rate as the laser can reach places that antiseptics and antimicrobials cannot reach because of their shallow penetration into bacterial colonies [biofilms]. Lasers can be used on the delicate tissue of the pulp without causing necrosis by using the correct settings and the right lasers.

Nd:YAG's and diodes are great for sculpting the gingival tissue in crown lengthening, smile makeovers and gingivectomy. Both can be used in treating gum disease, although the diode is not as ideal as the Nd:YAG laser, as it is hotter, can cut deeper

See Are you, Page 2

The critical missing element to complete care: where dentistry and orofacial myofunctional therapy meet (Part 1 of 2)

By Joy L. Moeller, RDH, BS, COM

I. Problems that can be addressed

- ▶ Does your patient complain about chronic headaches?
- ▶ Does your patient have an open-

mouth rest posture?

- ▶ Have your patient's teeth moved after orthodontic treatment?
- ▶ Does your patient exhibit an open bite?
- ▶ Does your patient complain of temporal mandibular joint dysfunction (TMD) or neck pain?
- ▶ Is the patient's tongue always "in the way" when you are drilling, scaling or examining the teeth?
- ▶ Does your patient exhibit a scalloped tongue from pressing against the teeth?
- ▶ Have you noticed oral habits

such as thumb or finger sucking, nail biting, lip licking or hair twirling or chewing?

- ▶ Does your patient lisp when saying the "s" sounds?
- ▶ Do you see the tongue come forward against the teeth when swallowing?
- ▶ Is your patient a mouth breather contributing to anterior gingivitis or open-mouth rest posture?
- ▶ Does your patient grind or clench his/her teeth?
- ▶ Does your patient have chronic

See Complete care, Page 2

AD

VOCO's advanced Nano technology sets a new bench mark for composites

DENTAL TRIBUNE 2007 REALITY 5+ Editors' Choice

WORLD-RECORD SETTING: 87% FILLERS

nanohybrid technology

Free Sample at www.voco-america.com

With natural fluorescence

Grandio

The award winning universal Nano Hybrid Composite with outstanding performance and superior handling

- Low shrinkage
- Great wear resistance

www.vocoamerica.com • info@voco.com

VOCO creative in research

Call toll-free 1-888-658-2584

PRSR STD
U.S. Postage
PAID
Permit # 306
Mechanicsburg, PA

Are you From Page 1

and has a potential greater zone of thermal damage in the wrong hands; it should not be used on pockets deeper than 4 mm. The Nd:YAG can be used to pocket depths above 12 mm. Those interested in the Nd:YAG for gum disease should really look at the Periolas MVP-7 by Millennium Dental Technologies as the laser is sold with instruction/training in the laser and LANAP technique.

And for lasers and hard tissue such as tooth and bone?

Erbium lasers are great for disinfection of teeth and for osseous surgery as they are specifically made for disinfecting and cutting hard tissue. They are also ideal for preparing class I and class V restorations and removal of defective composite materials; however, they cannot be used on metal or porcelains, as these cannot be cut by a laser.

Metals and porcelains must first be removed using the drill; however, once they are removed the laser can be used directly to remove any underlying caries. If the caries is very deep, the erbium laser can be used in a direct/indirect pulp-capping tech-

nique with the immediate placement of a CEREC 3-D porcelain restoration. An erbium laser like the Waterlase MD by Biolase can also be used in the direct treatment of root canals as it has laser endodontic tips that are used post instrumentation for cleaning and disinfecting the canal.

What are your thoughts on a connection between heart disease and periodontal disease?

I love it when patients tell me that they are fit and in good shape except, of course, for the severe gum disease they have. Unfortunately, we have grown up with faulty medical/dental health models that describe the body as distinct and disconnected units, and this shows up in how we view disease and the body. Severe infection in the body is dangerous as it can spread, especially to vulnerable organs.

Periodontitis is a bi-directional manifestation of disease. It can be seen as a manifestation of systemic disease such as diabetes, cutaneous disease, joint disease and osteoporosis. It can also be seen separately from systemic ones as its own complete disease with the great potential of releasing bacterial emboli into the blood system that can travel to the heart, lungs and other major

organs. It has been linked to cardiovascular disease since the late nineties and rightly so, as oral bacteria are not contained but spread and are particularly dangerous for heart patients who are vulnerable to endocarditis, especially before open-heart surgery.

An Nd:YAG laser can reduce microbial colonies that inhabit periodontal pockets by 97 to 100 percent, as the laser is precise, site specific and does not rely on secondary or tertiary effects to kill microbes. It destroys microbes and their colonies on contact without any side effects.

Editor's Note: Please see Cosmetic Tribune in this edition for a clinical article by Dr. Cortes and her contact information.

Complete care From Page 1

stomachaches, burping, drooling, hiccups or acid reflux?

- ▶ Does your patient have a forward head posture?
- ▶ Does your patient have a short lingual frenum or a tight labial frenum?
- ▶ When you check for oral cancer on the sides of the tongue, have you found lesions from tongue thrusting causing chronic irritation?

These are all signs and symptoms of an orofacial muscle asymmetry that can be addressed by an orofacial myofunctional therapist.

History of orofacial myofunctional therapy (OMT)


OMT is an area of specialization arising out of orthodontics. The field of OMT is unique because the therapist helps the patient to make major life-enhancing changes, which affect the entire body.

Many dentists during the 1800s and early 1900s recognized that tongue rest posture, mouth breathing and oral habits influenced occlusion. Edward H. Angle — justly termed by some as the grandfather of orthodontics — wrote “Malocclusion of the Teeth,” appearing in *Dental Cosmos* in 1907, in which he recognized the influence of the facial muscles on dental occlusion. In his research, he concluded that mouth breathing was the chief etiological factor in malocclusion.


The first program of OMT began in 1918 with an article written by an orthodontist, Dr. Alfred P. Rogers, titled “Living Orthodontic Appliances.” He was one of the first doctors in the United States who suggested that corrective exercises would develop tonicity and proper muscle function and thereby influence proper occlusion.

In the 1970s and '80s there were two different organizations representing therapists. Daniel Garliner and Dr. Roy Langer founded the Myofunctional Therapy Association, and Dr. Marvin Hanson, Richard

AD



HANDS-ON WORKSHOP




Narrow Body Implants to Stabilize, Cushion and Retain Lower Dentures

Without the use of: Housings O-Rings, Or Adhesives

Participate in the real-time procedure, installing Atlas® implants on a hard model. Retrofit the lab-made aesthetic denture and reline it with the Tuf-Link™ silicone material.

All steps and instruments are precisely the same as used in your office. Participants keep the model for staff training and patient education.




2008 Workshop Schedule	
Nov 5	New York, NY
Nov 5	Chicago, IL
Nov 14	San Francisco, CA
Nov 17	Miami, FL
Dec 10	Charlotte, NC
Dec 12	Anaheim, CA
Dec 15	Las Vegas, NV

Accreditation:
4 credits will be awarded upon completion of the course.

Keith Rossein, DDS
Hands-on Course Instructor

To register or for more information call Dentatus

Dentatus USA, Ltd.
1-800-323-3136
www.dentatus.com



FDA APPROVED FOR LONG TERM USE

© 2008 Dentatus USA, Ltd. • Patents Pending

DENTAL TRIBUNE

The World's Dental Newspaper - US Edition

Publisher

Torsten Oemus
t.oemus@dtamerica.com

President

Eric Seid
e.seid@dtamerica.com

Group Editor

Robin Goodman
r.goodman@dtamerica.com

Editor in Chief Dental Tribune

Dr. David L. Hoexter
d.hoexter@dtamerica.com

Managing Editor Endo Tribune

Fred Michmershuizen
f.michmershuizen@dtamerica.com

Managing Editor Implant Tribune

Sierra Rendon
s.rendon@dtamerica.com

Managing Editor Ortho Tribune

Kristine Colker
k.colker@dtamerica.com

Product & Account Manager

Mark Eisen
m.eisen@dtamerica.com

Product & Account Manager

Kimberly Price
k.price@dtamerica.com

Marketing Manager

Anna Wlodarczyk
a.wlodarczyk@dtamerica.com

Sales & Marketing Assistant

Lorrie Young
l.young@dtamerica.com

C.E. Manager

Julia E. Wehkamp
E-mail: j.wehkamp@dtamerica.com

Art Director

Yodit Tesfaye Walker
y.tesfaye@dtamerica.com

Dental Tribune America, LLC
215 West 35th Street, Suite 801
New York, NY 10001
Tel.: (212) 244-7181
Fax: (212) 244-7185



Published by Dental Tribune America
© 2008, Dental Tribune America, LLC.
All rights reserved.

Dental Tribune strives to maintain utmost accuracy in its news and clinical reports. If you find a factual error or content that requires clarification, please contact Group Editor Robin Goodman, r.goodman@dtamerica.com. Dental Tribune cannot assume responsibility for the validity of product claims, or for typographical errors. The publishers also do not assume responsibility for product names, or statements made by advertisers. Opinions expressed by authors are their own and may not reflect those of Dental Tribune America.

Editorial Board

Dr. Joel Berg
Dr. L. Stephen Buchanan
Dr. Arnaldo Castellucci
Dr. Gorden Christensen
Dr. Rella Christensen
Dr. William Dickerson
Hugh Doherty
Dr. James Doundoulakis
Dr. David Garber
Dr. Fay Goldstep
Dr. Howard Glazer
Dr. Harold Heymann
Dr. Karl Leinfelder
Dr. Roger Levin
Dr. Carl E. Misch
Dr. Dan Nathanson
Dr. Chester Redhead
Dr. Irwin Smigel
Dr. Jon Suzuki
Dr. Dennis Tartakow
Dr. Dan Ward

Barrett, William Zickefoose, and Galen Peachey founded the International Association of Orofacial Myology (IAOM). Currently the IAOM is the main professional organization in the world promoting and developing orofacial myofunctional therapy.

The team approach

Today the field is expanding to include many professions. Through a team approach, the patient can experience the best of all worlds and achieve remarkable results. The interdisciplinary approach to patient wellness includes but is not limited to:

- ▶ orthodontics
- ▶ general dentistry
- ▶ speech-language pathology
- ▶ dental hygiene
- ▶ periodontics
- ▶ oral surgery
- ▶ ear, nose and throat specialty
- ▶ cranial osteopathy
- ▶ allergology
- ▶ pediatric dentistry
- ▶ pediatrics
- ▶ physical therapy
- ▶ chiropractics
- ▶ gastroenterology
- ▶ plastic surgery

Failure to help many patients

Through 30 years of practicing orofacial myofunctional therapy, some questions patients or their parents asked me include:

- ▶ Why didn't someone tell me about this earlier?
- ▶ I knew I had a tongue thrust, I didn't know there was a special person to help me.
- ▶ Why didn't someone tell me my habit of tongue thrusting, thumb sucking or nail biting could be easily eliminated in therapy?
- ▶ I have tried multiple splints, functional appliances, medications and occlusal adjustments for my TMD problem. I was even referred to a psychologist for counseling because they told me it was stress related. Why didn't someone recognize my facial muscle dysfunction and refer me for orofacial muscle therapy sooner?
- ▶ This is the third time my orthognathic surgical result has relapsed. Why hasn't anyone referred me to an orofacial myofunctional therapist?
- ▶ My child was traumatized by wearing a "rake" in his mouth to stop his tongue thrust. His speech has gotten worse and he has withdrawn. After the rake was removed, the tongue thrust returned. Why wasn't I given the option of seeing a therapist who specialized in treating this disorder with exercises?
- ▶ My child wore a palatal expander for a high narrow palate. After the expander was removed, the palate collapsed because the tongue was resting down. Why wasn't I referred to an orofacial myofunctional therapist immediately following the expander being removed?
- ▶ I was told I was tongue-tied and needed a lingual frenectomy. After surgery, my tongue reattached and scar tissue formed and was worse than before we started! Why wasn't

I told to see a therapist immediately following surgery to prevent re-attachment?

Patients can learn to develop healthy muscle patterns. Healthy muscle patterns, when permanently habituated, can be proactive in preventing or treating:

- ▶ orthodontic relapses,
- ▶ articulation disorders,
- ▶ breathing disorders due to allergies or mouth breathing habits,
- ▶ TMD when it is a muscle or habit-related issue,
- ▶ digestive disorders from not chewing properly or swallowing air,
- ▶ postural problems,
- ▶ faster normalization of the facial muscles and neuro-muscular facilitation post orthognathic surgery.

See Complete care, Page 4



Fig. 1a Fig. 1b Fig. 1c
Figs. 1a-c: Before therapy. Patient presented with a lateral tongue thrust, mouth breathing, stomach sleeping, orthodontic relapse, difficulty chewing and swallowing, and forward head posture.

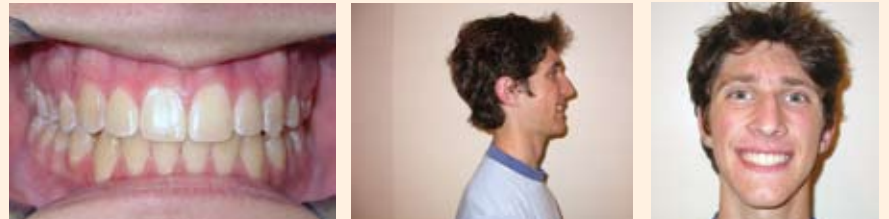


Fig. 1d Fig. 1e Fig. 1f
Figs. 1d-f: After 14 months of myofunctional therapy.

AD

"Oral Sedation Dentistry"

A 3-DAY COURSE

Fourteen safe and proven protocols, hands-on training, 20 patient experiences, and interactive lectures to equip you with the confidence and ability to effectively incorporate sedation into your practice.

75% of US adults experience some degree of dental fear^{1,2,3}

31% of baby boomers never go to the dentist (or only go in an emergency)⁴

15% of the population declines necessary dental treatment, because they fear oral injections⁵

TREAT MORE PATIENTS



Relaxed Patients. Better Care. More Profit.


Call (877) 325-3627 or visit DOCSeducation.org

Upcoming Courses

Los Angeles | Feb 20-22, 2009

Seattle | June 5-7, 2009

San Francisco | Nov 5-7, 2009



CA Permit Qualifying Program (25 CE hours)

REGISTER TODAY

Doctor Tuition: \$2195*
Team Tuition: \$738

*Ask how you can save 10% by becoming a DOCS member

¹ Harkavy, J., Kleinknecht, R.A., McGlynn, F.D., & Thorndike, R.M. (1984). Factor analysis of the dental fear survey with cross-validation. *J Am Dent Assoc.* 108 (1): 59-61.
² Getka, E., Glass, C.R. (1992). Behavioral and cognitive-behavioral approaches to the reduction of dental anxiety. *Behavior Therapy.* 23 (3): 443-448.
³ Getz, T., Milgrom, P., Weinstein, P. (1995). *Treating fearful dental patients: A patient management handbook.* University of Washington.
⁴ Academy of General Dentistry. (2007). National survey reveals baby boomers miss links between oral and overall health. Retrieved May 30, 2008, from: <http://www.agd.org/support/articles/?ArtID=1287>
⁵ Hamilton, J.G. (1995). Needle phobia: A neglected diagnosis. *Journal of Family Practice.* 41: 169-175.

AD-1087

Complete care

From Page 3

How can orofacial myofunctional therapy help the general dentist?

Orofacial myologists can assist the dentist in many aspects of his or her practice to:

- ▶ Re-educate muscle patterns that promote a stable orthodontic result.
- ▶ Reduce the time spent in fixed appliances.
- ▶ Normalize the inter-dental arch vertical rest posture dimension, the freeway space, also called the oral volume.
- ▶ Identify and eliminate orofacial noxious habits that interfere with stable occlusal results.
- ▶ Teach nasal breathing and remodel the airway through nasal cleansing and behavior modification.
- ▶ Reinforce compliance with wearing rubber bands, functional appliances and retainers.
- ▶ Develop a healthy muscle matrix and eliminate habits that contribute to TMD.
- ▶ Correct head and neck posture problems.
- ▶ Stabilize the periodontal condition by reducing tongue thrusting pressures and mouth breathing habits.

Because most of our patients are in need of orthodontic treatment or treatment by a functional dentist, if the patient was referred by a source outside of dentistry, we are certainly a great potential referral source for dentists.

The best time for the dentist to

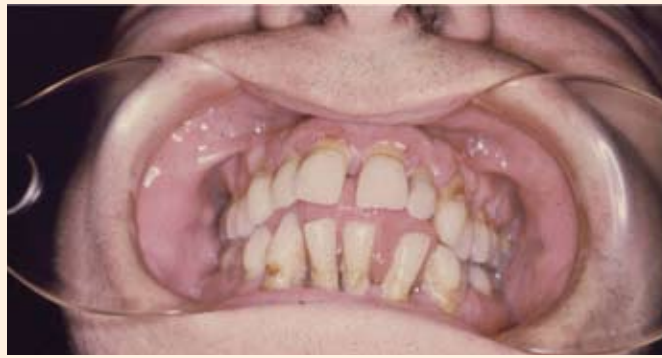

Fig. 2: Periodontal disease or orofacial myofunctional disorder?

refer the patient to an orofacial myofunctional therapist is before intervention by appliance therapy. It is always best to do the least invasive treatment first and eliminate habits that are interfering with treatment. This will ensure that the muscles are working with the forces of the appliances. Also, another good time to refer would be before the braces come off, depending on the patient's facial structure and motivation. We can work together to help the motivated patient achieve amazing results.

To elaborate on the importance of the working relationship between OMTs and the dental community, I have reached out to some of my esteemed colleagues for commentary.

According to Dr. John Kishibay, an orthodontist from Santa Monica, Calif., who is a professor at USC School of Dentistry: "Orofacial myofunctional therapy must be part of the treatment plan from the beginning. This way the patient understands from day one that the muscle adaptation is important for long-term stability. Especially important would be the orthognathic patient. The patient must learn to use the new space in an ergonomic manner,

in both a functional patterning and habit elimination awareness."

Dr. William Hang, an orthodontist practicing in Westlake Village, Calif., believes that OMT problems are one cause of poor facial development. He says: "Stability will continue to be an elusive, unachievable goal with poor facial balance frequently being the norm of the post orthodontic result. Myofunctional therapy must become the first line of defense in the quest for proper facial development rather than the rescue squad when the orthodontic result is going up in flames. When orthodontists embrace myofunctional therapy, they stop treating symptoms and begin to focus on treating the cause of poor facial development [altered oral rest posture]."

Dr. Jerry Zimring, a practicing orthodontist for 44 years in Los Angeles, believes that attaining proper occlusion is a state of balance between the teeth, the muscles and the bones. He states, "Both my daughter and my grandson were treated with myofunctional therapy with excellent results that would not have been possible without this valuable treatment. I feel strongly that myofunctional therapy should be part of every orthodontic practice."

Dr. Richard L. Jacobson, a Diplomate of the American Board of Orthodontics who has been in the exclusive practice of orthodontics in Pacific Palisades, Calif., for the past 28 years, stated: "We know that form follows function and function can follow form. Therefore, it is vital to identify those patients that need myofunctional therapy. In these patients myofunctional therapy by a

specialist is essential. Treatment is effective and orthodontic stability is enhanced."

The author would like to thank Karen Macedonio, a Certified Life Coach (and patient), Barbara J. Greene, COM, and Licia Coceani-Paskay, MS, CCC-SLP, COM, for their assistance with writing this article. A complete list of references is available from the publisher.

To find a therapist near you, go to www.iaom.com and look at the directory.

Contact info



Joy Moeller, BS, RDH, COM, is a certified orofacial myofunctional therapist and a licensed registered dental hygienist. She is in the exclusive private practice of OMT in Pacific Palisades and Beverly Hills, Calif. She is currently an elected member of the Board of Directors of the IAOM and is the hygiene liaison. Joy is also a former associate professor at Indiana University School of Dentistry and an on-going guest lecturer at USC and UCLA to ortho, perio and pedo dental residents, and at Cerritos College to hygiene students.

15340 Albright St., #305
Pacific Palisades, Calif. 90272
Tel.: (310) 454-4044
Fax: (310) 454-0391
E-mail: joyleamoeller@aol.com
Web site: www.myofunctional-therapy.com

Study OMT!

Joy Moeller will teach a five-day IAOM-approved course on orofacial myofunctional therapy Oct. 19-23 and a seven-day course (which includes two days of internship) on Feb. 11-17 and June 24-30, 2009 in Los Angeles with Barbara J. Greene, COM, and Licia Coceani-Paskay, MS, CCC-SLP, COM. For more information contact Greene at bgreene@tonguethrust.com or call (805) 985-6779.

AD

DENTALBANC. THE GOLD STANDARD IN PAYMENT MANAGEMENT

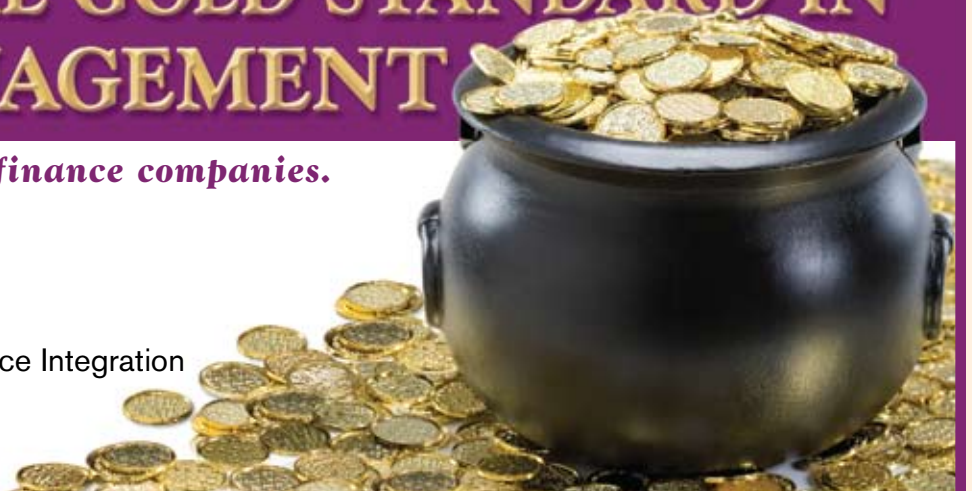Stop losing 10% or more to 3rd party finance companies.

- Credit Analysis with Recommendation
- ACH Draft and Credit Card Payment Option
- Complete Management of Your Accounts
- Credit Bureau Reporting and Collection Service Integration

DentalBanc

PROFESSIONAL PAYMENT MANAGEMENT

Why would you do it any other way? Call 888-758-0584 or visit www.dentalbanc.com to learn more.



CEREC 3-D CAD/CAM: The power of technology in clinical restorative dentistry



Join your colleagues for Dr. Antenucci's lecture at the Dental Tribune Symposia during the Greater N.Y. Dental Meeting at 10 a.m.-1 p.m. on Nov. 30.

CAD/CAM technology has revolutionized the practice of dentistry with enormous implications for the delivery of patient care that is timely, comfortable, long lasting, beautiful and economical. This presenta-

tion is designed to provide not only an overview of the role of CAD/CAM and CEREC 3-D in clinical dentistry today, but also provide attendees with practical clinical information on how CEREC 3-D literally transforms the practice of restorative dentistry. Numerous clinical cases will be provided along with a thorough discussion of case selection, fabrication and design, delivery and finish. Attendees will leave with a thorough understanding of the clinical application and use of CEREC 3D CAD CAM technology in achieving outstanding results.

Earn C.E. credits! Attendance is free for all GNYDM visitors!

For more information and registration, please contact Julia Wehkamp: j.wehkamp@dtamerica.com.

Successful treatment strategies for anterior total tooth replacement in the thin scalloped periodontal architecture: the ankylos tissue care concept for long-term success

Catch Dr. DiGiallorenzo's lecture at the Dental Tribune Symposia during the Greater N.Y. Dental Meeting at 1:30-2:30 p.m. on Dec. 1.



This lecture will provide a systemic, biologic and evidence-based approach to ensure success in the class 1 to class 4 case utilizing the

"Tissue Care Concept by Ankylos," PRGF, lasers and piezo surgery. Learn about:

- ▶ Diagnosis of patient biotypes and its affect on treatment decisions.
- ▶ Immediate or staged?
- ▶ Surgical management: incisions, atraumatic extraction, periodontal plastics, bone grafting (PRGF), over-correction, site preparation, and 3-D implant placement.
- ▶ Prosthetic management: abutment selection, provisionalization, restorative materials and methods.

Earn C.E. credits! Attendance is free for all GNYDM visitors!

For more information and registration, please contact Julia Wehkamp: j.wehkamp@dtamerica.com

AD

Endodontic irrigation via EndoVac: safety, efficacy and clinical techniques



Don't miss Dr. Schoeffel's lecture at the Dental Tribune Symposia during the Greater N.Y. Dental Meeting at 1:30-2:30 p.m. on Nov. 30.

Although seemingly simple, endodontic irrigation is a highly complex problem that begins with patient safety and ends with clinically efficient and effective results. However, as complex as the problem is, the answer is equally simple. Attendees will learn the answer, while becoming familiar with:

- ▶ Identifying flaws in current endodontic irrigation studies.
- ▶ Listing the principles and ancillary benefits of apical negative pressure.
- ▶ Describing the critical importance of safely using full-strength sodium hypochlorite during endodontic irrigation.

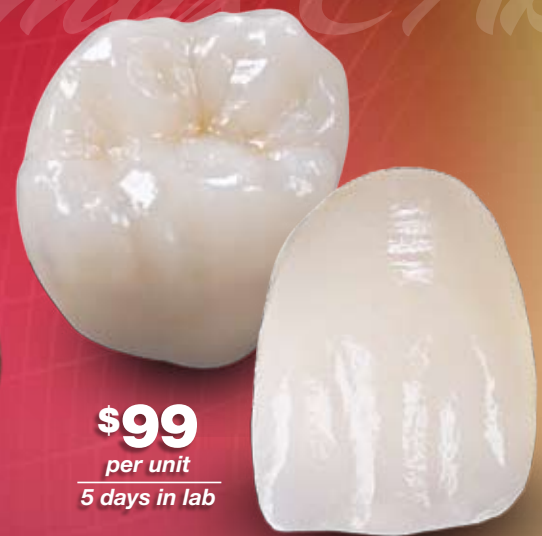Earn C.E. credits! Attendance is free for all GNYDM visitors!

For more information and registration, please contact Julia Wehkamp: j.wehkamp@dtamerica.com.



Cementable all-ceramics that beautifully match natural teeth!

IPS e.max® CAD



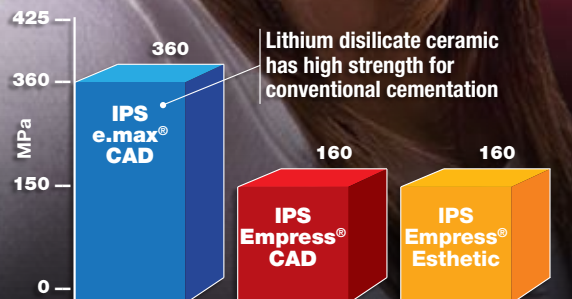
\$99
per unit
5 days in lab

CEREC® & Cadent iTero™ doctors who e-mail digital data save \$7 inbound shipping

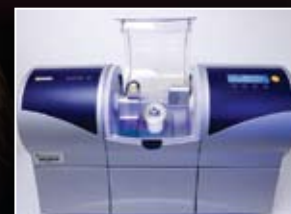- Conventional or adhesive cementation
- Virtually perfect contacts and occlusion
- IPS Empress®-like esthetics
- Indicated for single-unit crowns

"Of all the restorations available in our laboratory, my favorite crown is IPS e.max CAD because of its precise fit and its uncanny ability to blend in with natural dentition. Cementable all-ceramic crowns have never looked so good or fit so well."

-Dr. Michael C. DiTolla
Director, Clinical Education & Research



Lithium disilicate ceramic has high strength for conventional cementation



Milled with the NEW Sirona inLab® MC XL and Enhanced CEREC® 3D Software

888-786-2177
www.glidewell-lab.com

IPS e.max and IPS Empress are registered trademarks of Ivoclar Vivadent. CEREC and inLab are registered trademarks of Sirona Dental Systems, Inc. Cadent iTero is a trademark of The Cadent Company.



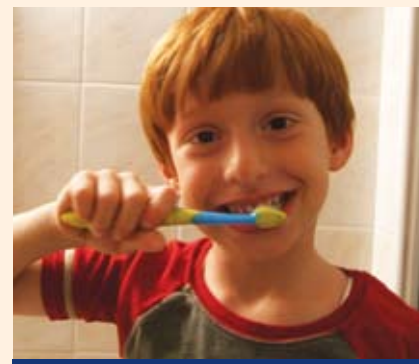Greater New York Dental Meeting helps to educate New York City's children

As the largest and most highly attended annual dental meeting and exhibition in the United States, the Greater New York Dental Meeting is constantly adding to its already impressive array of educational programs. This year the meeting's organizers will unveil a program focused on children's oral hygiene — The Children's Dental Health Initiative Program — which was made possible by their joining efforts with the United Federation of Teachers and Doral Dental USA.

Children from all five New York City boroughs will travel from their local schools in order to convene on the Greater New York Dental Meeting's exhibition area in the Jacob K. Javits Convention Center. There they will receive oral hygiene instruction in a fun child-friendly atmosphere. The entertaining program will emphasize the importance of oral care in a way that children can understand, and showcase step-by-step tooth care utilizing proper brushing techniques. At the end of

the program, children will have the opportunity to practice their newly learned oral hygiene skills at sinks located in the area and under the supervision of program volunteers.

Hygiene students from the New York University College of Dentistry Dental Hygiene Program, the New York City College of Technology Department of Dental Hygiene, volunteers from the Dental Hygienists' Association of the City of New York, and the New Jersey Dental Hygienists' Association have generously



A child practices proper brushing technique.

offered to volunteer their time and skills to be a part of this unique new program.

Children will leave with a toothbrush, toothpaste and lots of new information on how to properly care for their teeth. To maximize attendance, the program will run for three school days — Monday, Tuesday and Wednesday. Executive Director of the Greater New York Dental Meeting Dr. Robert Edwab said, "We are very excited about being able to help children learn proper oral health care in a fun atmosphere."

According to the Centers for Disease Control and Prevention's Division of Oral Health, tooth decay is one of the most common chronic infectious diseases among U.S. children. This preventable health problem begins early: 28 percent of children aged 2–5 have already had decay in their primary teeth. By the age of 11, approximately half of children have experienced decay, and by the age of 19, tooth decay in the permanent teeth affects two-thirds of adolescents.

Low-income children have twice as much untreated decay as children in families with higher incomes. Decay may result in pain, dysfunction, underweight, and poor appearance — problems that can greatly reduce a child's capacity to succeed in the educational environment. However, all these problems can be avoided by instructing children on proper brushing and flossing techniques and stressing how imperative it is they take care of their teeth and gums. "We must teach our children the importance of oral health early in their childhood," said General Chairman of the Greater New York Dental Meeting Dr. Clifford Salm.

Bring your entire staff and your family because New York City has something for everyone during the spectacular holiday season. There is no other city where attendees can socialize with colleagues, reap the benefits of an outstanding dental congress that features some of the most highly regarded educators in dentistry, and enjoy the eclectic and abundant mix of attractions that only the "Big Apple" has to offer. And remember, there is never a pre-registration fee at the meeting.

For additional information, please contact the Greater New York Dental Meeting at: 570 Seventh Ave., Suite 800, New York, N.Y., 10018-1806; Tel. (212) 398-6922; Fax (212) 398-6954; Web site www.gnydm.com; e-mail info@gnydm.com.

AD

The Whole Enchilada

With plenty of side dishes available



The whole kit and caboodle. Everything, and all of it. That describes PhotoMed. We've got everything you need for clinical photography. PhotoMed clinical camera systems feature the best digital camera equipment available. The system shown above is Nikon's D300 with the Micro-Nikkor 105mm VR macro lens and Nikon R1 Macro Flash. We complete the system with the new PhotoMed R1 Dual Point Flash Bracket that gives you incredible flash position flexibility. We also feature clinical systems built around Nikon's D60, D80 and D90.

We know that no one likes to spend time reading thick user manuals so your camera is delivered assembled, set and tested along with our concise custom instructions. And we include unlimited phone support and loan equipment if needed.

PhotoMed carries all of the accessories you may need: intraoral mirrors, retractors, Contrasters, printers, clinical photography books/training CDs and recreational lenses (the Nikkor 18-200 AF-S DX VR lens is a nice choice). Visit our website. Give us a call. Come see us at a dental meeting (there's a complete list of upcoming meetings at: www.photomed.net). We know you'll like us.



www.photomed.net • 800.998.7765

Mention the "enchilada ad" when you order for a complimentary side dish!

PhotoMed
INTERNATIONAL

Webinar schedule

Cone Beams: a new dimension of dentistry by Dr. Daniel McEowen

7 p.m. EST on Oct. 21 — Free

PreXion 5-D Dental Scanners are addressing the rapid shift in dentistry from analog-based 2-D film radiography to digital 2-D and 3-D volumetric rendering. This Webinar will introduce attendees to cone beam technology in general and make comparisons between all current available CBCT units. It will include a live scan, from scanning to processing, until images are available to work with. The objective is to learn to use the PreXion 5-D for general dentistry, endodontics, implantology, oral surgery, oral-maxillofacial surgery and periodontics, and show the ease of use of this unit.

Register at www.dtiinstitute.com/webinar/cone-beam

Be THE exceptional practice!, by Dr. Ron Schefdore

7 p.m. EST on Oct. 30 — \$95 fee



Learn how to improve patients' oral and overall health; grow a quality practice; why, when and how to screen periodontal patients for diabetes; obtain a professional blood lab report to use as a cross referral tool with physicians; remove the liability of blood screening from your office; treat periodontal disease from a bacterial, nutritional and underlying medical point of view for long-term periodontal health, overall wellness, and increased profits; establish the ideal practice.

Register at www.dtiinstitute.com/webinar/diabetes



Increase net revenue, foster employee confidence: the five keys to effective employment relations for the dental office,

by Juris Doctor Michael Garth Moore

7 p.m. EST on Nov. 11 — \$95 fee

Gain familiarity with legal concepts underlying employee claims; learn the processes and practices that reduce turnover of good employees; learn how to reduce anxiety in dealing with employee relations issues; learn the documentation that reduces the risk of unemployment compensation and wrongful termination claims.

Register at www.dtiinstitute.com/webinar/HR

AD

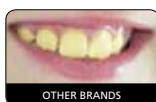Best Taste... Guaranteed!

Guess whose dentist didn't use new ClearShield fluoride varnish?

Goes on clear. . . clearly tastes better!

New Kolorz ClearShield 5% Sodium Fluoride Varnish goes on clear, with no embarrassing yellow discoloration. And its great watermelon flavor, developed by gourmet food-industry professionals, makes treatment a picnic for kids!

- Guaranteed to taste better than any other fluoride varnish, or your money back!
- Sealed single dose package includes easy-to-use applicator and mixing well
- Excellent consistency ensures complete coverage
- Maximum fluoride formula
- No Saccharine or Aspartame, only natural sweeteners
- Contains Xylitol
- Gluten free



No ugly, yellow teeth with ClearShield!



- ClearShield™ Fluoride Varnish
- Prophylaxis Paste
- Topical Anesthetic Gel
- Sixty Second Fluoride Foam and Gel
- Neutral Fluoride Foam



Get a FREE sample package of ClearShield!

To order, go to www.zenithdental.com/clearshield, call 1-800-662-6383, or complete coupon and mail or fax.

Name _____
 Address _____
 City _____ State _____ Zip _____
 Phone _____ Fax _____
 Email _____

All fields must be completed to receive free product. ZenithDental

Mail coupon to Kolorz ClearShield Offer, 242 South Dean Street, Englewood, NJ 07631, or fax to 201.894.0213. Offer ends 12/31/08. Offer limited to 3 per dental office. Offer code: DTRIBCS

Tell us what you think!

Do you have general comments or criticism you would like to share? Is there a particular topic you would like to see more articles about? Let us know by calling (800) 480-6977 or e-mailing us at feedback@dtamerica.com. If you would like to make any change to your subscription (name, address or to opt out) please send us an e-mail at database@dtamerica.com and be sure to include which publication you are referring to. Also, please note that subscription changes can take up to 6 weeks to process.

Please visit us at the ADA Annual Session, Booth #535.

SedationCare.com: increasing sedation dentistry consumer awareness

By Heather Victor

"I have not been to the dentist in about 10 years. I don't like anything about visiting the dentist. I have always gagged during X-rays, and the tooth polishing, drilling and scraping makes my skin crawl. The water is too cold for my teeth. I have always had nice teeth, but now they are discolored and I know I have some cavities. I need to step up and be a better role model for my three girls and go back to the dentist. I would love to give you a try and see if you can help me relax through this unpleasant process. Please help me."

The message above is just one of hundreds of e-mails oral sedation dentists receive every day from anx-

ious and fearful patients through the consumer-based educational Web site *SedationCare.com*. Research has shown that up to 75 percent of adults in the United States experience some degree of dental fear. So it's no surprise that many people are searching for better alternatives to help cope with the anxiety of receiving dental treatment.

Oral sedation dentistry, a safe and effective alternative to IV sedation, has helped over one million patients throughout North America conquer their dental fears. This ever-growing number is due largely in part to two things: an increased number of dentists offering the treatment and better consumer education.

Ranked No. 1 on most search

engines, *SedationCare.com* not only educates patients about the benefits of oral sedation dentistry it also allows them to search for expertly trained sedation dentists in their area. In fact, 149,454 searches for sedation dentists were performed on the site during last year alone — and that number continues to rise each month.

The site provides in-depth detail on how sedation dentistry works, including each step of the treatment process, the medications used, what to expect during and after sedation, the feelings experienced while under sedation, important topics to discuss with the dentist and which patients are good candidates for oral sedation. People can also read patient testimonials — a reassuring tool that helps

normalize dental fear and lets people know that they are not alone.

For many people seeking care, trying to find a reliable and qualified dentist is equally, if not more stressful, than the dental treatment itself. People want to know that the practitioner they see is properly trained, compassionate and experienced in providing the type of care they need. This makes *SedationCare.com's* tool for locating local qualified oral sedation dentistry practitioners even more valuable. People can find and directly contact any of the dentists listed on the site — and each is a member of DOCS Education, dentistry's leading provider of oral sedation and emergency preparedness continuing education.

Potential patients can rest assured that when they visit *SedationCare.com* they are receiving accurate, up-to-date, valuable information on oral sedation dentistry with the added benefit of finding a qualified provider in their area.

To learn more about oral sedation dentistry and find out how you can be listed as a provider on SedationCare.com, visit DOCSeducation.org or call (877) 325-3627.

AD

MonoCem®

SELF-ADHESIVE RESIN CEMENT

Still the Easiest – Proven Performance

self-adhesive

auto-mix

high retention values

self-etch

dual cure

moisture tolerant



Simplicity always stands out.

**Buy one 7g MonoCem®
Single Syringe Kit* &
get a 3.5g of
MonoCem® FREE!**





SHOFU DENTAL CORPORATION
Call for Information 800 827 4638 www.shofu.com
SAN MARCOS CALIFORNIA

*MonoCem® Translucent Single Kit (PN3208A)
MonoCem® Bleach White Single Kit (PN3209A)
Limited time offer while supplies last.
SNMONO-02-1107

New cameras from Canon and Nikon



The newest cameras to enter our line of clinical systems are the Canon Rebel XS and the Nikon D60. These two cameras represent the least expensive models from each manufacturer.

The new Rebel XS can be thought of as the Rebel XSi's little brother. The camera dimensions and weights are almost identical. The main differences are the LCD screen (2.5-inch vs. 3.0-inch) and resolution (10MP vs. 12MP). If you don't mind a slightly smaller screen, you can save a few bucks and still get great photos.

We first talked about the Nikon D60 in our April newsletter and at that time the camera was only available in "kit" form (with the 18–55 mm zoom lens). Nikon is now shipping the D60 as a body only.

PhotoMed International
14141 Covello St., #7C
Van Nuys, Calif. 91405
E-mail: info@photomed.net
Tel.: (800) 998-7765
www.photomed.net

The importance of gingival health in a functional cosmetic case

By Martha Cortes

Complete dentistry is the esthetic and occlusal harmonization of the teeth with the gingiva, lips and face. As dentists, we can directly affect the esthetics of the teeth and gingiva. However, we can also indirectly affect the lips and face by how we design teeth to sit in the oral cavity.

It is paramount in an esthetic case to have healthy gum tissue that enhances the beauty of a full smile makeover. The best, quickest, healthiest and most profitable way of treating gum disease is by laser therapy.

Laser Assisted New Attachment Procedure™ (LANAP) is the standard of care for periodontal laser therapy and beyond that of conventional treatment, which amputates, leading to results that can be less than desirable. LANAP is a patented soft-tissue technique specifically utilizing the Periolase® MVP-7 Nd:YAG (1064 nm wavelength) laser (Millennium Dental Technologies, Inc.) with the aim of regeneration rather than traditional resection of the gum tissue, which is done solely for pocket maintenance.

The patient, a woman in her early 60s, came to my office because she was having problems with a bridge (lower left) that had recently been replaced; she was unable to chew well. During the discussion she revealed that she was also having problems on the lower right, indicating that the problem was not local but one that involved the bite.

On further examination, it was revealed that she not only had occlusal problems, but she also had moderate periodontitis throughout with bone loss especially impacting the lower anteriors. The patient had worn away her teeth and, as a result, suffered from severe malocclusion.

She had large diastemas between the upper and lower centrals with little occlusal guidance. Her temporal mandibular joints demonstrated hypermobility while opening and closing. The patient also had ill-fitting porcelain fused to metal crowns on teeth #3-5 and #31, #30, #12, #21 with metal exposure and a new zirconium bridge with flat occlusion on teeth #18-20. All prosthesis had poor color matching and flat occlusion.

The periodontitis and bone loss were partially due to a traumatic bite that improperly distributed the occlusal forces laterally rather than

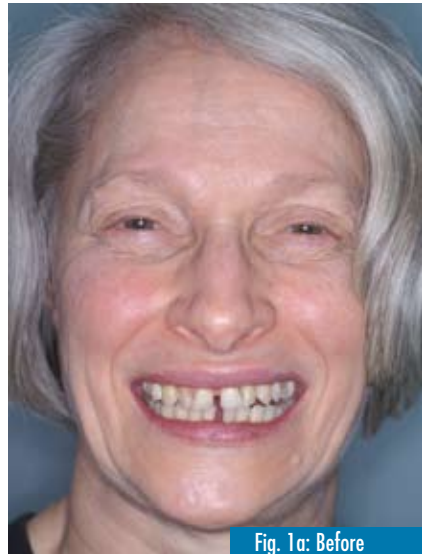

Fig. 1a: Before

perpendicularly so that the loading forces were forcing the lower anteriors to splay.

In order to inhibit the mechanical progression of the periodontitis and bone loss, and prevent the teeth from splaying further, it was decided to completely restore the teeth to a fully functional platform. The patient was at first intimidated by the idea of a complete smile makeover, and yet she was at the same time ready for this life-changing event. The patient understood that the esthetics would be built functionally so that the occlusion, teeth, arches and periodontium would support each other and thereby help keep the entire oral cavity healthy.

Having a functionally beautiful smile not only affects a patient's self-esteem, it also has an effect on the health of the head, neck and body as the patient tends to have better posture and better body integration, because aligned jaws might proprioceptively affect the body in space. Although the patient's main concern was dental health, the added benefit of a gorgeous esthetics appealed to her greatly.

Due to her severe malocclusion, the patient's habitual centric bite could not be used as the guide for her smile-makeover. The proper functional height for the patient's teeth needed to be found and established. The patient had ground down her posterior teeth and much of the forces of mastication were pathologically loading on the lower anteriors, causing them to splay and repetitively injuring the gingiva.

LANAP's uniqueness allows for the prepping and placing of restorations without having to wait an

See The importance, Page 2

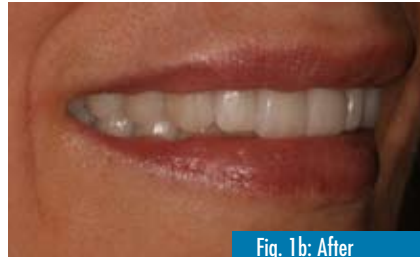

Fig. 1b: After

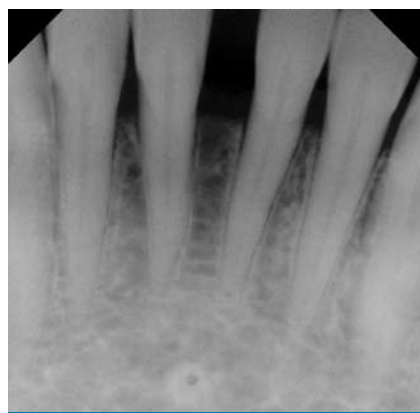


Fig. 2: Before LANAP (note the bone loss) [July 25, 2005].

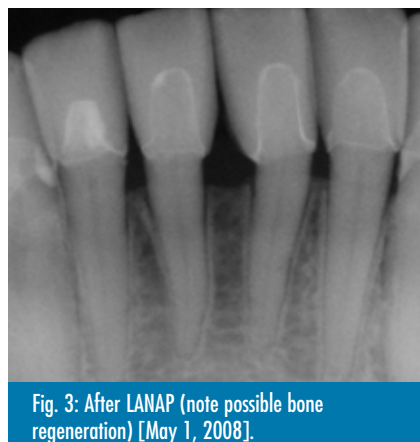


Fig. 3: After LANAP (note possible bone regeneration) [May 1, 2008].

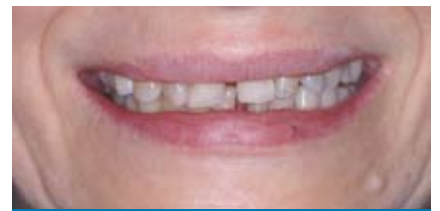

Fig. 4: Maloccluded smile with multiple diastemas.

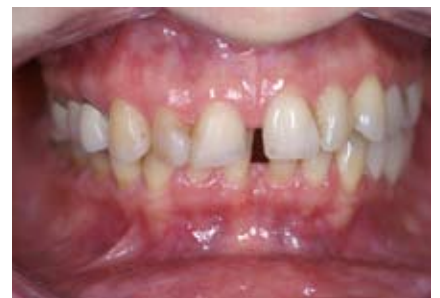

Fig. 5: Pre-op intraoral view: note the severe over-bite and canted maxilla.

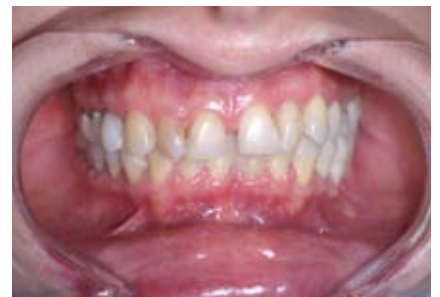

Fig. 6: Phase 1 with lower orthotic.

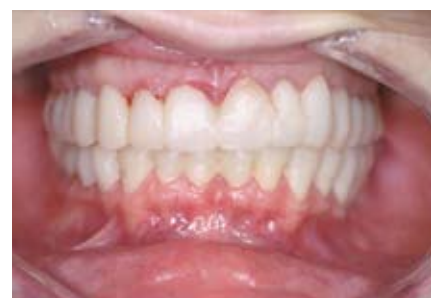

Fig. 7: Phase 2 with lower orthotic and provisionals on the uppers.

AD

R-SI-LINE® METAL-BITE™
Universal and scanable registration material, that's it!

- high viscosity • high final hardness • Shore-A 94
- setting time about 60 s • scanable for powderless 3D-data registration of antagonists (CAD/CAM)

Available at:
PATTERSON DENTAL
www.pattersondental.com

R-dental Dentalerzeugnisse GmbH
E-mail: info@r-dental.com, r-dental.com

BIB zur Perfektion