

DENTAL TRIBUNE

The World's Dental Newspaper • Pakistan Edition

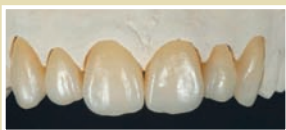

PUBLISHED IN PAKISTAN

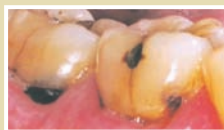www.dental-tribune.com.pk

JANUARY, 2017 - Issue No. 01 Vol.4

Cementation of zirconia

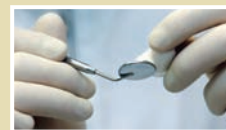

CLINICAL DENTAL LAB ▶ Page 4



Anesthesia-free and drill-free deep decay removal

CLINICAL PRACTICE ▶ Page 6



Infection control in an era of emerging infectious diseases

DENTAL HYGIENE ▶ Page 7



National Health Programme to go Nationwide: PM

DT Pakistan Report

ISLAMABAD - Prime Minister Nawaz Sharif announced extension of the National Health Programme to the entire country. Under the directives of the prime minister, the programme will now have a countrywide outreach, offering free-of-cost treatment to the poorest. □

The PM while presiding over the meeting at the PM house said that access to quality healthcare services is the inherent right of all Pakistanis, which was unfortunately denied to them for long. It is only through provision of quality and affordable health services that a nation can achieve its full potential and gains on the economic and social fronts. The government is committed to reach out to the poorest of the poor with a comprehensive package of curative health services □

The NHP was launched by the prime minister in Dec 31, 2015, for Islamabad and described it as the

first step towards making the country a welfare state. The scheme was to be extended to all parts of Punjab, Balochistan, Azad Jammu and Kashmir, Gilgit-Baltistan and the Federally Administered Tribal Areas (Fata) as the governments of Sindh and Khyber Pakhtunkhwa had declined to become part of the scheme in which they also had to contribute their share. □

The KP government has also launched its own programme which at present is confined to a few districts of the province. □

Under the federal government programme, a family gets Rs50,000 for secondary care treatment which begins as soon as a patient is hospitalized, covering all kinds of diseases. □

Each family can get a treatment of Rs250,000 under the category of priority diseases which includes cancer,

Continued on page 15

Number of Pak doctors in US growing

DT Pakistan Report

ISLAMABAD - The number of Pakistani doctors in the US is increasing, this was stated by the President of Federation of State Medical Boards of United States during his recent visit. Pakistan will become the 3rd biggest country to provide doctors who fulfil the space of international doctors in the USA. □

During the recent visit of Dr Humayun J Chaudhry, President and Chief Executive Officer (CEO) to Pakistan Medical & Dental Council (PM&DC) where a detailed presentation regarding functioning and licensure and CME was given

to him. □

PM&DC also arranged visits for the delegate in public, private and military medical dental college's i.e. Army Medical College, Rawalpindi Medical College, CMH, and Holy Family Hospital to brief the medical and dental educational system of Pakistan. Dr Humayun said that till to date, 12000 Pakistani national physicians and specialists doctors are working in 56 different states of USA. □

He also added that Pakistan is the 4th biggest country to provide doctors in USA and it is getting more advancement in the field of medicine and system of medical

dental education and its standard is at par with the western countries. □

He said out of 12000 doctors, 3100 doctors are graduated from Dow University of Health Sciences, 1900 from King Edward Medical College then from Agha Khan University and also Allama Iqbal Medical College Lahore. □

He apprised that the Pakistani national doctors in USA are having a very good repute and are considered the best doctors. He congratulated PM&DC being a responsible monitoring body and to maintain good standard of education in Pakistani medical and dental colleges.

PPMA denies Pharma companies' nexus with DRAP

DT Pakistan Report

KARACHI - The Pakistan Pharmaceutical Manufacturers' Association (PPMA) strongly denied the impression created by what it called elements having vested interests that the Drug Regulatory Authority of Pakistan (DRAP) has been working for the interests of Pharma companies saying that factual position to this day is quite opposite to this utterly false notion. □

Spokesman for PPMA issued the statement to this effect, in reference to the news story carried by a daily English newspaper on 26 January, 2017 titled "Drap accused of working for Pharmaceutical companies' interests". □

He said it had always been the stated position of the PPMA. DRAP has its own mandate regulate health sector including pharmaceutical Medical devices & Alternate medicine. PPMA has its own point of to

Continued on page 15

PDA takes on SRB Issue

DT Pakistan Report

KARACHI - PDA central council President along with Dr Mervyn Hosein and Dr Fehmed Patel visited the chief secretary to resolve the Sindh Revenue Board issue of implementing sales tax on some of the dental specialties. □

The PDA president informed the chief secretary and the relevant staff of SRB that the said SRB notification is unjustified since most of the work which SRB has classified under Cosmetic dentistry and orthodontics is due to deformities and not exactly for cosmetic reasons. For instance Cleft lip comes under cosmetic surgery but is a deformity which needs to be corrected.

Similarly malocclusion is a medical condition and requires treatment so it has to be differentiated from plastic surgery or beauty enhancement procedures. He urged the authorities that dental services do not come under Cosmetic and Plastic surgery. As such we are excluded providing or rendering aforesaid services as defined in the Sindh Sales Tax on services Act 2011.

Researchers to investigate oral bacterium as possible cause of infective endocarditis

DT International

BUFFALO, N.Y., USA: At the end of last year, researchers at the University at Buffalo School of Dental Medicine announced that they had received a \$239,000 grant from the National Institute of Dental and Craniofacial Research to study the mechanisms of *Streptococcus gordonii*. The bacterium is a normal part of the oral microbiome. It is, however, suspected of causing blood clots and triggering life-threatening endocarditis once it has entered the bloodstream through bleeding gingivae. □

The research will be carried out by a laboratory team led by Dr. Jason Kay, an assistant professor in the Department of Oral Biology, who specializes in the study of phagocytes that have the ability to ingest, and

sometimes digest, foreign particles, such as bacteria. □

"Our white blood cells have a number of ways of destroying invading microbes, but somehow these bacteria manage to escape, sometimes



In a new study, researchers will study oral bacteria that may contribute to the development of infective heart disease.

surviving inside the cells meant to kill it. How this occurs is not understood," Kay said. "Once we understand how this survival occurs, the knowledge will allow us to develop treatments that prevent normally good bacteria

from going bad." □

Kay's team hypothesizes that *S. gordonii* survives inside the phagocytes by resisting the cell's kill mechanisms, partly owing to certain genetic predispositions. Therefore, the study will aim at identifying genes that may increase the bacteria's survival inside the white blood cells by turning off specific genes within the microbes and monitoring the interactions. □

In addition, the researchers will examine whether the phagocytes are modified or damaged during the killing process, and how the maturation process of white blood cells affects their ability

to destroy the bacteria. □

Understanding these interactions will help clinicians better prevent one of the causes of infective endocarditis and ultimately lead to new treatments for the disease.

Asian immigrants make low use of dental services

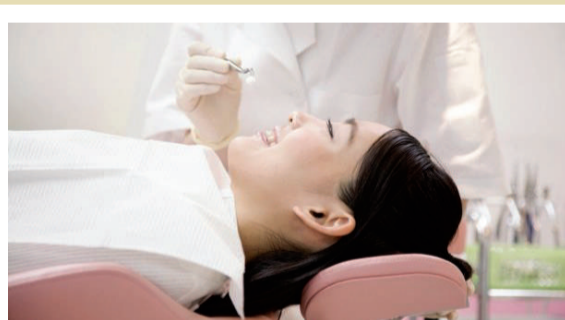DT International

NEW YORK, USA - In contrast to non-Hispanic whites, racial and ethnic minorities often face greater problems with regard to access and utilization of dental care services. A new study focusing on factors determining dental visiting patterns of Asians in the U.S. has shown that length of stay in the country is a significant factor affecting dental service utilization among this group. □

Although the Asian population is the second fastest-growing group in the U.S., little research on Asian immigrants and the various nationalities of this category has been done. In order to address this issue, the researchers evaluated health care data of 2,948 dentate adult Asian immigrants. They studied whether acculturation, measured by length of stay in the U.S., English language proficiency and U.S. citizenship, had affected their dental visiting patterns in the previous 12 months. □

They found that, overall, Asian immigrants, with the exception of Filipinos, made significantly low use of dental services. Despite cultural and attitude differences toward dental care within Asian subgroups, enabling factors like affordability, familiarity with health care system and oral health status had important effects on dental service utilization. The most prominent factor affecting utilization proved to be dental insurance coverage. □

English language proficiency, however, which is often considered the main barrier to health care services, was not a significant correlate of having a dental visit. However, length of stay in the U.S. (> 5 years) appeared to be the



Asian immigrants in the U.S. do not use dental services as often as non-Hispanic whites.

most significant factor among Asians. □

"We hypothesize that this could be because longer stays in the U.S. allow for immigrants to gain improved familiarity with health care system, increases health literacy, and social support networks," said Dr. Huabin Luo, assistant professor at the East Carolina University Department of Public Health, North Carolina, who led the study, together with Prof. Bei Wu from the New York University Rory Meyers College of Nursing.

The researchers concluded that health care professionals need to pay more attention to providing oral health education among newer immigrants and that interpreting services may be necessary. There is an apparent need for greater dental care promotion among these groups, especially in the beginning stages of their arrival, they said.

DENTAL TRIBUNE

The World's Dental Newspaper - Pakistan Edition

Publisher/CEO

Syed Hashim A. Hasan □
hashim@dental-tribune.com.pk

Editor Clinical Research:

Dr. Inayatullah Padhiar

Editors Research & Public Health

Prof. Dr. Ayyaz Ali Khan

Editor - Online

Haseeb Uddin

Designing & Layouting

Sh. M. Sadiq Ali

Dental Tribune Pakistan

3rd floor, Mahmood Centre, BC-11, Block-9
Clifton, Karachi, Pakistan.
Tel.: +92 21 35378440-2 | Fax: +92 21 35836940
www.dental-tribune.com.pk
info@dental-tribune.com.pk

Dental Tribune Pakistan cannot assume responsibility for the validity of product claims or for typographical errors. The publisher also does not assume responsibility for product names or statements made by advertisers. Opinions expressed by authors are their own and may not reflect of **Dental Tribune Pakistan**.

International Imprint

Group Editor □

Daniel Zimmermann

newsroom@dental-tribune.com □

Tel.: +44 161 112 1830

Clinical Editor □

Magda Wojtkiewicz

Online Editors/Social Media Manager □

Claudia Duschek

Editor □

Anne Faulmann

Editorial Assistant

Kristin Hübner

Copy Editors □

Sabrina Raaff

Hans Motschmann

Publisher/President/CEO □

Torsten Oemus

Chief Financial Officer

Dan Wunderlich

Chief Technology Officer

Serban Veres

Business Development Manager □

Claudia Salwiczek-Majonek

Jr. Manager Business Development

Sarah Schubert

Project Manager Online □

Tom Carvalho

Event Manager □

Lars Hoffmann

Education Manager □

Christiane Ferret

International PR & Project Manager □

Marc Chalupsky

Marketing & Sales Services

Nicole Andriä

Event Services □

Esther Wodarski

Accounting Services □

Karen Hamatschek

Anja Maywald

Manuela Hunger

Media Sales Managers □

Matthias Diessner (Key Accounts)

Melissa Brown (International) □

Antje Kahnt (International)

Peter Witteczek (Asia Pacific)

Weridiana Mageswki (Latin America)

Maria Kaiser (North America)

Hélène Carpentier (Europe)

Barbora Solarova (Eastern Europe)

Executive Producer □

Gernot Meyer

Advertising Disposition □

Marius Mezger

Dental Tribune International

Holbeinstr. 29, 04229 Leipzig, Germany

Tel.: +49 341 48 474 302 | Fax: +49 341 48 474 173

info@dental-tribune.com | www.dental-tribune.com

Regional Offices

□ **Asia Pacific**

Dental Tribune Asia Pacific Limited

Room A, 20/F, Harvard Commercial Building,

105-111 Thomson Road, Wanchai, Hong Kong

Tel.: +852 3113 6177 | Fax: +852 3113 6199

The Americas

Tribune America, LLC

116 West 23rd Street, Ste. 500, New York, N.Y.

10011, USA

Tel.: +1 212 244 7181 | Fax: +1 212 244 7185



RAPID ACTION & LONG LASTING PROTECTION

**CLINICALLY PROVEN SENSITIVITY RELIEF.
WORKS IN 60 SECONDS***



*when used as directed on pack

GSK is committed to the effective collection and management of human safety information relating to our products and we encourage healthcare professionals to report adverse events to us on +92 (21) 111-475-725 or pk_pharmasafety@gsk.com

Cementation of zirconia

By Jip Kreijns

MTen-methacryloyloxydecyl dihydrogen phosphate is a bit of a tongue-twister for anyone not a chemist by profession, so in everyday communication, this adhesive monomer is referred to by its three initial letters, MDP. The monomer was developed by Kuraray Noritake Dental in 1981 to improve the adhesive strength to hydroxyapatite and has proved its strength ever since. It is indispensable in dentistry. For example, reliable adhesive cementation of zirconia restorations would not be possible without MDP. □

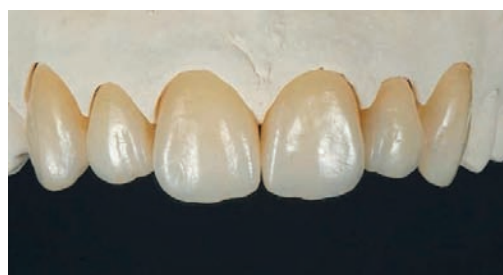Requirements for indirect restorations Indirect restorations in modern dentistry must fulfil at least three requirements. First of all, they must preserve tissue. This implies that a full crown is not the first choice, because approximately 70 per cent of the tooth tissue has to be sacrificed for such a restoration. Nevertheless, full crowns are often still indicated by virtue of their mechanical retention. However, given that the retention that can be achieved by adhesive cementation is now sufficiently reliable, a less invasive restoration than a crown should be chosen more often. And this choice may very well be for a zirconia restoration. Combined with the preliminary sandblasting of such an adhesive restoration, this choice is now an appropriate one, owing to MDP. □

Durability is the second requirement for an indirect restoration. This property of a restoration is largely associated with the flexural strength of the restorative material. While it has become clear that zirconia achieves the best durability scores, it should be pointed out that the cementation method also contributes significantly to the durability of a facing, inlay, onlay, adhesive bridge, etc., which can nowadays all be realised in zirconia. □

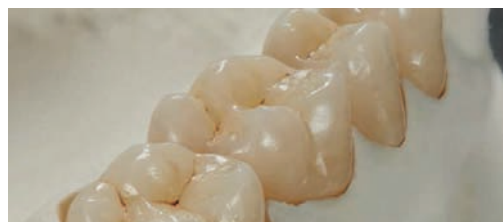Aesthetic acceptability is the third requirement for a modern indirect restoration. This means that porcelain baked on metal has become a thing of the past; all-ceramic materials are now the standard. Zirconia still has a relatively poor reputation in terms of aesthetics owing to the extreme whiteness of the earliest examples from the turn of the century. Zirconia is now available in varying translucencies, and there are even multilayer varieties (KATANA Zirconia ML, STML and UTML; all Kuraray Noritake), and these new zirconia materials no longer have to be porcelain-baked. Obviously, baking is still possible, and partial baking is a choice that is frequently made. One of the results of a multilayer build-up is that the transparency is higher incisally than cervically, as it is in natural dentition; the light falls through the incisal margin, but is blocked at the cingulum of the restoration. With a modern zirconia material such as KATANA Zirconia ML, this variable transparency goes hand in hand with a natural colour gradient from cervical to incisal. In a given colour, A1 for example, the cingulum has the corresponding dentine shade body and it passes to incisal in the appropriate enamel colour via two transition shades. □

Surface □

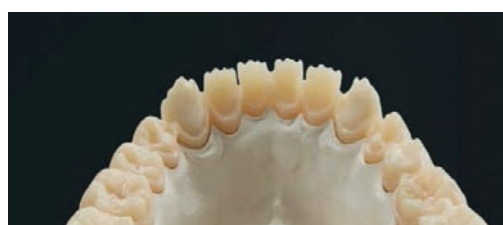
The new zirconia materials are changing the way dental technicians operate, as illustrated by the experience of Daniele Rondoni, a prominent dental technician from Savona in Italy, who has specialised in the use of multilayering technology for ceramic materials. According to his philosophy, the choice of restorative materials should be sufficiently wide to realise customised solutions. Among other things, he believes that there is still room for baked porcelain



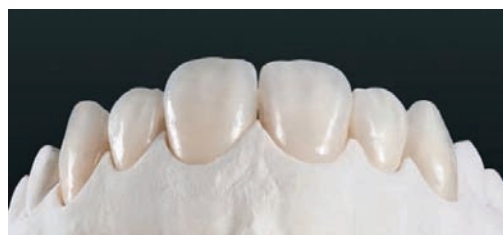
KATANA Zirconia UTML



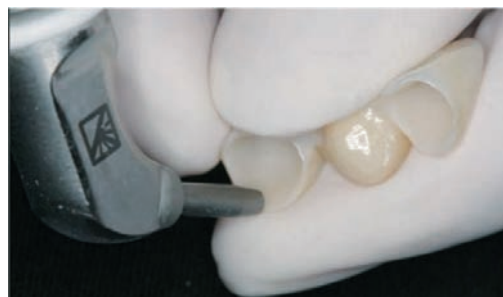KATANA Zirconia STML



KATANA Zirconia ML



These veneers were made from KATANA Zirconia UTML and coloured using CERABIEN ZR External Stain (Kuraray Noritake).



Sandblasting of zirconia oxide at a lower pressure is a requirement for an effective adhesion.

on a core of lithium disilicate or zirconia. Using baked porcelain, the dental technician can modify the surface texture of an aesthetic restoration to lend a certain age to the restoration. □

As for surface structure, that the material allows for the smooth polishing of the occlusal plane is crucial to counteract abrasion by the antagonist and to maintain the occlusal balance. In this respect, the hardness of the material selected is not the main factor; the smoothness and resistance of the surface are far more important.

Flexural strength □

When selecting material for restorations, the dental technician has the option to choose KATANA Zirconia Ultra Translucent Multi-Layered (UTML) for veneers or anterior crowns, a zirconia with a translucence comparable to that of glass. This translucence is especially important for an anterior restoration that is to be fitted between flawless natural teeth, a situation that often occurs after anterior trauma. Such a restoration effected using KATANA Zirconia UTML harmonises with the neighbouring natural teeth, not least because this type of zirconia does not cause the white appearance

common in anterior crowns. □

The second-generation aesthetic zirconia materials are sintered at a temperature of 1,550 °C. This temperature is maintained for 2 hours. The dental technician needs to be aware that this temperature differs from the sintering temperature for KATANA Zirconia High Translucent Multi-Layered (1,500 °C). □

Wide-span bridges can be realised with the latter product, whereas the size of bridges made from KATANA Zirconia Super Translucent Multi-Layer (STML) remains limited to a maximum of four dental elements. KATANA Zirconia UTML can be used for small anterior bridges, but is more suitable for anterior crowns and veneers. The reason for this is that the flexural strength of these highly aesthetic zirconia materials is lower than that of the standard zirconia, of which the flexural strength—1,125 MPa—is sufficient for the production of durable wide-span bridges. The flexural strength of the highly aesthetic zirconia varieties (approximately 750 MPa [STML] and 550 MPa [UTML]) is quite sufficient to ensure the durability of single aesthetic restorations and limited-span bridges.

Preparation □

Flexural strength is not the only decisive factor for durability; the method of preparation is also crucial to properties of this material. Chamfer preparation is the required form of preparation, with no knife-edge outline, no deep shoulder and, obviously, no undercuts. Since the restorations are fixed adhesively, parallel walls or grooves in the preparation are undesirable, and sharp edges and transitions must be rounded off. If a preparation for a full crown has nevertheless been made, a substantial height difference between the vestibular and palatal/lingual outline is contra-indicated. □

Using the new zirconia materials means that a thickness of only 0.4–0.8 mm need be removed for a veneer in the incisal and cervical areas, and only 0.5 mm is required in the labial plane, which corresponds with the requirement to preserve tissue. For inlays too, only 1 mm is sufficient to achieve a durable result. If the inlay is extended to an onlay, 1 mm is also sufficient for the area where the cusps are capped. For a full crown in the lateral parts, a 1 mm space must be kept as a minimum and this thickness must also be maintained for the upright walls of the preparation.

Fixation □

A wide range of possibilities has already been suggested for the durable fixation of zirconia-based restorations. All of these options have also been researched, but there is no point in conducting further research into the best cementation procedure, according to Prof. Matthias Kern from the University of Kiel in Germany. As a scientist and practitioner, Kern has been involved in the adhesive cementation of zirconia for nearly 20 years. Based on his wide experience, Kern is convinced that three requirements have to be met to achieve the reliable cementation of zirconia. First of all, a rubber dam must be applied for the procedure, which is obviously easier for partial restorations than for total restorations. It is not only from the perspective of tissue preservation that it is useful to keep the preparation limited for this reason. The second condition is that micromechanical adhesion needs to be achieved. For zirconia restorations, the necessary adhesion is obtained by sandblasting the surface. Obtaining chemical adhesion is the third requirement. □

Based on extensive research, Kern is convinced that chemical adhesion can only be achieved by

Continued on page 13

DAMAGED ENAMEL CAUSES SENSITIVITY.



REBUILDS ENAMEL FOR LASTING SENSITIVITY RELIEF

Colgate®

PAKISTAN'S #1 SENSITIVITY TOOTHPASTE
RECOMMENDED BY DENTISTS*

*Based on Professional Dentists Tracking Study - IPSOS Pakistan Nov 2015

Anesthesia-free and drill-free deep decay removal

By Dr. Robert Feudo

Applications and research on lasers in dentistry continue to expand, yet the Solea dental laser (Convergent Dental) is the first and currently the only laser system that can cut any tissue with a single setting. The one-setting-fits-all approach works for tooth structure, bone and soft tissue, enabling any dentist to reliably deliver anesthesia-free, blood-free, suture-free and pain-free results. □

The following case shows just how safely and easily caries disease, specifically a deep-decay situation, can be removed by dentists using Solea, and the esthetically pleasing results that follow. Solea's revolutionary software is so easy to use that any dentist can become a laser dentist while providing the patient a more pleasant experience.

Case presentation □

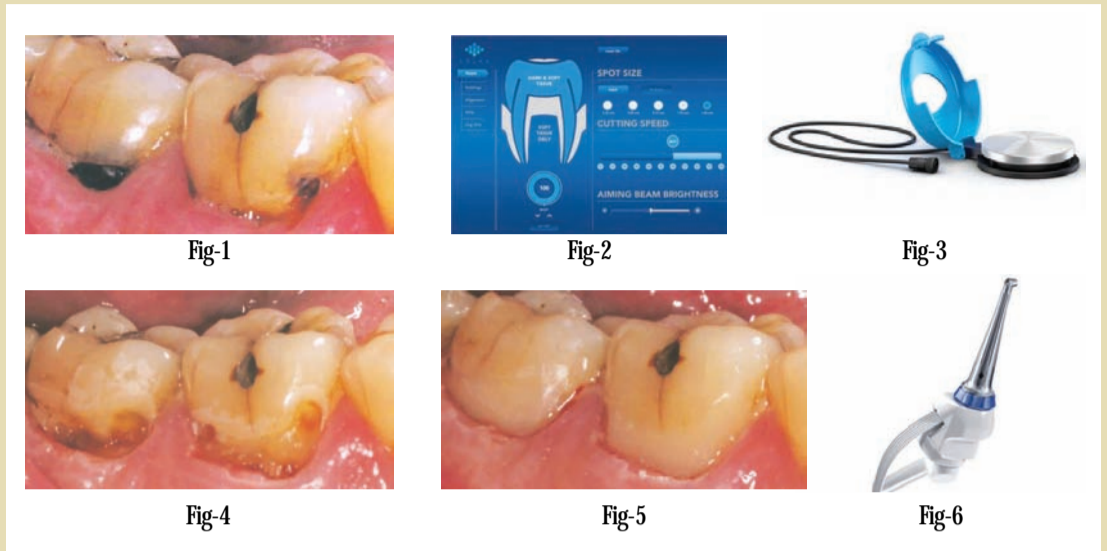
The patient presented with recurrent subgingival buccal decay on tooth #18 and #19 (B) (Fig. 1). The clinical objective was to completely remove the caries and then restore the teeth. The total procedure was completed in approximately 10 minutes and did not require any injectable anesthetic.

Technique using Solea □

For the first step of the procedure, the enamel needed to be cut to access the decay (Fig. 2). This procedure was performed using the "Hard and Soft Tissue" setting and was adjusted to 100 percent mist to effectively penetrate the enamel. For soft tissue, a reduced mist setting would be applied for appropriate coagulation. □

To prepare the enamel as well as the patient, it's recommended to outline the prep at approximately 10-20 percent power and observe the patient and the analgesic effect. Simply apply pressure to the foot pedal (Fig. 3) to increase or lessen the laser power. □

Once the enamel was outlined, a 1.25 mm spot size was chosen and a cutting speed of between 40-60 percent was used to smoothly and gently break through the enamel. With Solea, the learning curve is minimal; maneuvering the handpiece back



and forth is all it takes for a clean and efficient cut. Once the proper amount of enamel was removed, I then removed some soft tissue as well to better access the subgingival decay. I used a 1.00 mm spot size setting and 40-50 percent cutting speed along with 100 percent water mist. I did not need to adjust the water and usually don't unless the area is extremely inflamed. □

The dentin was now exposed, and I was ready to eliminate the deep decay (Fig. 4). For the decay removal in the dentin, the same 1.00 mm spot size was chosen with a cutting speed between 30-40 percent. The decay was then thoroughly and easily removed using the laser by applying a gentle gliding back-and-forth motion of the handpiece. Both teeth were then ready for restorative work using only the Solea and a spoon excavator. □

The teeth were then restored using Ultra-Etch (Ultradent), Adhese Universal (Ivoclar Vivadent), and Filtek Supreme Ultra Universal Restorative A3B (3M). The total procedure, from start to finish, was a mere 10 minutes (Fig. 5).

Benefits of Solea □

Solea has drastically changed the way I practice dentistry. This is just one of many cases that I've completed using this truly revolutionary laser. Using Solea has provided my practice substantial

surges in production and workflow efficiency, and, moreover, patient compliance has dramatically increased. □

Procedure time was reduced from typically 40 minutes compared with a mere 10 minutes with Solea to complete the case. Productivity was increased in several ways. Because the patient did not require any anesthetic, a significant amount of time was saved. If I were to use traditional instrumentation, there would have been at least one injection given and then time spent waiting for anesthetic to set in. In addition, the occlusion was accurately checked with the patient at the completion time of the procedure - potentially avoiding a follow-up appointment for a bite adjustment. Eliminating the anesthetic process also allows the ability to perform multiquadrant dentistry in the same appointment.

About the author □

Dr. Robert Feudo maintains a state-of-the-art dental facility on the North Shore of Boston in Danvers, Mass. He holds a BS in biology from Suffolk University and received his DMD from the Tufts School of Dental Medicine. Feudo is a member of the American Dental Association and the Massachusetts Dental Association.

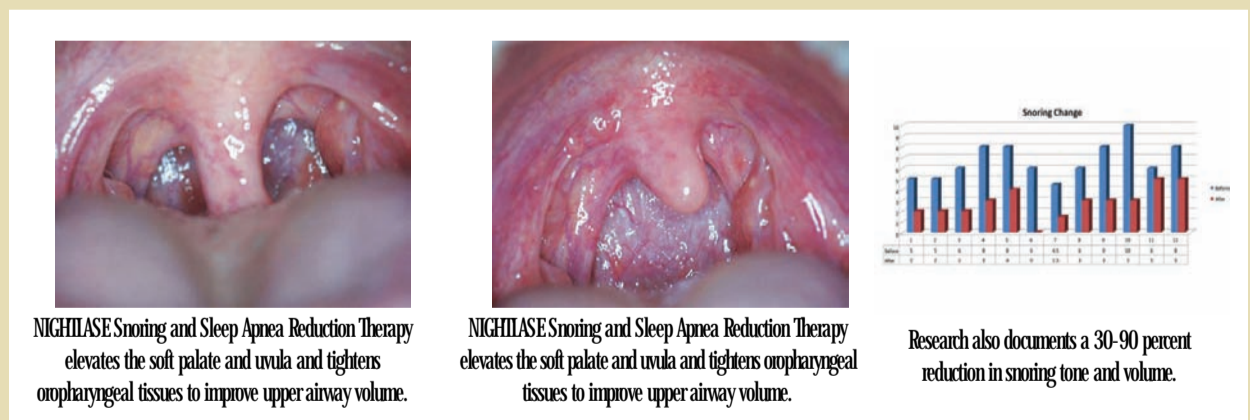- DT, General Dentistry USA

Non-surgical laser has sleep applications

By Harvey S. Shiffman, DDS

Of the commercially available hard- and soft-tissue lasers, only the LightWalker (Fotona, San Clemente, Calif.) combines two proven wavelengths, Nd:YAG and Er:YAG, with unrivaled power and precise pulse control resulting in high levels of efficacy for a wide range of procedures. With this advanced level of performance comes significant patient comfort. □

The procedure described here has been developed to take advantage of these attributes. Snoring and sleep disordered breathing affect millions of Americans, both adults and children.[1,2] The signs and symptoms are the result of partial or complete collapse of the upper airway during sleep.[3] The structures involved in our protocol include the soft palate,



uvula and the base of the tongue.[4] The goal of the treatment is to decrease the amount of blockage of the upper airway.[5] □

Dentists are in a great position to help screen and in many cases treat these problems with airway management. Helping patients improve their sleep can profoundly

improve their health, quality of life and well-being of their loved ones. The "Gold Standard" for the treatment of sleep disordered breathing is the CPAP type device. Following that in 1981 was the introduction of Mandibular Advancement Devices (MAD). Compliance with both of these treatment modalities shows a

reduction in compliance over time and significant side effects. However, the "NIGHTLASE Snoring and Sleep Apnea Reduction Therapy" protocol is a unique approach to treatment using the Fotona LightWalker dental laser with a proprietary protocol and handpiece. Another positive benefit is

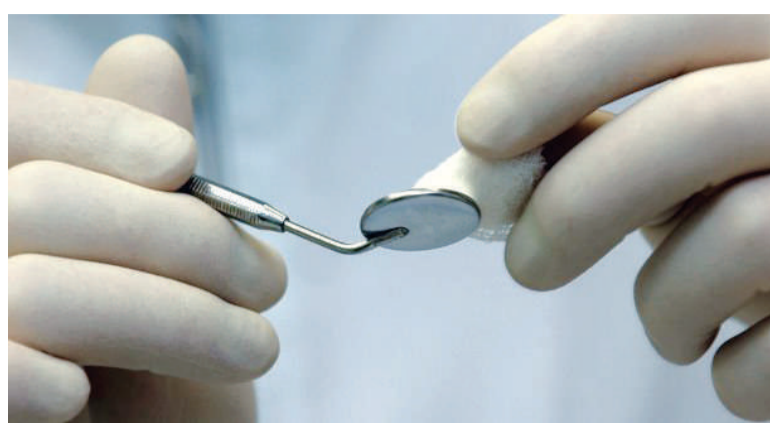Continued on Page 07

Infection control in an era of emerging infectious diseases

By Eve Cuny

More than three decades have passed since the emergence of human immunodeficiency virus (HIV) as a global pandemic. More than any other infection, it is possible to single out HIV as the primary stimulus for changing infection control practices in dentistry. Prior to the mid-1980s, it was uncommon for dentists and allied professionals to wear gloves during routine dental procedures. Many dental clinics did not use heat sterilisation, and disinfection of surfaces was limited to a cursory wipe with an alcohol-soaked gauze sponge. This was despite our knowledge that hepatitis B virus (HBV) had been spread in clusters in the offices and clinics of infected dentists and that dentists were clearly at occupational risk for acquiring HBV.

Today, many take safe dental care for granted, but there is still reason to remain vigilant in ensuring an infection-free environment for providers and patients. HIV has fortunately proven to be easily controlled in a clinical environment using the same precautions as those effective for preventing the transmission of HBV and hepatitis C virus.[1] These standard precautions include the use of personal protective attire, such as gloves, surgical masks, gowns and protective eyewear, in combination with surface cleaning and disinfection, instrument sterilisation, hand hygiene, immunisations and other basic infection control precautions. Sporadic reports of transmission of blood-borne diseases associated with dental care continue, but are most often linked to breaches



Infection control in the dental practice includes washing hands, wearing gloves, using disposable supplies, and disinfecting reusable materials properly.

in the practice of standard precautions.[2]□

Emerging and re-emerging infectious diseases present a real challenge to all health care providers. Three of the more than 50 emerging and re-emerging infectious diseases identified by the Centers for Disease Control and Prevention and the World Health Organization (WHO) include Ebola virus disease (EVD), pandemic influenza and severe acute respiratory syndrome.[3, 4] These previously rare or unidentified infectious diseases burst into the headlines in the past several years when they exhibited novel or uncharacteristic transmission patterns.□

Concern about emerging infectious diseases arises for several reasons. When faced with a particularly deadly infectious disease such as EVD, which can be spread through contact with an ill patient's body fluids, health care workers are naturally concerned about how to protect themselves if an ill patient presents to the dental clinic. With diseases such as pandemic influenza and severe acute respiratory syndrome, which may be

spread via inhalation of aerosolised respiratory fluids when a patient coughs or sneezes, the concern is whether standard precautions will be adequate.□

In addition to standard precautions, treating patients with these diseases requires the use of transmission-based precautions. These encompass what are referred to as contact, droplet and airborne precautions for diseases with those specific routes of transmission. Transmission-based precautions may include patient isolation, placing a surgical mask on the patient when he or she is around other people, additional protective attire for care providers, and in some cases the use of respirators and negative air pressure in a treatment room. In most cases, patients who are contagious for infections requiring droplet or airborne precautions should not be treated in a traditional dental clinic setting.□

Updating a patient's medical history at each visit will assist dental health professionals in identifying patients who are symptomatic for infectious diseases. Patients with respiratory

symptoms, including productive cough and fever, should have their dental treatment delayed until they are no longer symptomatic. Additionally, health care professionals who are symptomatic should refrain from coming to work until they have been free of fever without taking fever-reducing medication for 24 hours.□

In most cases, a patient with symptoms as severe as those experienced with EVD will not present for dental care and therefore extraordinary screening and protection protocols are not recommended. If a patient is suspected of having a highly contagious disease, he or she should be referred to a physician, hospital or public health clinic. □

Dental professionals should take action to remain healthy by being vaccinated according to accepted public health guidelines, understanding that the recommendations may differ according to country of residence. Performing hand hygiene procedures at the beginning of the day, before placing and after removing gloves, changing gloves for each patient, wearing a clean mask and gown or laboratory coat, and wearing protective eyewear are all positive actions that help prevent occupational infections. In addition, cleaning and heat sterilisation of all instruments and disinfection of clinical surfaces ensure a safe environment for patients. There is solid evidence that dental care is safe for patients and providers when standard precautions are followed, but patients and dental health care workers are placed at risk when precautions are compromised and breaches occur.

– DT Dental Hygiene USA

Non-surgical laser ...

Continued from front page

the 24-hour-a-day improvement in airway vs. CPAP and MAD.□

NIGHTLASE uses the photothermal capabilities of the LightWalker laser to convert and initiate the formation of new and more elastic collagen.[6] The target mucosal tissues are the oropharynx, soft palate and uvula. The proprietary "Smooth Mode" pulse characteristics create a non-ablative heat generation or "Heat Shock" that initiates the conversion of existing collagen to more elastic and organized forms and also initiates "neocollagenesis," the creation of new collagen.□

This process results in a visible elevation of the soft palate and uvula and tightening of the oropharyngeal tissues, resulting in an improvement in the upper airway volume. The results can be seen in Figures 1 and 2.□

NIGHTLASE therapy is indicated for cases when the patient has been diagnosed with chronic snoring, UARS or mild to moderate sleep apnea and either cannot or chooses not to wear an appliance or CPAP device. It can also be used in co-therapy with those devices, allowing for lower CPAP pressures and less MAD advancement. NIGHTLASE represents a less-invasive alternative to current surgical, chemical or radiosurgical options that may require hospitalization, general anesthesia or soft-tissue removal.□

NIGHTLASE has a significant success rate in producing a positive change in sleep patterns. Research published by Miracki and Visintin[7] has shown that it can reduce and attenuate snoring, and provides an effective non-invasive modality to lessen the effects of obstructive sleep apnea. As with any treatment, there are potential risks with laser

treatment. However, the risks are minimal and certainly less than alternative therapies if the protocol is followed correctly. NIGHTLASE therapy is not a permanent alteration and lasts anywhere from six to 12 months and is easily touched up at follow-up appointments.[2]□

In 2013 we completed a pilot study that addressed only snoring with 12 patients. Twelve-month follow-up showed a 30-90 percent reduction in snoring tone and volume (Fig. 3). The lower percentages were smokers, obese patients and those with severe OSA. Follow-up studies with polysomnography using HST are in process, as are pharyngometer studies, both of which have recorded significant positive changes.□

A recently published pilot research study by Lee and Lee[8] has shown through 3-D CT imaging the volumetric positive changes after NIGHTLASE treatment to help

support the clinical results, and the authors have follow up studies with 3-D CT, polysomnography and a larger group of patients in process. We are excited to present these modern, minimally invasive and more natural treatment modalities to the dental community. Using the LightWalker laser, we can now have another tool in our dental toolbox and offer our patients health improvements that reach beyond restorative and rehabilitative dentistry.□

If the reader is curious about using the NIGHTLASE protocol or about laser dentistry in general, you can contact the manufacturer for more information. As always, we recommend a good variety of advanced educational programs in dental sleep medicine to see where NIGHTLASE might fit into your patients' treatment protocols.

– DT, General Dentistry Canada

Madrid, Spain
29 August - 1 September 2017

fdi 
World Dental Congress


MADRID 2017



*Bringing the World together
to improve oral health*

**THE BIGGEST INTERNATIONAL
DENTAL CONGRESS**

Abstract submission deadline:
3 April 2017

Early-bird registration deadline:
31 May 2017

www.world-dental-congress.org

THERE'S MORE TO THIS...



...THAN MEETS THE EYE



REGISTER FOR YOUR FREE PLACES NOW:
ONLINE: THEDENTISTRYSHOW.CO.UK/DT



dentistry show

for all that dentistry demands
12th & 13th May 2017 / NEC Birmingham

www.thedentistryshow.co.uk www.the-dts.co.uk

Co-located with

