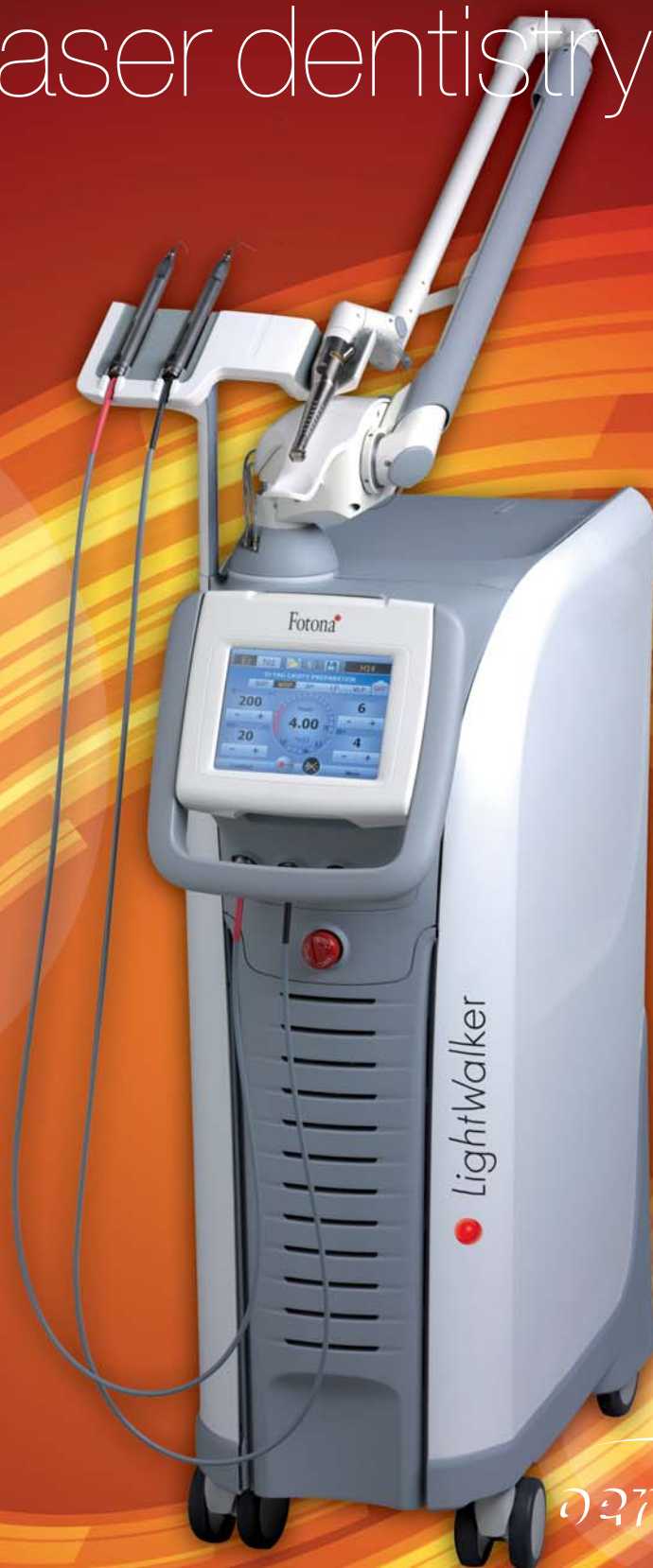

# laser

international magazine of laser dentistry

1 2011



| **research**

Clinical comparison of two laser wavelengths

| **case report**

A concept of laser-assisted treatment of periimplantitis

| **interview**

Laser-assisted treatment—  
Questions and answers

0277113

Preserved collagen  
fibrils of the intertubular  
dentin at the entrances  
to the dentinal tubules.

# The universe at your fingertips.



## LightWalker®

**Introducing the highest technology dental laser system**

**Supreme clinical results in:**

- TwinLight™ Perio Treatments (TPT)
- TwinLight™ Endo Treatments (TET)
- No-sutures soft tissue surgery
- Gentle TouchWhite™ bleaching
- Patient-friendly conservative dentistry

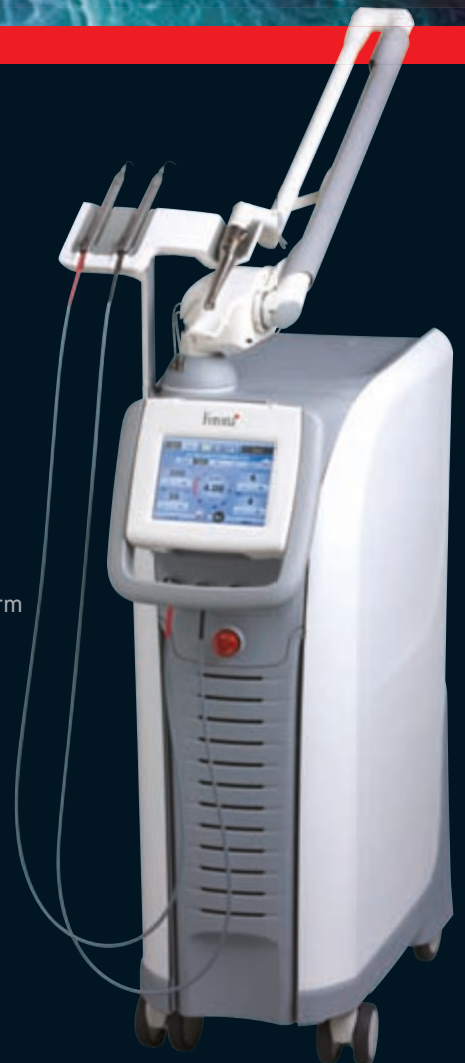**Unmatched simplicity of use:**

- Pre-sets for over 40 applications
- Intuitive user navigation
- Balanced and weightless OPTOflex arm
- Nd:YAG handpiece detection system
- Er:YAG scanner ready

Journey into a new dental experience with speed, precision and great results.

Visit Fotona at IDS 2011 - Köln, 22 - 26 March, Hall 10.2, Booth M050.

[www.lightwalkerlaser.com](http://www.lightwalkerlaser.com)



[www.fotona.com](http://www.fotona.com)

**Fotona**  
choose perfection

88897/8.0



Prof Dr Norbert Gutknecht  
WFLD President  
Editor-in-Chief

# It's **show** time!

**The world greatest dental exhibition, IDS 2011 in Cologne, is just ahead. A lot of speculations and expectations are in the air. Everybody is curious to know what is new in the dental world, so do I. It is not only a curiosity to know what kind of new products, instruments and equipment are presented, but it is also of special interest to see what kind of developments have been taking place in the field of laser dentistry.**

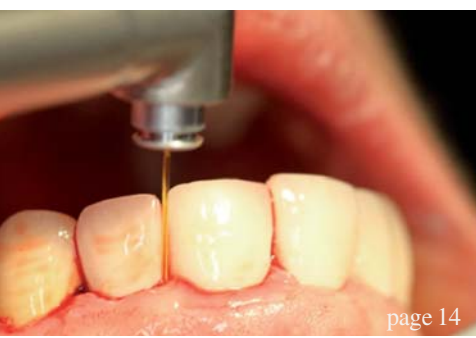If I believe the speculations, which have been shared with me, I am sure that we will find a number of highlights in this area. New technical features, new treatment concepts, new biophysical ideas and new wavelength combinations will be presented, explained and demonstrated to the visitors.

I hope therefore that a big number of interested visitors will be stimulated to find out more about the beneficial use of a laser supported dental treatment concept.


Finally I wish all laser exhibitors within this dental show a very good success in promoting their products.

A handwritten signature in black ink, appearing to read 'Gutknecht', written in a cursive style.

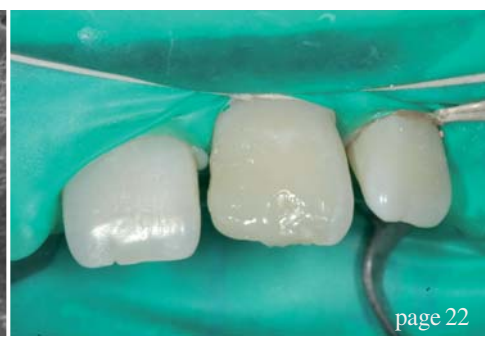Prof Dr Norbert Gutknecht  
Editor-in-Chief



page 14



page 20



page 22

| editorial

03 It's **show** time!  
| Prof Dr Norbert Gutknecht

| research

- 06 Diode laser surface decontamination in **periodontitis** therapy  
| Dr Georg Bach
- 14 Clinical **comparison** of two laser wavelengths  
| Dr Ron Kaminer
- 18 The treatment of **prominent frenulum** with diode laser 940 nm  
| Dr Merita Bardhoshi

| special

20 Photo-acoustic **endodontics** using PIPS  
| G. Olivi *et al.*

| clinical report

22 **Paediatric** laser-assisted **dentistry**  
| Claudia Caprioglio *et al.*

| case report

30 A concept of **laser-assisted treatment** of periimplantitis  
| Dr Gérald Mettraux

36 **Esthetic rehabilitation** of anterior hypoplastic tooth using Er:YAG laser  
| Dr Georgi Tomov

| user report

39 Laser-assisted teeth **bleaching**  
| Dr Dimitris Strakas

| interview

42 The expert defines **laser dentistry 2011**  
| An interview with Prof Dr Norbert Gutknecht

| news

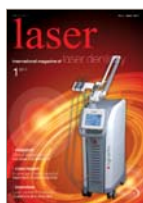
- 41 **AALZ** Hong Kong and China  
| Dr Ryan Seto
- 46 **Manufacturer** News

| meetings

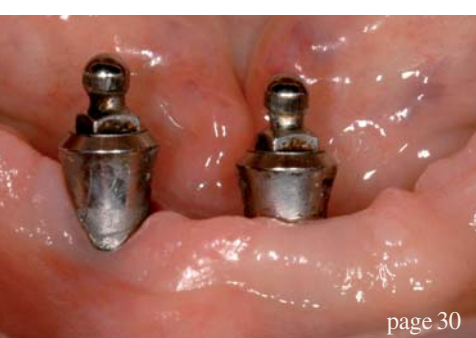49 **International** events 2011

| about the publisher

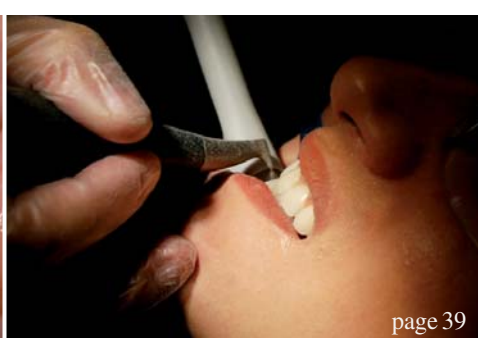50 | Imprint



Cover image courtesy of Fotona d.d., [www.fotona.com](http://www.fotona.com).  
Artwork by Sarah Fuhrmann, Oemus Media AG.



page 30



page 39



page 41

*Express  
your mastery*

Join the fast growing success of Syneron Dental Lasers

Presenting

LITETOUCH™

The Dentist's 1<sup>st</sup> Choice

IDS Show - Cologne, Germany, March 22-26, 2011 Booth N050, Hall 4.2

III WFLD-ED European Congress - Sapienza University of Rome - Italy, June 9-11 2011 ,Booth 13

For seats reservation please contact: [dental@syneron.com](mailto:dental@syneron.com)

WWW.SYNERONDENTAL.COM



**Syneron™**  
DENTAL LASERS

# Diode laser surface decontamination in periodontitis therapy

## 15 years of incorporating

Author\_Dr Georg Bach, Germany

### CASE 1

**Fig. 1** Panoramic tomography (emergency service) dating back to 1995—immediately prior to commencement of treatment.

**Fig. 2-4** Baseline findings in 1995.

**Fig. 5a & b** Tooth 37 was not conservable in spite of hemisection (August 1995), resulting in a large edentulous space in the third quadrant (November 1995).

We don't always have the opportunity to provide long-term dental treatment for patients with a profound marginal parodontopathy who have undergone resective surgical therapy, at times including reconstructive work. Correspondingly, there is only a limited amount of literature available due to the aforementioned fact. The number of published studies/other publications is even more limited as regards new therapy concepts or adjuvant treatments to complement a proven therapy regimen. In 1995, the first diode laser (wavelength 810 nm) was presented at IDS in Cologne. This device—initially as a prototype—had been used within the scope of a test phase since

1994. At the end of 1994 patients were treated with this "new" laser wavelength for the first time, which had not been used in dentistry up until that time. The Freiburg laser work group led by Krekeler and Bach, who were the first ones to deal with the integration of diode laser light in dentistry, noticed the considerable advantages of this new technology.

High-performance diode lasers emit monochromatic coherent light at a wavelength of 810 nm. This light is absorbed particularly well by dark surfaces. Thus the injection laser (= diode laser) is ideally suited to perform cuts, as are com-

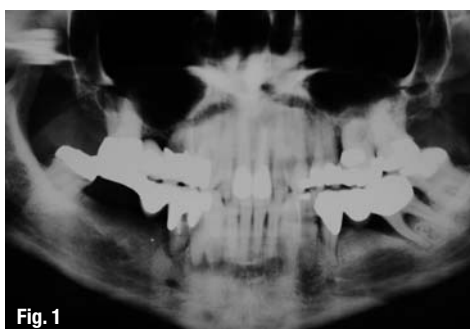


Fig. 1

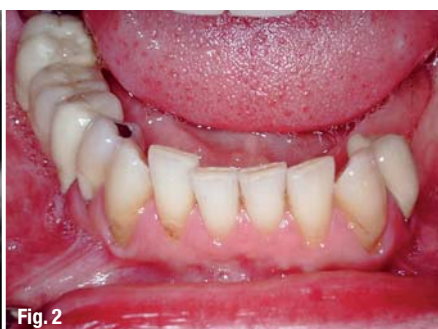

Fig. 2

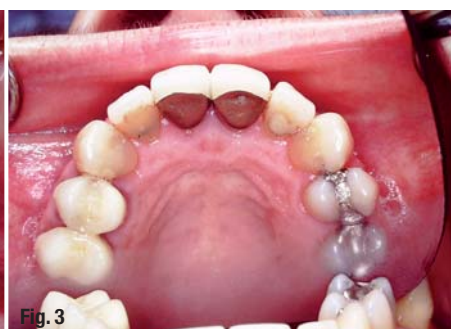

Fig. 3

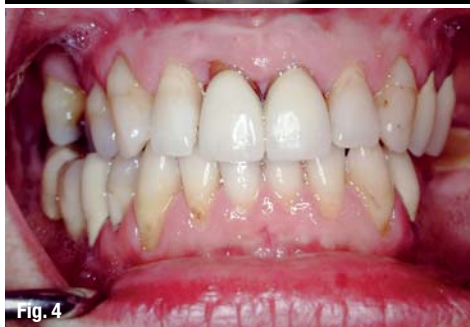

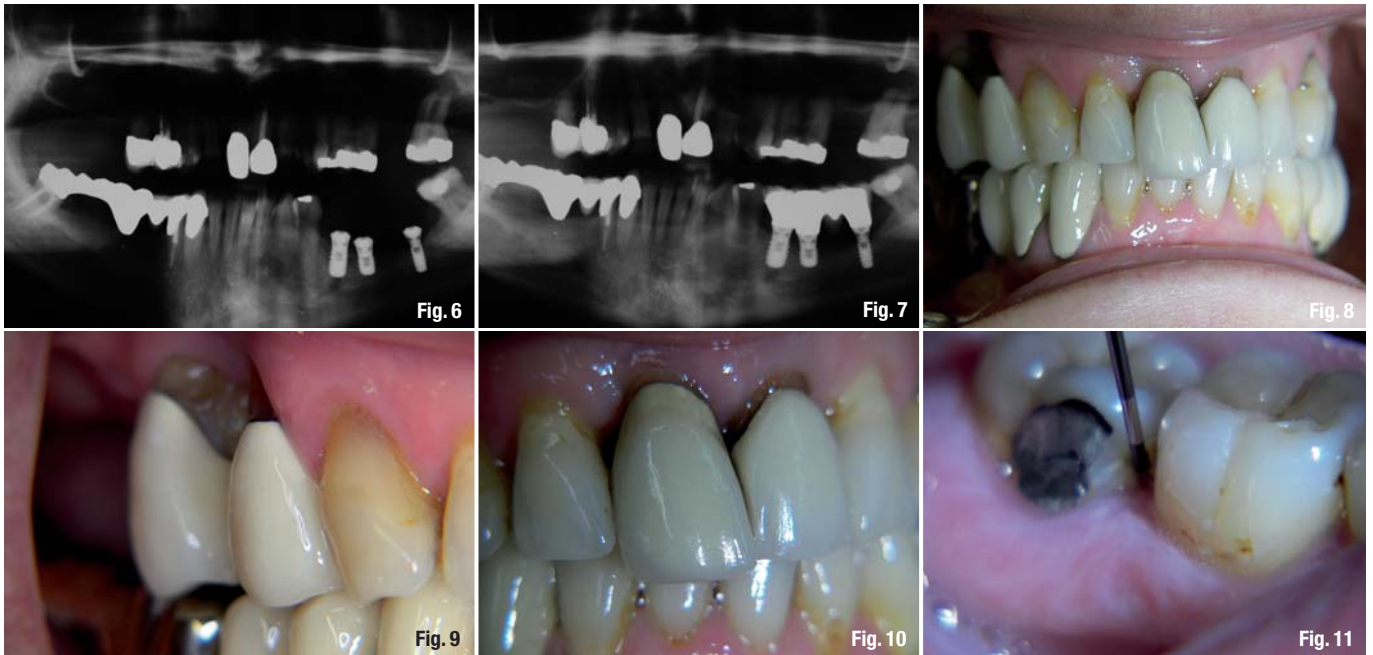
Fig. 4

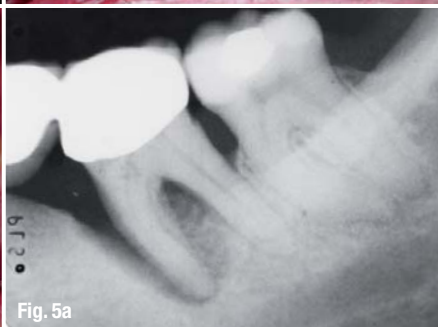

Fig. 5a

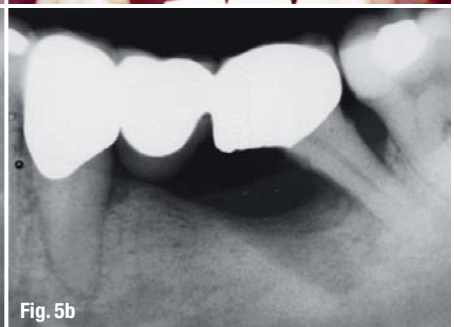

Fig. 5b



**Fig. 6** Orthopantomogram after insertion of 3 short implants ("shorties") in the atrophied left half of the mandible.  
**Fig. 7** 6-year follow-up in 2001.  
**Fig. 8-11** Clinical findings in 2009, shortly prior to restoration of the maxilla (general view and details).

mon in dental surgery, as well as for the removal of benign tumors in the oral cavity, for exposing implants and for use in mucogingival surgery. This excellent cutting performance of the diode laser can be attributed to the exceptional absorption of the laser light by the hemoglobin in the tissue. Aside from an application in soft-tissue surgery, the diode laser is also used for decontaminating surfaces that are colonized by germs (on implants and teeth). It was proven in these applications that especially a gram-negative, anaerobic germ spectrum is sufficiently damaged by the laser light.

The following paper describes—by means of three selected patient cases—our "Freiburg" experience of incorporating laser light decontamination in the therapy of marginal parodontopathies.

### Material and methodology

We are presenting treatment results for three patients who received dental treatment over a period of 15 years (12/94-04/10). Initially, these three patients suffered from a profound parodontopathy with inadequate degeneration of supportive tissue. The course of treatment for these three patients proceeded according to the following regimen:

#### 1. Initial therapy (12-1994 through 01-1995)

- Motivation and instruction of the patient
- Cleaning and polishing
- Application of disinfecting agents

#### 2. Resective phase (01-1995 and/or 02-1995)

- Creation of a mucoperiosteal flap
- Removal of granulation tissue

- Decontamination with diode laser light ( $p = 1.0 \text{ Watt}$ ;  $t_{\text{max}} = 20 \text{ sec}$ )

- Apical shifting of soft tissue

#### 3. Reconstructive phase (01-1995 and/or 02-1995)

- Bone augmentation, if required
- Mucogingival corrections, if required

#### 4. Recall phase (from 05-1995 to present)

- After 4 weeks, 6 months, 1 year and then annually: complete survey of clinical evidence, X-ray diagnosis, repeated decontamination with diode laser light of exposed root areas, if required.

### Imaging procedures

As a general rule, the orthopantomogram (panoramic tomography) and in special cases/as a supplementary measure dental film images as a parallel technique were the applied imaging procedures.

A-scan and B-scan ultrasonography was also used in a few cases of exacerbated inflammations. An orthopantomogram was taken preoperatively and immediately post-operatively, and a panoramic tomography every three years thereafter.

The distinct advantage of an orthopantomogram is its panoramic view of all teeth, the osseous limbus alveolaris and important adjacent anatomic structures. By comparison, dental film images as a parallel technique provide information about the progression and stagnancy of the issue degeneration, because they enable statements about the behavior of the limbus alveolaris.

## Microbial diagnostics

At the time of diagnostic radiology (see above), germ extractions of the affected areas were also performed. This was not done by way of the conventional microbial examination technique (germ extraction—cultivation—pure cultures—microscopic specimen—gas chromatography—sensitivity to antibiotics and color test strips); instead, DNA-RNA hybridization tubes were used.

The advantage of these hybridization tubes was that no live material from the probed areas was required for cultivation, thus reducing work in the dental practice. In addition, the results were available much faster than with the classic microbial examination. The disadvantage of these rapid tests is a relatively high price and the fact that the employed product only detects special marker germs so that not all microbial organisms in the sulcus can be identified.

The area where a germ extraction was planned had to be carefully dried with a cotton swab. The paper tip was then put in place and, after an exposure time of 10 seconds, was immediately packaged in a sterile container and forwarded to the manufacturer for germ identification. The manufacturer identified the germs and evaluated the so-called marker germ values.

The result was considered negative if less than 0.1% was identified as a marker germ. The result was considered to be low if 0.1–0.99% was identified as a marker germ. The result was considered to be medium if 1.0–9.9% was identified as marker germ and high if more than 10% was identified as marker germ.

## Laser light decontamination

Decontamination was an essential part of the overall therapy:

It was achieved with diode laser light of 810 nm wavelength, 1 watt of power and an application time of 20 seconds per tooth and implant under fiber contact in continuous wave mode. When adhering to

these parameters (time limitation and power limitation) it can be guaranteed that the germ spectrum causing the disease can be sufficiently damaged and at the same time that pulpa and/or peri-implant or periodontal tissue structures do not suffer any thermal damage (Bach and Krekeler [1994]).

## Three patient cases 1995/2010

Three patients are presented from the original patient group of the "diode laser basic study" (25 patients) from 1995 (Krekeler/Bach, Department of Parodontal Surgery of the University Dental Clinic, Freiburg/Breisgau) who showed "typical progression patterns" and whose treatment illustrates the advantage of integrating diode laser light application into a proven therapy regimen for the treatment of marginal parodontopathies.

### 1<sup>st</sup> Case (Figs. 1–14)

#### The holding therapy case

Female patient, born in 1954.

#### Medical history

The patient went to the Sunday emergency service at the Freiburg dental clinic because of pain in tooth 37. A profound parodontopathy was diagnosed there, and the patient came to our department on the following Monday requesting treatment. She had received a complete fixed restoration from her dentist 6 months ago, but without a preprosthetic X-ray diagnosis. Ms. D. is a healthy and very health-conscious physiotherapist.

#### Clinical baseline findings (1995)

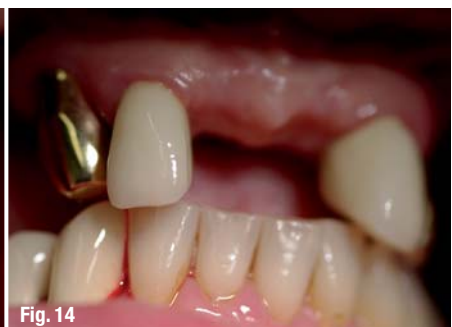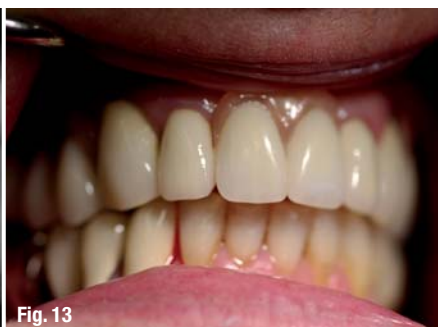Abutment tooth 17 showed a degree of loosening of 2, as did tooth 26 and tooth 45. Mesial probing resulted in profuse, hard to arrest bleeding. BOP and high probing depths were found in general. The interdental spaces had soft deposits, also under the pontics.

#### X-ray diagnosis (1995)

The panoramic tomography (orthopantomogram) shows severe horizontal and vertical bone le-

**Fig. 12** The periodontal lesions (vertical bone degeneration) on teeth 15, 14, 24, 25 are so advanced that these teeth can be considered non-conservable.

**Fig. 13 & 14** There are essential modifications in comparison with the baseline findings regarding the maxilla. Some teeth have to be extracted. Furthermore, a removable bridge (telescopic bridge) was inserted.

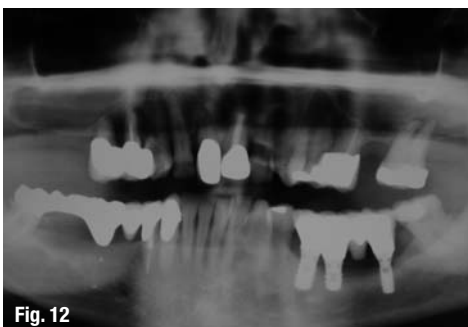



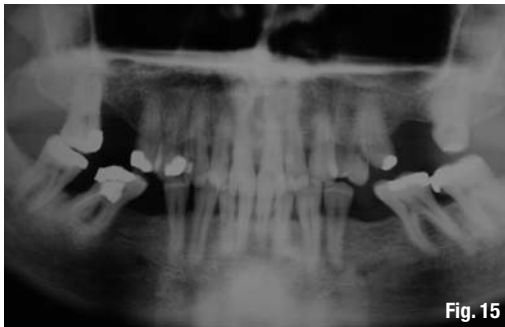


Fig. 15

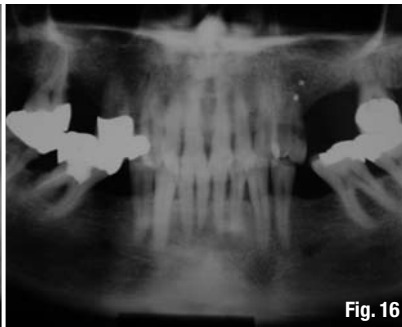


Fig. 16

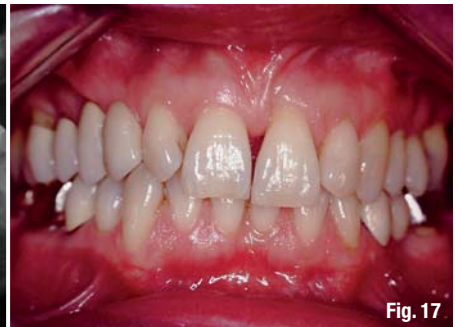

Fig. 17

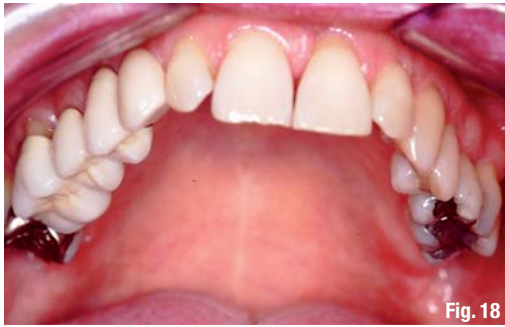

Fig. 18

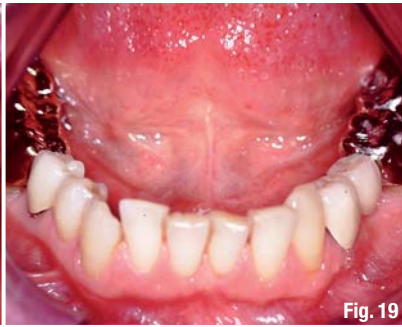

Fig. 19

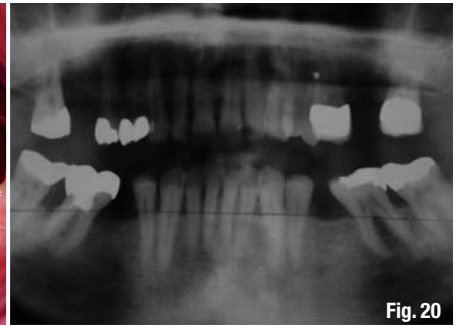


Fig. 20

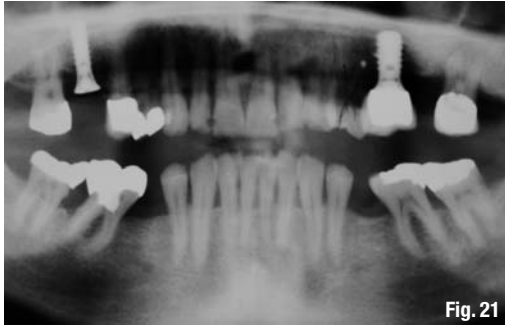


Fig. 21

sions. Teeth 35 and 26 have dish-shaped defects. Trifurcation 34 is opened radiologically.

*Diagnosis*

Most severe form of adult marginal parodontitis having portions with a fast-course component.

*Course of treatment 1995–2010*

Tooth 37 was extracted within the scope of initial pain treatment, as were teeth 26, 17 and 35. Removable immediate prostheses were incorporated because all three pontic reconstructions had to be destroyed during the extraction therapy. The pre-treatment phase proved to be unproblematic; the patient was very motivated and eager to learn the oral hygiene techniques as instructed.

From June to August 1995 the remaining teeth were treated with open curettement. She had no recurrence for a long time. She received implants in the third quadrant while the remaining maxillary side teeth received fixed prostheses. The edentulous space in the second quadrant remained at the patient's request; in the first quadrant, the principle of a shortened row of teeth was realized (up to 5' to 5<sup>th</sup>).

This condition was maintained from the end of 1996 to 2008. The patient conscientiously observed all recall appointments. Aside from the usual cleaning, motivation and instruction steps, a diode laser light application was always performed. Special emphasis was placed on the periodontally severely damaged premolars and the remaining molar 27.

First re-inflammations of the marginal parodontopathy were noticed in 2009; a curettement of teeth 14, 15 and 27 was performed once again. Due to subliminal but latent discomfort, teeth 15, 14 and 27 were removed at the beginning of 2010 and a new concept for treatment of the maxilla was developed.

A removable telescopic prosthesis (cuspid are abutment teeth) was incorporated. The prosthesis on the mandible, which has been in place for 15 years, is still there, and there are no signs of a degeneration of the supportive tissue on the natural and artificial abutment teeth.

*Epicrisis*

Very remarkable in this patient was the considerable amount of trust she had—in spite of bad experiences in the past—in the new laser-assisted therapy concept, which was out of the ordinary at the time. Her compliance was exceptionally good for the entire 15 years. Because of her conscientious oral hygiene and strict adherence to the recall system she remained recurrence-free for more than a decade. This still holds true for the mandible, while the antecedent massive degeneration of supportive tissue required the removal of three maxillary teeth. Thanks to the diode laser assisted periodontal therapy and the continuous recall, the patient was able

**CASE 2**

**Fig. 15** Panoramic tomography dating back to 1994—prior to commencement of treatment.

**Fig. 16** Initial X-ray image taken in 1995.

**Figs. 17–19** Baseline findings in 1995.

**Fig. 20** Four-year follow-up 1999.

**Fig. 21** Panoramic tomography taken in 2004; dental implants were inserted to increase the number of abutment teeth.