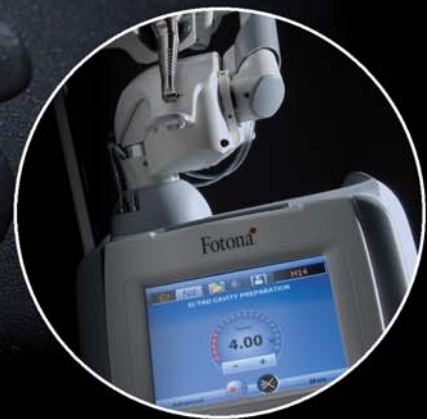

laser

international magazine of laser dentistry

1 2013



| **overview**

Laser versus conventional therapies

| **research**

Photodynamic therapies – Blue versus Green

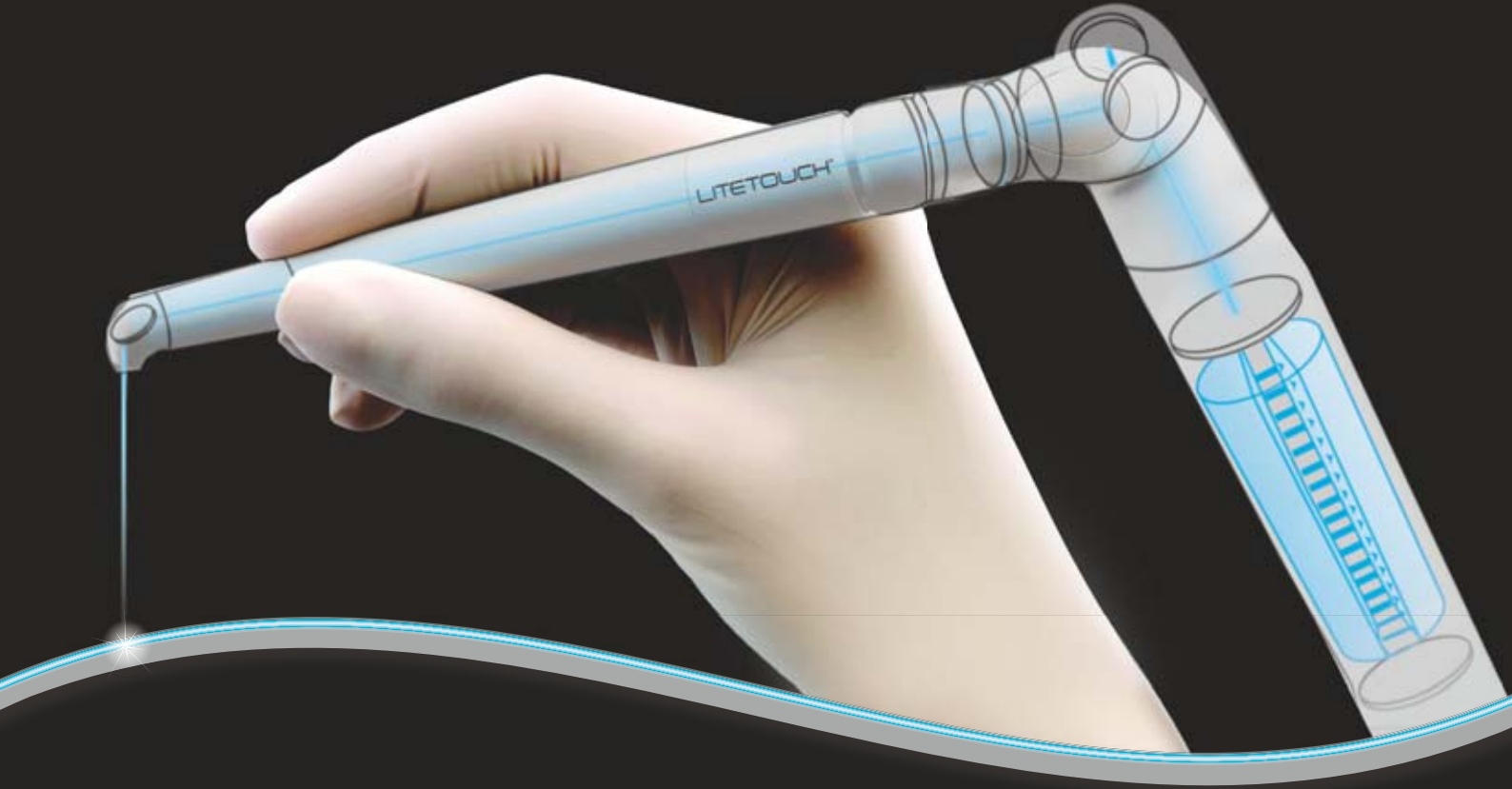
| **industry report**

Long-term treatment of peri-implant lesions in geriatric dentistry



Syneron[™]
DENTAL LASERS

*Express
your mastery*



Education. Technology. Family.

Join the Syneron Dental Lasers Family at IDS 2013

Come and see the LiteTouch[™] in action

The unique Er:YAG laser that has changed the face of laser dentistry

**IDS
2013**

Live presentations every hour, Booth N050, Hall 4.2, March 12-16, 2013, Cologne, Germany.
Reserve your personal consultation at dental@syneron.com

WWW.SYNERONDENTAL.COM

Cologne in the eyes of laser dentistry



Dr Georg Bach

Dear readers of **laser** international magazine of laser dentistry,

I must confess that the headline of this editorial is a little presumptuous—and of course, not only is Cologne in the focus of the dental community, but the whole dental family is watching the city on the Rhine. This time, for sure, it is not because of the carnival, but because of IDS, International Dental Show, which starts only shortly after.

Although we have experienced this dental trade show for decades, it still radiates a hard-to-describe mixture of curiosity, thirst for knowledge and fascination.

IDS has always been a special event for laser dentistry, if not even the motor of this incredible and sometimes turbulent development this dental specialty has undergone since the early 1990s.

Judging from the hype triggered by the first Nd:YAG lasers presented in Cologne as well as the "all new" area of laser-supported hard tissue therapies and photodynamic therapy, laser dentistry has brought about a multitude of both new and aspiring laser users: IDS has always proved to be the perfect place for laser dentistry!

As the dental laser industry is well aware of this fact, all important manufacturers and distributors are represented with stands, staff and equipment and even with an entertaining programme.


Of course, dear reader, I am not yet able to predict if the time-honoured Cologne exhibition halls will witness a new laser hype, but you will certainly encounter state-of-the-art dental lasers at IDS. Therefore, I wish you as well as our editorial team much fun at IDS 2013!

Independently from whether or not you will be able to visit Cologne, I hope that all readers of **laser** international magazine of laser dentistry will enjoy this issue!

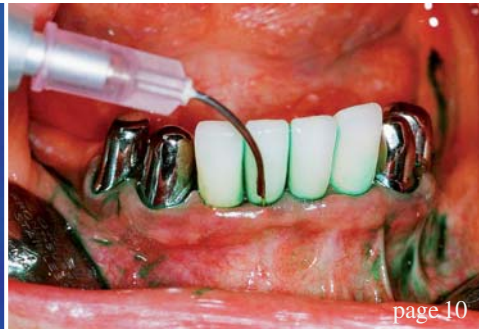Warm regards,



Georg Bach



page 06



page 10



page 26

| editorial

03 **Cologne** in the eyes of **laser dentistry**
| Dr Georg Bach

| overview

06 **Laser versus** conventional therapies
| Cristiane Meira Assunção *et al.*

| research

10 **Photodynamic** therapies – **Blue** versus **Green**
| Dr Michael Hopp *et al.*

| case report

26 **Becoming kissable:**
Laser-assisted haemangioma removal
| Dr Darius Moghtader

| industry report

30 **Er:YAG Garnet** in laser-assisted **crown lengthening**
| Dr Avi Reyhanian

34 **Long-term treatment of peri-implant lesions in geriatric dentistry**
| Dr Georg Bach

38 **X-Runner Er:YAG dental laser** application
| Prof. Dr Carlo Fornaini

| education

44 **1st International Congress of WALED and GLOBAL 2013 in Istanbul**
| AALZ Germany

| meetings

46 **The next chapter in the IDS success story**
| Koelnmesse

| news

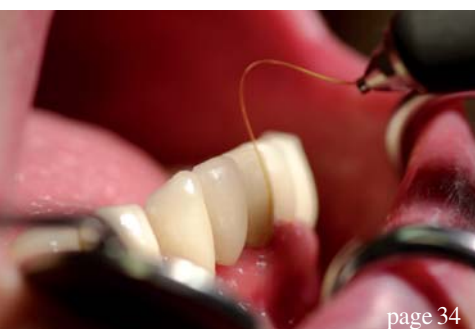42 **Manufacturer News**
48 **News**

| about the publisher

50 | imprint



Cover image courtesy of Fotona, www.fotona.com



page 34



page 44



page 46



After endodontic laser treatment there is no smear layer around the opening of the lateral canal.

The universe at your fingertips.

LightWalker®

Introducing the highest technology dental laser system

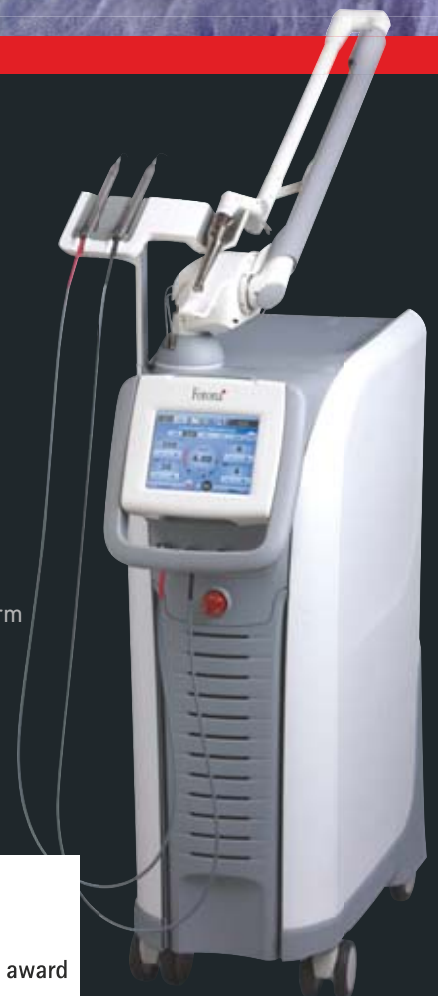Supreme clinical results in:

- TwinLight™ Perio Treatments (TPT)
- TwinLight™ Endo Treatments (TET)
- Effective oral implant surgery
- Gentle TouchWhite™ bleaching
- Patient-friendly conservative dentistry

Unmatched simplicity of use:

- Pre-sets for over 40 applications
- Intuitive user navigation
- Balanced and weightless OPTOflex arm
- Nd:YAG handpiece detection system
- Er:YAG scanner ready

Journey into a new dental experience with speed, precision and great results.
Visit www.lightwalkerlaser.com today!



Laser **versus** conventional therapies

Authors Cristiane Meira Assunção, Joanna Tatith Pereira, Renata Schlesner Oliveira & Dr Jonas de Almeida Rodrigues, Brazil



Fig. 1a

Fig. 1a DIAGNOdent 2095.

Introduction

In recent years, several studies have been conducted on the clinical applications of laser in dentistry. At the same time, there has been a marked emergence of organisations in support of the use of laser in dentistry. In the last decades, laser therapy has been used in dentistry as an adjunct or alternative to conventional approaches. In this paper, the following topics will be reviewed: the application of laser in caries prevention and diagnosis, hard- and soft-tissue treatments, and periodontal and endodontic procedures. There is a large research effort into new indications for laser in dentistry. It is expected that laser will become an essential component of the dentist's armamentarium.

While the technology was regarded as complex and of limited use in clinical dentistry in the past, a growing awareness of the usefulness of laser in the modern dental practice has been observed. Laser can be used as an adjunct or alternative to conventional approaches.¹ When comparing the use of laser with conventional therapies, three important areas must

be considered: safety, efficacy and effectiveness. From an ethical standpoint, it is important to use the best available evidence when making clinical decisions.²

Diagnostic laser applications

The most common methods for caries detection are visual and radiographic examination.³ However, visual examination is a subjective method that depends on the knowledge and clinical experience of the examiner.³⁻⁶ Several studies have demonstrated that radiographic examination demonstrates poor sensitivity to non-cavitated lesions.^{3,7-9} For this reason, fluorescence-based methods have been developed, aiming at the detection of occlusal and approximal carious lesions, for example DIAGNOdent 2095 (KaVo; LF; Figs. 1a-c) and DIAGNOdent 2190 (LF pen; Figs. 2a & b). They rely on the same principle: a laser diode emits red light at 655 nm and a photodetector quantifies the reflected fluorescence from bacterial metabolites (fluorophores) in carious lesions, showing values ranging from 0 to 99.^{3,9}

A study that assessed the performance of a visual method, radiographic examination and fluorescence-based methods in detecting occlusal caries in primary teeth found that the visual method and VistaProof fluorescence camera (Dürr Dental; FC) exhibited better accuracy in detecting enamel and dentine carious lesions, whereas the visual method combined with LF, LF pen and FC better detected dentine lesions on occlusal surfaces in primary teeth, with no statistically significant difference among them.³

Another study compared the performance of fluorescence-based methods (FC, LF and LF pen), radiographic examination, and another visual

The logo for WFLD, The World Federation for Laser Dentistry, is located in the top left corner. It consists of the letters 'WFLD' in a bold, white, sans-serif font, with a red horizontal line underneath. Below the line, the full name 'The World Federation for Laser Dentistry' is written in a smaller, white, sans-serif font.

The World Federation
for Laser Dentistry

4th Congress of the European Division

Let there be light!

Brussels, July 11–12, 2013
www.wfldbrussels2013.com

You are cordially invited to participate
For information, please visit our website

Congress President:

Pr S. Nammour

International Organizing Committee

Chairman: Pr Roly Kornblit

Dr Boris Gaspirc (Slovenia)
Dr Peter Fahlstedt (Sweden)
Pr Anton Sculean (Switzerland)
Dr Miguel Vock (Switzerland)
Pr Ferda Tasar (Turkey)
Pr Sevil Gurgan (Turkey)
Pr Christopher Mercer (UK)
Dr Miguel Martins (Portugal)
Dr Marina Vitale (Italy)
Dr Sharonit Sahar-Helft (Israel)
Pr Lajos Gaspar (Hungary)
Dr Dimitris Strakas (Greece)
Dr Kallis Antonis (Greece)
Pr Matthias Frentzen (Germany)
Dr Frederick Gaultier (France)
Dr Gérard Navarro (France)
Pr Marita Luomanen (Finland)
Dr Peter Steen Hansen (Denmark)
Pr Julia Kamenova (Bulgaria)
Dr Emina Ibrahimimi (Austria)
Dr Anna Maria Yiannikou (Cyprus)
Pr Igor Shugailov (Russia)
Dr. Oleg Tysoma (Ukraine)
Pr Assem Soueidan (France)

Honorary Presidents:

Pr Lynn Powel; Pr Isao Ishikawa ,
Pr Hong Sai Loh, Pr Jean Paul Rocca,
Pr Norbert Gutknecht

International Scientific Committee

Chairman: Pr Carlo Fornaini (Italy)

Pr Jean Paul Rocca (France)
Pr Norbert Gutknecht (Germany)
Pr Paolo Vescovi (Italy)
Pr Umberto Romeo (Italy)
Pr Antoni J. Espana Tost (Spain)
Pr Josep Arnabat (Spain)
Pr Carmen Todea (Romania)
Pr Adam Stabholz (Israel)
Dr Thierry Selli (France)

Local Organizing Committee:

Chairman: Pr Roeland De Moor

Marc Tielemans
Daniel Heysselaer
Amaury Namour

Secretariat: Cristina Barrella Penna

Chairman for commercial relations & Promotion:
Pr Roly Kornblit

www.wfldbrussels2013.com

method called the International Caries Detection and Assessment System (ICDAS) II on occlusal surfaces. This study demonstrated that the combination of ICDAS and bite-wing radiographs yielded the best performance for detecting caries on occlusal surfaces.⁹

Caries prevention: Enhancing enamel resistance

In the past, several *in vitro* studies have shown that enhancing enamel demineralisation resistance can be achieved by irradiation with lasers. In a blind *in vitro* study, Ana et al. 2012¹ compared the effect of professional fluoride application with that of laser irradiation with regard to the demineralisation of enamel and fluoride formation and retention. The study found that both methods enhanced enamel resistance, and no side-effects were found. A greater concentration of retained calcium fluoride-like material was found in the laser group. Formation and retention of calcium fluoride were also improved with laser irradiation.

The wavelengths absorbed most strongly by dental enamel are the 9.3 and 9.6 µm carbon dioxide laser wavelengths. The reduction in acid dissolution of enamel is said to be caused by a loss of the carbonate phase of enamel crystals due to the heat of irradiation. Rechmann et al. 2011¹⁰ demonstrated that short-pulsed 9.6 µm carbon dioxide laser irradiation successfully inhibited enamel caries without any harm to the pulpal tissue of the teeth irradiated. The efficacy of carbon CO₂ laser irradiation regarding its long-term effect on caries resistances can be verified by further studies.

Hard-tissue applications: Caries removal

There is limited evidence to support the effectiveness of dental lasers in the removal of caries compared with rotary burs. In order to evaluate this, a systematic review of seven studies with adequate methodologies was performed.⁸ Two of the studies

found that there was no difference with regard to time taken for caries removal and cavity preparation. Four of the studies found that the laser took up to three times longer to perform these procedures. Four of the studies found that there were no differences between lasers and rotary burs with regard to pulpal effects. One of the studies found that dentists preferred the bur to the laser, and all the studies found that patients favoured the laser with respect to comfort. The studies found that adult patients prefer the laser, although the response from children was inconclusive. The results are not surprising, considering that local anaesthesia is often not needed when using a laser, making the overall dental experience more pleasant for the patient.¹⁰

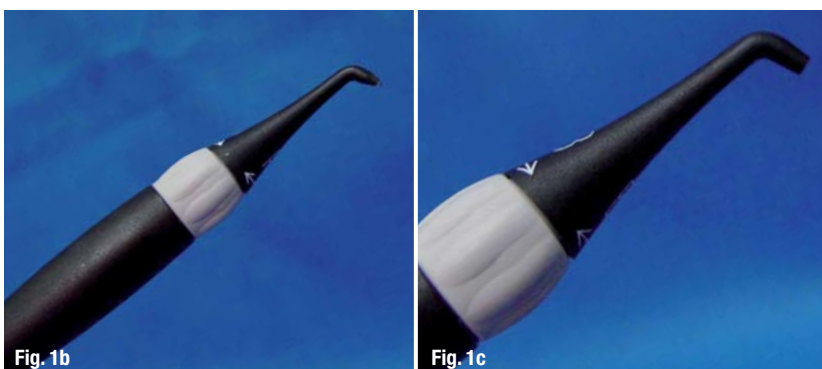
Endodontic laser procedures (disinfection)

The main causes of endodontic treatment failure are the presence of persistent micro-organisms and recontamination of the root canal owing to inadequate sealing.¹¹ The long-term success rate of conventional endodontic treatment depends on several factors, such as the diverse and complex anatomy of the root-canal system that consists of small canals diverging from the main canal. This complex system does not allow direct access during biomechanical preparation because of the canals' positioning and diameter.⁶ New antimicrobial approaches to disinfecting root canals have been proposed; these include the use of high-power lasers and photodynamic therapy, which works by dose-dependent heat generation. However, in addition to killing bacteria, they have the potential to cause collateral damage such as charred dentine, ankylosed roots, melted cementum, root resorption and periradicular necrosis.²

In order to compare the effectiveness of antimicrobial photodynamic therapy with standard endodontic treatment and combined treatment to eliminate bacterial biofilms present in infected root canals, a study was conducted on ten single-rooted freshly extracted human teeth inoculated with stable bioluminescent Gram-negative bacteria. It found that endodontic therapy alone reduced bacterial bioluminescence by 90%, while photodynamic therapy alone reduced bioluminescence by 95%. The combination reduced bioluminescence by up to 98%, and, importantly, the bacterial regrowth observed 24 hours after treatment was much less for the combination group than for the treatment groups individually.¹²

Alternatives to conventional therapies to improve the disinfection of root canals are Nd:YAG and Er:YAG lasers. One study evaluated the bactericidal

Fig. 1b_Tip A for occlusal surfaces.
Fig. 1c_Tip B for smooth surfaces.



efficacy of Nd:YAG and Er:YAG lasers in experimentally infected curved root canals and concluded that in the straight root canals the Er:YAG laser had a bactericidal effect of 6.4 to 10.8 % higher than that of the Nd:YAG laser. Conversely, the bactericidal effect of the Er:YAG laser in the curved root canals was 1.5 to 3.1 % higher than that of the Nd:YAG laser.¹³ These results suggest that further development of the endodontic laser tip and techniques are required to ensure its success.

_Periodontal laser procedures (disinfection)

Conventional periodontal therapy procedures include mechanical scaling and root planing, which has some limitations, especially in reducing bacteria inside deep pockets. In order to overcome the limitations of conventional mechanical therapy, several adjunctive protocols have been developed. Among these, laser has been proposed for its bactericidal and detoxification effects and for its ability to reach sites that conventional mechanical instrumentation cannot.¹⁴

Different lasers could be used in periodontal therapy for calculus removal, periodontal pocket disinfection, photoactivated dye disinfection of pockets and de-epithelialisation to assist regeneration.¹⁵

Several studies have indicated that the diode laser, with a wavelength of between 655 and 980 nm, can accelerate wound healing through the facilitation of collagen synthesis, promotion of angiogenesis, and augmentation of growth factor release. Furthermore, the diode laser has in vitro bactericidal and detoxification effects and can prevent ablation of the root surface, which theoretically reduces the risk of removal of normal root tissue.¹³

Sgolastra et al. 2012¹⁴ did not observe significant differences for any investigated outcome (clinical attachment level, probing depth, and changes in the plaque and gingival indices) in their systematic review. These findings suggest that the use of the diode laser as an adjunctive therapy to conventional non-surgical periodontal therapy did not provide additional clinical benefit. However, given that few studies were included in the analysis, the results should be interpreted with caution. Important issues that remain to be clarified include the influence of smoking on clinical outcomes, the effectiveness of the adjunctive use of the diode laser on microbiological outcomes, and the effect of adverse events. Future studies are required to assess the effectiveness of the adjunctive use of the diode laser, as well as the appropriate dosimetry and laser settings.



Fig. 2a




Fig. 2b

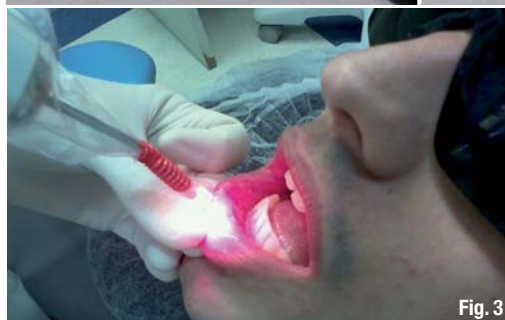


Fig. 3

Fig. 2a_Cylindrical tip for occlusal surfaces.

Fig. 2b_Wedge-shaped tip for proximal surfaces.

Fig. 3_Intra-red laser therapy for treatment of a primary herpetic infection in an adolescent patient undergoing chemotherapy (Therapy XT, DMC).

_Soft-tissue applications

There are numerous soft-tissue procedures that can be performed with laser. Two key advantages of this are reduced intra-operative bleeding and less post-operative pain compared with conventional techniques, such as electrosurgery. Certain procedures in patients with bleeding disorders are better suited to lasers with greater haemostatic capabilities.⁵

_Conclusion

Although the results of laser therapy are similar (in safety, efficacy and effectiveness) to those obtained with conventional methods, new techniques and devices have been developed. Laser could thus be an evidence-based and well-supported treatment option for the dentist in daily dental practice.

Editorial note: A list of references is available from the publisher.

_contact	laser
<p>Dr Jonas de Almeida Rodrigues School of Dentistry Federal University of Rio Grande do Sul Av. Paulo Gama, 110 Porto Alegre – RGS 90000-000 Brazil jorodrigues@hotmail.com</p>	