issn 2161-6558

International Edition • Vol. 11 • Issue 1/2021

roots

the international magazine of endodontics

1 2021

_clinical
Coronal leakage prevention

_technology
Root canal irrigation using a laser

_meetings
AAE21: 'Live & on-demand'

MEET THE **ALL-NEW**

SkyPulse®

A NEW GENERATION OF SPECIALIZED, INNOVATIVE, AND INTUITIVE ENDO LASERS

CALL 972-598-9000 OR EMAIL INFO@FOTONA.ORG TO SCHEDULE A VIRTUAL MEETING WITH A FOTONA SPECIALIST!

TECHNOLOGY & DESIGN TO ELEVATE YOUR PRACTICE

- **SWEEPS®** PHOTOACOUSTIC ENDO TXS
- HARD & SOFT TISSUE APPLICATIONS
- PHOTOBIOMODULATION / PAIN RELIEF
- FEATHER-LIGHT, FLEXIBLE UNIFLEX ARM
- COMPACT & PORTABLE DESIGN
- ADDITIONAL LASER WAVELENGTHS FOR **EXPANDED APPLICATIONS**
- & MUCH **MORE!**

SWEEPS® Photoacoustic endodontics

"Having the SkyPulse® Laser to perform SWEEPS® and to help stimulate healing after my procedures is ***profoundly different than anything I've ever experienced in endodontics."***

- Dr. Valerie Kanter, DMD, MS
Endodontist, Los Angeles, California

Fotona
Ultra Performance Lasers
FOTONA.COM/US

@FotonaLasers_Official
@FotonaLasersUS
@FotonaLasersUSA



editorial

05 Continuing education and changes
_John J. Stropko, DDS, Editor in Chief

clinical

08 Coronal leakage prevention to improve endo success
_Gregori M. Kurtzman, DDS

technology

18 Root canal irrigation using a laser
_Valerie Kanter, DMD

associations

20 Access to care program is launched

meetings

21 AAE21 goes 'live & on-demand'

milestones

22 Dr. John J. Stropko retires

about the publisher

23 _imprint

on the cover

Using laser technology available from Fotona for root canal therapy. (Photo/Provided by Fotona)

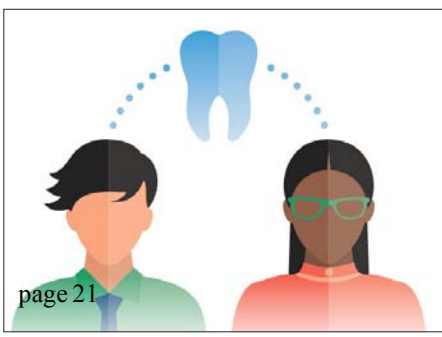

SIGN UP NOW

Dental Tribune e-newsletter

DENTAL TRIBUNE

The world's dental e-newsletter

news / live event coverage / online education / KOL interviews
event reviews / product launches / R&D advancements

www.dental-tribune.com

facebook.com/DentalTribuneInt

twitter.com/DentalTribuneIn

linkedin.com/company/dental-tribune-international

Continuing education and changes



John J. Stropko, DDS
Editor in Chief

How fortunate we are, to be members of such an incredible profession. In spite of the pandemic, the opportunities to learn new and better techniques are always available. With our current e-technology, it is possible to attend seminars, solely or as a group, anywhere in the world! So much is just waiting to help us on our journeys. For those who are relatively new to our profession, I would like to take this opportunity to share some significant changes that have occurred within the past 60 years.

Back in the mid '50s, it was common for the dentist to stand up while treating patients while using a foot to control the rheostat for the belt-driven, slow-speed (18-20K rpm) handpiece. Then in the early '60s, a few practices were fortunate to have access to the new Bordan Airotor, an air-turbine, high-speed handpiece that achieved an incredible 250K rpm! Teeth could be prepared in less time, but the same uncomfortable posture of standing up and using the foot-controlled rheostat was still the norm.

Over the next few years, the practice of dentistry was changing, especially the concern about the dentist's operating posture. Sitting down to treat a patient became more of a standard, and this led to several changes in office design and equipment. In 1967, my first office was equipped utilizing the latest design and technology. But one of the first things we became aware of was the wasted time and energy for the patient to use the cuspidor, so a high-speed evacuator system was installed to eliminate the problem. It was an exciting time!

Most practices grew rapidly, and "busyness" followed along with the realization of a certain dissatisfaction with everyday work life. Some popular continuing education courses were concerned with practice management. Management consultants could spend a few days at your office to enable the dentist(s) and their staff to more efficiently utilize the time spent with patients. "If you always think the way you have always thought, you will always get what you have always got!" Dental technology was advancing more rapidly. To keep pace with all the advancements, C.E. courses became more and more available. And most of the time after taking a course, additional investments had to be made for new materials, instruments or equipment to utilize the new skills or techniques. For example, after one seminar at the Pankey Institute I came home and bought loupes for magnification and a headlamp for improved lighting. C.E. courses were definitely a "game changer," and going into the office everyday became "fun again"!

It was not long before many states established mandatory minimum C.E. attendance requirements for the doctors. Also, minimum requirements were instituted by the ADA and AGD for acceptance of those C.E. courses. After 24 years of restorative practice I decided to become an endodontist, and in 1987 I became a student once again and received my Certificate of Endodontics from Boston University in June 1989.

As a new specialist, just out of training, I knew there was so much more to learn. One of my biggest concerns about my specialty training was that I did not learn anything different about apical surgery than before I started. Fortunately, there were some good C.E. courses in our profession to learn from, and I decided to start my journey.

One of my first endodontic C.E. courses was "Apical MicroSurgery," presented by Dr. Clifford Ruddle in Santa Barbara, Calif. As part of the two-day seminar, Dr. Gary Carr presented his work with the surgical operating microscope. The "hands-on" session using the SOM for the first time just blew me away! Within two weeks after the course, I had my own SOM with an assistant's scope attached, and we have never worked without one since. My wife, Barbara, and I spent the next several years as visiting instructors helping Dr. Carr at the Pacific Endodontic Research Foundation (PERF) in San Diego. Prior to the surgical

‘More advancements and changes are happening at an ever-increasing rate. There are masters of our profession in every country of the world. It is important to seek them out and to study under them.’

technique developed at PERF, it was common to leave the sutures in for seven to 10 days, there was a significant amount of swelling, and narcotics and antibiotics were routinely prescribed. With the new procedures, using the SOM, sutures were removed in 24 hours, NSAIDs were prescribed and antibiotics were usually not necessary.

The improved vision and direct lighting the SOM provided was the most significant advancement in dental treatment to date. To take advantage of what could now be done with the SOM, many new instruments were developed. Just a few examples were micro-scalpels, hemostats and ultrasonics. Due to unavoidable splashing while using the air/water syringe, the simple process of rinsing and drying conventional and surgical endodontic preparations led to the creation of the Stropko Irrigator, enabling precision and control for the procedure.

During the 1990s, computer technology gradually replaced hard copy paper records for patients, and scheduling became a more routine process. The influence of computers in the advancement of endodontics was incredible! Many in our profession today don't remember the "darkroom," the small, closet-like room in our offices where the developing and fixing of radiograph films was done. One of the most profound changes in dental technology was the advent of digital radiography. Cone-beam computed tomography (CBCT) became a huge asset for a better diagnosis, easier treatment and more predictable results. MTA was introduced as a new root-end filling material and to be used for perforation repairs.

At the turn of the century, changes had become the norm. More predictable treatments for invasive cervical resorption (ICR) were established. The minimally invasive technique for maintaining root structure and strength during conventional treatment was adopted. New bioceramic materials and sealers were developed. The GentleWave technique is one of the more recent developments to aid in the conventional cleaning and disinfection of the canal system.

The most current "high-speed" handpieces operate at 400K rpm for precision work. For applications requiring higher torque than a high-speed handpiece can deliver, a "low-speed" handpiece operating up to a max of 40K rpm can be utilized. Today, the laser is starting to supplant the handpiece. The use of laser low-level light therapy (LLLT) can be used postoperatively to decrease normal postoperative sequela and speed up healing. As a result, the future of dentistry is looking more and more pain-free.

Over all these years, I have been privileged to enjoy numerous opportunities to present lectures and seminars, visit hundreds of dental offices and make lasting friendships, both nationally and internationally. It was interesting to talk with different doctors and enjoy occasional "after-hours" casual conversations. When we were together, no matter the subject, it always ended up in dentistry! We are a curious group for sure, and after watching some of the finest operators at work, it was obvious that the common ingredient for excellence was the passion they had for what they did and how it should be done.

On a few occasions, I left an office I just visited and had the feeling that he or she should have retired some time ago. My prayer became that I would know when to quit. It happened about 10 years ago. It was a routine endodontic case. To finish the case to the level I always tried to achieve would have normally taken no more than two hours, but instead it took me more than four hours. I suddenly realized that my hand-eye coordination was not what it used to be, and my time had come to "put the handpiece down."

More advancements and changes are happening at an ever-increasing rate. There are masters of our profession in every country of the world. It is important to seek them out and to study under them. It is imperative for practitioners to participate in as many C.E. seminars as possible. Some changes that have to be made as the result of learning new techniques may seem complex and be a sizeable investment in both time and money, but the rewards to yourself, your staff and your patients will make it all worthwhile.

So, do not delay, make the changes today!

John J. Stropko, DDS

John J. Stropko, DDS
Editor in Chief

WE CONNECT THE DENTAL WORLD

Media | CME | Marketplace

www.dental-tribune.com

Coronal leakage prevention to improve endo success

Author_Gregori M. Kurtzman, DDS, MAGD, FAAIP, FPFA, FACD, FADI, DICOI, DADIA, DIDIA

_Introduction

Endodontic failure has been associated with coronal leakage within the canal system following obturation. A more likely determinant of clinical success or failure than apical leakage is leakage from the coronal aspect of the tooth.[1-3] This may be the result of leakage of the core material and restoration placed following endodontic treatment related to recurrent decay. The patient may delay placement of a crown on the tooth due to finances, waiting on available insurance benefits or a lack of urgency as the pain that led them to seek endodontic treatment has been eliminated.

Following obturation of the canal system, no matter what our intentions are, patients may delay restoration of the tooth that has been endodontically treated. Time and financial constraints often influence when the final restoration may be completed. Additionally, between appointments, an adhesive material will prevent leakage and subsequent contamination of the canal system.

Recent advances in obturation materials have demonstrated superior sealing of the canal system, as the materials are insolvent in oral fluids that plagued ZOE and CaOH-based sealers that were in wide use for decades. Yet without addressing the coronal aspect of the tooth following endodontic treatment, endodontic failure still may occur related to leakage originating coronally and progressing between the obturation material and canal walls, leading to apical pathology. Studies have confirmed that overall success of root canal treatment relates to a sound coronal seal.[4-7] Regardless of the obturation materials or method utilized, a properly cleaned, shaped and obturated tooth should be permanently restored as soon as possible.[8]

_Coronal leakage

The literature indicates that coronal leakage is a major determinant of endodontic success or failure, no matter what materials are placed into the canals to obturate the canal system. When the coronal portion of the tooth is not sealed with materials that are adhesive to tooth structure and are resistant to dissolution by oral fluids, over time endodontic failure may be inevitable.

It is not uncommon for patients to present with marginal decay around a crown on a tooth that has had prior endodontic treatment. Those teeth having had prior endodontic treatment do not have potential sensitivity that may be reported in a vital tooth that may indicate a problem under the crown, so the patient is not alerted to the need to seek dental treatment, allowing the leakage to progress. Coronal leakage may quickly lead to apical migration of bacteria even when leakage is of a short duration. Progression relates to what materials are present obturating the canal system and in the coronal aspect of the tooth. When the patient does present with marginal leakage related to recurrent decay, it might have been ongoing for an extended period of time. This may complicate treatment or may render the tooth non-restorable, necessitating extraction.

The literature has reported that exposure of a sealed canal system to artificial and natural saliva may lead to complete bacterial leakage within two

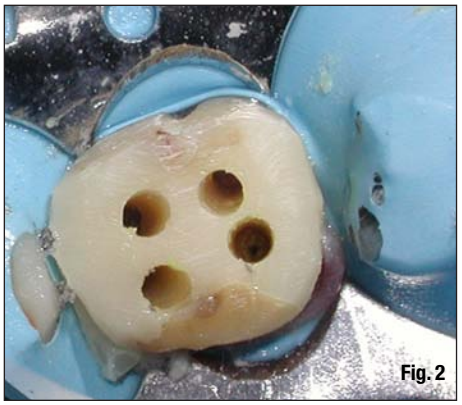

days.[9,10] Dye leakage can occur in as little as three days as reported in an in-vitro study.[11-13] It has been suggested that gutta-percha does not offer an effective barrier to crown-down leakage when exposed to the oral environment.[14-16] Additional studies on using gutta-percha and various sealers indicate that gutta-percha will allow bacterial leakage. But, use of an adhesive sealer may significantly slow or stop coronal-apical bacterial migration related to adhesion of the sealer to the gutta-percha within the obturated canal system.[17]

Staphylococcus, a gram-positive facultative anaerobe, is the predominant bacteria found in endodontically treated teeth undergoing coronal leakage with persistent apical periodontitis. This is followed by *Streptococcus* and *Enterococcus*, both of which are normal salivary flora.[18,19] Coronal leakage, thus, can provide a constant source of microorganisms and nutrients that can initiate and maintain periradicular inflammation and may well be the largest cause of failure in endodontic therapy.[20]

Endodontic obturation materials, no matter which are utilized, will not prevent coronal microleakage for an indefinite period of time.[21] A sample of 937 obturated teeth in one study on teeth that had not received restorative treatment during the previous year reported that the technical standard of both the coronal restoration and obturation were essential to periapical health.[22] It is not uncommon following endodontic treatment as a result of deficient composite resin fillings and secondary caries under restorations for coronal leakage to occur.[23]

Unfortunately, the endodontic obturation materials utilized over the past 50 years when challenged coronally have shown that they do not prevent leakage. A study reported on 45 teeth that were cleaned, shaped and obturated using a lateral condensation technique with gutta-percha and an endodontic sealer. The coronal portions of the obturation materials were placed in contact with *Staphylococcus epidermidis* and *Proteus vulgaris*, with the number of days required for these bacteria to penetrate the entire root canals determined. More than 50 percent of those teeth in the study became completely contaminated after a 19-day exposure to *S. epidermidis*, and 50 percent of those treated teeth were also totally contaminated when exposed to *P. vulgaris* at 42 days.[24] AH-26 and other commonly used sealers were compared after 45 days of exposure to oral fluids, and it was found that none of the sealers was capable of preventing leakage and coronal dye penetration.[25]

We can understand that the quality of the obturation material and coronal restoration are both essential to periapical health, as none of the present-day root canal sealers may hermetically seal "the root canal wall – gutta-percha obturation interface." The importance of perfectly sealing coronal restorations both between appointments to complete endodontic treatment and following endodontic treatment before a permanent restoration is placed needs to be emphasized and considered.[26]

_Pre-endodontic buildups

As has been outlined, coronal leakage is a major contributor to endodontic failure.[27,28] When significant coronal breakdown is present or replaced by a previously placed non-adhesively bonded direct restoration, a bonded core placed prior to instrumentation/disinfection and obturation of the canal system can greatly diminish the coronal leakage potential both during and after endodontic treatment. Isolation of the pulp chamber can be a challenging task when minimal coronal structure remains, and endodontic treatment is required as part of the oral rehabilitation (Fig. 1).

Coronal reinforcement has traditionally been addressed following the endodontic phase.[29] Yet a coronal bonded buildup can simplify the endodontic phase, strengthening the remaining tooth structure, decreasing the potential for further damage to the remaining tooth due to dam clamp placement or functioning on the tooth before a full coverage restoration can be placed. Sealing the pulpal floor to the outer periphery of the tooth and surrounding the canal orifices will decrease coronal leakage po-

Fig. 1_Severe coronal breakdown of a lower molar requiring endodontic therapy. (Photos/Provided by Dr. Gregori M. Kurtzman)

Fig. 2_Coronal pre-endodontic buildup achieved with canal projectors providing individual straight-line access into each canal.

Fig. 3_Temporary filling material has been placed over the shortened canal projectors placed back into the pre-endodontic buildup to seal the canals between appointments to complete the endodontic treatment.