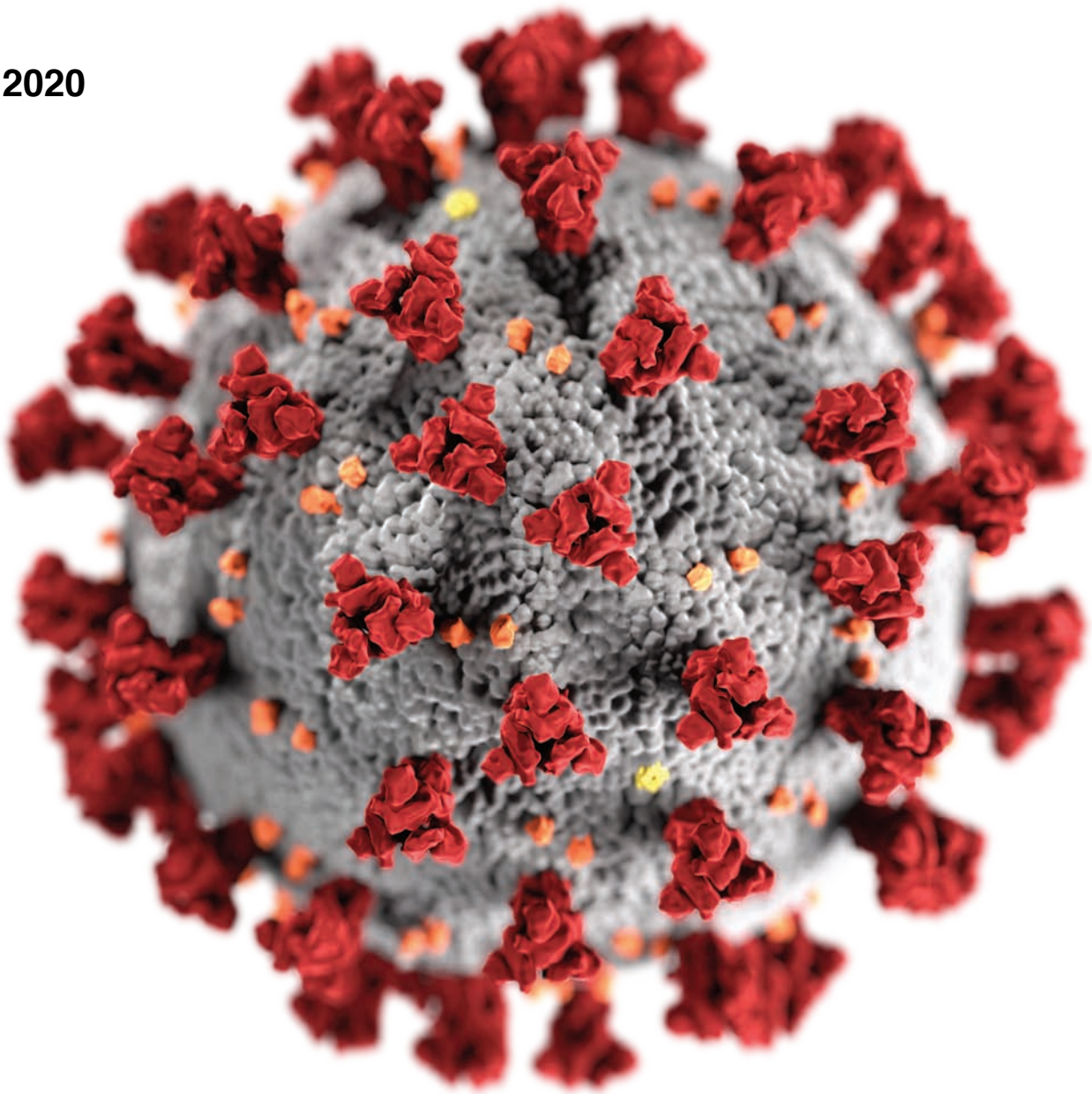


roots

the international magazine of endodontics

1 2020



_special report

AAE provides considerations for COVID-19 crisis

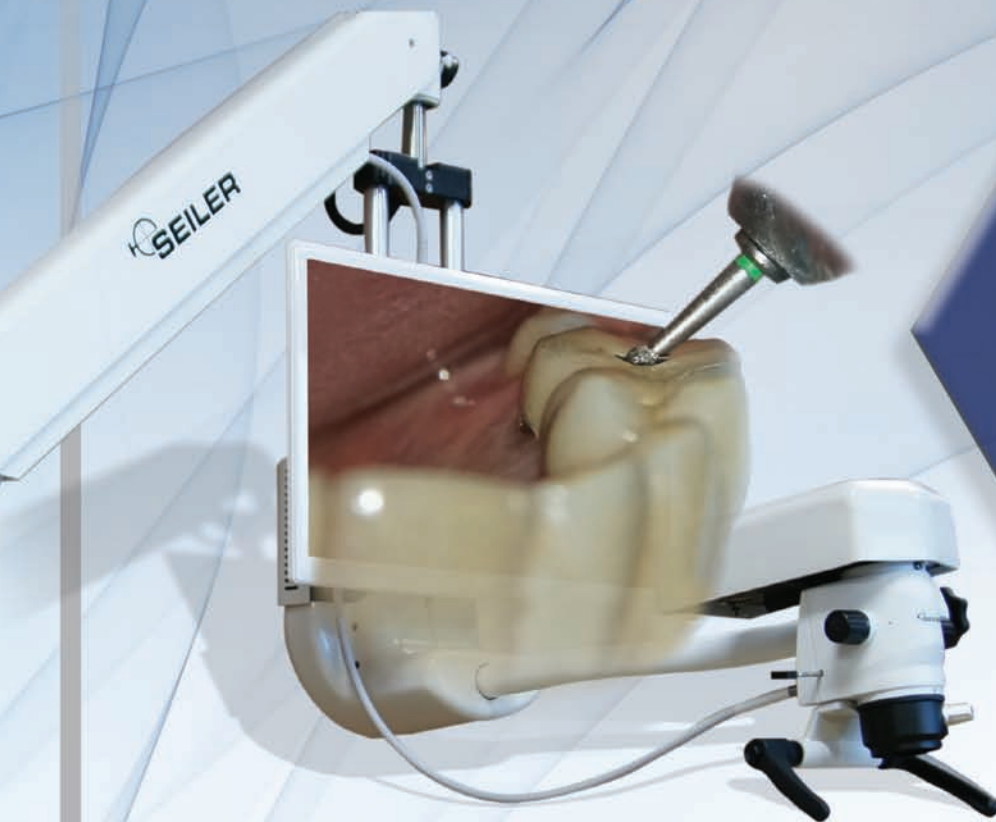_update

What the passage of the CARES Act means for endodontists

_case report

Bio-C Sealer and Bio-C Repair in periapical surgery

LIMITED TIME OFFER



24 MONTHS
0%
FINANCING
NO PAYMENT
FOR 3 MONTHS

Promise Vision 3D

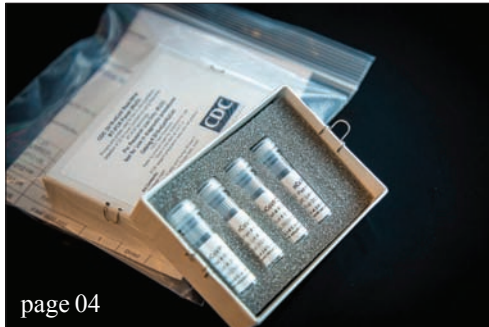~~\$37,995~~
\$34,995

- No binocular head
- 60 Frames per second with no latency
- Smaller learning curve than a microscope
- Quicker procedures and better ergonomics
- Improved patient awareness and rapport
- Bigger field of view and depth of field than a regular microscope

Act fast, as this is a one-time limited offer!



Toll Free: 800.489.2282 • Local: 314.968.2282 • Email: micro@seilerinst.com • www.seilerinst.com



page 04



page 06



page 07

| special report

- 04 AAE provides considerations for dental and endodontic care during **COVID-19 crisis**
_AAE Staff

| advocacy

- 06 AAE sends **message to governors** and state health officials
_Dr. Keith V. Krell

| update

- 07 What passage of **CARES ACT** means for endodontists

| case report

- 08 The use of **Bio-C Sealer and Bio-C Repair** in periapical surgery
_Renato Interliche, Douglas Giordani Negreiros Cortez and Clauber Romagnoli

| industry

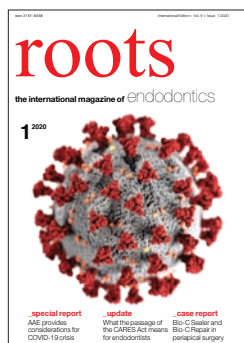
- 11 **Designed by an endodontist** specifically for endodontic procedures
_CJM Engineering Staff

| donated care

- 12 Endodontists from **all three Boston dental schools** donate root canals to local patients in need

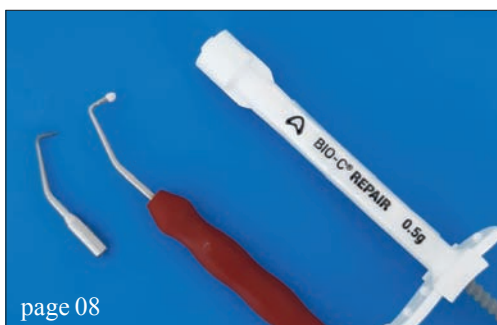| about the publisher

- 14 _imprint




| on the cover

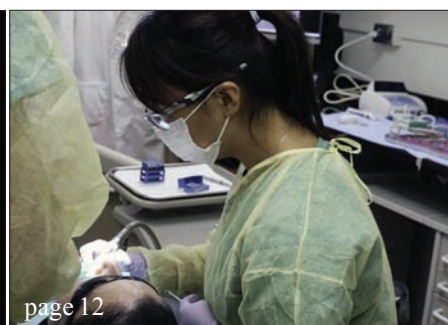
This illustration, created at the Centers for Disease Control and Prevention (CDC), reveals ultrastructural morphology exhibited by coronaviruses.



page 08



page 11



page 12

AAE provides considerations for dental and endodontic care during **COVID-19** crisis

The American Association of Endodontists (AAE) has announced several recommended considerations to its 8,000-plus endodontist and dentist members amid the COVID-19 outbreak. The announcement came at a time when other dental organizations revealed similar recommendations regarding dental care and emergency vs. non-emergency treatment.

"Given the rapid and global spread of the COVID-19 pandemic, it is the responsibility of everyone — health care providers and fellow citizens — to do everything possible to reduce the spread of this infection," said AAE President Dr. Keith V. Krell. "While there is no simple solution to balancing delivery of oral health care and minimizing the spread of the coronavirus, there is much we as endodontists and dentists can do to help reduce its spread."

Along with these recommendations, the AAE also published on its website, ahead of publication in the May issue of the *Journal of Endodontics*, a review, available at www.aae.org/specialty/clinical-resources/coronavirus-disease-19-covid-19-implications-for-clinical-dental-care/, co-authored by Dr. Ken M. Hargreaves, providing an

overview of the epidemiology, symptoms and routes of transmission of COVID-19. In addition, specific recommendations for dental practice are suggested.

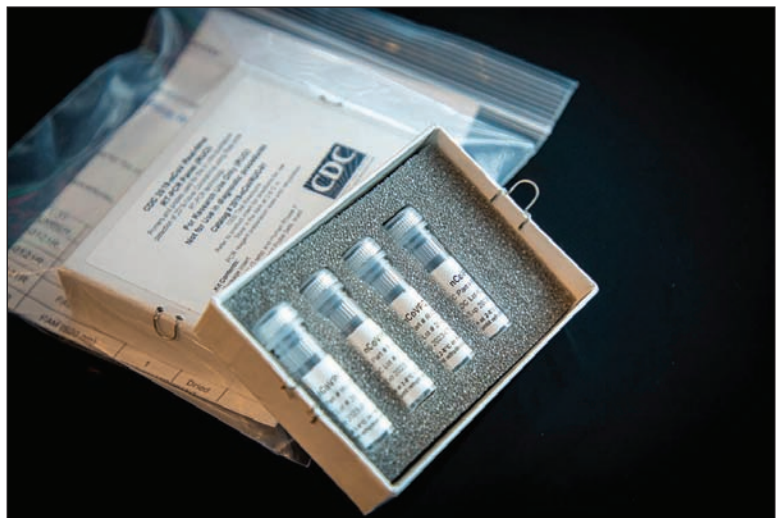"Advance publishing of this very important guidance has been critical in getting our members up to speed on the situation we're facing," Krell said. "In the coming days, we'll continue to respond accordingly as the situation changes."

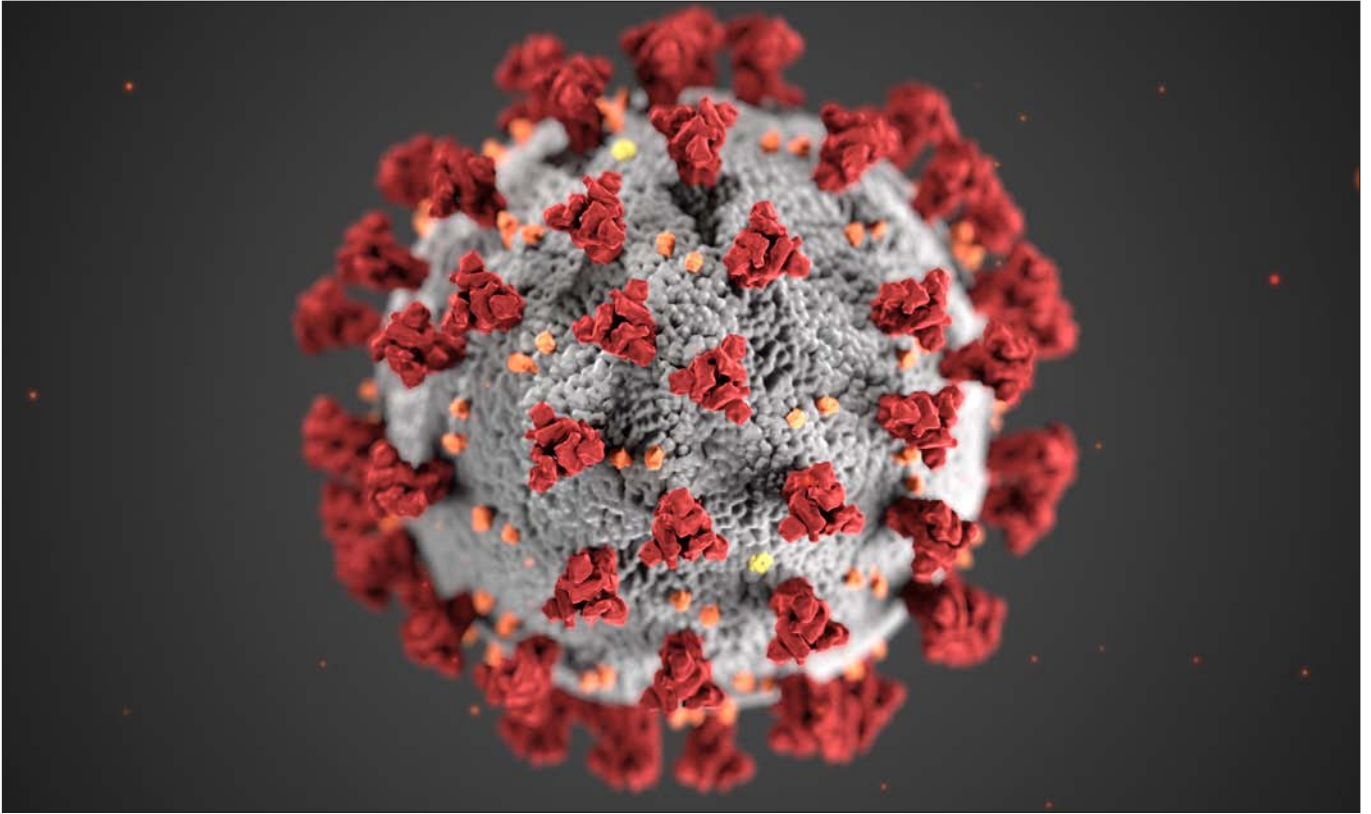
The AAE's recommendations are as follows:

- We agree with the CDC as well as professional organizations such as the ADA in recommending postponement of non-urgent oral health care for up to three weeks.
- Examples of urgent conditions requiring oral health care may include severe dental pain, abscess with lymphadenopathy or a dental infection-related fever.
- Some urgent conditions may be treated with appropriate analgesics or antibiotics. A recent report from the *British Medical Journal* recommends acetaminophen over ibuprofen. While providing pharmacological treatment, practitioners can continue to monitor patient responses by telephone contact.

This is a picture of CDC's laboratory test kit for severe acute respiratory syndrome Coronavirus 2 (SARS-CoV-2).

CDC tests are provided to state and local public health laboratories, Department of Defense (DOD) laboratories and select international laboratories. (Photo: cdc.gov)





‘Examples of urgent conditions requiring oral health care may include severe dental pain, abscess with lymphadenopathy or a dental infection-related fever.’

- If pharmacotherapy is insufficient, the recent review co-authored by Hargreaves summarizes considerations for appropriate dental care.

- As of now, the impact of the epidemic varies across the country. Accordingly, the recommendations of our members' local and state dental societies should be reviewed.

As this pandemic evolves, new recommendations will likely emerge. In addition to updates being made to [aae.org/covid](https://www.aae.org/covid), below we provide a list of websites with useful information:

- COVID-19 Situation Webpage: <https://www.cdc.gov/coronavirus/2019-ncov/cases-updates/summary.html>.

- ADA Coronavirus Resource Center for Dentists: <https://success.ada.org/en/practice-management/patients/infectious-diseases-2019-novel-coronavirus>.

- ISDS Issues Recommendations for Dental Offices Regarding COVID-19: <https://www.isds.org/news-details/2020/03/16/isds-issues-recommendations-for-dental-offices-regarding-covid-19>.

- New York State Dental Association: Novel Coronavirus (COVID-19): [https://www.nysdental.org/news-publications/novel-coronavirus-\(covid-19\)](https://www.nysdental.org/news-publications/novel-coronavirus-(covid-19)).

- California Dental Association: Urgent COVID-19 Updates: <https://www.cda.org/Home/News-and-Events/COVID-19-coronavirus-Updates>.

About the AAE

The American Association of Endodontists, headquartered in Chicago, represents more than 8,000 members worldwide. The AAE, founded in 1943, is dedicated to excellence in the art and science of endodontics and to the highest standard of patient care.

The association inspires its members to pursue professional advancement and personal fulfillment through education, research, advocacy, leadership, communication and service.

More information about the AAE is available at [aae.org](https://www.aae.org).

(Source: AAE)

This illustration, created at the Centers for Disease Control and Prevention (CDC), reveals ultrastructural morphology exhibited by coronaviruses. Note the spikes that adorn the outer surface of the virus, which impart the look of a corona surrounding the virion, when viewed electron microscopically. A novel coronavirus, named Severe Acute Respiratory Syndrome coronavirus 2 (SARS-CoV-2), was identified as the cause of an outbreak of respiratory illness first detected in Wuhan, China, in 2019. The illness caused by this virus has been named coronavirus disease 2019 (COVID-19). (Photo/CDC, Alissa Eckert, MS; Dan Higgins, MAMS)

AAE sends **message to governors** and state health officials



Keith V. Krell, DDS, MA, MS
President, AAE

The following message was sent to governors and state health officials on behalf of AAE's 8,000-plus members:

To Governors and State Health Departments,

The American Association of Endodontists (AAE) urges your Department of Health to recognize endodontists as essential emergency health care providers for distribution of necessary N95 masks and other personal protective equipment (PPE), for the following reasons:

1. Endodontists treat dental emergencies that become life-threatening if untreated;
2. Endodontists engage in emergency care in high aerosol environments; and
3. Endodontists mitigate the burden on medical and hospital emergency departments.

Endodontists treat dental emergencies that become life threatening if untreated

In 2007, a 12-year-old boy from Baltimore named Diamonte Driver made national news when he died because an untreated infected molar resulted in an abscess that spread to his brain. In 2011, a 24-year-old Cincinnati resident died of an untreated tooth infection. In 2017, a 26-year-old truck driver died of a tooth infection that had only been treated with pain medication. Unfortunately, these are not the only such cases.

The conditions that led to Diamonte's and the others' deaths are the very same emergency conditions that are treated effectively by endodontists in the dental practice. It is critical to understand that dental emergencies become life-threatening if they are not treated properly.

Endodontists provide emergency care in high-aerosol environments

Endodontics is the branch of dentistry concerned with "the morphology, physiology and pathology of the human dental pulp and periradicular tissues," specifically, the "treatment of diseases and injuries of the pulp and associated periradicular regions."¹

Put simply, endodontists treat pulpal conditions often produced as a result of untreated decay, often

exhibiting with abscessed pulp and often experienced as severe pain. Endodontic treatment includes surgical and non-surgical therapies, both of which require the use of a high-speed drill. The drill creates aerosols that have been affirmed by the CDC as capable of transmitting the Coronavirus. These aerosols are necessary in emergency dental care but require N95 masks for protection of the dentist and staff.

Endodontic care reduces the burden on emergency departments

In 2016, there were 2.2 million emergency department visits for dental issues in the United States; that's one every 14 seconds.² In 2009, the top two dental conditions that resulted in emergency department visits were dental decay (41.8 percent) and abscesses (37.4 percent); these are the conditions most effectively treated by endodontists.

Today, with the need for emergency departments to focus their limited resources on the COVID-19 pandemic, avoidable dental-related emergency department visits are especially problematic. Dentists, especially endodontists, must serve as the first point of contact for dental emergencies if we are collectively going to minimize the burden on the limited capacity of emergency departments. Moreover, by helping patients with dental emergencies through telehealth or emergency office visits that respect social distance, these patients avoid becoming agents and recipients of transmission of the Coronavirus in emergency departments where social distance is a challenge.

For the reasons explained here, it is critical for ensuring the safety of patients and for protecting valuable emergency department resources and staff that endodontists be included as essential emergency health care providers for distribution of necessary N95 masks and other PPE.

Sincerely,
Keith V. Krell, DDS, MA, MS,
President, AAE

1. <https://www.ada.org/en/ncrdscb/dental-specialties/specialty-definitions>.
2. https://www.ada.org/-/media/ADA/Science%20and%20Research/HPI/Files/HPIgraphic_0819_1.pdf?la=en.

(Source: AAE)

What passage of CARES Act means for endodontists

On March 27, 2020, a \$2 trillion COVID-19 economic relief bill called the Coronavirus Aid, Relief and Economic Security (CARES) Act was signed into law. The measure builds upon earlier versions of the CARES Act and is meant to be the third round of support from the government during the Coronavirus pandemic.

The American Dental Association (ADA) and the U.S. Small Business Administration (SBA) have provided the following information. Here's what endodontists, their staffs and residents need to know:

Economic Injury Disaster Loans (EIDL)

If your small business has suffered substantial economic injury and is located in a declared disaster area (<https://disasterloan.sba.gov/ela/Declarations/Index>), you may be eligible for the U.S. Small Business Administration (SBA) EIDL. Substantial economic injury means the business is unable to meet its obligations and to pay its ordinary and necessary operating expenses. The loan offers as much as \$2 million per applicant.

The SBA will also offer EIDL applicants an emergency grant of up to \$10,000 remitted within three days to immediately cover expenses for COVID-19 related sick leave, mortgage, rent and necessary overhead. The SBA will provide a total of \$10 billion in emergency grants, awarded on a first-come, first-served basis. EIDL applicants would not have to repay the SBA emergency grant if they are ultimately denied the EIDL loan. For more information or to apply, visit the SBA site, <https://disasterloan.sba.gov/ela/Information/EIDLloans>.

Loan forgiveness

A part of your federal small business loans may be forgiven tax-free in amounts spent for some payroll, sick leave, family leave and overhead expenses between Feb. 15 and June 6, and some debt obligations incurred prior to Feb. 15.

Retirement account withdrawals

If you as an endodontist, your spouse or your dependent is diagnosed with COVID-19, or face adverse financial consequences from being quarantined, furloughed, laid off or having work hours reduced due to the virus, then you may withdraw money from



The Coronavirus Aid, Relief and Economic Security (CARES) Act, signed into law on March 27, builds upon earlier versions of the CARES Act and is meant to be the third round of support from the government during the Coronavirus pandemic. (Photo: Tommy Schultz, [dreamstimefree.com](https://www.dreamstime.com))

retirement funds (i.e., 401K, etc.) of up to \$100,000 in 2020 without paying a tax penalty.

Student loan interest deferral

The act provides interest-free suspension of federal student loan through Sept. 30. This suspension will not be applicable to private loans. Contact your lender to verify eligibility. Additional benefits include income tax breaks for employees receiving student loan assistance payments, deferred social security tax, federal tax rebates, and higher unemployment benefits. Visit the ADA (<https://www.ada.org/en/publications/ada-news/2020-archive/march/senate-passes-cares-act>) to read more about these additional benefits.

For more information

Visit aae.org/covid for the latest AAE information on the Coronavirus pandemic.

(Source: AAE)

The use of Bio-C Sealer and Bio-C Repair in periapical surgery

Authors_Renato Interliche, Douglas Giordani Negreiros Cortez and Clauber Romagnoli

This case report aims to present a clinical case in which periapical surgery with root-end filling was performed with the use of new bioceramic-based sealers. The ease handle of these materials was verified as well as a fast bone repair in a short period. It was concluded that, if the results are maintained in the long term, these sealers may be the first choice for these clinical procedures.

Failures in endodontic treatments are not uncommon, and most of them result from an imperfect root canal decontamination during the first treatment.¹ Some endodontic failures cannot be saved by retreatment. As an example, we have cases of true cysts, extra radicular bacterial biofilm and fractures not detected during the initial treatment. In these clinical situations, complementation by root-end surgery may be the treatment of choice.

Another situation where we can use the root-end surgery to re-establish periapical health is when the tooth in question was recently rehabilitated but still has inadequate esthetics or there are financial concerns. In these cases, surgery is more useful and quick in resolving the situation.

Currently, the surgical modality indicated for such cases is the removal of the periapical lesion, a root-end resection followed by a root-end treatment and filling.

For the last step (root-end filling), several materials have already been used during the past few decades, including silver amalgam, zinc oxide eugenol-based sealer and the current bioceramic-based sealers. Such bioceramic-based sealers are derived from MTA and have improved properties when compared to it.

In addition to the excellent biological properties, these new sealers are more user friendly. They are ready-for-use and can be used in a humid environment.

The aim of this case report is to present a clinical case of a root-end surgery in the maxillary cuspid using the association of Bio-C Sealer and Bio-C Repair.

The patient G. L., female, 56 years old, without any systemic health problems, was referred to the private office for clinical evaluation and

management of left maxillary cuspid (tooth 23). It was observed on the periapical X-ray the presence of a radiolucent lesion and a possible perforation in the buccal face resulting from an attempt to access and remove the root canal post.

After clinical and radiographic examination, a cone beam computed tomography was performed for better diagnosis and to establish the treatment plan for the involved tooth (Fig 1).

By observing the perforation and root canal deviation by the previously installed root canal post, it was suggested to perform a root-end surgery to remove the periapical lesion, followed by a root-end resection, treatment and filling. Concomitantly, the root canal perforation would be restored on the buccal surface with photoactivated composite.

After local anesthesia (Articaine, DFL, Rio de Janeiro, Brazil), an intrasulcular gingival incision was made between teeth 24, 23 and 22 on the buccal aspect, followed by a perpendicular relaxing incision in the distal region of tooth 24. The triangular flap was raised, and the lesion was located.

The lesion was removed with curettes, and the root apex was sectioned using an ultrasonic tip (Blade Sonic – Helse Ultrasonic, Santa Rosa do Viterbo, Brazil). The root-end treatment also was made using an ultrasonic tip (E1 – Helse Ultrasonic, Santa Rosa do Viterbo, Brazil) with a depth equal to the active part of the tip.

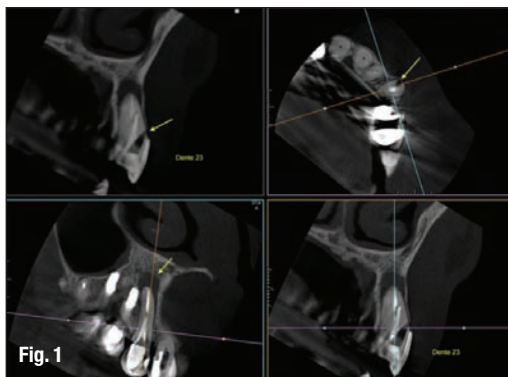
After the root-end treatment, a sufficient amount of Bio-C Sealer was inserted into the cavity in order to completely fill the cavity preparation. This was achieved with a previously curved irrigation needle following the angles of the ultrasonic tip (Fig. 2).

With the cavity filled with more flowable root canal sealer (Bio-C Sealer), a denser cement plug of Bio-C Repair was accommodated, using a surgical plugger (Fig. 3).

After the complete filling of the cavity is observed, the material excess is removed by washing the cavity with saline solution (Fig. 4).

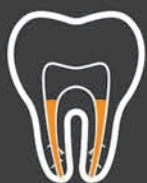After the clot formation, interrupted sutures were performed, and the patient was medicated with antibiotics and anti-inflammatories for five days. Chlorhexidine mouthwashes were also recommended. The sutures were removed after 10 days. The radiographic follow-up was performed after 30 and 90 days (Figs. 5, 6).

Fig. 1 A cone beam computed tomography was performed for diagnosis and to establish a treatment plan. (Photos/Provided by Renato Interliche, Douglas Giordani Negreiros Cortez and Clauber Romagnoli)





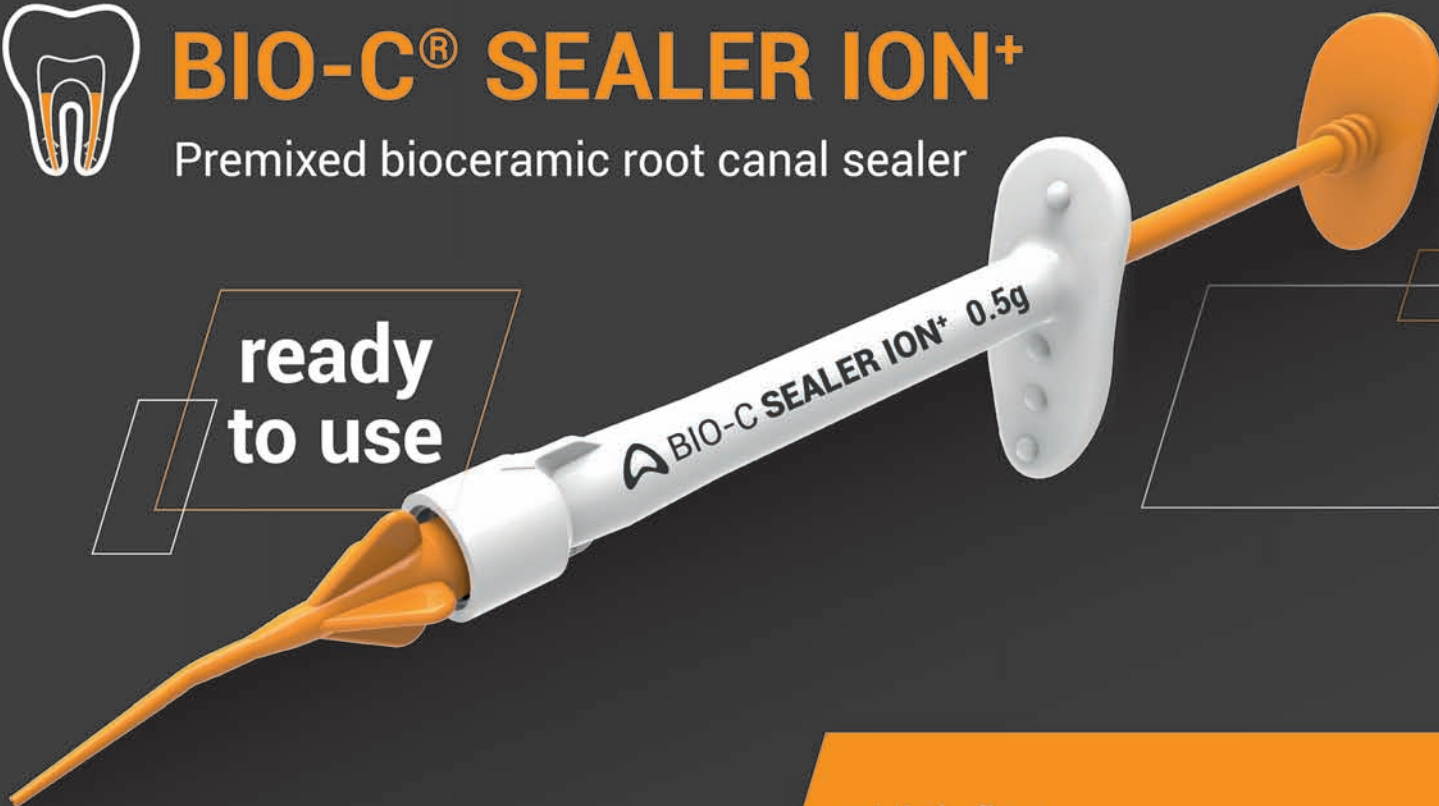Finally there is a choice!!!



BIO-C[®] SEALER ION⁺

Premixed bioceramic root canal sealer

ready
to use



BIO-C[®] SEALER ION⁺ is a ready-to-use improved calcium silicate bioceramic root canal sealer.

The premixed presentation makes it easier to be applied and simplifies the obturation saving time.

- High flow
- Cold and warm techniques
- Biocompatible
- Low solubility
- Sets in presence of moisture
- Non staining
- Compatible with warm gutta-percha techniques



Code: 704-0082 - 4 preloaded syringes with 0.5 g each and 20 disposable intracanal tips.

Available through

 **HENRY SCHEIN[®]**
DENTAL
(1-800-372-4346)



For Canada
(1-800-265-3444)