

# roots

international magazine of endodontics



## **clinical review**

Use of 3D technology in the diagnosis and treatment of endodontic disease

## **trends & applications**

The use of pre-mixed bioceramic materials in endodontics

## **case report**

Apicectomy of an endodontically compromised central incisor



A GREAT “PATH”  
LEADS TO YOUR GOAL

HAVING DIFFICULTIES?

**D-FINDERS™**

GUIDES YOU WHERE OTHERS CAN'T

CONTACT MANI FOR MORE INFORMATION:

[WWW.MANI.CO.JP/EN](http://WWW.MANI.CO.JP/EN)

[DENTAL.EXP@MS.MANI.CO.JP](mailto:DENTAL.EXP@MS.MANI.CO.JP)

**Dr Gary Glassman**

Guest Editor



# Better **technology** and referral relationships—**Are they related?**

**Advancements in technology** have made it easier for dental professionals to deliver successful endodontic treatment. Nevertheless, endodontics continues to be a specialty that is best handled by trained experts.

It is appropriate for a general dentist to perform endodontic treatment on a patient when he or she is properly trained to perform the said procedure, has the appropriate equipment and possesses the requisite skill set for the treatment. However, if there is any doubt that the clinician can perform the procedure to the same standard of practice as an endodontic specialist, the case should be referred out. The American Association of Endodontists offers its case difficulty assessment form and guidelines to help general practitioners with case selection.

Rapid advancements in endodontic technology have permitted dental professionals to enjoy higher success rates. Patients can retain their teeth for as long as possible, reducing the need for retreatment and/or extraction, and thereby limiting the high costs they once faced.

The dental operating microscope is a prime example. As it enables clinicians to visualise the anatomy of the pulp chamber, they can locate the canal anatomy more proficiently and offer minimally invasive treatment by keeping access openings as small as practical while maintaining the structural integrity of the tooth. In addition, practitioners are able to maintain a more ergonomically favourable position, thereby reducing stress on their back and neck.

Ultrasonic instruments with specially designed endodontic tips allow clinicians to uncover calcified canals,

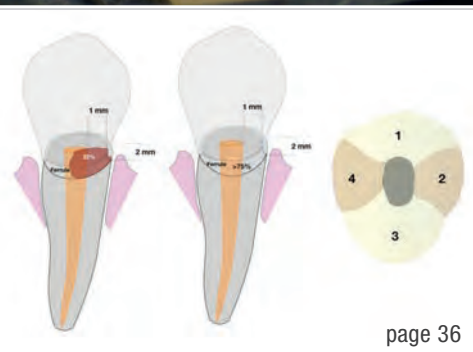
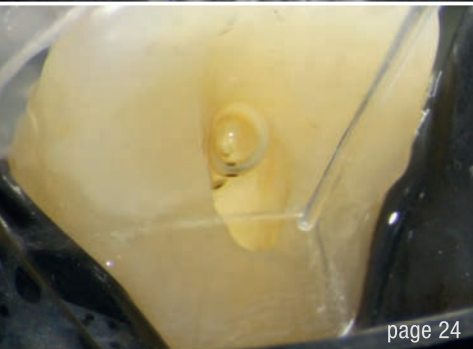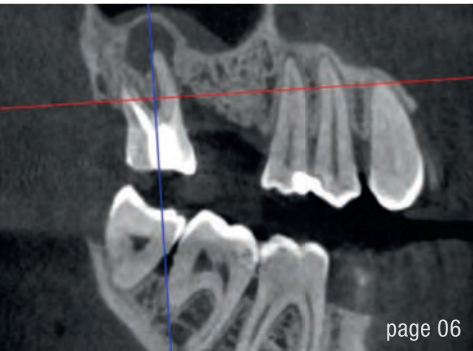
remove pulp stones, refine access preparations, and remove posts and cores. They aid in the debridement of the root canal system during irrigation protocols in a controlled and predictably safe manner.

Cone beam computed tomography (CBCT) offers unprecedented accuracy and acuity. We can visualise the tooth in 3D; it is like a road map to the anatomy of the root canal system. In addition, the resolution of the CBCT is higher than that of traditional radiography, allowing the detection of periradicular pathology, which may have otherwise gone undetected. The type, location and extent of internal/external resorption can now be definitively diagnosed and the relationship of normal anatomical structures can be assessed with ease.

Dental service organisations offer specialists like endodontists an opportunity to connect with general dentists and their patients, who may require advanced care. An open dialogue between endodontists and their general dentist colleagues will help ensure that patients receive the best possible treatment. Plus, the accessibility of the patients through their general dentist's office is often more practical and convenient, both for the patients and the practitioners.

Communication and continuing education are key components of the relationship between endodontists and general dentists, noting that a true partnership between practitioners ultimately leads to better patient care.

Dr Gary Glassman  
Guest Editor



Cover image courtesy of Produits Dentaires SA (www.pd-dental.com).



**editorial**

Better **technology and referral** relationships—**Are they related?** 03  
Dr Gary Glassman (Guest Editor)

**clinical review**

Use of **3D technology in the diagnosis** and treatment of endodontic disease 06  
Dr Fabio Gorni

**case report**

**Apicectomy** of an endodontically compromised **central incisor** 12  
Drs Georgi T. Tomov & Mutlu S. Turkkkan

**industry report**

Laser enucleation of a **radicular cyst** with the **PIPS protocol** 16  
Dr Betül Göfteci

**materials**

**Obturation materials** in a state of flux—fluid boundaries between **biocompatibility and bioactivity** 20  
Dr Barbara Müller

**trends & applications**

**Irrigation** in curved canals 24  
Drs Francesca Cerutti & Riccardo Tonini

The use of **pre-mixed bioceramic materials** in endodontics 28  
Drs Gilberto Debelian & Martin Trope

**opinion**

**Next-level endodontic restorative continuum—a new perspective** 36  
Root to restoration  
Dr Kenneth S. Serota

**practice management**

Successful **communication** in your **daily practice** 44  
Part VII: Special services for VIP patients  
Dr Anna Maria Yiannikos

**manufacturer news** 46

**interview**

**“Join our ride!”**—VDW celebrates its 150<sup>th</sup> anniversary 48  
Interview with Sonja Corinna Ludwig

**meetings**

**IDS 2019: Leading global trade fair of the dental industry reaffirms its position** 50  
International Events 54

**about the publisher**

submission guidelines 56  
international imprint 58



# IT'S TIME FOR TRUE LOW DOSE CBCT

## X MIND trium

50%  
dose reduction\*  
without compromising  
3D image quality

3D  
mapping of bone  
density for improved  
success rate

75µm  
ultra high resolution image  
for reliable diagnosis



TRUE  
LOW DOSE

\*Ratio based on DAP measurements from standard X-Mind trium settings 90kV-8mA-300prjs

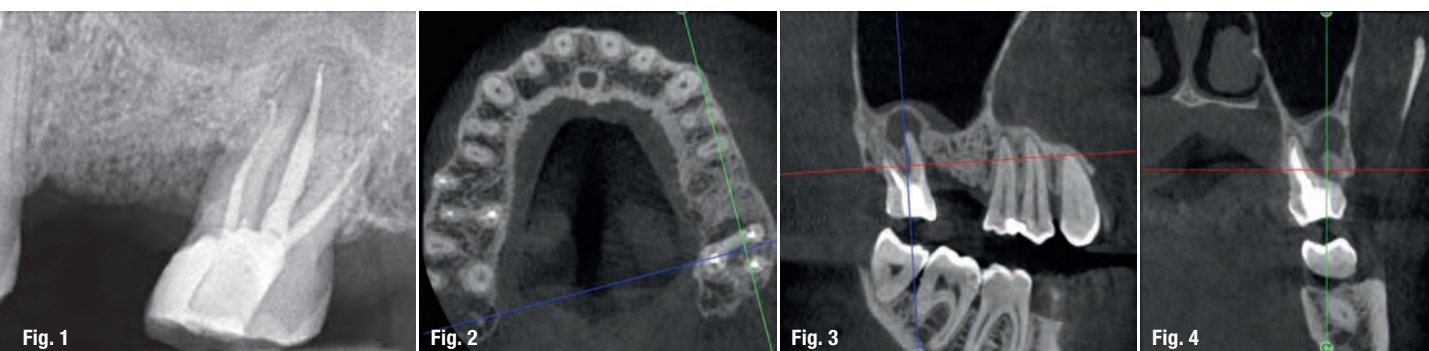
X-Mind® trium, a 3-in-1 extraoral imaging system (CBCT 3D, Panoramic and Cephalometric). This medical device is a class IIb device according to the applicable European Directive in force. It includes CE marking. Notified body: DNV GL NEMKO PRESAFE AS - CE 2460. This medical device for dental care is reserved for healthcare personnel; it is not covered by health insurance providers. This equipment was designed and manufactured in accordance with an EN ISO 13485-certified quality assurance system. Please read the user guide carefully. Manufacturer: De Götzen - a company of ACTEON Group. For dental professional use only.

DE GÖTZEN® | A company of ACTEON® Group  
Via Roma 45 | 21057 Olgiate Olona VA  
Tel + 33 39 0331 376760 | Fax + 39 0331 376763  
E-mail: [info@acteongroup.com](mailto:info@acteongroup.com) | [www.acteongroup.com](http://www.acteongroup.com)



# Use of 3D technology in the diagnosis and treatment of endodontic disease

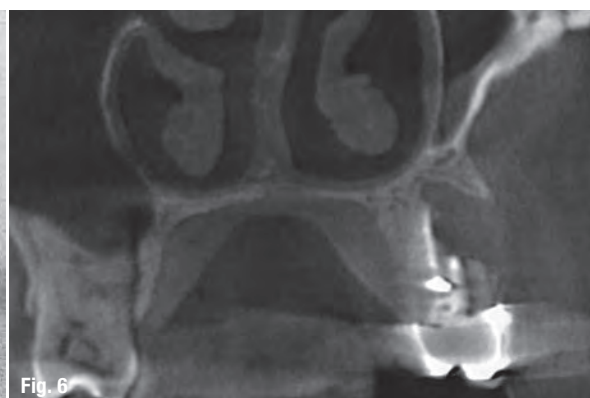
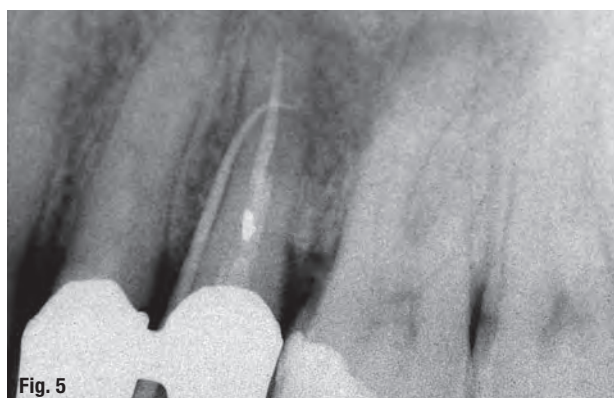
Dr Fabio Gorni, Italy

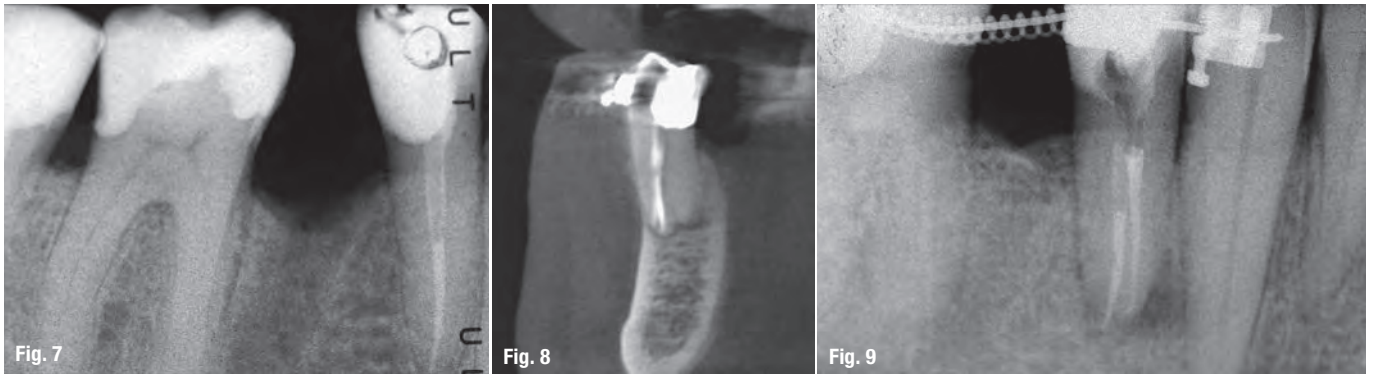


In recent years, the technology associated with endodontic therapy has undergone a veritable revolution. For years, intraoral radiographs were used as the basis for diagnosis and for planning root canal therapy, despite the fact that these images did not provide a faithful reproduction of the endodontic anatomy. This created a series of technical problems, which, although they could be partly overcome by the operator's personal experience, to some extent remained unresolved, especially in the field of diagnosis.

I personally started using cone beam computed tomography (CBCT) for endodontic purposes more than ten years ago. Although the machines that I used then were far from ideal for this specific purpose, the possibilities offered today by increasingly sophisticated technologies have greatly improved my diagnostic and interventional capabilities. In order to make an accurate diagnosis, an

endodontist needs to perform a highly detailed assessment of the canal and pulpal anatomy, which requires high-definition examination techniques and software that enables the endodontist to rotate the tooth accurately and easily. This may seem obvious and trivial, but is not. Indeed, over the past ten years, I have had the opportunity to work with a large number of devices and dozens of software programmes, but only very few have proven to be suitable for endodontic purposes. For a few years now, I have been using ACTEON's trium technology, with extremely satisfactory results. The imaging is very accurate and highly detailed, and above all, the user friendliness of the ACTEON Imaging Suite makes it possible to identify even slight differences between the different radiographic slices, differences that are of paramount importance for making a correct endodontic diagnosis and for the therapeutic decision-making process itself. Clinician experi-

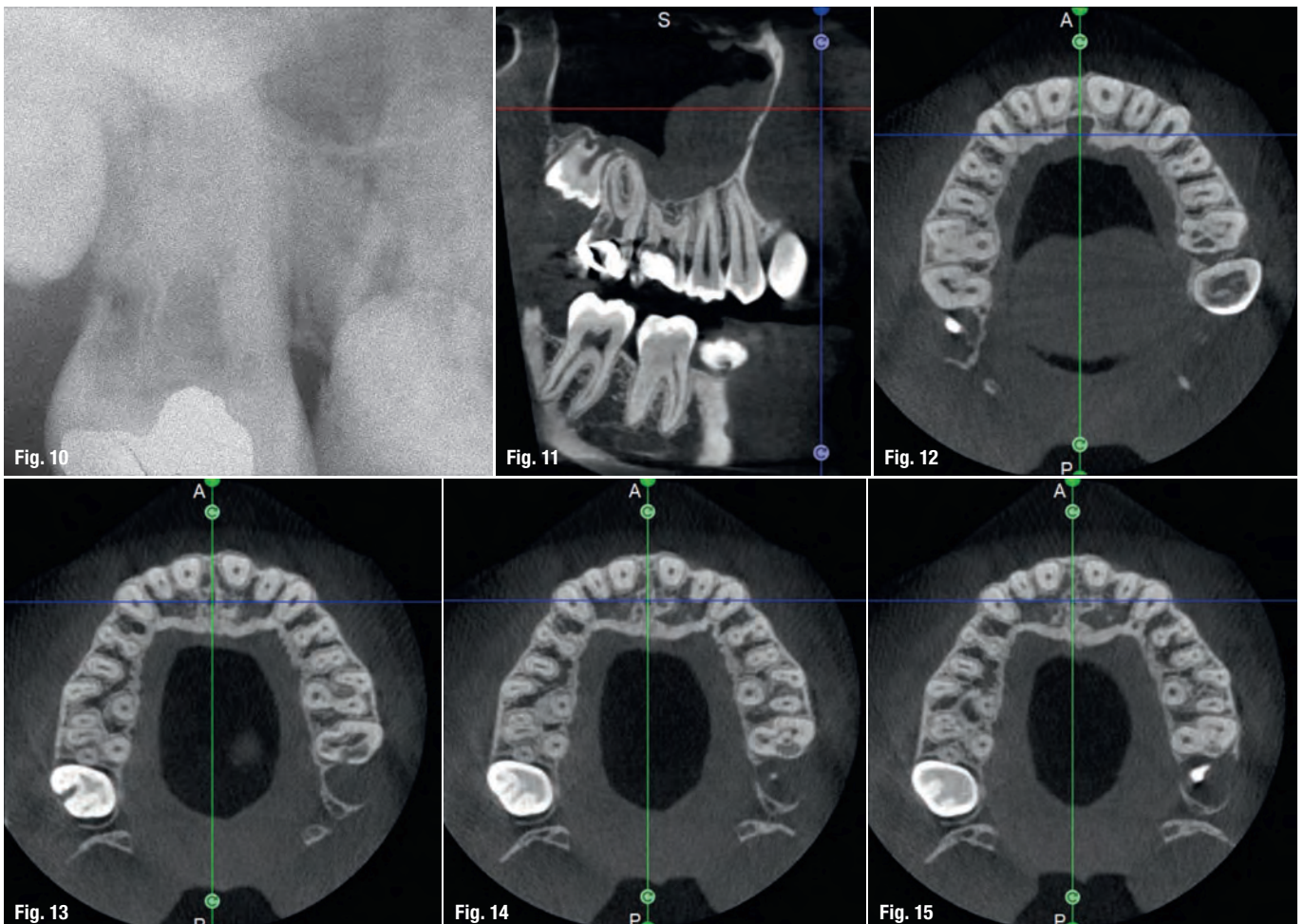


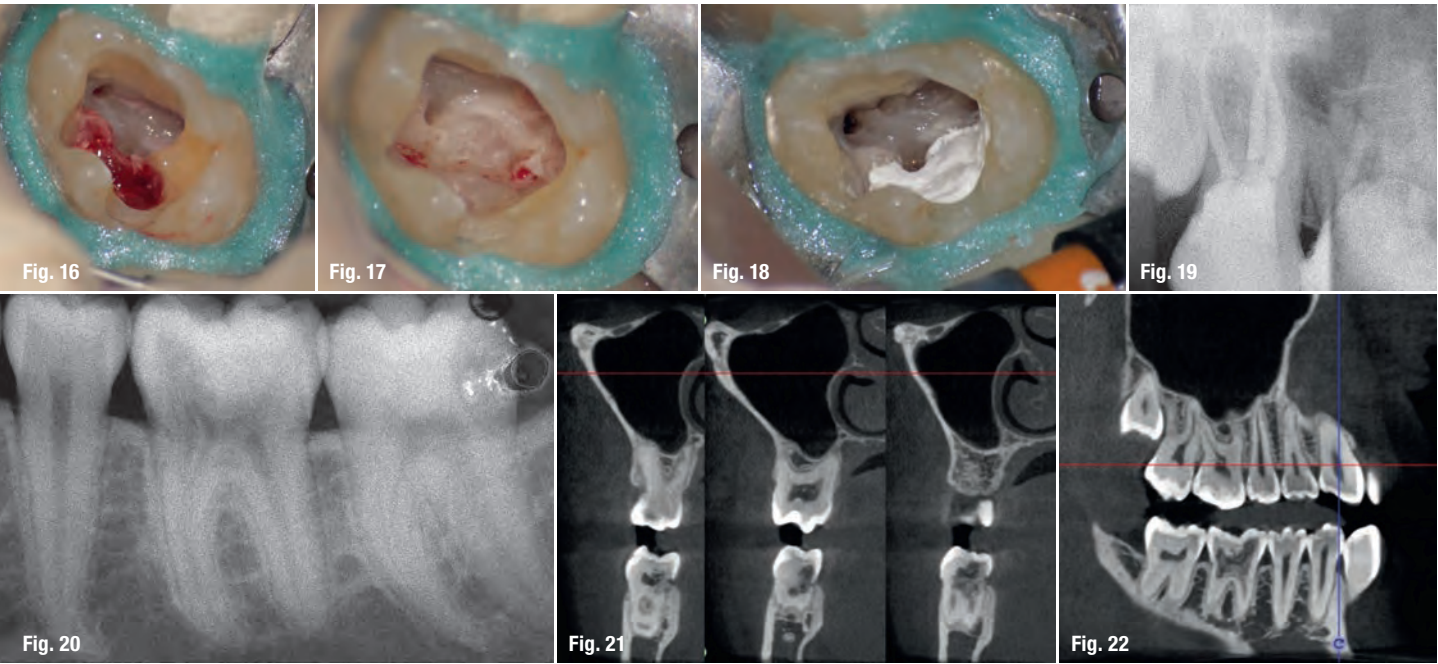


ence alone is not sufficient for establishing the correct approach to be adopted in the case of endodontic disease, and very often clinical cases that were initially scheduled for orthograde treatment, after CBCT assessment, turn into cases for endodontic surgery or vice versa. We can therefore state that the capability we have now of performing these studies in a quick and easy manner has drastically reduced the number of incorrect diagnoses and, consequently, the number of clinical errors.

The case with which I would like to start my clinical review is a perfect example of how difficult it is to establish

the origin of the patient's symptoms on the basis of an intraoral radiograph alone. Not only does the 2D study fail to establish with certainty the presence of a lesion, but more importantly, it is impossible to establish the size, morphology and type of the lesion. An analysis of the 3D imaging, however, provides a clear picture of the clinical situation: the coronal and sagittal slices revealed the presence of a large lesion extending from the apex of the mesial root of this molar to the furcation, while the axial slices allow us to conduct a precise analysis of the endodontic anatomy and, in particular, the shape of the mesial root, which in this case was fused with the palatine





root. A full overview of the case can, therefore, guide the decision-making process and direct the treatment plan towards a specific type of treatment (Figs. 1–4).

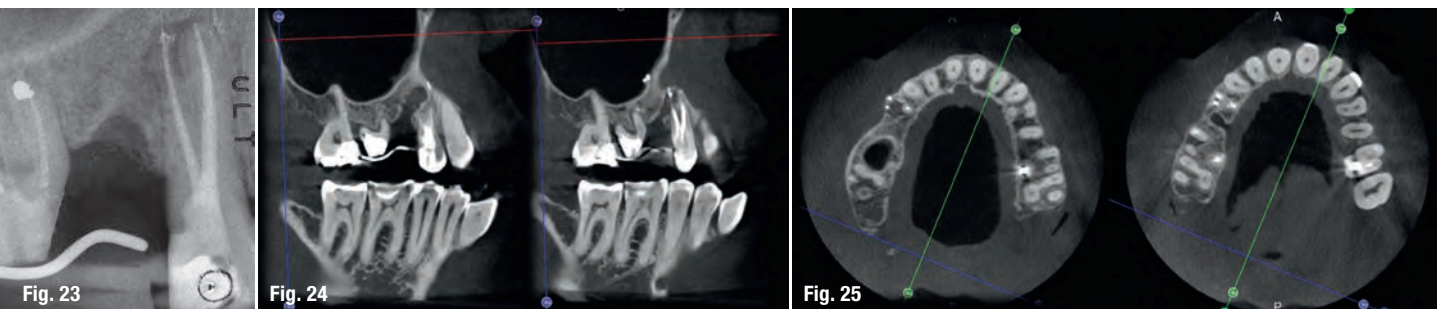
In the maxillary premolar shown in Figures 5 and 6, the fistulogram revealed the presence of an apical lesion that extended coronally to approximately the middle third of the root. The clinical decision could, therefore, propend towards orthograde retreatment; however, CBCT gave us a very different view of the situation compared with the radiograph, as it indicated that a prior treatment had irreversibly damaged the tooth, which would therefore have to be extracted.

The situation was entirely different for the mandibular premolar shown in Figures 7 to 9, where, in the absence of any radiological signs of a lesion and despite the apparently correct endodontic approach adopted by another colleague, the patient complained of persistent pain which was both spontaneous and triggered by percussion of the tooth. In this case, the previous excellent root canal therapy would suggest an endodontic surgery approach, which could guarantee a higher success rate than retreatment. Given this diagnostic doubt, it was decided

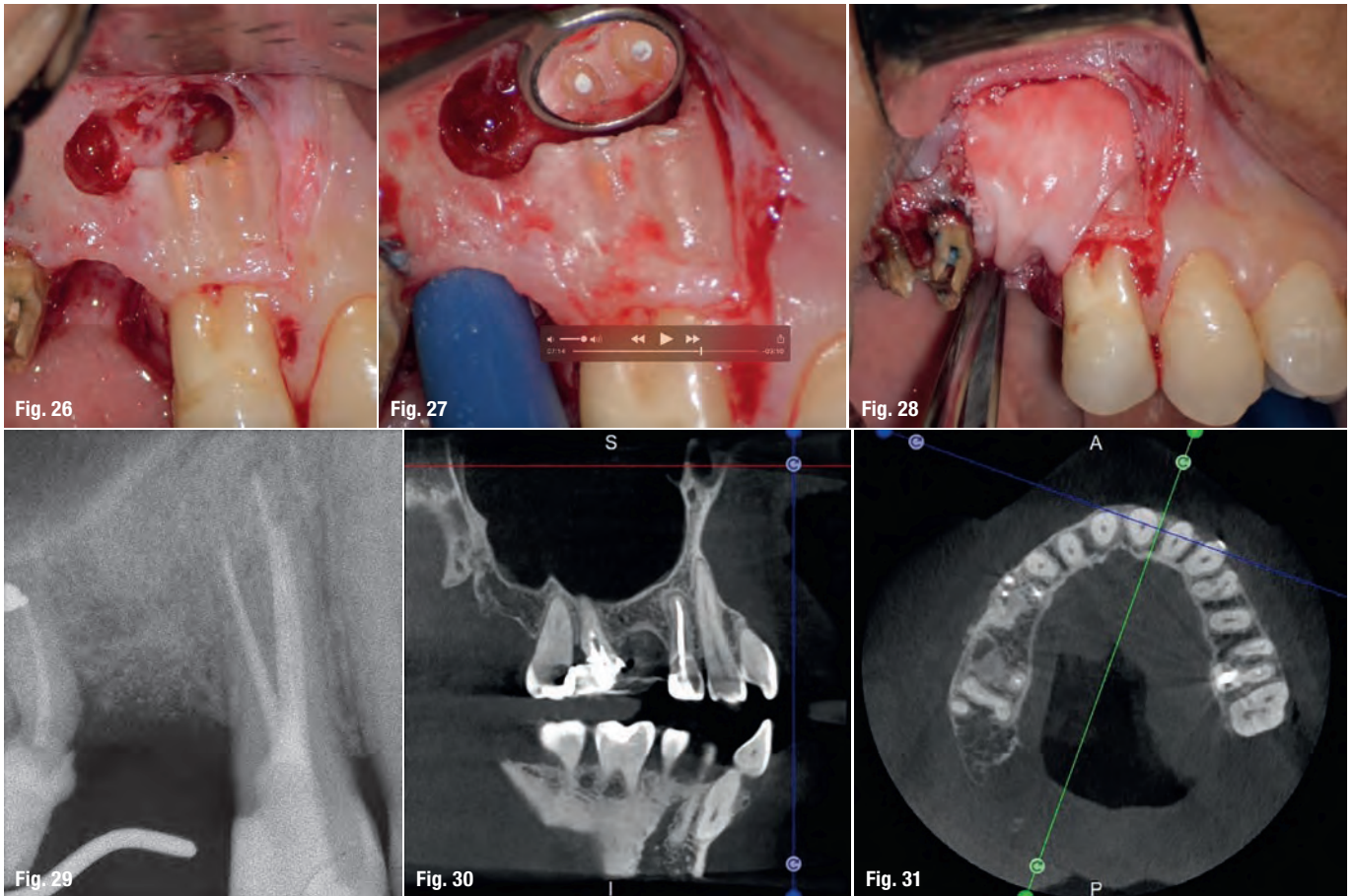
to perform a 3D study, which revealed an endodontic lesion caused by an untreated lingual canal. This correct diagnosis, thus, made it possible to perform selective intervention on the remaining pulp, leading to successful treatment of the untreated canal.

Undeniably, one of the most complex conditions to treat is external invasive root resorption, where the extent of the defect affects the treatment options. It therefore becomes sensible to perform a preoperative evaluation of the location and extent of the resorption, and the potential for recovery, thus, depends on correct 3D planning of the procedure, which can only be achieved after examination of the CBCT images. It is very important to be able to view the slices of the tooth correctly in all three planes, focusing in particular on the axial slices, which will prove to be strategic from an endodontic diagnosis point of view.

Comparing the two teeth shown in Figures 10 to 22 demonstrates just how important it is to analyse all the slices of the CBCT study correctly. We can see that, in the maxillary molar, the lesion penetrates into the pulp chamber, starting from the root's distal surface, but remains within the coronal third of the tooth, without sig-







nificantly affecting the integrity of the pulp chamber floor (Figs. 10–15). The clinical images illustrate the operative treatment phases, from resorption debridement through to repair using bioceramic cement (Figs. 16–19). The final radiographic images confirm the validity of the conservative and endodontic treatment of the tooth. The situation is completely different for the mandibular molar, where the evaluation of the CBCT scan clearly reveals the extent of the resorption, which invades the pulp chamber floor until the furcation, a situation that cannot be deter-

mined from observing the preoperative radiograph alone (Figs. 20–22).

Preoperative CBCT evaluation is useful in cases requiring a surgical approach, not only in order to confirm the presence of a lesion but also to plan the procedure and, in particular, identify the type of surgical incision to be used, based on its size and location (Figs. 23–25). This specific case is characteristic of this situation. The intraoral radiograph did not make it possible to ascertain

