

implants

international magazine of oral implantology

case report


Non-invasive measurement of the height and thickness of the peri-implant soft tissue

research

Immune sustainability on titanium implants?

interview

Digital dentistry—
the sky is the limit



WE CAN WORK IT OUT.

These implant systems were awarded the CleanImplant “Trusted Quality” seal after an unbiased and peer-reviewed quality assessment.

See what’s new:



UnicCa
BTI

Inverta
SOUTHERN
IMPLANTS

Patent
CHAMPIONS IMPLANTS

ICX-Premium
MEDENTIS MEDICAL

whiteSKY
BREIDENT MEDICAL

Prama
SWEDEN & MARTINA

SDS 2.2
SWISS DENTAL
SOLUTIONS

T6
NUCLEOSS

Astra Tech EV
DENTSPLY SIRONA

AnyRidge
MEGAGEN

(R)Evolution
CHAMPIONS IMPLANTS

BlueDiamond
MEGAGEN

SuperLine
DENTIUM

In-Kone
GLOBAL D

Contact S
BIOTECH DENTAL

- Find out more. Join in and support the charitable initiative.
- Receive quality information about your implant in use.
- Provide more safety for your patients and avoid negligence claims.
- Win new patients as a CleanImplant Certified Dentist.

Visit us at
EAO BERLIN!
Booth C 06



More information about this non-profit initiative:
www.cleanimplant.com/dentists

CLEAN IMPLANT
FOUNDATION

Dr Rolf Vollmer
First Vice President
and Treasurer of DGZI



Team spirit in implantology

Dear colleagues and friends,

Today, increasing expectations in terms of shorter treatment times are a major demanding for dentists and dental technicians. The challenge for the practitioner is to obtain an immediate temporary restoration added to the implant placement with an ideal aesthetic result in the shortest possible treatment time. Also, for many years, practitioners and patients have been concerned about bone resorption, leading to reduced retention and, therefore, stability of conventional dentures. Full-arch implant-supported fixed dental prostheses may provide more comfort and substantial improvements in prosthetic function, adaptation, and stability compared to conventional treatment options. In this issue of **implants—international magazine of oral implantology**, you will find some interesting patient cases that address these very issues.

Furthermore, in our interview with Dr Dirk U. Duddeck, Managing Director and Head of Research at the CleanImplant Foundation, you will learn how the seal of quality, which underlines the first-class surface cleanliness of dental implants, is only awarded after a rigorous, peer-reviewed analysis and testing procedure.

Despite the high temperatures, let us take a glimpse at what lies ahead in the busy autumn: The DGZI, German Association of Dental Implantology, is pleased to welcome you to a top event under the motto “Implantology in the team” in the beautiful city of Hamburg. On 6 and 7 October, the 52nd International Annual Meeting will take place, once again hold with a modified concept. Attendees will

experience a dental convention that sets the course for the future, raises new questions, and provides answers, but also shows new ways in the interaction between participants, speakers, and industry. This content-related claim is also reflected in the congress programme and the innovative organisational concept.

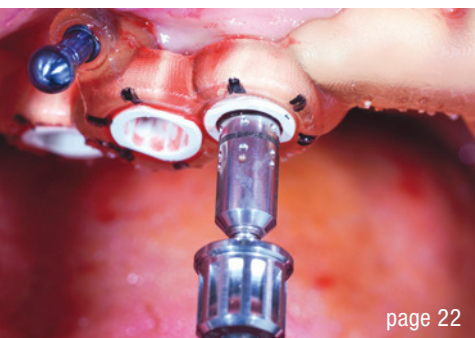
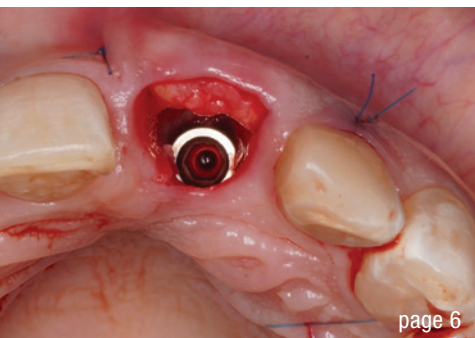
Participants and speakers from Japan, Georgia, Egypt, Kuwait, and the USA (just to name a few countries) will have the opportunity to network, to receive first-class practical training and to build a bridge from the latest scientific findings in the academic field to the implementation of innovations in daily practice. During the congress, the DGZI “Implant Dentistry Award” will be awarded in the categories “Dental Implantology”, “Implantological Assistance” and “Dental Implant Prosthetics”.

Enjoy two content-rich and instructive training days and get to know the historic Hanseatic city of Hamburg!

Yours,

Dr Rolf Vollmer

First Vice President and Treasurer of DGZI



editorial

Team spirit in implantology 03
Dr Rolf Vollmer

case report

Immediate aesthetic single-unit anterior restoration using a Grand Morse implant 06
Dr Luis Honorato Schmied

The transparent gingiva project 12
Drs Ariel Savion, Serge Szmukler-Moncler & Roni Kolerman

Immediate loading of a final fixed prosthesis in the edentulous maxilla on Straumann BLX implants 22
Drs Kerem Kilic, PhD & Erdem Kilic, PhD

research

Immune sustainability on titanium implants? 30
Drs Johann Lechner, Fabian Schick & Florian Notter

industry

“We fight dirty” 34
Dr Dirk U. Duddeck

interview

Digital dentistry—the sky is the limit 36
Dr Shivi Gupta

news

manufacturer news 38

events

IADR Innovation in Implantology Research prize awarded to Dr Alberto Monje 40

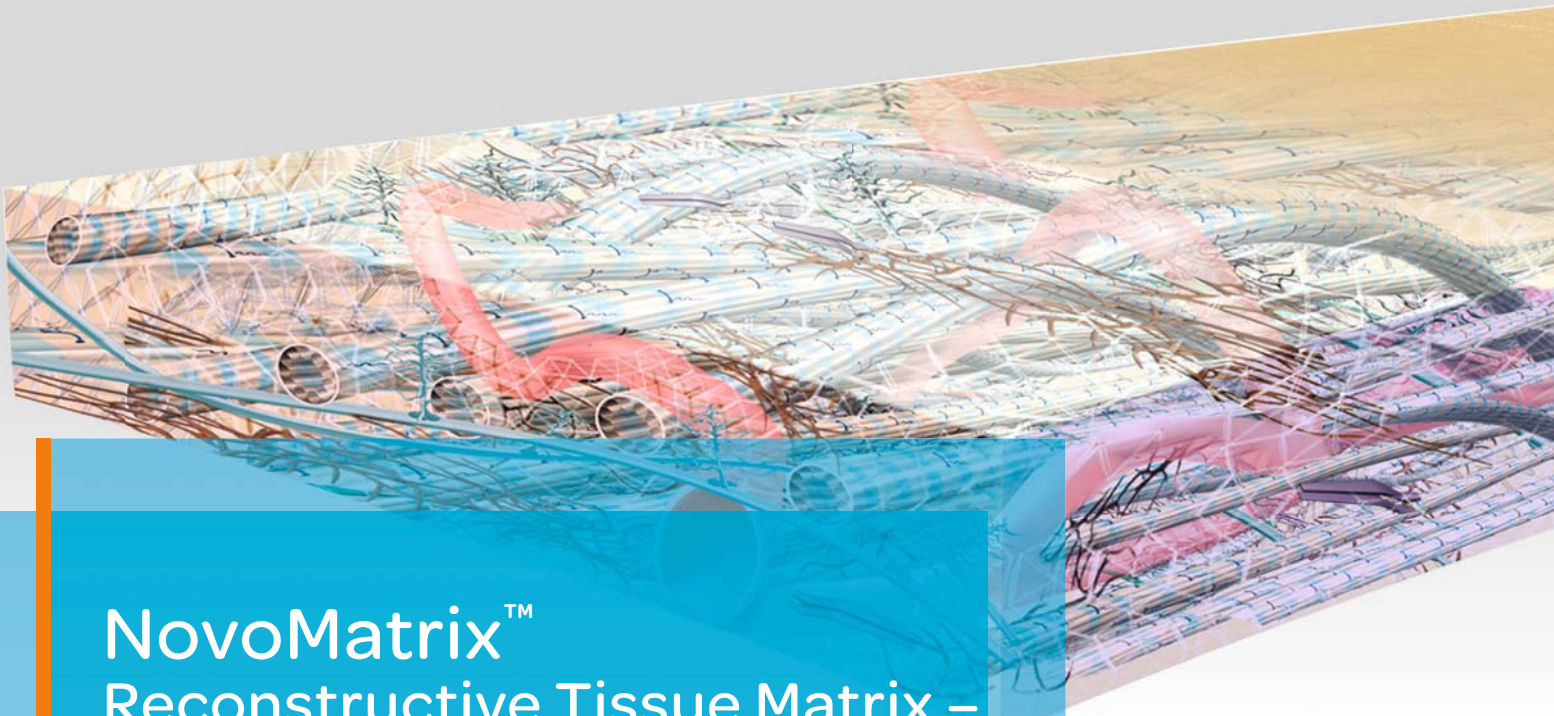
“Ceramic Implants meets Aesthetics” successful in Munich 41

about the publisher

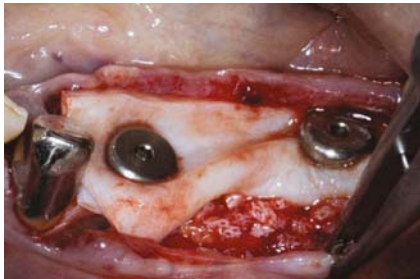
imprint 42

Cover image courtesy of Neodent Brasil, www.neodent.com

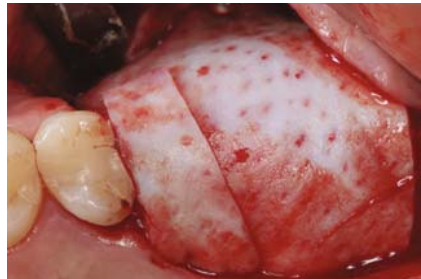



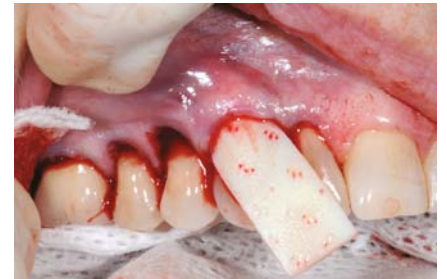NovoMatrix[™] Reconstructive Tissue Matrix – the next generation material



Ridge reconstruction



Gingival augmentation



Root coverage

NovoMatrix[™] Reconstructive Tissue Matrix is an acellular dermal matrix derived from porcine tissue intended for soft tissue applications. The proprietary LifeCell[™] tissue processing is designed to maintain the biomechanical integrity of the tissue, which is critical to support tissue regeneration.

Benefits of NovoMatrix[™]

- shorter surgery time¹
- lower patient morbidity^{1, 2, 3}
- excellent tissue integration^{4, 5, 6, 7}
- natural tissue and color structure⁸
- rapid and complication-free healing of soft tissue^{4, 6, 7, 9}

www.biohorizonscamlog.com/novomatrix



References available at: www.biohorizonscamlog.com/references_novomatrix
Before use, physicians should review all risk information, which can be found in the Instructions for Use attached to the packaging of each NovoMatrix[™] Reconstructive Tissue Matrix graft. NovoMatrix[™] is a trademark of LifeCell[™] Corporation, an AbbVie.
©BioHorizons. All rights reserved. Not all products are available in all countries.

Immediate aesthetic single-unit anterior restoration using a Grand Morse implant

Dr Luis Honorato Schmied, Chile

Patients' increasing expectations in terms of shorter treatment times are a major challenge for dentists and dental technicians. To support dental professionals in providing quality care faster, the Neodent Grand Morse implant system offers three implant designs, including Helix GM, all featuring the innovative hydrophilic Acqua surface. This maximises primary stability and predictability in immediate restoration protocols.

Case report

The 40-year-old female patient presented with a medical history of cerebral venous thrombosis, suffered in 2016, and epilepsy, diagnosed in 2018. The patient initially presented to the office complaining of spontaneous pain in tooth #21 and, on examination, had an enlarged periodontal ligament and a negative response to the pulp vitality test (Figs. 1 & 2). An emergency assess cavity and endodontic treatment were performed.

Three months after treatment, the patient returned complaining of spontaneous pain. The root canal was treated again and the patient medicated until the pain subsided. However, three months after retreatment, the patient had pain, mobility and suppuration. The root canal was again retreated, and the patient was medicated, but the mobility, pain and suppuration did not resolve.

Planning

A CBCT scan was requested, and tooth extraction was indicated (Fig. 3). Preoperative antibiotic treatment was prescribed for five days before surgery. It was planned to extract tooth #21 and immediately place and restore an implant to replace it.

Treatment and provisional restoration

Tooth extraction and careful alveolar conditioning were performed, taking care not to damage the alveolar bone.

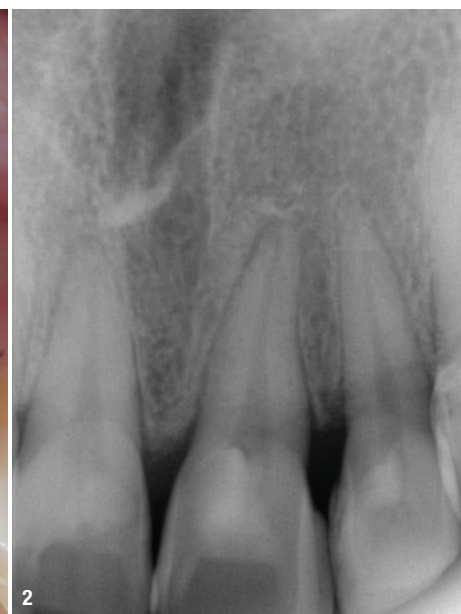
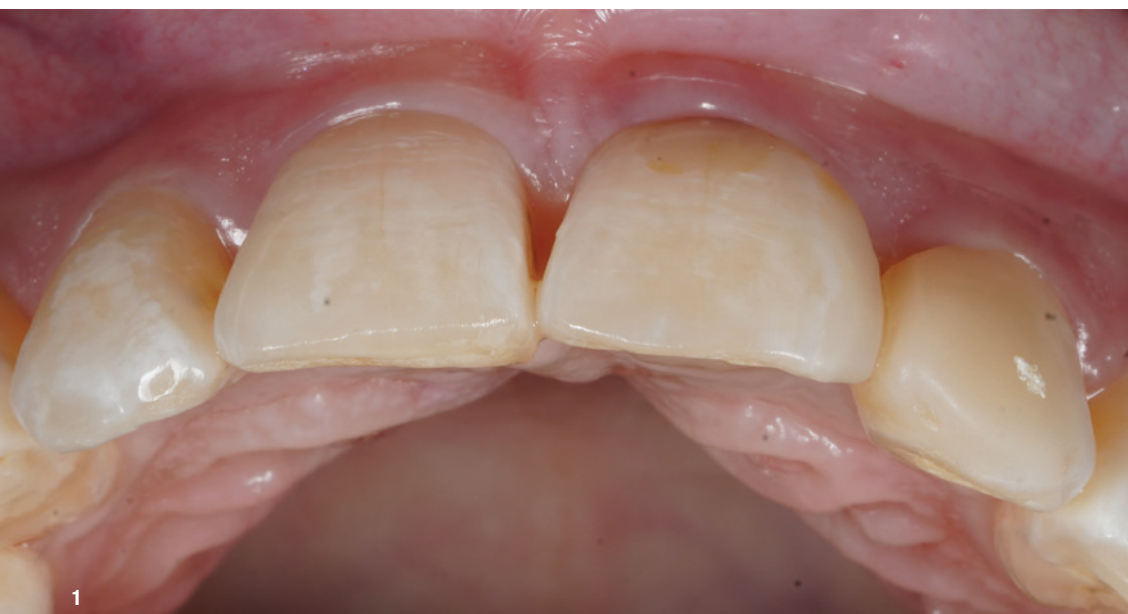

Fig. 1: Initial clinical aspect. Fig. 2: Initial periapical radiograph.

State-of-the-art ultrasound technology without radiation exposure.

Ensuring your implant success and the health of your patients.

The feeling when the implant is in place and my patient is happy:
INCREDIBLE!

Gentle and safe examination method

Precise measurement of jawbone density

Localisation of chronic inflammation in the jawbone

MORE INFORMATION:
www.cavitaude

CONTACT:
info@cavitaude

Order under:
shop.cavitaude

MADE IN GERMANY



The drilling protocol was then performed following the instructions of the manufacturer, and a Helix GM 4.0 × 13.0mm implant was placed to an insertion torque of 60Ncm. A connective tissue graft was harvested from the lateral area of the palate and the wound sutured (Fig. 4). This graft was then placed in a previously prepared vestibular gap and secured with sutures. A biomaterial was also inserted in the gap, and the abutment and screw-retained provisional crown, created from the crown of tooth #21, were placed. Postoperative control was performed three days, one week and two weeks after surgery.

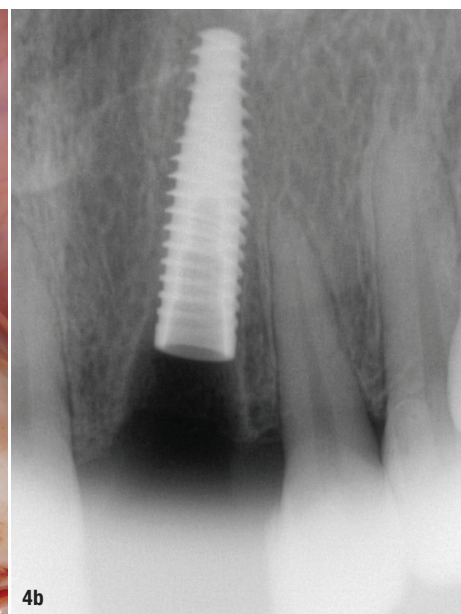
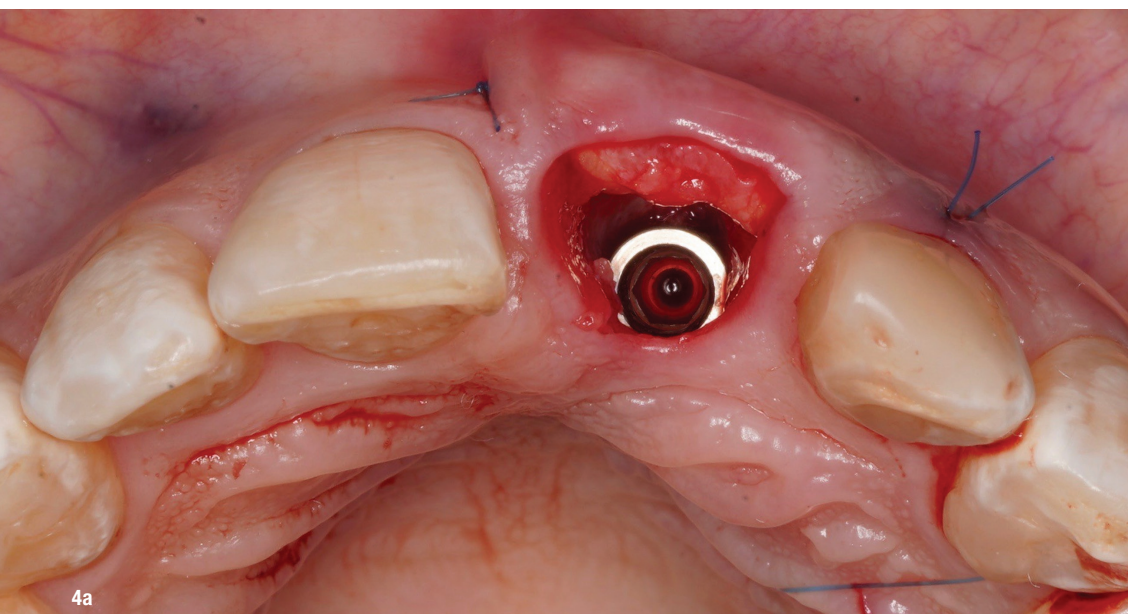
Final restoration

Three months after surgery, the provisional crown was removed, and the buccogingival margin was observed to be in the desired position with an adequate emergence profile and healthy periodontal parameters (Fig. 5).

A GM 3.5 × 4.0 × 1.5mm titanium base abutment was selected. A personalised zirconia coping was milled to which it was possible to transfer the emergence profile created from the day the implant was placed. A week later, the impression was taken using a custom open tray of acrylic resin and a Scan Regular addition-cured silicone (Yllcr Biomaterials). The colour of the final prosthesis was then selected. For the conditioning of the prosthetic solution, the Yzap primer and Sylano bonding agent (Yllcr Biomaterials) were used. The final prosthesis was then tried in and cemented (Fig. 6). Excess cement was removed before polymerisation.

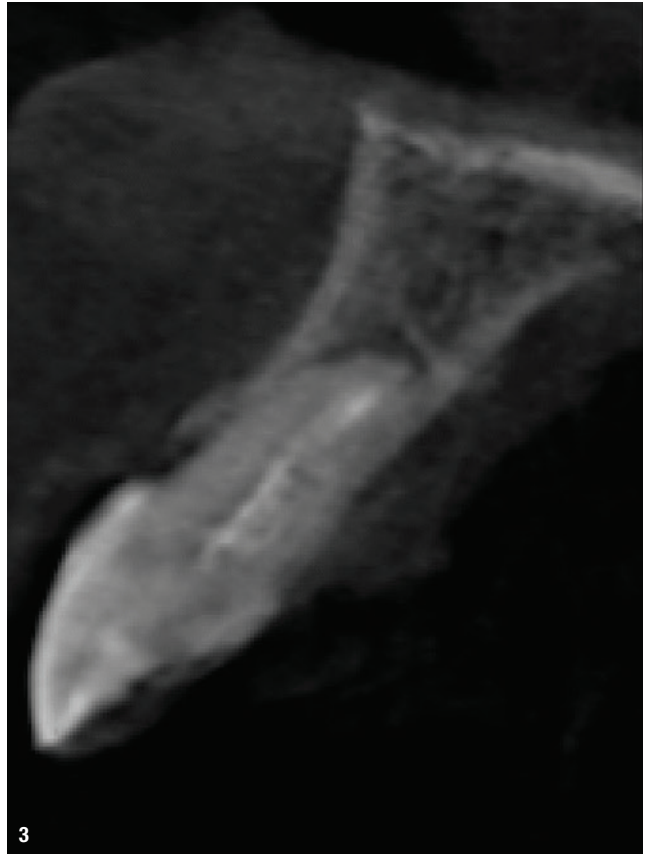

Fig. 3: CBCT scan after canal medication of tooth #21.



Figs. 4a & b: Occlusal and radiographic view of the implant and connective tissue placed.

The universe at your fingertips.

TwinLight[®] Peri-implantitis Treatment

A simple and effective procedure that offers the power to treat peri-implantitis – an increasing threat to oral health.

- Minimally-invasive technique
- Fast regeneration/healing
- Reduced inflammatory response
- Highly effective treatment
- No antibiotics needed



LightWalker[®]

The ultimate all-in-one hard and soft tissue laser

Peri-implantitis treatment video

