

# roots

international magazine of endodontics



## research

Reducing microleakage with lasers

## technique

The advantage of using  
a dedicated carrier to place MTA

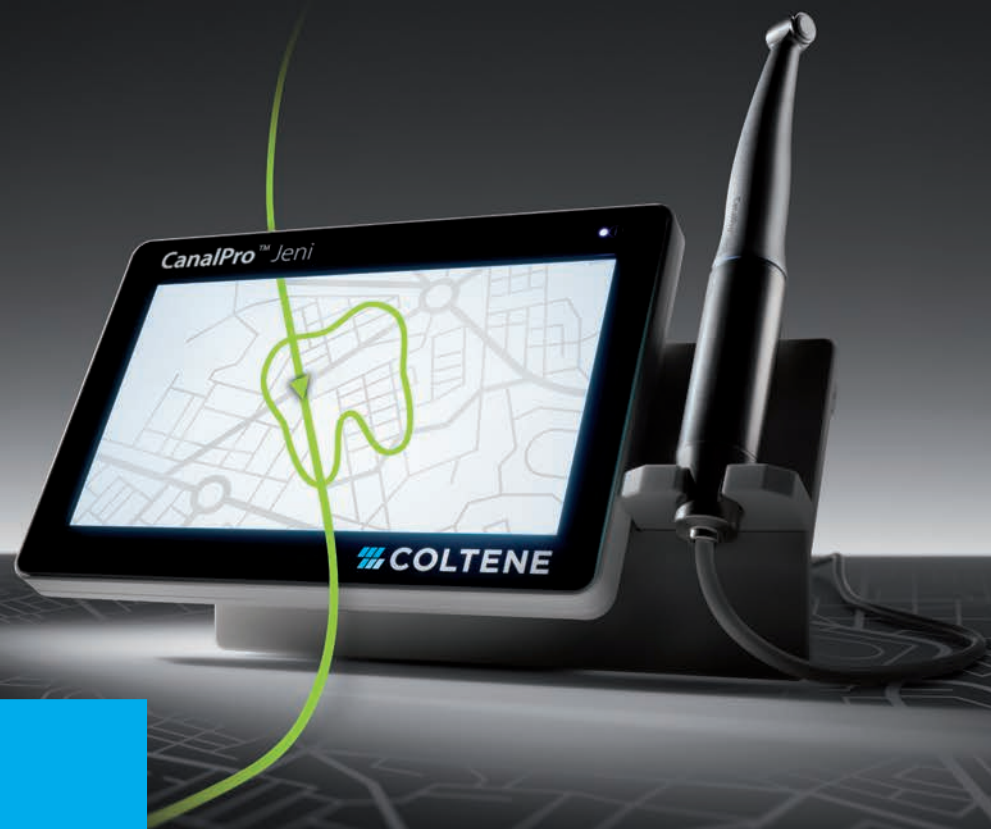## trends & applications

Calcified canals: A new approach

# CanalPro™ Jeni

Digital assistance system for canal preparation

Jeni – ready – go!



**NEW**

Test it yourself!

<https://canalpro.coltene.com/jeni/#book>

## Autonomous «navigation» in the endo canal owing to revolutionary software

- › Digital assistance system for canal preparation controls the file movement at millisecond intervals
- › Movement profile of the file continuously adapts to the individual root canal anatomy
- › Irrigation recommendation is indicated by an acoustic signal
- › Due to the integrated apex locator and fully insulated angled handpiece, continuous measurement of the working length is possible in real time

info.de@coltene.com | [www.coltene.com](http://www.coltene.com)

**COLTENE**

**Adj. Prof. Philippe Sleiman**

Guest editor



## Daily clinical challenges

**Endodontics is the art and science** of daily challenges, expecting the unexpected, having eyes at the tips of your fingers and employing all your senses. First and foremost, we must not forget that we hold medical degrees, and indeed, endodontics can sometimes be very demanding when dealing with patients with special medical histories or some illness or even contagious virus, and we need to fulfil our paths.

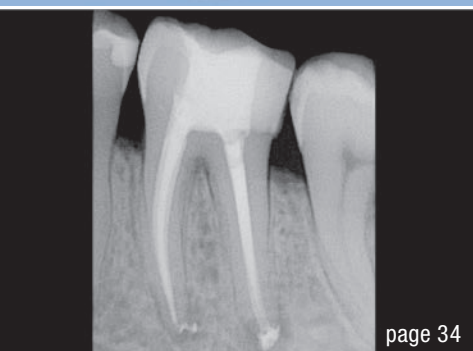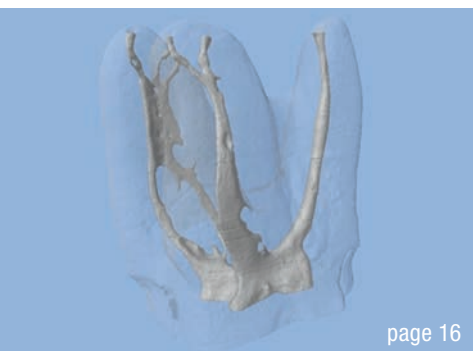Travelling to the office, looking at the day's schedule and not knowing what challenges lie ahead, it is essential to foster a good mood and to spread it to your team in order to have a calm and smooth day, putting all your worries aside.

Accepting the diagnosis as it is and trying to replace nature is something that we never have to do or promise. If the tooth needs root canal therapy or does not, we need to say so. If the tooth is cracked or compromised, we need to accept it and try to explain to our

patient and to the referring dentist the best options for treatment. Sometimes, it may be considered a waste of your clinical time, but use it as an opportunity to have a break to check on your family and chat with your staff over a warm coffee. If microsurgery is needed to remove a cyst, better sooner rather than later. One of the major causes of burn-out in dentistry is not delivering what we wish for.

We cannot be in control of everything; mother nature and our body have the upper hand. It is not a reversible treatment that we are doing, and room for error is almost non-existent. This is something that demands great mental preparation in order to keep calm and give the best that we can for our patients—after all, we are performing the most complicated treatment in dentistry; we are doing endodontics.

Adj. Prof. Philippe Sleiman  
Guest editor



Cover image courtesy of poowanai Budsaman/Shutterstock.com



**editorial**

**Daily clinical challenges** 03  
Adj. Prof. Philippe Sleiman

**research**

Reducing **microleakage** with Er,Cr:YSGG and/or Nd:YAG lasers 06  
Drs Mina Mazandarani, Maziar Mir & Masoud Shabani, Prof. Norbert Gutknecht

**technique**

“Le **passage**” 12  
Adj. Prof. Philippe Sleiman

Continuous wave of condensation: **A new cordless obturation system** 16  
Dr Gary Glassman

**The advantage of using a dedicated carrier to place MTA** 22  
Drs Massimo Giovarruscio & Francesca Cerutti

**Eliminating the challenges** of crown removal or endodontic access through restorations 26  
Dr Gregori M. Kurtzman

**case report**

**EdgeFile X7: Beastly bifurcation** 32  
Dr Yanina Figueroa

**The journey is the reward** 34  
Dr Silviu Bondari

**trends & applications**

**Calcified canals: A new approach to an old problem** 36  
Dr Randolph Todd

**interview**

“At **Slow Dentistry**, we believe that time is a universal **vector of excellence**” 38  
An interview with Dr Miguel Stanley

**practice management**

Feedback done **right** 42  
Andrea Stix

**news**

**ADA supports point-of-care COVID-19 testing by dentists** 44

**Decellularised matrix hydrogel** may promote dental pulp regeneration 45  
Monique Mehler

**manufacturer news** 46

**about the publisher**

submission guidelines 48

international imprint 50



**EDGEENDO®**

# PERFORMANCE.PRICE.TECHNOLOGY.

We are pleased to announce sterile endodontic rotary files will be available to our European customers in Q1 2021. EdgeEndo® systems offered include: EdgeTaper™, EdgeTaper™ Platinum, EdgeGlidePath™, EdgeOne™ Fire, EdgeOne™ Fire GlidePath and EdgeFile® X7.

In conjunction, our best-selling file system, the EdgeFile® X7, will be launched Q1, 2021! X7 is the most recognized and proven solution. It has repeatedly outperformed competitor files in peer reviewed published research. Read just one of many studies (see QR code below).



## EDGEFILE® X7

- Proprietary heat treatment process
  - FireWire NiTi™ Alloy improves strength and flexibility\*
- Available in .04 and .06 Constant Taper
  - Variable Pitch
- Maximum flute diameter 1mm allows for minimally invasive preparation
- Parabolic Cross Section non cutting tip
  - Maximizes file cutting efficiency
- Electropolished file
  - Increases sharpness and strength
- Reduced handle length for increased posterior access
- ISO tip size 17-45
- Available lengths: 21, 25 & 29 mm



Evaluation of the Amount of Root Canal Dentin Removed and Apical Transportation Occurrence after Instrumentation with ProTaper Next, OneShape, and EdgeFile Rotary Systems. Scan code to read full study.



Scan to read our X7 Simplified Technique Guide.

To learn more about EdgeEndo and the offering, please access the website [www.edgeendo.com](http://www.edgeendo.com) and select your country to find your dealer.

Made in the USA 

\*Based on resistance cyclic testing as shown on the FireWire NiTi Strength Graph:<http://edgeendo.com/comparative-study-of-cyclic-fatigue-resistance/>  
ProTaper® Next is a registered trademark of Dentsply Sirona. OneShape® is a registered trademark of MICRO-MEGA.

# Reducing **microleakage** with Er,Cr:YSGG and/or Nd:YAG lasers

## An evaluation

Drs Mina Mazandarani, Maziar Mir & Masoud Shabani, Iran; Prof. Norbert Gutknecht, Germany

### Introduction


In endodontics, effective cleaning of the root canal system is essential for ensuring successful root canal therapy with long-lasting treatment outcomes.<sup>1-3</sup> During endodontic instrumentation, various morphological changes occur on the root canal walls, including organic and mineral debris<sup>4-7</sup> and smear layer formation.<sup>2,4,7</sup> Therefore, not only are conventional cleaning and removal of debris and the smear layer important steps in endodontic procedures,<sup>1,2</sup> but chemical irrigation is strictly recommended for use in conjunction with mechanical instrumentation in order to dissolve debris and the smear layer.<sup>8,9</sup> In fact, the methods employed to clean and shape root canal spaces create a smear layer, which may harbour microorganisms that ultimately result in periapical pathosis.<sup>3,7</sup> Many irrigant solutions, such as sodium hypochlorite and ethylenediaminetetraacetic acid (EDTA), are used. Sodium hypo-

chlorite is effective in removing organic tissue remnants,<sup>8</sup> while EDTA is effective in removing the inorganic portion of the smear layer.<sup>9</sup> However, both irrigants are unable to remove the smear layer effectively.<sup>1,3,10</sup>

A successful root canal therapy is based on a number of factors: reduction of microorganisms to the minimum, sufficient and proper root canal instrumentation and disinfection, as well as well-adapted root canal obturation.<sup>11</sup> A crucial disadvantage of irrigant solutions is that their bactericidal effect is limited to the main root canal. Because of the narrow diameter of the dentinal tubules and the high surface tension of the liquid solutions, they are able to penetrate only a small distance into the tubules. The penetration depth of chemical disinfection only reaches 100µm into the adjacent dentinal tubules.<sup>12,13</sup> However, the bacteria can penetrate over 1,000µm from the canal lumen,<sup>12</sup> as described by Kouchi et al.<sup>14</sup> and

Group number	Groups	Laser setting	Fibre/Tip size	Time of operation	Sample size
1	Conventional preparation & EDTA & Er,Cr:YSGG & Nd:YAG	Er,Cr:YSGG = (1.5 W, 20Hz), 140µs, [Waterlase MD]* Nd:YAG = (1.5 W, 15Hz) Pulse duration = 160µs [Fotona]**	Er,Cr:YSGG = 320µm Nd:YAG = 200µm	2 mm/sec Rotational	12
2	Conventional preparation & Er,Cr:YSGG & Nd:YAG	Same as * and **	Er,Cr:YSGG = 320µm Nd:YAG = 200µm	2 mm/sec Rotational	12
3	Conventional preparation & EDTA & Nd:YAG	Same as **	200µm	2 mm/sec Rotational	12
4	Conventional preparation & Nd:YAG	Same as **	200µm	2 mm/sec Rotational	12
5	Conventional preparation & EDTA				12
6	Conventional preparation				12
<b>Total</b>					<b>72</b>

**Table 1:** All groups of laser-irradiated root canals and control (n=72).



## VDW.ROTATE™ NiTi Root Canal File

The remix taking rotary preparation to the next level

### VERSATILITY

VDW.ROTATE™ includes an intuitive 3 file basic sequence plus a wide range of larger files for various clinical cases with matching paper points and obturators.

Be virtuoso!

### RESPECT OF THE NATURAL CANAL ANATOMY

The instruments follow the natural canal anatomy smoothly thanks to its specific heat treatment making the file more flexible without compromising its cutting efficiency.\*

Get in the swing!

### EFFICIENT DEBRIS REMOVAL

The adapted S cross section gives more space for debris removal and provides control of the instrument for a swift, thorough and safe preparation.\*\*

Set the beat!

\*compared to other VDW continuous rotary instruments  
\*\*compared to a centred rotary cross section

Root third	Group 1	Group 2	Group 3	Group 4	Group 5	Group 6
Apical	845 (Gr. 2)	950 (Gr. 2)	975 (Gr. 2)	582 (Gr. 2)	632 (Gr. 2)	483 (Gr. 1)
Middle	183 (Gr. 1)	512 (Gr. 2)	579 (Gr. 2)	517 (Gr. 2)	917 (Gr. 2)	821 (Gr. 2)
Coronal	380 (Gr. 1)	356 (Gr. 1)	504 (Gr. 2)	391 (Gr. 1)	718 (Gr. 2)	962 (Gr. 2)

**Table 2:** Graded average dye penetration depths (µm). Gr. = grade.

Ando & Hoshino.<sup>15</sup> Therefore these bacteria are protected in the deeper layers of dentine. In this protected area, we find Gram-negative bacteria, which are characterised by their unusual migration qualities and their resistance to chemical irrigant solutions. They maintain their virulence against conventional endodontic techniques. And we find that, from this bacterial reservoir, the bacteria will spread to the periapical areas of the tooth, causing inflammation and infection.<sup>12</sup> Since conventional root canal therapy is not always successful, new methods could perhaps enhance the long-term prognosis and overcome the shortcomings of conventional instrumentation methods.<sup>11</sup>

Today, lasers are used in endodontics to dramatically improve the prognosis of root-filled teeth.<sup>12</sup> Laser irradiation produces different effects on the same tissue, and the same laser can produce various effects in different tissues. Er:YAG and Er,Cr:YSGG lasers have been reported to ablate dental hard tissue<sup>16–21</sup> with minimum injury to the pulp and surrounding tissue.<sup>17–19,22–25</sup> The Er:YAG laser has been reported to ablate enamel and dentine effectively, because of its highly efficient absorption in both water and hydroxyapatite,<sup>16,20,21</sup> and the Er,Cr:YSGG laser, which uses a pulsed beam system, fibre delivery and a sapphire tip bathed in a mixture of air and water vapour, has been shown to be effective for cutting enamel, dentine<sup>18,20</sup> and bone.<sup>18</sup> Moreover, this specific property, combined with a water spray for both lasers, enables the effective removal of debris and the smear layer.<sup>23,26–31</sup> The surface morphology of root canals can be altered by using a 1,064 nm Nd:YAG laser. Remaining soft tissue as well as the smear layer can be partially or completely removed, depending on the energy level used.<sup>11</sup>

The Nd:YAG laser seems to be the laser of choice in root canal therapy. It is also the best-documented laser in the literature for root canal sterilisation. Most of the studies concerned with the Nd:YAG laser in endodontics deal with the quantitative evaluation of bacteria reduction.<sup>12</sup> Laser irradiation has been widely introduced in endodontic treatments as an aid to disinfection and the removal of debris and the smear layer from instrumented root canal walls and might be a solution for the various limitations and shortcomings of mechanical and chemical disinfection. Microleakage continues to be a main reason for failure of root canal therapy, where the challenge has been

to achieve an adequate seal between the internal tooth structure and the main obturation material, gutta-percha.<sup>32</sup> It has been found that approximately 60% of endodontic failures are due to inadequate obturation of the root canal system.<sup>33,34</sup> Although gutta-percha is the most popular core material used for obturation, it cannot be used as the sole filling material because it lacks the adherent properties necessary to seal the root canal space. Therefore, a sealer and cement are always needed for the final seal.<sup>35,36</sup> The Resilon/Epiphany system uses a new obturation material that bonds chemically with the internal tooth structure, thereby decreasing the possibility of microleakage.<sup>32</sup>

The scientific investigation of fundamental problems plays a decisive role in understanding the mechanisms of action of exposing biological materials to laser irradiation and their consequences.<sup>37</sup> The purpose of this study is to analyse microleakage differences when removal of the smear layer is done conventionally, chemically (with and without EDTA) and with Er,Cr:YSGG and/or Nd:YAG laser irradiation and Resilon/Epiphany is used as the obturation material.

## Materials and methods

In this study, 72 freshly extracted caries- and restoration-free single-canal bovine teeth<sup>38,39</sup> stored in normal saline (0.9%) at 4 °C were used, after scaling with scalpels or hand instruments to remove residual tissue and calculus and rinsing thoroughly with tap water. Samples were randomly divided into six groups of 12 teeth each. The working lengths were established as 1 mm short of the apexes. The canals were hand instrumented with Kerr files (Maillefer) to the size of ISO 30 to this length in order to create an apical stop. The root canals were thoroughly rinsed with saline solution and gently dried using paper points (Dentsply Sirona). Then Groups 1 to 4 were irradiated by laser, and EDTA (Produits Dentaires; 15 ml, LOT 6217 FL) was used to remove the smear layer for some groups, followed by a final rinse with saline solution (Table 1).

All 72 samples were prepared for obturation using the Resilon/Epiphany system. The canals were dried with absorbent paper points (Dentsply Sirona). A dry paper point was soaked with self-etching primer (SybronEndo; 6 ml, ref. No. 972-2007) and used to coat the root ca-



nal walls. The size of the Resilon master cones was then determined. An appropriate amount of the dual-polymerising Resilon sealer (SybronEndo; 4 ml) from the automix syringe was expressed on to a slab. The canals were coated with the sealer using the automix syringe, pre-measured Resilon master cones and a file. The viscosity of the sealer was modified by adding a drop or two of RealSeal thinning resin (SybronEndo, ref. No. 972-2006). Subsequent accessory points of Resilon core material were also coated with the sealer and inserted into the canal and compacted through lateral condensation. Once the obturation was completed, the coronal surface was light-polymerised for 40 seconds. The coronal portions of all samples were then restored.

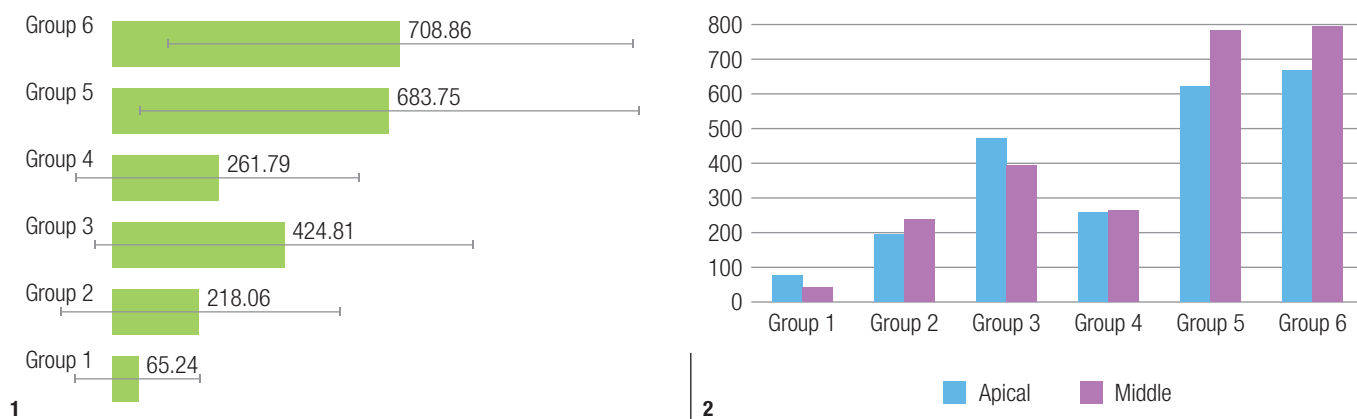
Acid etching was done using a 35% orthophosphoric acid-etch gel for 15 seconds. After acid etching, all cavities were coated with a layer of primer (Syntac Primer, Ivoclar Vivadent), adhesive (Syntac Adhesive, Ivoclar Vivadent) and bonding agent (Heliobond, Ivoclar Vivadent) and light-polymerised (Translux, Kulzer) for 20 seconds. Then a composite (Ivoclar Vivadent; Shade A3) was used in increments to seal the coronal 2 mm of the roots and was light-polymerised for 40 seconds. For the dye penetration test, the samples were first coated with two layers of nail polish (Sally Hansen, Del Laboratories), except for the last apical 2 mm, which was left exposed so that the dye could only penetrate the canal via the apical region. The samples of each group were then kept in separate containers of distilled water and incubated at 37 °C for five days, to stimulate clinical conditions.

After incubation, the samples of each group, again in separate containers, were immersed in an aqueous solution of 2% methylene blue at 37 °C for seven days so that the root canals would be filled with dye solution by capillary action. After this time, the teeth were removed from the dye and rinsed under running water for 5 minutes and incubated again in distilled water at 37 °C for 24 hours. After incubation, the teeth were removed from the dye-containing solution, rinsed and dried. The samples were

dehydrated in a sequence of alcohol solutions (70% for 24 hours, 96% for 24 hours and 100% for 48 hours). Then they were kept in a histological cleaning agent (Histo-Clear II, National Diagnostics) for 2 hours and embedded in resin (K Plast) in groups in separate containers and stored in a water bath for four to seven days until the resin had set. The glass containers were broken to remove the resin-embedded samples, and Vaseline was applied into a self-made former container for each sample, to avoid sticking of acrylic to the container.

Dye leakage was assessed after immersion in methylene blue, by examining vertical and horizontal sections under a transmitted-light microscope (Leica DMRX with an integrated Hitachi HV-C20A camera, Leica Microsystems) at an objective lens magnification of 0.63x (optical lens magnification of 10x) by means of a computer programme (Diskus, Hilgers Technisches Büro). Then horizontal cuts of 500 µm in thickness were made, splitting the roots into three portions: coronal third, middle third and apical third. The horizontal sections were examined under the transmitted-light microscope at an objective lens magnification of 2x (optical lens magnification of 10x) by means of the same computer programme, to assess dye penetration, and the data was saved. It is necessary to note that the digital camera, which connects the microscope to the PC and software, will magnify the image, but the power of magnification is not easy to calculate. Therefore, the final magnification of the image that is shown on screen or printed out depends on the size of screen. That is why we only report objective lens and optical lens magnification in such cases.

Data analysis was performed using StatView software (SAS Institute Inc.), and the extent of leakage in each group was investigated in both vertical and horizontal cuts to gain a near 3D view. The scores were statistically evaluated by three calibrated examiners using the Kruskal–Wallis test to determine the statistical differences among the groups ( $p < 0.05$ ), and comparison of paired groups was done using the Wilcoxon signed rank



**Fig. 1:** Average dye penetration depth (µm) in all six groups. **Fig. 2:** Average dye penetration depth (µm) in all six groups based on the images of the vertical cuts of the roots.