

DENTAL TRIBUNE

The World's Dental Newspaper • Pakistan Edition



PUBLISHED IN PAKISTAN

www.dental-tribune.com.pk

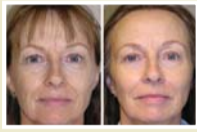MAY, 2019 - Issue No. 03 Vol.6



An exclusive interview with Dr. Jamal Syed

INTERVIEW

► Page 4



Anti-ageing medicine and orthodontic appliance therapy ...

CLINICAL ORTHODONTICS

► Page 8



The complete digital implant workflow

CLINICAL IMPLANTOLOGY

► Page 9

'Future, Innovation, Together!', APDC 2019

DT Pakistan Report

SEOUL - Dentists from the Asia-Pacific region gathered at COEX, in southern Seoul, South Korea, from May 8th to 12th, to exchange their latest academic knowledge and enhance networking. The general meeting of APDC took place in Korea after 17 years; last one being in 2002.

The theme of the 41st Asia-Pacific Dental Congress was 'Future, Innovation, Together!'

The Congress was hosted by Korean Dental Association (KDA). The events were organized by Asia-Pacific Dental Congress (APDC), the 54th KDA Scientific Congress and the 16th Seoul International Dental Exhibition (SIDEX 2019).

President World Dental Federation (FDI) Kathryn Kell, President APDF/APRO Fernando Fernandez, along with representatives of 21 Asia-Pacific members countries, including

Pakistan, Myanmar, Singapore, and Vietnam and FDI members, including China, U.S., Canada, and Germany, attended the event to discuss Asia-Pacific people's dental health improvement and international cooperation in this regard.

The APDC events brought the competence and capabilities of the Korean dental industry into limelight; it also drew out ideas from major stakeholders of dentistry, worldwide, to help dentists improve oral health of the 4.5 billion people in Asia-Pacific region in the era of Fourth Industrial Revolution. The congress also took a look at and addressed revolutionary dental care ideas and leading-edge dental equipment.

Speaking during a news conference at the Inter-Continental Hotel near COEX, before the general meeting of the Asia-Pacific Dental Congress, President Korean Dental Association Kim Cheol-soo said, "Beginning my



Kim Cheol-soo (third from left), president of the Korean Dental Association, speaks during a news conference at the InterContinental Hotel near COEX, southern Seoul, Wednesday, before the general meeting of the Asia-Pacific Dental Congress.

term as the 30th president, I visited each country's dental association events with FDI. I will make efforts so that APDF can continue to take part in FDI and keep pace with the global trends through international cooperation."

Kim is the fourth Korean dentist to serve as president of APDF.

The scientific session of APDC was graced by reputable speakers from around the world, but especially from

the Asia-Pacific region. Among the many renowned international speakers, Dr Azad Ali Azad of Armed Forces Institute of Dentistry was also invited from Pakistan to present at the Congress. He spoke on "Digital Dentistry Today and Tomorrow". A delegation from Pakistan, including President Pakistan Dental Association Dr Mahmood Shah among others, visited the congress to represent the country.

Product serialization to be introduced to limit counterfeit drugs distribution

DT Pakistan Report

ISLAMABAD - The government's initiative of introducing bar coding and serialization will soon be adopted by the Drug Regulatory Authority of Pakistan (DRAP) for prompt tracing of spurious or counterfeit medicines at every level.

According to a DRAP official, a national task force has been constituted for eradication of spurious and un-registered drugs with the coordination of provincial health departments; the government has increased the number of drug inspectors to ensure availability of quality medicines and have check on spurious drugs in open markets.

He said the authority had conducted as many as 23,809 inspections throughout the country during last one year with report of 3,445 cases of violation of DRAP Act 2012. official said authority's central drug laboratory has collected total 41,435 samples of

Continued on Page 15

Authentik™ Buy the Real Thing!

SAY NO TO QUACKERY

VISIT PMDC REGISTERED DOCTORS ONLY

DOWNLOAD AND VERIFY YOUR DOCTOR

SCAN QR CODE

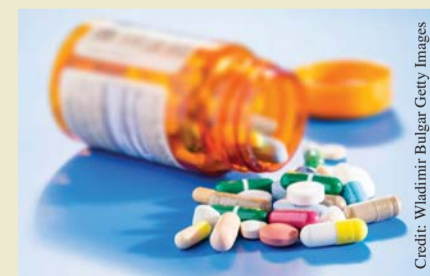Authentik™ Buy the Real Thing!

Download on the App Store GET IT ON Google Play

PPMA and govt settle for 75% rise in drug prices

DT Pakistan Report

KARACHI - The episode of disagreements and controversies has finally come to an end with an agreement between Pakistan Pharmaceutical Manufacturers Association (PPMA) and the federal government



Credit: Wladimir Bulgar Getty Images

regarding the hike in drug prices. According to the settlement there will be an increase in drugs prices by up to 75%. Any increase in medicines' prices above

Continued on Page 15

Prof. Dr Ghani proceeds to Glasgow as MFDS examiner

DT Pakistan Report

PESHAWAR - Prof. Dr Ghani is leaving for Glasgow, UK, as examiner for MFDS Part 2 of the Royal College of Physicians & Surgeons of Glasgow (RCPSG).



During his 10-day long visit to UK, Prof. Dr Ghani will also attend the examiners re-training event at RCPSG, which is a requirement of the UK General Dental Council for re-accreditation and continuity as examiner in the chosen dental specialty. The training event is mandatory to be re-taken after the completion of every 5-years term of examinership by existing examiners of the RCPSG. Prof. Dr Fazal Ghani's current positions include Professor and Head of Department of Prosthodontics, Dean of the Postgraduate Dental Studies and Coordinator of International Relations at Peshawar Dental College in Pakistan. He is also International Advisor to the Royal College of Physicians & Surgeons of Glasgow.

Prof. Dr Ghani is a pioneer training supervisor for Fellowship in Prosthodontics of the College of Physicians and Surgeons Pakistan, and has supervised and examined many Prosthodontics Fellowships, MSc, M. Phil and PhD candidates. In addition to his work experience, Prof. Dr Ghani has also published over 100 articles and reviewed over 300 articles for numerous national and international journals. He is also the senior member of Higher Education Commission Expert Committee that monitors and

Continued on Page 15



Dr Farrukh Aijaz hosts reception to honour Dr Inayatullah Padhiar SI

DT Pakistan Report

ISLAMABAD - Farrukh Aijaz recently hosted a reception in Islamabad to honour Dr Inayatullah Padhiar on receiving Sitara-e-Imtiaz. Drs. Kamran Vasfy, Farrukh Aijaz, Abdul Qadir, Inayatullah, Noeen Arshad, Anis-ur-Rehman, Saeed Jan, and Umair Farrukh were also present on the occasion.

Lecture on cleft lip management and volunteer work in US at LMDC

LAHORE - The CDE committee under the patronage of Prof. Aqib Sohail, Principal & Dean, College of Dentistry, Lahore Medical and Dental College (LMDC), recently arranged a lecture at LMDC Auditorium. The topic of discussion was "Oral Health Care, Volunteer work in the United States & Management of Cleft Lip/Palate". The lecture was given by Dr Salman Malik, an Oral & Maxillofacial Surgeon running his private practice in Londonderry, New Hampshire.



Dr Salman Malik spoke about the different surgical techniques he has found to be successful in the numerous cleft lip and palate patients he has treated over the years. He spoke about how treating such patients required a multidisciplinary approach. He also shed some light upon how he has treated such patients in the field with minimum equipment.

Dr Salman Malik showed much concern about outreach programs and volunteer work. He talked about the New York University volunteer programs and how they were conducted. He mentioned that he had recently been in Swat Valley himself and had personally worked on many patients there free of cost. He concluded his lecture by encouraging everyone to participate in volunteer work and giving back to the society.

Prof. Dr Aqib Sohail concluded the seminar by enlightening the audience about the current treatment and procedures being done in Pakistan for Cleft Lip and Palate patients. He further went on to support Dr Salmans' efforts and encouraged his fellow colleagues and residents to participate in community work.

The CDE committee also appreciated the efforts of Ms. Syeda Attiaa Batool, who is the Cultural Affairs Assistant (Student Outreach) working in the US Consulate General, for facilitating and aiding in organizing this lecture. **-PR**

Dentsply Sirona has a new Chief Technology Officer

Bensheim/Salzburg- Dentsply Sirona recently announced that Dr Cord Friedrich Stähler has joined the company's management team as Chief Technology Officer (CTO)- effective May 1, 2019. In his new role, Stähler will lead the global strategy for product development and innovation.

"We are delighted to have Cord Stähler join us. His expertise makes him the ideal choice for consistently

advancing our course of realigning our global strategy and raising our profile as a leading provider of innovative dental solutions," CEO Don Casey explains.

With Cord Stähler, Dentsply Sirona is gaining a renowned expert in healthcare, life science and diagnostics. He holds a PhD in Human Genetics and brings many years of experience in leadership roles with global companies. Based at Dentsply

Sirona's Bensheim site, he will be responsible for establishing a product development and innovation strategy for pioneering dental technology across all areas. In this capacity, he will report directly to CEO Casey.

Michael Geil, Managing Director

Continued on Page 15



DENTAL TRIBUNE

The World's Dental Newspaper - Pakistan Edition

Publisher/CEO

Syed Hashim A. Hasan
hashim@dental-tribune.com.pk

Editor Clinical Research

Dr. Inayatullah Padhiar

Editors Research & Public Health

Prof. Dr. Ayyaz Ali Khan

Editor - Online

Haseeb Uddin

Designing & Layout

Sh. M. Sadiq Ali

Dental Tribune Pakistan

3rd floor, Mahmood Centre, BC-11, Block-9
Clifton, Karachi, Pakistan.
Tel.: +92 21 35378440-2 | Fax: +92 21 35836940
www.dental-tribune.com.pk
info@dental-tribune.com.pk

Dental Tribune Pakistan cannot assume responsibility for the validity of product claims or for typographical errors. The publisher also does not assume responsibility for product names or statements made by advertisers. Opinions expressed by authors are their own and may not reflect of **Dental Tribune Pakistan.**

International Imprint

Publisher/Chief Executive Officer **Torsten R. Oemus**

Chief Financial Officer **Dan Wunderlich**

Director of Content **Claudia Duschek**

Senior Editors **Jeremy Booth**
Michelle Hodas

Clinical Editors **Nathalie Schüller**
Magda Wojtkiewicz

Editor & Social Media Manager **Monique Mehler**

Editors **Franziska Beier**
Brendan Day
Luke Gribble
Kasper Mussche

Assistant Editor **Iveta Ramonaite**

Copy Editors **Ann-Katrin Paulick**
Sabrina Raaff

Business Development & Marketing Manager **Alyson Buchenau**

Digital Production Managers **Tom Carvalho**
Hannes Kuschick

Project Manager Online **Chao Tong**

IT & Development **Serban Veres**

Graphic Designer **Maria Macedo**

E-Learning Manager **Lars Hoffmann**

Education & Event Manager **Sarah Schubert**

Product Manager Surgical Tribune & DDS.WORLD **Joachim Tabler**

Sales & Production Support **Puja Daya**
Hajir Shubbar
Madleen Zoch

Executive Assistant **Doreen Haferkorn**

Accounting **Karen Hamatschek**
Anita Majtenyi
Manuela Wachtel

Database Management & CRM **Annachiara Sorbo**

Media Sales Managers

Melissa Brown (International)
Hélène Carpentier (Western Europe)
Matthias Diessner (Key Accounts)
Maria Kaiser (North America)
Weridiana Mageswki (Latin America)
Barbora Solarova (Eastern Europe)
Peter Witteczek (Asia Pacific)

Executive Producer **Gernot Meyer**

Advertising Disposition **Marius Mezger**

Dental Tribune International GmbH

Holbeinstr. 29, 04229 Leipzig, Germany
Tel.: +49 341 48 474 302 | Fax: +49 341 48 474 173
info@dental-tribune.com | www.dental-tribune.com

©2019, Dental Tribune International GmbH. All rights reserved. Dental Tribune International makes every effort to report clinical information and manufacturer's product news accurately, but cannot assume responsibility for the validity of product claims, or for typographical errors. The publishers also do not assume responsibility for product names, claims, or statements made by advertisers. Opinions expressed by authors are their own and may not reflect those of Dental Tribune International.

How can you provide **more comfort** to your sensitivity patients?

Apply the superior science of **Colgate® Sensitive Pro-Relief™**  Toothpaste for **superior** sensitivity relief*



Instant[†] relief in office
48.9%¹ reduction in sensitivity after prophylaxis[†]

"Is it supposed to be sensitive?"
—Real Patient[¶]



Lasting[§] relief at home
90.1%¹ reduction in sensitivity after 2 weeks[†]

"Even when I drink cold water, it is much better."—Real Patient[¶]



Their satisfaction will speak for itself.^{¶1}

*Vs conventional sensitive toothpastes containing 5% potassium nitrate (equivalent to 2% potassium ion).

[†]For instant relief, apply directly to the sensitive tooth with fingertip and gently massage for 1 minute.

[‡]Air blast hypersensitivity test in a clinical study after 1 application and after 2 weeks.

[§]Lasting relief with continued 2x daily brushing.

[¶]In the same study, testimonials were recorded from real patients after treatment with Colgate® Sensitive Pro-Relief™.

References: 1. Ayad F, Ayad N, Vazquez J, et al. *Am J Dent* 2018.

Colgate®

Teamwork makes the dream work; Dr Jamal Syed

Dr Jamal Syed is an accomplished dental surgeon who specializes in Periodontology and Implantology. He has passionately engaged himself in dental research throughout his career, and has many popular research papers to his name. Currently, Dr Jamal is employed at King Abdul Aziz University, Jeddah, KSA, where he is In-charge Advanced Technology Dental Research Laboratory and Assistant Professor Oral Biology and Periodontology. He is also visiting faculty at two different dental institutes in Italy.



Photo: DT Pakistan

By Dr H. Mustafa Khan

Dental Tribune Pakistan: Tell us a little about your background, especially what made you choose dentistry as your profession?

Dr Jamal Syed: My story is a little bit different as compared to others. Mostly our parents want their children to become medical professionals instead of going into dentistry. In my case I was admitted to SMC (now JSMU) as MBBS first year student. Luckily a close friend of my father visited him from UK; he told him to get me admitted in dentistry. So upon his advice my father got convinced and told me to get admission in BDS.

I came into BDS because of my father's wish, but I started to love dentistry when in 2nd year my

“My country can only flourish when we can establish think tanks for our health and education systems.”

Professor of Pathology, once in his lecture, told us that if he got the chance to be a dental surgeon then, he would opt to do that. From that day dentistry is my passion.

DTP: What prompted you to select your particular specialty, and who influenced or guided you?

JS: It was Dr Zohair Siddiqui (late). May Allah bless him with the best place in Jannah (Amen). He was my dearest teacher and always a guide and mentor to me. So you can say that he was the main influence when it came to selecting my specialties as a Periodontist, Oral Implantologist and Oral Biologist.

DTP: Why is it that there are very few dentists with your specialty?

JS: It could be lack of interest in producing Postgraduates in this specialty. Secondly, Periodontology does not come with a promise of much money if not associated with implants.

DTP: What are the common periodontal diseases in Pakistan? What are the reasons behind them, and how many of these are preventable?

JS: To be frank, I have not seen any national survey that gives you the precise statistics of the most prevalent diseases in Pakistan. Having said that regional/institution based studies cannot determine the ratio of periodontal disease among a population of 220 million. But

“Periodontology does not come with a promise of much money if not associated with implants.”

worldwide surveys tell us that gingivitis is the most prevalent disease. If monitored with regular dental visits and good oral hygiene practice most of the periodontal diseases may be prevented.

DTP: You are a fellow and master, which one is better and why?

JS: Masters and PhDs are degrees, and so they are respected and accepted as genuine qualifications worldwide, including all developed countries of the first world.

Fellowships are of two types: first one is awarded in recognition of your experience and/or publications. This is the one which I have received. The second one is merely a diploma, or in

“Masters and PhDs are degrees, and so they are respected and accepted as genuine qualifications worldwide”

many instances just entrance qualification into any specialty, which can never be better than a degree even if it is of three to four years.

DTP: How was your experience at University of Dundee, Scotland, UK and can you draw a comparison with our local teaching standards?

JS: Experience with Dundee was awesome as I learnt a lot from there. Dundee is among the top hundred universities in the world, and while I was studying there, it was number one in Europe and UK.

Although Pakistan is a place with ample talent but unfortunately this talent remains undiscovered until you get acquainted with international standards; or when some individual gets the opportunity to learn directly from International Universities of higher ranking.

There is no comparison of Pakistani institutions with international universities, even though Pakistani academicians are trying hard to meet the international standards, which I appreciate. One reason could be lack of availability of funds.

DTP: Where do we stand when it comes to medical or dental research work and publications?

JS: Sorry to say this but it is a long debate and better be discussed in a separate interview. Dental research is my passion, which I am performing most of the time in Saudi and Italian research laboratories.

If I have to comment: in short majority of us in Pakistan are not interested in genuine research. I must say majority, but that does not mean that people are not working on research projects here in Pakistan at all.

DTP: Do you feel that new dentists graduating are practice ready and prepared to face challenges of practice management?

JS: Yes, as I mentioned earlier that we are a talented nation and obviously the coming generations are always better than the previous ones. They just need sincere and honest guidance from us as seniors.

“Besides improving the clinical skills and standards of a dentist we should also improve the dental care professionals' abilities according to the international standards.”


DTP: How do you think you can contribute for the betterment of the dental profession?

JS: I have been out of Pakistan since 2008, serving in various international universities as full time/visiting faculty. Two Italian institutes and a research lab have appointed me as a visiting faculty and oral scientist.

Whenever I visit Pakistan I have always extended my full co-operation to all my colleagues working here, especially in Karachi. I am always ready to deliver lectures and hands-on workshops during my stay in the country, and even skype sessions while I am not in Pakistan. But no one tried to avail this opportunity except for a few.

Continued on Page 15

SENSODYNE
RAPID ACTION



**BEAT
SENSITIVITY
PAIN
FAST**

Clinically proven relief in just
60 SECONDS



1st Symposium of Pakistan Academy of Paediatric Dentistry

DT Pakistan Report

PESHAWAR - The Pakistan Academy of Paediatric Dentistry arranged a one-day symposium at the Khyber College of Dentistry, Peshawar. It was the first symposium held by the Pakistan Academy of Paediatric Dentistry hosted by the Khyber Pakhtunkhwa chapter.

Dental health care for children is an ignored area of health care in Pakistan. The burden of dental diseases is the greatest in children. The Pakistan Academy of Paediatric Dentistry was formed by paedodontists to promote the dental health of children and to voice the dental health issues of

children. This symposium served to share views and increase interaction between paediatric dentists as well as dentists from other subspecialties for the benefit of the dental health of children.

The speakers of the symposium were President, Pakistan Academy of Paediatric Dentistry, Prof Dr Amjad Hussain Wyne, Head of Paediatric Dentistry, Institute of Dentistry, CMH Medical College, Lahore, Prof Dr Arham Chahan, Diplomate American Board of Paediatric Dentistry, Consultant, Shifa International Hospital, Islamabad, Dr Noeem Arshad, Assistant Prof & Head of Department of

Paediatric Dentistry, Rehman College of Dentistry Peshawar, Dr Laila Mustafa, and Consultant Dr Sara Rehman.

The topics of the presentations included 'Oral midazolam (in management of children)', 'Challenges in handling and treating paediatric patients', 'Paediatric restorative dentistry under general anesthesia: the third dimension', 'Canine gouging and infant oral mutilation: a case report' and 'The importance of retaining primary teeth during childhood'.

The symposium was attended by the university's faculty members, dental surgeons, postgraduate trainees, undergraduate



Photographs: DT Pakistan

students, and house officers from various dental colleges across KP.

The speakers are renowned educationists and clinicians in the field of Paediatric Dentistry. They shared their educational and clinical experiences with the audience.

The undergraduate and postgraduate students benefited by having

interaction with the national giants in the field of Paediatric Dentistry.

This symposium was arranged to serve as a platform for sharing views on the important dental health issues of children. Moreover, it would increase the interest of general dentists in Paediatric Dentistry and promote this emerging discipline of dentistry.

'Anchor for success: Go micro' - PAO workshop at de' Montmorency College

LAHORE - A clinical workshop "Anchor for success: Go micro" was recently held in collaboration with the Pakistan Association of Orthodontics (PAO) at one of the most prestigious



Photographs: DT Pakistan



dental institutes in Punjab, the de' Montmorency College of Dentistry. The event was chaired by the president of PAO, Professor Dr Ghulam Rasool, and supervised by the Dean of the de' Montmorency College of Dentistry, Professor Dr Waheed ul Hameed.

The workshop was facilitated by Dr Ahsan Mahmood Shah, Associate Professor and in charge of the Department of Orthodontics at Khyber College of Dentistry and Dr Junaid Israr, Associate Professor, Lahore Medical and Dental College.



Dr Muhammad Saood (Assistant Professor), Dr Sulaiman, and Dr Faizan Hassan from the Khyber College of Dentistry were also part of the team for facilitation.

Dr Ahsan initiated the workshop with a lecture on the use of micro-implants in orthodontics followed by a detailed discussion on clinical cases.

Fifty-nine participants

navigated through the series of stations where they were given the opportunity to interact with facilitators for a hands-on experience with micro-implants.

The participants were enlightened with the practicality of the workshop and were very happy with the PAO for organizing events specifically for their learning. -PR

Implantology seminar at AIDM by Dr Choi

KARACHI - The Altamash Institute of Dental Medicine organized a dental implant seminar for promoting continuing dental education. A lecture and hands-on was demonstrated by a renowned implantologist, Dr Choi from Korea. In his address, he discussed the various challenges faced by dental surgeons during implant placement procedures and introduced a new implant placement guide by DOI NAVI, which reduces the chances of error, patient discomfort, and the time of placing implants at the right position. He also presented some of his cases which were marvellously done.

After a brief lecture, he gave a demonstration of how to use the implant placement guide with a sinus lifting procedure. At the end of the session, final year students and faculty raised



Photographs: DT Pakistan



questions which were answered by Dr Choi and his team. Later, Professor Dr Mohammad Altamash gave his vote of thanks and appreciation to Dr Choi for providing awareness for the best practices and also to the students and dental faculty for being a part of the session. -PR



HELP KEEP YOUR PATIENTS ON A JOURNEY TO HEALTHY GUMS

PARODONTAX® TOOTHPASTE IS CLINICALLY PROVEN TO REDUCE PLAQUE, BLEEDING GUMS AND INFLAMMATION

4X

greater plaque removal*¹

48%

greater reduction in bleeding gums*¹

Recommend **parodontax®** toothpaste to help patients maintain their optimal gum health between dental visits.

DAILY FLUORIDE TOOTHPASTE FOR HEALTHY GUMS & STRONG TEETH

parodontax®

EXTRA FRESH



Helps stop and prevent bleeding gums

GlaxoSmithKline Consumer Healthcare Pakistan Ltd.
35-Dockyard Road, West Wharf, Karachi - 74000

GSK is committed to the effective collection and management of human safety information relating to our products and we encourage healthcare professionals to report adverse events to us on +92 (21) 111-475-725 or pk_pharmasafety@gsk.com

* Compared to a regular toothpaste and professional clean and 24 weeks' twice-daily brushing.

Anti-ageing medicine and orthodontic appliance therapy treatment: An interdisciplinary approach

By Derek Mahony

Anti-ageing is a branch of medicine focused on how to prevent, slow or reverse the effects of ageing, thus helping people to live longer and healthier lives. Recently, however, more evidence-based medicine has led to antiageing becoming a multi-billion-dollar industry. In the past few decades, the market for anti-ageing products and services has grown into a global industry valued at an estimated US\$261.9 billion in 2013, up from US\$162 billion just five years before, according to BCC Research, a publisher of technology market research reports based in Wellesley in the US.

enhances facial symmetry, producing soft-tissue changes consistent with improved facial esthetics. This appliance can be added to the treatment protocol of facial injection to create a relatively non-invasive interdisciplinary approach to midface enhancement.

With this article, we show how orthopaedic/orthodontic appliance therapy, in conjunction with the placement of dermal fillers for the reduction of lines/wrinkles and depressions in the face, can produce desirable facial soft-tissue enhancement. Furthermore, we show that the volumetric changes achieved by this combined treatment approach can produce a desirable result, namely a more youthful appearance.

decompress her temporomandibular joint), was fabricated and delivered (Fig. 2). When she closed on the bite block, her occlusion freed up and the muscles realigned the mandible so that her centre line lined up correctly. Her headache symptoms were relieved in three weeks and her maximum opening was improved to 42 mm. The patient continued Homeoblock treatment for nine months.

Intra-oral and extra-oral photographs were taken to monitor treatment, and 3-D stereo photo grammetry was performed. Extra-oral 3-D digital photographs were taken with a facial capture system (3dMD). A facial capture system (3dMD/Kodak) and stereophotogrammetry were used to

a study published in the Journal of Dentistry in 1996.³ It was concluded that “stereo photogrammetry is a suitable 3-D registration method for quantifying and detecting development changes in facial morphology”.

Evaluating the patient’s face over the nine months of Homeoblock treatment for her temporomandibular dysfunction showed a change in the morphology of the face (Fig. 3). Morphometric analysis was performed by superimposing before and after 3-D images and using finite element modelling. Thousands of triangular reference points were used to establish the change. The blue area indicated no change and the red to orange areas showed an increased dimension of up to 2.9 mm. We saw

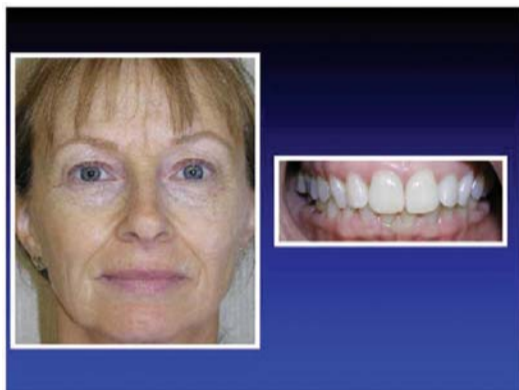

Fig. 1: Pretreatment facial and anterior intra-oral photographs (note deep dental overbite).




Fig. 2: The Homeoblock appliance.

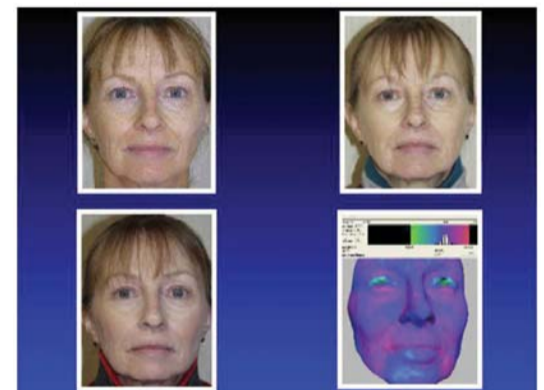

Fig. 3: The pretreatment face, the post-treatment face at six months and nine months, and finally, a morphometric evaluation of the change.

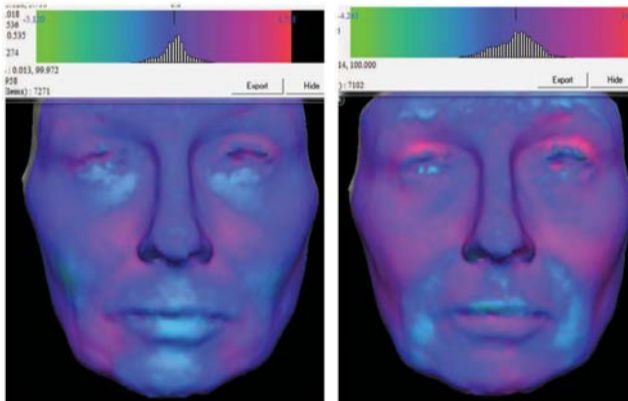


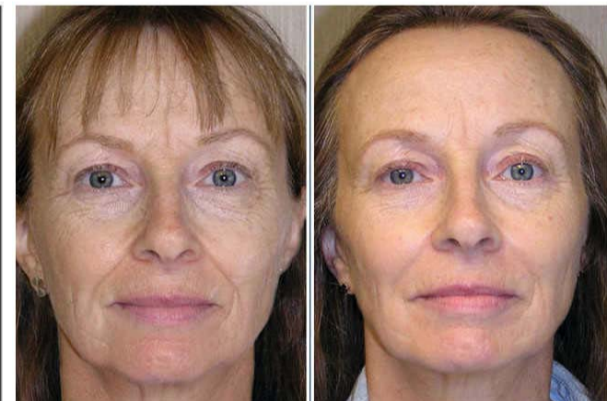Fig. 4: Morphometric evaluation of the final results: finite element analysis showed increased facial volume with a directional change of almost 4 mm, indicated by the red to orange colour.




Fig. 5: Superimposing the red post-treatment face over the blue pretreatment face, we can graphically illustrate the volumetric changes that occurred during our treatment.




Fig. 6: Morphological facial changes in the lips, zygoma and jowl area after the placement of 1 ml Restylane and 1.3 cc Radiesse.



Figs. 7a & b: Before and after facial photographs.

The recent medical literature and evidence-based medicine show that, as we age, there seems to be a loss of fat volume in some areas of the face, as well as a change in the morphology of the facial skeleton. Facial soft-tissue augmentation by injection has become increasingly popular as a minimally invasive option for patients seeking cosmetic facial enhancement. Replacing lost soft-tissue volume allowed for a more comprehensive approach to total facial rejuvenation. It has been demonstrated that orthodontic treatment with an intraoral orthopaedic dental appliance (Homeoblock, Ortho-Smile) increases soft-tissue volume and

Case study

A healthy woman in her mid-sixties presented for treatment with a strong desire to improve her facial appearance (Fig. 1). Her oral hygiene was good and there was no active periodontal disease. She had headache symptoms and clinical examination showed a displacement with reduction on her right side, with a maximum jaw opening of 38 mm. Her centre line was displaced 2 mm to the right and lined up when she opened < 10 mm, indicating that she had a mandibular displacement to the same side. A Homeoblock appliance, with a 5 mm bite block on the right side (to

generate a clinically accurate digital model of the patient’s facial surface. It uses a technique of stereotriangulation to identify external surface features viewed from at least two cameras. This approach incorporates the projection of a unique, random light pattern that is used as the foundation for triangulating the geometry in 3-D. The capture takes < 2 ms per frame. The data is processed and a highly precise < 0.5 mm root mean square of the distance measured is calculated, creating a digital model of the patient that is ready for immediate clinical use. Stereophotogrammetry for quantifying facial morphology was introduced in

an increased volume above and under the eyes, the zygomatic region, the upper lip, and the marionette and pre-jowl areas. From the facial photographs, we could see a reduction in the lines, wrinkles and depressions (Figs. 4 & 5).

After nine months, the patient’s facial changes prompted her to go forward with injections of dermal fillers. She was given 1 ml of Restylane (Galderma) for lip enhancement and two 1.3 cc corrections with Radiesse (Merz Aesthetics) in the pre-jowl and marionette areas and along the inferior border of the mandible, and the inferior

Continued on page 14

The complete digital implant workflow

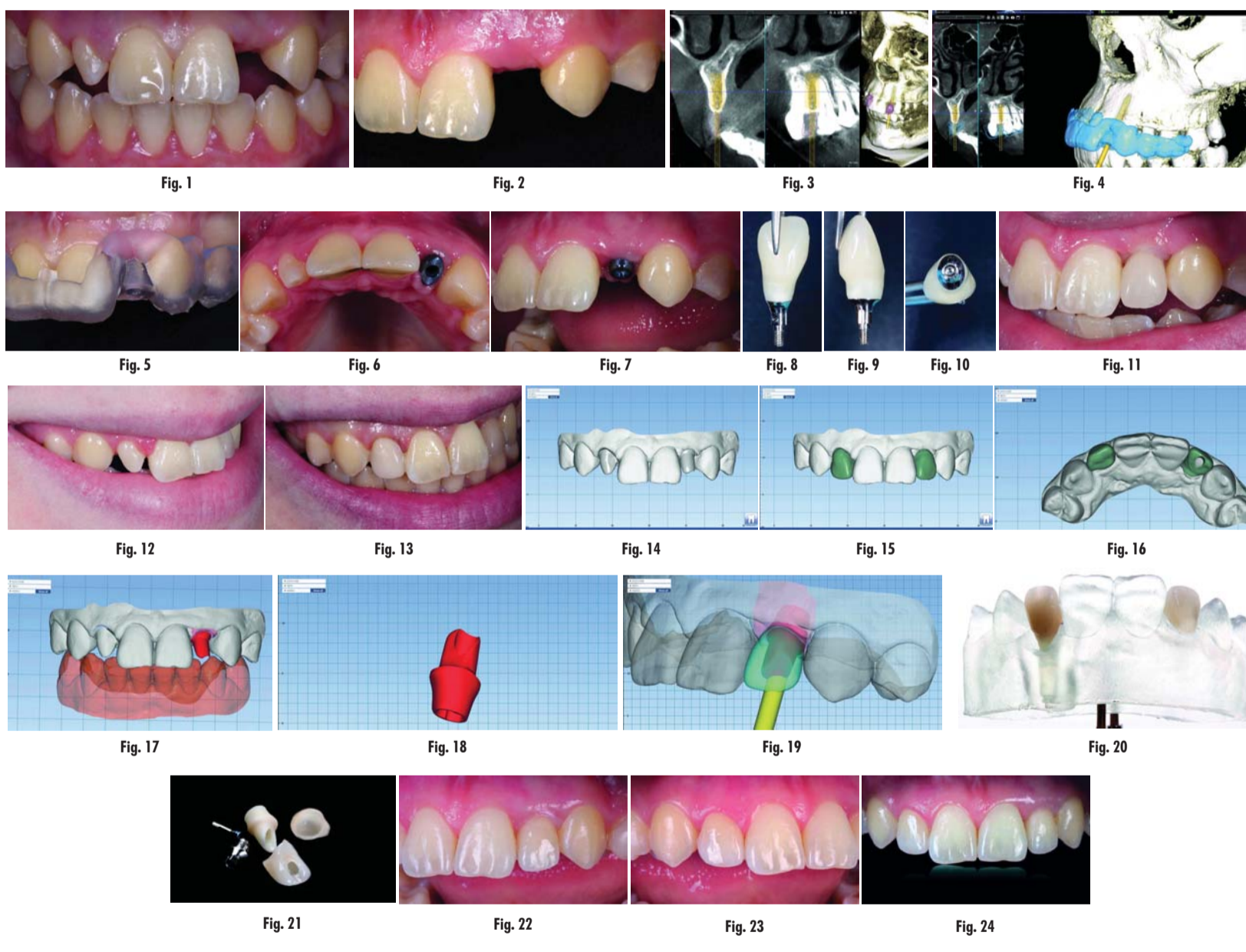
By Dr Kirill Kostin, Russia

Planmeca is known for high-tech innovations and continuous product development. The company's powerful Planmeca Romexis software platform allows all stages of the dental implant and aesthetic prosthodontic treatment to be completed using one piece of software, from the computer-assisted design of patients' smiles to the fabrication of surgical guides. The following clinical case, which I performed together with my colleagues Dr Ponomarev, Dr Kozhevnikov and Dr Yarokhin, illustrates how digital solutions can be used in

fabrication of a ceramic restoration. This article presents a clinical case in which the treatment was completed using the Planmeca Romexis 3D Implant Guide software, Planmeca PlanCAD Premium software and Planmeca PlanMill 40 milling unit. The clinical case features a female patient, who complained about missing tooth #22, as well as the shield-like shape of tooth #12 (Figs. 1 & 2). During the initial examination, the area around the missing tooth was estimated to be quite narrow for an implant. However, the patient declined orthodontic preparation, as she had already previously had orthodontic treatment with orthodontic surgery.

even though the anatomical conditions appeared to be less than advantageous. We achieved a torque of 30 Ncm and attached a healing abutment to the implant (Figs. 6 & 7). Three months after the implant placement operation, the osseointegration of the implant fixture was completed. A temporary crown was fabricated on the implant from a VITA ENAMIC multiColor block to support the formation of soft tissues (Figs. 8–10). We improved the original design on the Straumann superstructure with gum contouring. On tooth #12, crown lengthening was performed with an electrocoagulator (Figs. 11–13).

anatomical Empress crown (Figs. 20 & 21). The ceramic facing concealed the excessive brightness of the zirconium, and we were able to achieve the desired colour. Thanks to the digital workflow, we managed to fulfil the wishes of the patient. (Figs. 22–24). **Conclusion** With digital technologies, the entire implant workflow can be completed in the dental clinic, from planning to fabrication of the restorations. Digital planning increases the reliability of the implant treatment and helps the dentist to succeed in the operation. Digital tools allow achieving the maximum functional and aesthetic



prosthodontic treatment, implant placement and restoration design. According to our experiences, digital CAD/CAM technologies enable maximal functional and aesthetic results compared to traditional methods.

Clinical case report

The clinical case illustrates the advantages of using Planmeca CAD/CAM solutions in the digital planning of an implant placement and surgical guide, as well as in the

In this particular case, we started with an aesthetic analysis of the patient's CBCT data and concluded that a Straumann implant with a 2.9 mm diameter would fit in the area of tooth 22, if we used a surgical guide for maximum precision (Figs. 3–5). For tooth #12, we decided to fabricate a thin-walled IPS e.max ceramic restoration (Ivoclar Vivadent).

Thanks to digital planning and a carefully fabricated surgical guide, the implant was placed successfully,

Once the formation of the soft tissues was complete, tooth #12 was minimally prepared for the ceramic crown with the help of a surgical microscope. After the preparation, the teeth were scanned in order to digitally design a custom abutment and crowns (Figs. 14–19).

The final smile design was planned digitally together with the patient. For the implant structure, we chose an individual zirconium abutment screw with a ceramic facing and a fully

result even in combined operations in which an implant placement and ceramic restoration are performed simultaneously.

Thanks to the development of modern technologies, a 3D model of a patient's set of teeth can now be acquired in only a few minutes, without infringing on the comfort of the patient. At the same time, combining a CBCT image with an intraoral scan enables the dentist to

Continued on Page 14