

# DENTAL TRIBUNE

The World's Dental Newspaper • India Edition

PUBLISHED IN INDIA

www.dental-tribune.com

VOL. 1 No. 2

## News in brief

### Single council to regulate medical education

The Government of India, to have an organised approach in medical education, proposes to scrap off all the regulatory bodies and plan a single regulatory body—National Council of Human Resources in Health—to oversee seven departments related to medicine, nursing, dentistry, rehabilitation and physiotherapy, pharmacy, public health/hospital management and allied health sciences. The council will be implanted as an autonomous body independent of governmental control with ample power, including quasi-judicial.

**Dental Tribune**  
The World's Dental Newspaper  
India Edition

Published by

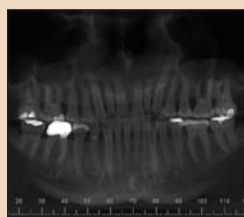
**JAYPEE BROTHERS**  
MEDICAL PUBLISHERS (P) Ltd.

### Rising smoking rates among women

The Tobacco Atlas, Third Edition published by The American Cancer Society and World Lung Foundation has reported that India has the 3<sup>rd</sup> highest number of female tobacco users in the world. Study among 11.9 million female consumers of tobacco in India, shows 5.4 million smoke & the rest chew it. Further, the report says that the gap in tobacco death rates between men and women is closing because of this trend among women in many countries including India, & particularly among young women.

### Smokers have fewer and flatter taste buds

A study based on analysis of tongues of 62 Greek soldiers says, smokers have fewer and flatter taste buds. A team of researchers used electrical stimulation to test the taste threshold and found that application of electric current to the tongue, generates a unique metallic taste but 28 smokers in the study group scored worse than 34 non-smokers. Also on endoscopic examination smokers tongues show flatter fungiform papillae, with reduced blood supply.



### Technology

Cone Beam CT the change of paradigm in modern dentistry

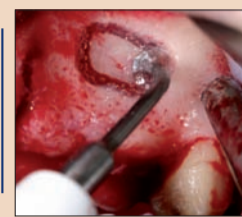Page 5



### Interview

With Dr. Sushil Koirala

Page 14



### Trends & Application

Piezosurgery—precise and safe new oral surgery technique

Page 20

## FDA says mercury dental fillings not harmful

Reuters

**WASHINGTON, DC, USA:** The US, Food and Drug Administration recently reported that silver-coloured dental fillings containing mercury are safe for patients, reversing an earlier caution against their use in certain patients, including pregnant women and children. While elemental mercury has been associated with adverse health effects at high exposures, the levels released by dental amal-

gam fillings are not high enough to cause harm in patients, the FDA said, citing an agency review of roughly 200 scientific studies.

In 2006, Moms Against Mercury and three other groups sued the FDA to have mercury fillings removed from the US market. Later that year, an FDA panel of outside experts said most people would not be harmed but that more information was needed.

But Susan Runner, acting director for the FDA division that oversees dental devices, said there was no “causal link” between amalgam fillings and health problems. “The best available scientific evidence supports the conclusion that patients with dental amalgam fillings are not at risk,” she told reporters on a conference call. Over the past 20 years, the agency has received just 141 reports of problems in patients with the fillings, she added.



Containers with dried amalgam waste mud. (DTI/Photo Anke Schiemann)

DTI page 5

## Green tea may help reduce periodontitis



DTI/Photo courtesy of Spictex International

Dr. Naren Aggarwal  
DTI India

A recent research shows that green tea, the most popular beverage worldwide, may help reduce periodontal disease. Green tea refers to a variety of tea that has during its processing undergone minimal oxidation, & hence contains good amounts of antioxidant chemicals. In India, tea is consumed mostly in the CTC (cut, tanned and cured) form that brings out strong flavors and color but loses out on the content of antioxidants such as polyphenols. These are chemicals that are currently under intense research for their cardiovascular, anticancer and anti-aging properties. Polyphenols,

notably catechin, are believed to be responsible for most of these claimed health benefits. Lead investigator of this study, Dr. Yoshiro Shimazaki of Kyu-shu University, Fukuoka, Japan, said, “Few previous studies suggest that green tea polyphenols inhibit the growth and cellular adherence of periodontal pathogens and production of virulence factors by these pathogens”. Increasing trend of green tea consumption prompted her team to conduct this epidemiological study that shows a modest inverse association between the intake of green tea and periodontal disease, but the relationship was found to be weak. Adding

caution, she further added, “Therefore, I think that it is difficult to prevent periodontal disease only by drinking green tea and that conventional oral care is the most important”. This study, however, did not confirm the mechanism

of green tea providing this benefit.

Brooke Bonds, the leading tea company in India has recently released its green tea in the market fueling speculation on the increasing demand for this tea in the coming years. DTI

“e.max LITHIUM  
DISILICATE IS THE  
MOST ROBUST  
CERAMIC SYSTEM  
TESTED TO DATE.”\*

IPS  
e.max

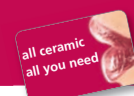### This changes everything.

The durability of lithium disilicate glass-ceramic crowns is higher than that of veneered zirconium oxide. Lithium disilicate is therefore the material of choice for single crowns: strong, esthetic, economical. Try it yourself.

1,000 N\*\*  
IPS e.max  
lithium  
disilicate

\*Mouth Motion Fatigue and Durability Study  
Petra C Guess, Ricardo Zavanelli, Nelson Silva and  
Van P Thompson, New York University, March 2009  
1 90% failure by 100,000 cycles  
2 No failures at 1 million cycles

350 N\*\*  
veneered  
zirconium  
oxide



www.ivoclarvivadent.com

Ivoclar Vivadent AG  
Benderstr. 2 | FL-9494 Schaan | Liechtenstein | Tel.: +423 / 235 35 35 | Fax: +423 / 235 33 60

Ivoclar Vivadent Marketing Ltd. (Liaison Office) India  
503/504 Raheja Plaza | 15 B Shah Industrial Estate | Veera Desai Road, Andheri (West) | Mumbai 400 053 |  
Tel.: +91 (22) 2673 0302 | Fax: +91 (22) 2673 0301 | E-mail: info@ivoclarvivadent.firm.in

ivoclar  
vivadent  
passion vision innovation

September 12<sup>th</sup>

# WORLD ORAL HEALTH DAY

*To commemorate the world oral health day, Indian Dental Association (IDA), announced the launch of Tobacco Intervention Initiative and Women Dental Council*

Naren Aggarwal  
DT India

On the World Oral health Day, the Indian Dental Association (IDA) launched an ambitious awareness program, Tobacco Intervention Initiative (TII), by pledging to engage its member dentists to sensitize their patients to health hazards of tobacco consumption, and help quit the addiction. The program is voluntary and interested dentists need to receive structured training at the designated centers before they can offer this free-of-cost service to their patients.

Dr. Ashok Dhoble, secretary-general, IDA said, "For dentists to start TII centers in their practices, they would first need to undergo training by experts on how to assist patients overcome nicotine dependence through a certificate program." "In this, a TII centre kit consisting of technique manual kit and CD, patient education CD and brochure, and a poster on patient education would be provided to each attendee," he added. A TII website is also slated to be launched for professionals and public to access information related to activities planned under this initiative. Mumbai took the lead by warming up to this campaign by opening 56 TII centers, while Delhi began with three such centers. IDA is hoping to see 5000 TII centers operating by the end of 2010, covering all the regions of the country.

"Dentists as oral physicians should use every opportunity in their daily practices to take up this cause with their patients to impress upon them the harmful short-and long-term effects of tobacco abuse" commented Dr. Mahesh Verma, who is the dean of Maulana Azad Dental College, New Delhi. When asked how this effort would be different from the tobacco cessation programs already in function at various chest clinics in the country, he said "although TII



DTI/Photo courtesy of Indian Dental Association



DTI/Photo courtesy of Indian Dental Association

centers would not be offering nicotine replacement therapy or approved drugs such as bupropion or varenicline, dental professionals would emphasize the need to stop tobacco use, and help their patients seek appropriate therapy to be able to kick this habit."

In India, each year almost 900000 people lose their lives due to cancers (oral and lung), and chest and heart problems that can be linked directly to the abuse of tobacco. According to the third National Family Health Survey, a whopping 57% of males and 11% of females use nicotine in some form. The problem is more worrisome amongst young people between 17-22 years, almost half of whom are in the habit of having tobacco. Interestingly, almost 50% of tobacco is consumed in a chewable form along with betel leaves and lime, which, in certain regions of India, has resulted in highest rates of oral cancer in the world.

Government of India plans to initiate a nation-wide tobacco control program that will aim to discourage use of this product as well as encourage farmers to shift to non-tobacco

crops in its 11th 5-year plan. In this direction, the health ministry recently was able to make it legally mandatory to display graphic warning in large-fonts on all the tobacco products, after battling stiff resistance from the pro-tobacco groups for several years. Smoking at all public spaces and offices is already prohibited in India. But, despite all such efforts, tobacco consumption continues to rise in India, while a reverse trend has been achieved in the western world. With such an enormous public health challenge to cope with, TII by dentists is one more effort to gather against tobacco, and the tangible gains of this initiative will only be known later.<sup>DT</sup>

Isha Goel  
DT India

Acknowledging the sizeable presence of female dentist members, the Indian Dental Association (IDA), on the occasion of World Oral Health Day, raised the curtains to the formation of Women Dental Council (WDC) under its wings, with the purpose to provide them with an official platform to air their views and address their unique concerns. The need for such a step has been building up for quite sometime considering the fact that, today, almost 80 percent of the dentists graduating from 240 colleges are women. Dental associations from US, UK, and Singapore already have similar official bodies in existence that represent female dentists.

Dr. Sabita Ram, chairman of WDC, on this occasion, outlining the main objectives said, "the mission behind this initiative is to create maximum working opportunities for women dentists, and to understand their unique requirements and addressing them. Given the current challenges that face women dentists who struggle keeping a balance between career and family in a constantly changing work environment, the WDC will act as a vehicle providing help ranging from finding jobs to setting-up practices, while simultaneously looking into the gender issues involved."

Dr. Meera Verma, Vice Chair person of WDC said, "The WDC would take initiative in promoting the general and oral health of women and children." "A lot of women dentist have come forward and have expressed their desire to be part of the body to attain the vision of WDC" she added.

Women Dental Council of IDA was conceptualized and inaugurated during the Nagpur, IDA annual conference in Feb 2009. The launch programme of the WDC in Northern India was held on September 12, to coincide with the oral health day.

The guest of honor at this function Dr. Kiran Bedi, after finding that in the present governing body of IDA there were few women office bearers, prevailed on the general secretary of IDA, Dr. Ashok Dhoble, to commit reserving 50% of such posts only for women dentists in future. This, she felt, was the necessary first step for IDA to show its seriousness about the formation of WDC. Dr. Kiran Bedi is a well known social worker who has received the Magsaysay award for her contributions, and was adjudged the most admired woman in 2002. She also hosts a popular TV show on family disputes that helps raise public awareness to the legal solutions of such conflicts.<sup>DT</sup>

## International Imprint

Executive Vice President  
Marketing & Sales

Peter Witteczek  
p.witteczek@dental-tribune.com

## DENTAL TRIBUNE

The World's Dental Newspaper • India Edition

Published by Jaypee Brothers Medical Publishers (P) Ltd., India

©2009, Dental Tribune International GmbH. All rights reserved.

Dental Tribune India makes every effort to report clinical information and manufacturer's product news accurately, but cannot assume responsibility for the validity of product claims, or for typographical errors. The publishers also do not assume responsibility for product names or claims, or statements made by advertisers. Opinions expressed by authors are their own and may not reflect those of Dental Tribune International.

Chairman  
Torsten Oemus  
toemus@dental-tribune.com

Director  
P.N. Venkatraman  
venkatraman@jaypeebrothers.com

Chairman DT India  
Jitendar P. Vij  
jaypee@jaypeebrothers.com  
Chief Editor  
Dr. Naren Aggarwal  
naren.aggarwal@jaypeebrothers.com

Editor  
Dr. Isha Goel  
isha.goel@jaypeebrothers.com

Editorial Consultants  
Dr. Gurkeerat Singh  
Dr. Amit Garg

Dental Tribune India  
Published by: Jaypee Brothers Medical Publishers (P) Ltd.  
4858/24 Ansari Road, Daryaganj,  
New Delhi 110002, India  
Phone: 43574557  
e-mail: jaypee@jaypeebrothers.com  
Website: www.jaypeebrothers.com

# STA System keeps patients comfortable — even during the injection itself

Fred Michmershuizen  
DTA

*SAN FRANCISCO, CA, USA: When it comes to getting from here to there, who wants to ride around in a horse and buggy? And when it comes to delivery of anesthetic before a dental procedure, who wants to use 160-year-old technology? Milestone Scientific, with its Single Tooth Anesthesia (STA) System, is changing the way local anesthesia is being delivered today.*

You can set aside that scary syringe — which frightens patients and causes undue stress — and instead pick up a small handpiece and needle that you hold in your hand like a pen. Because the injection is administered below the pain threshold, your patient will be more comfortable.

According to Dr Eugene R. Casagrande, director of international and professional relations

at Milestone Scientific, who spoke with Dental Tribune during the recent CDA meeting, the Dynamic Pressure Sensing (DPS) technology used by the STA System guides the dentist to the correct spot to give a comfortable and successful intra-ligamentary injection.

The system provides continuous visual and audio feedback, so the dentist knows when the needle has left the correct site or if the needle is blocked.

The STA System is also quite versatile. Casagrande says that despite the device's name, STA System is not just for treating one tooth at a time. Any injection delivered with the traditional dental syringe can be administered more comfortably and more easily with the STA.

Two new, state-of-the-art palatal injections — the AMSA and the P-ASA — can be administered using the STA System in



a comfortable manner to anesthetize multiple teeth and related tissue. Also, an interligamentary injection that is different from the traditional PDL can be administered easily, comfortably and successfully.

There are also benefits for the patient, who is able to have a more comfortable experience, and to the practice itself.

"I call it a win-win-win," says Casagrande. "It is a win for

the dentist because injections are very easy and stress-free to administer. It is a win for the patient because injections are more comfortable, and there is no collateral numbness to the lips, face or tongue. And it is a win for the practice because the STA System affords an efficiency factor that can result in increased productivity."

As Casagrande explains, a patient can be treated in multiple quadrants without having to

return for multiple visits. Even better, he says, it is not uncommon for patients to refer others to a particular dental practice because they are pleased with the way they are treated with the STA System.

"Patients appreciate the fact that dentists who use the STA are going out of their way to make the most difficult and important part of the dental experience as comfortable as possible," Casagrande. [DT](#)

← [DT](#) page 1

That conclusion counters a statement the agency made last June that the fillings may cause health problems in pregnant women, children and fetuses. The FDA's decision could impact makers of metal fillings, which include Dentsply International Inc and Danaher Corp's unit Kerr, as well as distributors such as Henry Schein Inc and Patterson Cos Inc.

According to the American Dental Association (ADA), about 50 per cent of fillings given to patients are mercury-filled, with a growing number of patients instead opting for lighter, tooth-coloured options such as resin composites. The ADA, which represents the dental industry, backed the FDA's decision not to restrict mercury fillings, saying alternatives are also considered "moderate risk" by the FDA.


"The FDA has left the decision about dental treatment right where it needs to be—between the dentist and the patient," ADA

President Dr John Findley said in a statement. But Charlie Brown, a lawyer for Consumers for Dental Choice, said poorer people or those who receive their health care through large institutions such as the US military are more likely to receive the cheaper, silver-coloured fillings and are at greater risk for harm.

"Most consumers, and most dentists, have already switched to the main alternative, resin composite," said Brown, whose group was part of the lawsuit settlement last June that called on the agency to issue more specific rules. His group is now weighing its legal options, he said. Moms Against Mercury President Amy Carson said she was disappointed in the FDA's reversal. Her group, along with several others, filed a new petition with the FDA on Tuesday, again calling for a ban on mercury fillings, she added. [DT](#)

(Edited by Daniel Zimmermann)

## In Pericoronitis / Tooth Abscess<sup>1</sup>




**BIDANZEN<sup>®</sup> FORTE**  
Serratiopeptidase Tablets 10 mg

**OPENS WAY FOR SPEEDY HEALING**

● Significantly reduces post-surgical cheek swelling and pain<sup>2,\*</sup>

\* Dosed along with 1000 mg of paracetamol in surgical extraction of 3<sup>rd</sup> molar.  
Ref. 1. Prescribing Information Bidanzen, India  
2. Al-Khateeb TH, Nusair Y. Effect of the proteolytic enzyme serrapeptase on swelling, pain and trismus after surgical extraction of mandibular third molars. Int J Oral Maxillofac Surg. 2008 Mar;37(3):264-8.

**BIDANZEN & BIDANZEN FORTE: Abbreviated Prescribing Information:**  
Active Ingredient: Enteric film coated tablets containing Serratiopeptidase 5 mg (10,000 units) and 10 mg (20,000 units) respectively. Indications: Remission of swelling after operation, trauma, chronic sinusitis and galactosias; Difficulty to expectorate (bronchitis, pulmonary tuberculosis, bronchial asthma, post anesthesia); pericoronitis of wisdom tooth, alveolar abscess; cystitis.  
Dosage and Administration: **Adults:** Daily dose of 15-30 mg orally, in 3 divided doses after each meal, appropriately adjusted according to patient's age and symptom. **Children:** One 5 mg tablet 2-3 times daily after meals, depending on degree of severity of disease. Contraindications: Hypersensitivity. Warnings and Precautions / Interactions / Effects on Ability to drive and Use machines / Pregnancy and Lactation: No specific data available. Adverse Reactions: Skin - Stevens-Johnson syndrome, toxic epidermal necrolysis, rash, pruritus; Hypersensitivity - Shock, anaphylactic symptoms; Hepatic - Hepatitis, jaundice.

 GlaxoSmithKline  
Refer to full prescribing information before use.  
For full prescribing information please contact: GlaxoSmithKline Pharmaceuticals Ltd., Dr. Annie Besant Road, Worli, Mumbai 400 030.  
© Registered Trademark

For the use only of a registered medical practitioner or a hospital or a laboratory  
BDZ0909/05

## DT Asia Pacific does well in readers poll

Dentists in Asia find Dental Tribune Asia Pacific to be highly up-to-date & applicable to their practice, a readers poll conducted at the FDI World Dental Congress in Singapore has revealed. More than 85 per cent of those interviewed said that they would recommend the newspaper to a colleague. Topics readers were

most interested in were science & research (24%), followed by world news (21%) & news from Asia (20%).

According to the poll, readers would also like to read more about restorative dentistry, practice management, as well as paediatrics & special needs dentistry.

Dental Tribune Asia Pacific was one of the first local editions published by the Dental Tribune International (DTI) media group. The first edition appeared in April 2002. Meanwhile, the newspaper reaches over 30,000 dental professionals in 25 countries including Singapore, Malaysia, Hong Kong,

the Philippines and Australia, to name a few. Their office is based in Hong Kong and Leipzig in Germany.

In the last five years, DTI has grown from a rather small endeavour to a significant global publishing network. At present, DTI—with headquarters in Leip-

zig, New York, and Hong Kong—has publishers and editors in more than 20 countries that deliver the latest news & trends in dentistry to over 600,000 professionals worldwide. Local issues of DTI publications are currently available in all relevant markets, including Germany, the UK, Italy, Russia, China, Japan, the US, France and India. [DTI](#)



### Welcome to the home of dentistry

## and win up to Rs 15,400

Register at **Dentalghar** for the chance to win a bursary towards your studies

#### Win

Dentalghar is proud to have launched an Educational Bursary Award in association with leading providers of interactive teaching and online courses for healthcare professionals, Smile-on Ltd and the worldwide protection organisation Dental Protection Ltd. The bursary is available to help students and clinicians fund their education, maximizing their potential to deliver better oral care.

#### How to enter

To win, register at [www.dentalghar.com](http://www.dentalghar.com) and submit a piece of work that highlights the difficulties of communicating as a dental health professional across barriers of language, culture, faith and other aspects of diversity. The entry can take the form of articles, projects, research reports and other written work over 2000 words.

Finally, visit Dentalghar to hear **Dr. Ashok Dhoble**, the Hon. Secretary General of the Indian Dental Association's latest thoughts on dentistry, in his interview filmed at the **FDI World Dental Congress, 2009**.

To find out more go to [www.dentalghar.com](http://www.dentalghar.com)

**HENRY SCHEIN®**  
MINERVA DENTAL  
partnership in practice

**dentalghar**

**smile-on**  
Inspiring Better Care

Win a  
Rs 15,400  
Bursary

### New organisation makes dentists 'conebeam-ready'



The International Cone Beam Institute is a new independent organisation of cone-beam computed tomography (CBCT) experts that aims to provide the highest level of education, training & product information for 3-D technology to dental professionals worldwide.

As a vendor-neutral organisation, it is an industry first for a company to provide information to dental professionals, future imaging centres and vendors at an international level. General information, such as the various cone-beam scanners available in the US & international markets, as well as general information on available third-party software, will be available to everyone with out charge. ICBI also provides in depth and customised vendor analysis to help practitioners understand this comprehensive technology.

Members of ICBI's website ([www.exploreconebeam.com](http://www.exploreconebeam.com)) are able to review case studies & gain advice from CBCT experts. They also have access to special consulting services, online training and training seminars. In addition, ICBI offers a connection to oral maxillofacial radiologists who can provide reading services to aid in the interpretation of CBCT scans. The organisation also has a blog where users can exchange case studies, ideas and techniques regarding capturing the highest quality images. The International Congress of Oral Implantologists, the world's largest implant education organisation, fully endorses the ICBI. Partners of ICBI include Dental Tribune International and the Dental Tribune Study Club. [DTI](#)

# Cone Beam CT the change of paradigm in modern dentistry—clinical applications in endodontics and periodontology

By Prof. Dr. Liviu Steier

Panoramic radiography changed the paradigm of diagnosis when introduced in the early 1960s. The limitations of two-dimensional radiography are:

1. Magnification,
2. Distortion,
3. Superimposition,
4. Misrepresentation of structures.

## Due to this the use is and was limited

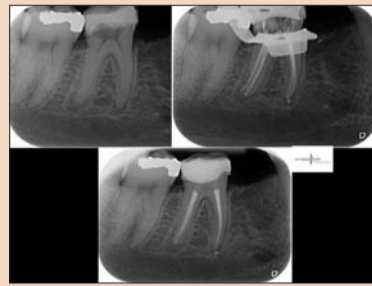
Cone beam technology (CBCT) is a recent introduced technology in dentistry which succeeded to change and continues to change diagnosis, treatment indication and treatment approach—having as such a more comprehensive impact than the introduction of panoramic radiography. Of course one of the most impressive topics is the availability of software for 3D-reconstruction.

It is of great importance to mention that CBCT provides data at lower cost and absorbed doses than conventional CT. The author has resumed this article for the purpose of demonstration how CBCT aided tremendous value to routine dental practice.

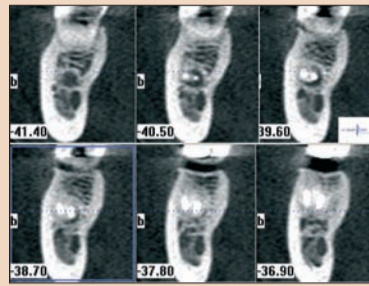
1. Use of CBCT in endodontics
2. CBCT in periodontics

### 2.1 CBCT and soft tissue

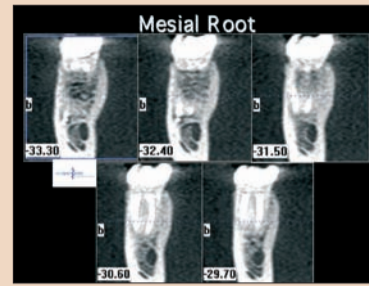
In 2008 Januario et al published in the Journal of Esthetic Restorative Dentistry (J Esthet Restor Dent 20: 366-374, 2008)



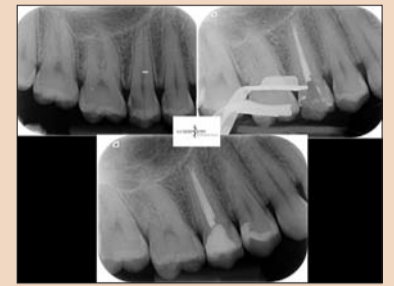Classic periapical radiography before, during and at completion of RCT on tooth 46.



CBCT scans of the RCT performed on tooth 46. Very good opportunity to evaluate the cone fit (www.ct-dent.co.uk).

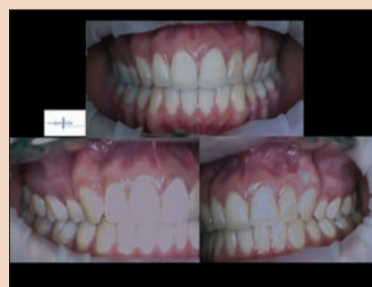

CBCT scans of the RCT performed on tooth 46. (www.ct-dent.co.uk).



Classic periapical radiography before, during and at completion of RCT on tooth 15.

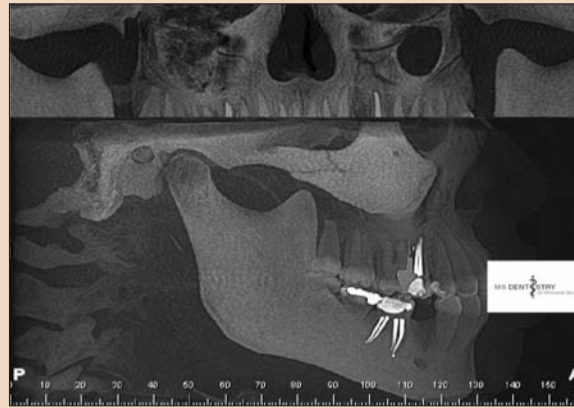
a paper called: 'Soft Tissue Cone Beam Computed Tomography: A Novel Method for the Measurement of Gingival Tissue and the Dimensions of the Dentogingival Unit'. In this paper, the authors described a simple method to diagnose the thickness of the gingiva specially in the anterior aesthetic zone. The scans were



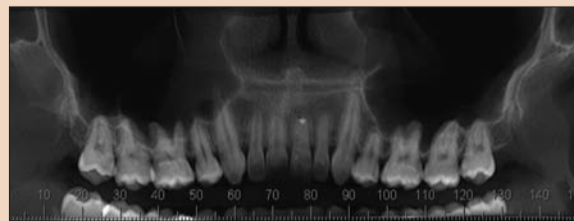Clinical picture of the patient showing a very thin periodontal biotype.

performed with an iCAT (Imaging Science International, Inc., Hatfield, PA; USA). The authors positioned the subject for the scan wearing a plastic lip retractor.

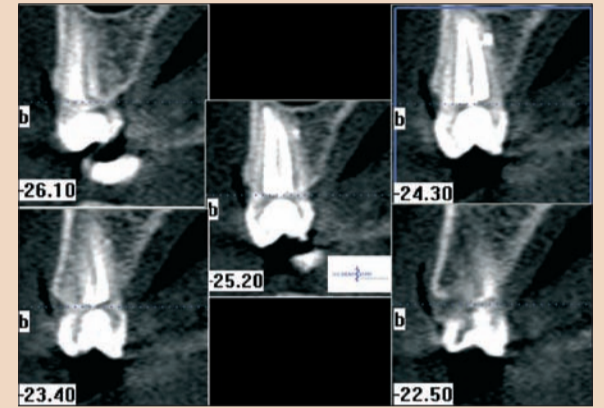A 28-year-old female patient was referred to our practice for evaluation and treatment planning of the periodontal status. No special remarks regarding medical or dental history. The patient has undergone orthodontic over a couple of years. The



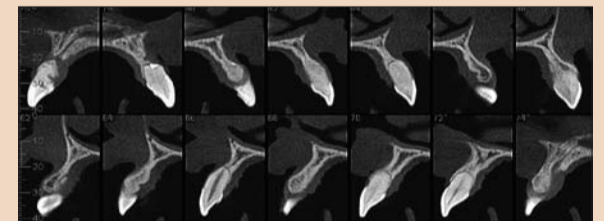
CBCT of the same case. Upper picture demonstrating the panoramic view while the lower shows the cephalometric view.



Panoramic image of the upper jaw produced by the CBCT.



CBCT scans of the RCT performed on tooth 15. Good opportunity to evaluate the successfully obturated lateral canal in the periapical third of the palatal canal.



CBCT image showing an almost completely resorbed buccal alveolar plate and a very thin periodontal biotype.

patient was referred for the completion of the diagnostic to take a CBCT at CTdent (2 Devonshire Place, W1G 6HJ, London, see also [www.ct-dent.co.uk](http://www.ct-dent.co.uk)). The CBCT confirmed the preliminary diagnosis. A treatment plan has been elaborated.

### 2.2 CBCT and hard tissue

Vandenberghe and coworkers researched periodontal bone architecture using 2D CCD and 3D full-volume CBCT-based imaging modalities.

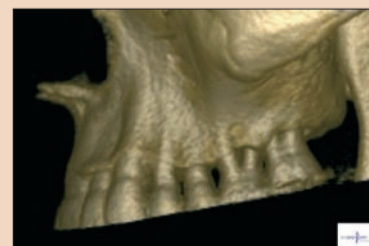
Their investigation concluded that CBCT offered a significant benefit over conventional radiography. The authors concluded that CBCT can be used to diagnose the bony support as well as surrounding soft tissue and may reveal valuable informations for example regarding furcation involvement. A 55 old human patient was referred to our practice for evaluation, treatment planning and execution. Of major concern was the first upper molars. After performing the routine diagnostic approaches such as BOP, periodontal probing, etc, the patient was referred to CTdent for a CBCT.

## Summary


Information provided by this modern technology represents an invaluable milestone in diagnostic, treatment planning as well as evaluation of treatment outcome specially for periodontal applications, especially in the areas of intrabony defects, dehiscence and fenestration defects, and periodontal cysts, and in the diagnosis of furcation-involved molars.

## Conclusion

1. For periodontology, CBCT proves to be superior to 2D imaging for the visualisation of bone topography & lesion architecture as well as for the covering.



The CBCT centre sent along as 3D reconstruction of the left side.



The CBCT centre sent along as 3D reconstruction of the right side.

2. For endodontics CBCT seems to be the most promising applications for diagnosis, treatment planning and treatment evaluation.

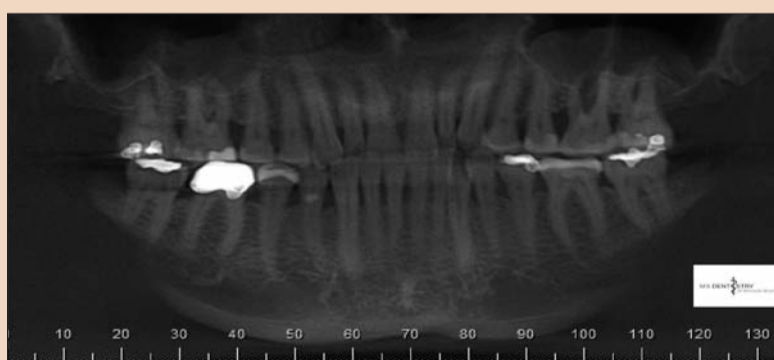CBCT images and 3D reconstructions allow for visualisation and exact measurement of dimensions. Diagnosis built on the combination of clinics and CBCT are a reliable aid in planning and execution of simple as well as advanced dental procedures.

References are available on request.

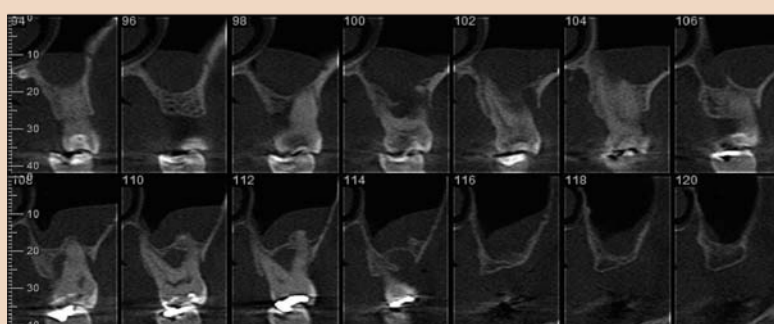
### About the author



**Dr. med.dent. Liviu Steier** is a visiting professor at the School of Dental Medicine in Florence; visiting professor at Tufts School of Dental Medicine on its endodontic postgraduate programme; and an honorary clinical associate professor at Warwick Medical School. He is a registered specialist in endodontics (GDC) and specialist fuer Prothetik ([www.dgzpw.de](http://www.dgzpw.de)). He can be reached at [l.steier@msdentistry.co.uk](mailto:l.steier@msdentistry.co.uk)



Panoramic view CBCT image showing the advanced bone resorption at the level of the first upper molars.



The CBCT confirms the class III furcation involvement.

# Four ways to increase case acceptance

Roger Levin, DDS

*'A pessimist sees the difficulty in every opportunity; an optimist sees the opportunity in every difficulty.'*

—Winston Churchill

Everyone wants new year to be better than last one. Well, here's how: improve your system for presenting treatment to patients — especially larger need-based and elective cases. When I say that to dentists at my Total Practice Success™ seminars, a few attendees will inevitably respond, "I'm doing everything I can, but nothing seems to work. About the same percentage of patients accept treatment year-to-year no matter what I do."

This is when I start asking questions about their case presentations:

- Is your team involved? Does your hygienist regularly educate patients about all practice services?

- Do you emphasize patient benefits right from the get-go?
- How up-to-date are your marketing materials? Do they promote all of your services, especially cosmetic dentistry and implants?
- Do you offer flexible financial options to every patient?

As you can probably guess, the majority of the responses are in the negative. That's because most people, including dentists, have difficulty accurately evaluating their performance. We all want to believe that we're doing the best that we can. Of course, we often are, but sometimes we are not. Admittedly, changing can be difficult. It often takes a major event, such as the worst economy since the Great Depression, to shake us out of our complacency.

While the past several months have certainly been a wake-up call, this is no time to

dwel on the negative. We're starting a new year — a time brimming with possibilities—so, let's focus on the one indisputable fact that I can't emphasize enough to dentists everywhere: Your practice is the best investment you ever made.

Now is the time to re-invest in your practice by improving your system for case presentation. Levin Group helps our clients increase case acceptance with a systematized approach called Greenlight Case Presentation. These four "green light" action steps can help you do the same.

## Promote comprehensive dentistry

Successful practices take a long-term view of patients' oral health. Most patients are potential candidates for any number of traditional and elective procedures, yet too many practices take a shortsighted view and focus exclusively on the patients'

current needs and treatment. Yes, practices should address a patient's immediate concerns, but there also should be a focus on lifelong dentistry that takes a comprehensive view of the patient's dental future needs and wants. Unfortunately, a high percentage of dental appointments are still single-tooth treatments. Offering comprehensive care to all patients can result in a significant increase in production and profitability.

## Focus on benefits right from the start

Dentists love the technical aspects of treatment, but most patients couldn't care less. They just want to know how treatment will benefit them. Let's take implants, for example. Patients want to hear how implants will improve their smile, prevent bone loss, increase their quality of life, etc. It's not that clinical explanations should be avoided entirely, but it's just that they should be de-emphasized. Save technical details for later in the case presentation, and keep them to a minimum unless the patient asks specific questions. Remember, patients generally have one thing in mind: "What's in it for me?" Only by focusing on benefits can patients become truly motivated. Without motivation, it's doubtful patients will move forward with treatment.

## Educate patients

Just as billion-dollar corporations run the same TV commercials repeatedly to create product awareness, a practice must also educate patients about all of its services multiple times during each and every visit. Case presentation shouldn't be solely the doctor's responsibility, each team member must do his or her part to educate and motivate patients about practice services. In addition, marketing materials — brochures, posters, infomercials on monitors, etc. — should be featured in patient areas throughout the practice.

## Present flexible financial options

Practices can dramatically increase case acceptance by offering a broad array of financial options to all patients. Many doctors make the mistake of

assuming which patients may or may not be able to afford certain cases. Case acceptance dramatically increases when patients see the value in the recommended treatment and are presented with a variety of flexible financial options that suit their budget. Levin Group recommends that practices use these options:

- 5 percent discount for full payment in advance for larger cases,
- credit cards,
- half upfront, half before completion of treatment,
- outside or third-party financing.

## Conclusion

Case acceptance drives practice success. These four action steps can help you and your team get more patients to say "yes" to recommended treatment. Combat a tough economy by increasing your case acceptance and give the green light to more success in 2009!

*Dental Tribune readers are entitled to receive a 20 percent courtesy on the Levin Group's Total Practice Success™ Seminar held for all general dentists on May 28 & 29 in Nashville. To register and receive your discount, call (888) 975-0000 and mention "Dental Tribune" or email customerservice@levingroup.com with "Dental Tribune TPS" in the subject line.*

**INTERNATIONAL JOURNAL OF CLINICAL PEDIATRIC DENTISTRY**

ISSN 0974-7052 January-April 2009 Volume 2 Number 1

*International Journal of Clinical Pediatric Dentistry*

Editor-in-Chief  
Usha Mohan Das (India)

Associate & Managing Editors  
Nikhil Marwah (India)  
KJ Toumba (UK)

Also available online at [www.jaypeebrothers.com](http://www.jaypeebrothers.com)

Editor-in-Chief  
Usha Mohan Das (India)

Associate & Managing Editors  
Nikhil Marwah (India)  
KJ Toumba (UK)

Peer reviewed journal with original communications, review articles and case reports in pediatric dentistry. The international editorial and advisory board ensure evidence-based quality content.

ANNUAL SUBSCRIPTION  
Rs. 4,500/- (INSTITUTIONAL)  
Rs. 3,000/- (INDIVIDUAL)

**INTERNATIONAL JOURNAL OF CLINICAL IMPLANT DENTISTRY**

January-April 2009 Volume 1 Number 1

*International Journal of Clinical Implant Dentistry*

Editor-in-Chief  
Shankar Iyer (USA)

Senior Editor  
Mahesh Verma (India)

Managing Editor  
Brij Sabherwal (India)

Also available online at [www.jaypeebrothers.com](http://www.jaypeebrothers.com)

Editor-in-Chief  
Shankar Iyer (USA)

Senior Editor  
Mahesh Verma (India)

Managing Editor  
Brij Sabherwal (India)

The official publication of AAID-Asia Maxi Course is a peer reviewed journal that aims to provide dentists with the information on trends and techniques of implantology to stay ahead in practice.

ANNUAL SUBSCRIPTION  
Rs. 4,500/- (INSTITUTIONAL)  
Rs. 3,000/- (INDIVIDUAL)

Also available online at: [www.jaypeebrothers.com](http://www.jaypeebrothers.com)

**Jaypee Brothers Medical Publishers Pvt. Ltd.**

4838/24, Ansari Road, Daryaganj, New Delhi-110002, India  
Phone: +91-11- 43574357, Fax: +91-11-43574314  
E-mail: [jaypee@jaypeebrothers.com](mailto:jaypee@jaypeebrothers.com), [www.jaypeebrothers.com](http://www.jaypeebrothers.com)

## About the author



Dr. Roger P. Levin is chairman and chief executive officer of Levin Group, the leading dental practice management firm. Levin Group provides clients with Total Practice Success, the premier comprehensive consulting solution based on the implementation of high performance systems. A third-generation dentist, Levin is one of the profession's most sought-after speakers, bringing his Total Practice Success Seminars to thousands of dentists and dental professionals each year.

# Tetric® N-Ceram

fast – modern – esthetic



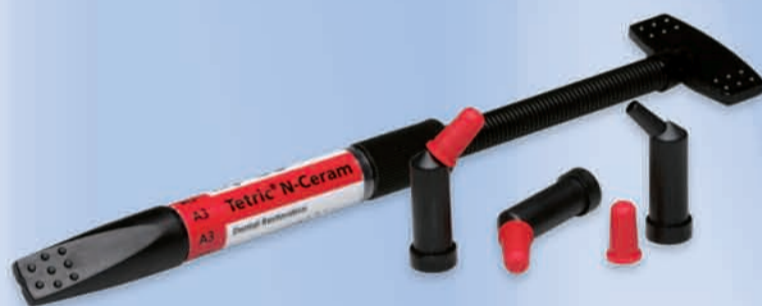Participate and win „Nightlife & Lifestyle“ in Bahrain.

**1<sup>st</sup> prize:** 1 trip for 2 to the Grand Prix of Bahrain 2010

**2<sup>nd</sup> prize:** 1 Sony Vaio Laptop

**3<sup>rd</sup> prize:** 1 LCD flat screen TV

**4<sup>th</sup> – 20<sup>th</sup> prize:** 1 Game "Quantum of Solance" plus 1 Politip Promo Pack

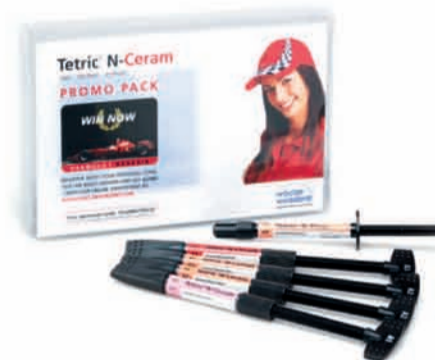

A nano-optimized mouldable composite  
It's **NEW**. It's **NANO**. Get it **NOW**.



Terms and conditions apply. Prizes are not redeemable for cash.

Get the Ivoclar Vivadent F1-Kit and register with your personal code on:  
[www.ivoclarvivadent.com](http://www.ivoclarvivadent.com)



Please contact our dealer partners for further details:

**Bangalore:** Fairway Inc. sales@fairwaydent.com (Phone: 080 25212961)  
Omega Inc. Omegainc@rediffmail.com (Phone: 080 25450189)  
**Chennai:** Vijay Dental Depot Pvt. Ltd. vijaydent@vsnl.com (Phone: 044 2475 5512)  
**Delhi:** P.G. Pharmaceuticals pgp29@rediffmail.com (Phone: 011 27313440)  
**Mumbai:** NK Patel and Sons sales@nkpatelandsons.com (Phone: 022 66347684)

[www.ivoclarvivadent.com](http://www.ivoclarvivadent.com)

**Ivoclar Vivadent AG**  
Bendererstr. 2 | FL-9494 Schaan | Liechtenstein | Tel.: +423 / 235 35 35 | Fax: +423 / 235 33 60

**Ivoclar Vivadent Marketing Ltd. (Liasion Office) India**  
503/504 Raheja Plaza | 15 B Shah Industrial Estate | Veera Desai Road, Andheri (West) | Mumbai 400 053 | India  
Tel.: +91 (22) 2673 0302 | Fax: +91 (22) 2673 0301 | E-mail: india@ivoclarvivadent.com

**ivoclar**  
**vivadent**  
passion vision innovation

# Think Out Of The Box!

Dr. Sujata Goyal, MDS  
India

Teeth have people attached to them! And it is never easy to break the news about an impending loss of a tooth, especially a front tooth, to our patients. The cause of tooth loss or the hopelessness of the situation notwithstanding, the decision to sacrifice the natural tooth always seems very cruel to the patients. Moreover, if the loss is inevitable, every patient wants an immediate replacement to escape the social embarrassment of a 'window', in their smile. And as clinicians we are expected to meet patients' expectations who seek a fixed, non-invasive, highly esthetic, non-metallic restoration, which should not also be expensive! All of us have faced this challenging situation many a times in our clinical practice.

Various conventional restorative options to replace missing teeth are: removable partial dentures; porcelain fused to metal or all ceramic fixed restoration; resin-bonded fixed partial dentures; or implant-supported prostheses. However, these restorative alternatives carry their own limitations such as:

- Lack of adequate bone support for abutment teeth or placing the implants
- Excessive removal of healthy tooth structure for abutment preparation, which is considered to be further mutilation by many patients
- Dependence or delay involved in the fabrication which is not acceptable to people who have an active social life. They will also need a provisional restoration
- Multiple appointments which is normal for the fabrication of indirect prostheses
- Repair is difficult and expensive in case of a failure.

Increased patient demands cause thus clinicians to seek materials and techniques that enable minimally-invasive approaches for chair-side applications. Adhesive dentistry permits dental treatment that were previously considered impossible with conventional techniques, opening new frontiers in modern dental restorations. Adhesion has undergone consider-

able maturation since its introduction to dentistry in the early 1950s by pioneers in the field. In the last decade only, however, our knowledge of adhesive materials has grown exponentially and consequently, there has been a significant increase in the role adhesives play in daily dental practice. With the advent of minimally-invasive dentistry, there has been a paradigm shift, moving away from metal restorations towards adhesive dentistry for the conservation of tooth structure. When minimal tooth structure is removed, bonded composite resins can be placed, which restore the tooth to 90-95% of its original strength and 100% of its original appearance.

The use of adhesive techniques and composite materials reinforced with fiber systems allows clinicians to respond to these demands.<sup>1</sup> Fiber-reinforced materials have highly favorable mechanical properties, & their strength-to-weight ratios are superior to those of most alloys. When compared to metals they offer many other advantages as well, including noncorrosiveness, translucency, good bonding properties, and ease of repair. Since they also offer the potential for chair-side and laboratory fabrication, it is not surprising that fiber-reinforced composites have potential for use in many applications in dentistry. Polyethylene fibers improve the impact strength, modulus elasticity, and flexural strength of composite materials. Unlike carbon and Kevlar fibers, polyethylene fibers are almost invisible in a resinous matrix and for these reasons, seem to be the most appropriate and esthetic strengtheners of composite materials.<sup>2</sup>

The case presented here illustrates an alternative solution to every day clinical problem in an attempt to meet rising demands of our patients.

## Case report

A 38-year-old female patient reported to our practice with pain in the left lower lateral incisor (Fig. 1). On clinical examination the tooth had grade 4 mobility, was partially avulsed, and sensitive to palpation and

percussion. Intra-oral periapical x-rays revealed severe bone loss and a periodontal abscess. The tooth had a hopeless prognosis and a mutual decision to extract it was taken. Nevertheless, the young patient was heartbroken and didn't want to let go of her

resins or even cast metal frame works.<sup>3-8</sup> However, these materials could never be chemically incorporated into the dental resin and as a result could not withstand the repeated loading in function and parafunction. More bulk was necessary to pre-

ment, but also ease of use and an assortment of widths of the fibers to manage a wide variety of clinical situations. Also, research has demonstrated that the fiber reinforcement architecture with Ribbond™ enhances flexural strength and flexural

## “Using the natural tooth as a pontic offers the benefits of being the right size, shape and color”

natural tooth. Idea of a RPD was devastating to her. Adjacent teeth didn't fulfill requirements of ideal abutment so we couldn't promise her a conventional tooth-retained FPD as well. Implant was an expensive option for her at that time, so we had to think out of the box! There are a number of reports in the litera-

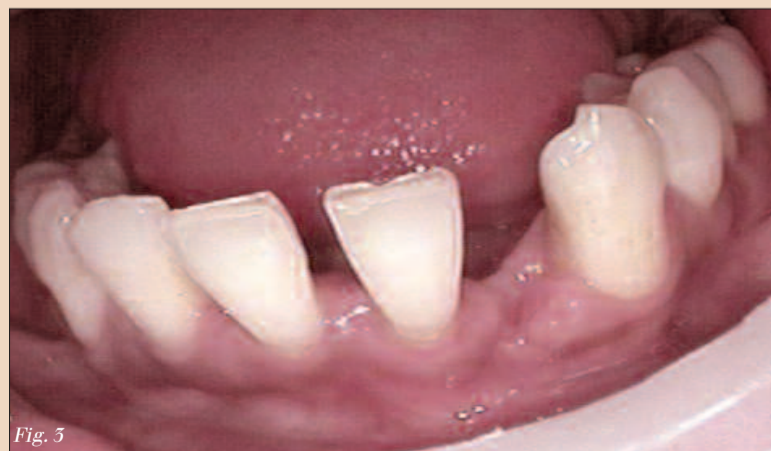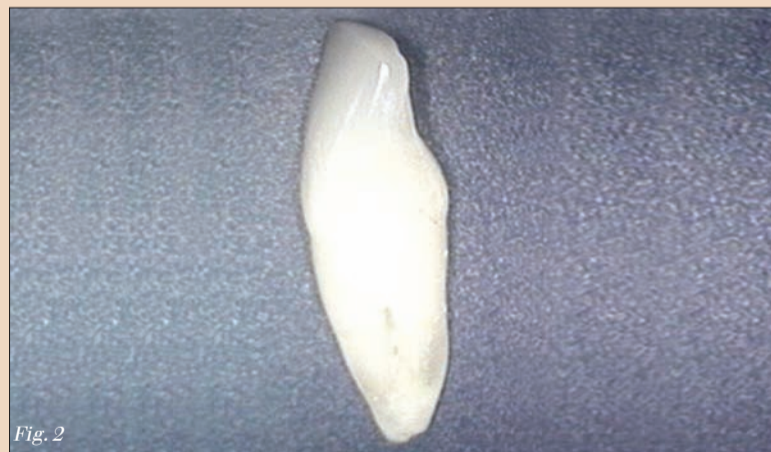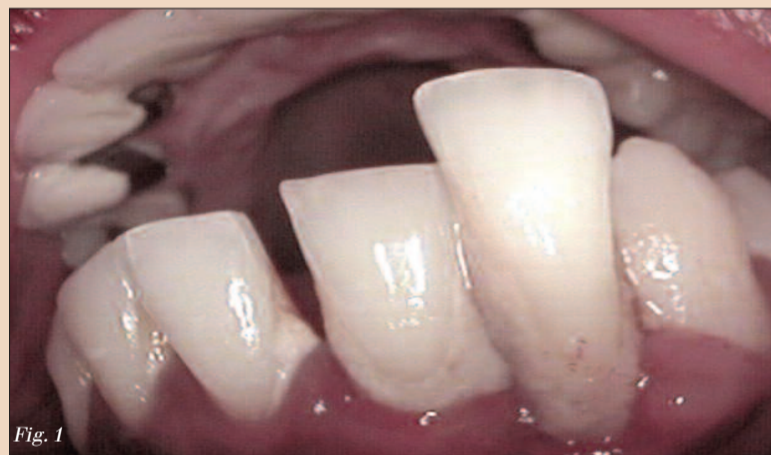vent the failures, which resulted in difficulty to clean, and collection of plaque, leading to further progression of periodontal disease.

The challenge here was to place a thin, but strong natural looking restoration that was non-invasive. I've been using

modulus of the composite resins and hence resists cracking.<sup>9-11</sup>

As part of the therapy, complete prophylaxis was carried out, the tooth in question was extracted (Fig. 2) and the site allowed to heal for two days. Complete isolation of the site free of oozing or any moisture is mandatory for bonding, so this delay was considered necessary. When the crown of the tooth is in good condition, it can be easily bonded temporarily to the adjacent teeth with light-cured restorative material. This technique has been used several times by us in the past producing satisfying results. Using the natural tooth as a pontic offers the benefits of being the right size, shape and color. Moreover, the positive psychological value to the patient by using his or her natural tooth is an added benefit. Extracted tooth to be used as pontic was first of all trimmed into the size as per the space available. The open root canal was sealed with composite and polished after being shaped into a modified ridge lap design as this design will meet both esthetic and hygiene requirements. It was decided that all remaining lower incisors would be splinted using Ribbond™ extending from one canine to the other canine as all the remaining mandibular incisors were also mobile due to periodontal disease.

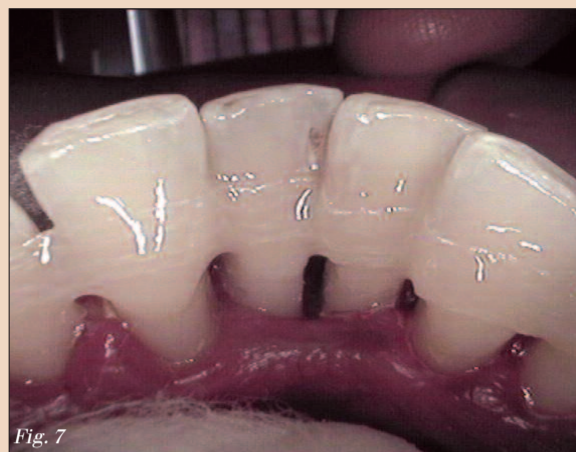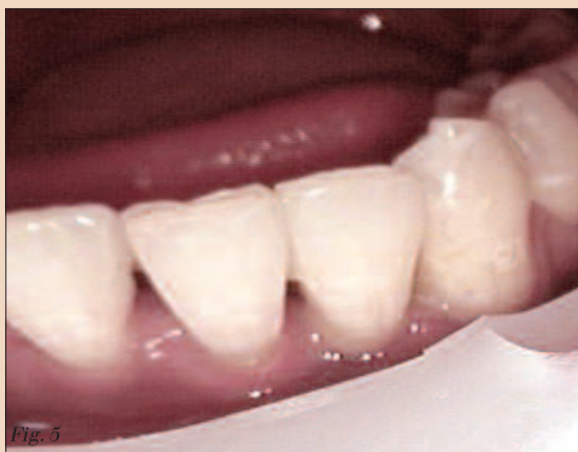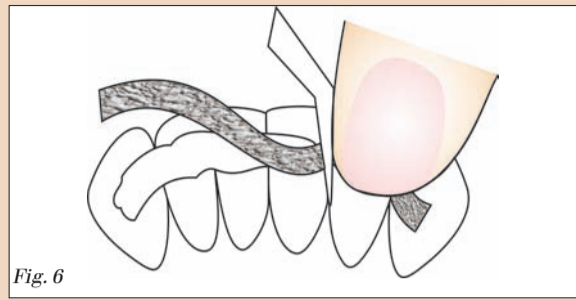

Two days later patient reported back with a nicely healed site (Fig. 3). Teeth were thoroughly cleaned on the facial, lingual and interproximal surfaces with pumice paste, finishing strips and a prophylaxis cup to remove any traces of surface impurities, which could affect the adhesion adversely. Required length of the fiber was measured with the help of well adaptable soft tin foil provided



ture for splinting of the mobile teeth and adding a natural tooth, an acrylic resin tooth or a tooth carved out of composite as a pontic, connected to the adjacent teeth with various means such as wire meshes of nylon or metal, wire ligatures, composite

one brand of fiber reinforcement ribbon, Ribbond™ for almost ten years with good success. Ribbond™ is a bondable, polyethylene, lock-stitch multidirectional reinforcement ribbon that offers not only excellent composite resin reinforce-





in the pack. At all times, plasma-treated polyethylene fiber should be handled with care to avoid contamination. It should be taken out of the pack with clean cotton pliers and cut with special Ribbond™ scissors. Another alternative to cut this tough fiber cleanly is using a wire-cutter. After wetting the fiber is wetted with adhesive resin, it should be covered to avoid light exposure till the

time of use (Fig. 4). All surfaces in the canine to canine region were etched for 30 seconds with a 32% phosphoric acid gel. Teeth were then rinsed with air-water spray and gently dried. The lower anterior area was isolated with cotton rolls and adhesive resin was applied with the help of a brush on all the etched surfaces. At this point LC block-out resin was used

to block the gingival embrasures so that excess composite does not flow into the gingival embrasures. The unfilled adhesive resin applied on etched surfaces was cured at this point. After this, the extracted trimmed lateral incisor was placed and adjusted in its final position between central incisor and canine to stabilize it using few drops of flowable resin on its proximal sides. The resin was cured

according to the manufacturer's instructions (Fig. 5). Then, composite resin was placed on the middle one-third of the lingual surface from canine to canine. Fiber ribbon was embedded into the composite resin adapting it well onto the teeth surfaces with the help of a plastic filling instrument (Fig. 6<sup>12</sup> and 7). Excess resin was removed and then cured for 20 seconds at least for each tooth. The ribbon should remain completely covered with the resin during this process. Then, composite resin was shaped, finished and polished to achieve an esthetic restoration. To ensure long-lasting functional restoration, occlusion was checked to rule out any contact of the opposing teeth in function or at rest. The restoration done for the patient was found to be stable and functional even after five years.

**Conclusion**

Many a times there is a need for quick and direct replacement for a single lost anterior tooth. For such cases a fiber reinforced restoration not only meets the demands of the pati-

ent but also act as a splint for the adjacent mobile teeth. These restorations are esthetic, non-invasive, biocompatible and long-lasting if there is a judicious case selection and protocol of adhesive dentistry is followed. **Dr**

References available on request.

**About the author**



**Dr. Sujata Goyal** is a professor and heads the department of prosthetic dentistry at Luxmi Bai Institute of Dental Sciences, Patiala, India and also conducts courses on implantology. She is practicing since 1988 with special interest in the field of esthetic dentistry & implantology. She has published internationally on bone manipulation techniques and is a member of the editorial review board of *International Journal of Clinical Implant Dentistry*. She can be contacted at [seth1964@gmail.com](mailto:seth1964@gmail.com).

**PLANMECA**

*Highlights*



Planmecha ProMax 3D



Planmecha ProSensor



Planmecha Romexis



Planmecha Sovereign



Perfect field size for all needs





**PLANMECA**

Please contact Planmecha India to find the distributor closest to you.

Planmecha India, P.O. Box No. 16763, Sion, Mumbai 400022  
tel. 0 9323548732 / 0 9821018559, fax 022 24051379, s.r.nakhate@planmecha.net

Planmecha Oy, Asentajankatu 6, 00880 Helsinki, Finland, tel. +358 20 7795 500  
fax +358 20 7795 555, sales@planmecha.com, www.planmecha.com