

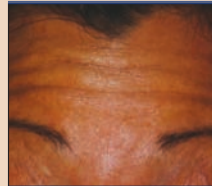DENTAL TRIBUNE

— The World's Dental Newspaper · Middle East & Africa Edition —

PUBLISHED IN DUBAI

April 2010

No. 4 VOL. 8



Trends & Applications
Botox and dermal fillers for every dental practice

▶ Page 4



Media CME
Cutaneous sinus tracts: An endodontic approach

▶ Page 6



MIDDLE EAST EVENTS 2010

▶ Page 8

In Cooperation with the Faculty of Dentistry at the Royal College of Surgeons in Ireland

Ajman University Organized a Joint Accredited Dental Conference

In its quest to promote the Innovative Medical Environment, the College of Dentistry at Ajman University of Science & Technology (AUST) and the Faculty of Dentistry of the Royal College of Surgeons in Ireland (RCSI), in collaboration with the Dental Society of the Emirates Medical Association, have organized a multi-disciplinary dental conference themed, "Advancing Excellence in Dental Care."

The two-day event has kicked off Sunday 4th April at the Sheikh Zayed Centre for Conferences and Exhibitions, under the patronage of H.E. Dr. Saeed Abdulla Salman, AUST President. In his address read by Dr. Ahmad Ankit, AUST Vice President for External Relations and Cultural Affairs, Dr. Saeed Salman praised the achievements in higher education and scientific research attained by the United Arab Emirates under the wise leadership of H.H. Sheikh Khalifa bin Zayed Al Nahayn, President of the UAE, and H.H. Sheikh Mohamed bin Rashed Al-Maktoum, Vice President of the UAE and Ruler of Dubai.

"It is our three dimensional vision – education, information and



investment - that has enlightened our endeavors and contributed to the institution's achievements so far" said AUST President. "AUST College of Dentistry," he explained, "was the first of its kind in the UAE when it began offering accredited programs in the year 2000. Since that time it has succeeded in fulfilling dozens of projects and initiatives in academia, and serving the community by providing oral care to more than 100,000 patients."

Prof. Abdul Azim Ahmed, Chairman of AUST Innovative Medical Environment Commission welcomed the participants

saying that "The conference is the fruition of the endeavours of both AUST's IMEC and CoD, in implementation of the Reform and Development Plan, devised by the University's higher administration." Prof. Abdul Azim added that "the conference is a perfect opportunity for AUST community as well as other dentistry faculty and students from peer institutions to acquire first hand experience in dental care and to relate with a number

→ DT page 2

Ajman University of Science and Technology member wins the Arab Dental Universities Union Award.

The College of Dentistry in Ajman University of Science and Technology has organized a tribute ceremony for Dr. Raghad Hashim, Assistant Professor and the Head of the Growth & Development Department at the College of Dentistry for her prize winning of the best scientific research of faculty members in Arab universities on dentistry in 2009.

The research was themed the relation between children oral health and eating habits. The prize is awarded by the Union of Arab Universities in Association with the Arab Colleges of Dentistry in Beirut, Lebanon.

It is worth noting that Dr. Hashim had been awarded many prizes before, to name but a few, she came first in Al-Owais Award for Studies and Scientific Innovation in 2005 for the best research on health and medical sciences in the UAE, entitled the health and environmental condition of the children in Ajman. She also



won Colgate Award after presenting her work at the International Association of Dental Research (IADR) conference held in Washington, USA in 2005. During her presence at another IADR conference in New Orleans, USA, Dr. Hashim had one of her researches been nominated for the Giddon Award in 2007. DT

AD

DTMEA 4/10

PROMEDICA

Highest quality made in Germany

- ▶ high quality glass ionomer cements
- ▶ first class composites
- ▶ innovative compomers
- ▶ modern bonding systems
- ▶ materials for long-term prophylaxis
- ▶ temporary solutions
- ▶ bleaching products...

All our products convince by

- ▶ excellent physical properties
- ▶ perfect aesthetical results

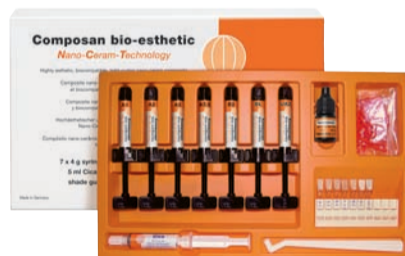NEW at PROMEDICA

New: Bleach Shade!



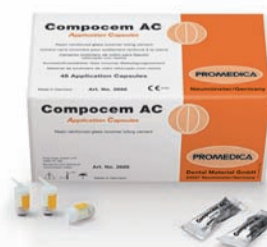Temporary crown and bridge material

- particular fracture and wear resistance
- now available in 6 attractive shades



Light-curing nano-ceram composite

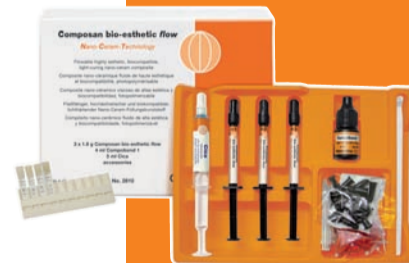- universal for all cavity classes
- comfortable handling, easy modulation
- highly esthetic and biocompatible



Resin-reinforced glass ionomer luting cement

- strong adhesion, very low film thickness
- especially suited for zirconia-based pieces

Nano-Ceram-Technology



• exact match of translucency and shade to the packable Composan bio-esthetic

PROMEDICA

PROMEDICA Dental Material GmbH

Tel. +49 43 21 / 5 41 73 · Fax +49 43 21 / 5 19 08

Internet: <http://www.promedica.de> · eMail: info@promedica.de



Editorial Board

Prof. Abdullah Al-Shammary, Restorative Dentistry, KSA
 Prof. Hussain F. Al Huwaizi, Endodontics, Iraq
 Prof. Samar Burgan, Oral Medicine, Jordan
 Dr. Abdel Salam Al Askary, Implantology, Egypt

Dr. Talal Al-Harbi, Orthodontist, Qatar
 Dr. Mohammed H. Al Jishi, Bahrain
 Dr. Lara Bakaeen, Prosthodontist, Jordan
 Dr. Aisha Sultan, Periodontist, UAE
 Dr. Kamal Balaghi Mobin Aesthetics, Iran

DENTAL TRIBUNE

The World's Dental Newspaper - Middle East & Africa Edition

Published by Education Zone

in licence of Dental Tribune International GmbH

© 2010, Dental Tribune International GmbH. All rights reserved.

Dental Tribune makes every effort to report clinical information and manufacturer's product news accurately, but cannot assume responsibility for the validity of product claims, or for typographical errors. The publishers also do not assume responsibility for product names or claims, or statements made by advertisers. Opinions expressed by authors are their own and may not reflect those of Dental Tribune International.

President/CEO Yasir Allawi
 y.allawi@dental-tribune.ae

Director mCME: Dr. D. Mollova
 info@cappmea.com

Marketing manager Khawla Najib
 khawla@dental-tribune.ae

Production manager Hussain Alvi
 dentalme@dental-tribune.ae

PO Box 214592, Dubai, UAE, Tel + 971 4 391 0257
 Fax + 971 4 366 4512 www.dental-tribune.com

← DT Page 1

of prominent and experienced professionals in this field."

In the address of the dean of the Faculty of Dentistry at the Royal College of Surgeons in Ireland, Prof. Patrick J. Byrne expressed his thanks to Ajman University for organizing the conference and for bringing together eminent speakers and participants from around the world. Prof. Patrick, who praised the existing partnership between the RCSI and AUST, briefed the participants on the objectives of the conference, saying that: "keeping up with the literature and evidence of best practice in one area of dentistry alone is onerous, but keeping up with the whole spectrum of modern dentistry may seem almost impossible. We hope that in the two days you will spend with us in Ajman University, we will be able to assist you with that task."



Dr. Salem Abu Fannas, dean of AUST College of Dentistry welcomed AUST guests and extended his appreciation to Dr. Patrick Byrne and his team from the Royal College of Surgeons in Ireland, Prof. Malcolm Harris from the University of Central Lancaster, as well as Dr. Aisha Sultan, president of the Dental Society of the Emirates Medical Association for their support to this event which has brought together leading academics and clinicians. "This conference will promote research and place our students in an international arena to mix with well established masters of Dentistry as a Science and as a Profession." Dr. Salem said.

AD

كلية نيقولا وآسب الجامعية
NICOLAS & ASP UNIVERSITY COLLEGE

The First Accredited Dental Postgraduate University College in the Middle East

Register NOW...

Masters In Orthodontics
 4th Intake (February 2010)

3 years study in UAE
 Accredited by
 U.A.E. Ministry of Higher Education
 & Scientific Research
 and Malmo University, Sweden

Master Degree in Pediatric Dentistry

3 years study in UAE
 Accreditation in Progress
 Start Date: March 1, 2010 (tentative)

High Diploma In Oral Implantology
 5th Intake

1 Year (modules) for practicing Dentists and Specialists
 Program is done in cooperation with
 Gothenberg University, Sweden
 Accredited by
 U.A.E. Ministry of Higher Education & Scientific Research

Master Degree in Endodontics

3 years study in UAE
 Accreditation in Progress
 Start Date: March 1, 2010 (tentative)

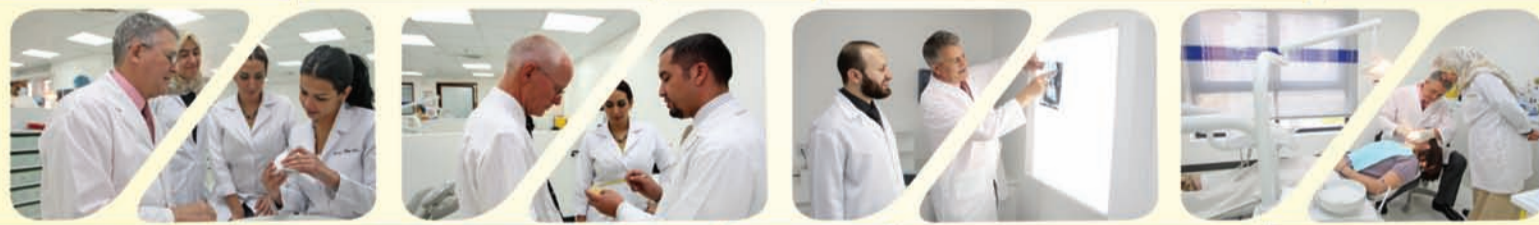
Program Directors:

Unique group of European & American faculty

Dr. Jon Årtun, DDS, PhD, Dr Odont
 Acting Program Director & Prof. of Orthodontics
 Advanced Orthodontic Training Program

Dr. Christer Dahlin, DDS, PhD, Dr Odont
 Director of Implantology Programs
 Professor in Oral & Maxillofacial Surgery

For more information: Tel.: 0097143624788



Abu Dhabi Headquarters

Admission Office:
 Al Odaid Office Tower, Airport Road, Abu Dhabi, UAE
 10th Floor, Office 1201
 Telephone: +971 2 404 7141

Dubai Branch

Dubai Healthcare City
 Ibn Sina Building (No. 27)
 Block D, 3rd floor, Office 302
 Telephone: +971 4 3624787

Fax: +971 4 362 4793

P.O. Box: 53382, Dubai, UAE

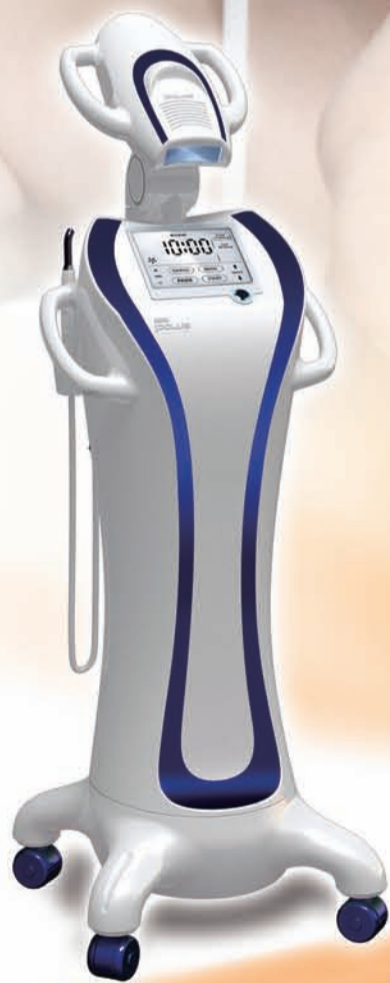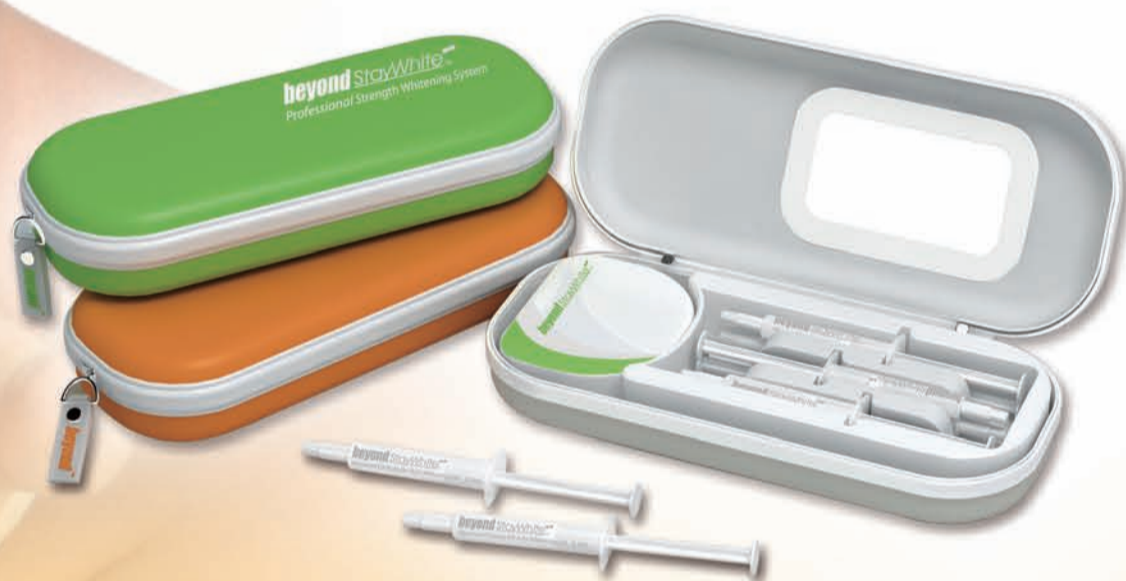Website: www.dubaipostgraduate.com

Email: info@dubaipostgraduate.com

beyond™

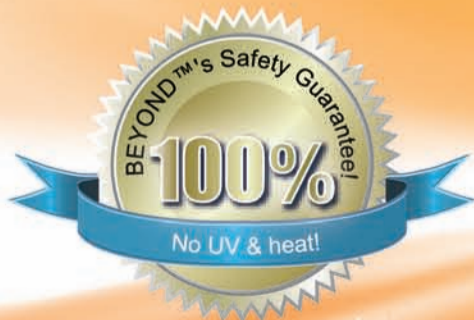*Innovation and Excellence in
Aesthetic Dentistry*

**Discover Your
Smile Potential**
with BEYOND™ whitening products!



beyond™
POLUS®

Our next generation
whitening system -
*the future of power teeth
whitening has arrived!*



beyond StayWhite™
Professional Whitening System

Take-home tray whitening available through
the dental office

- One hour a day for 14 days - no messy overnight whitening
- Visibly whiter teeth in five days
- Gentle hydrogen peroxide formula minimizes risk of sensitivity
- Convenient travel case with mirror for easy application on the go

Contact us today to learn more about BEYOND™
products and distribution opportunities in your area!

beyond™ Dental & Health

BEYOND™ USA HEADQUARTERS
12503 Exchange Dr. Suite 558
Stafford, TX 77477 USA
Tel: +1-281-277-4352
Fax: +1-281-277-4350
E-mail: beyondusa@beyonddent.com

www.beyonddent.com

Algeria: DENT CO LTD, Tel: +213-31-90-00-89
Egypt: Arabian Doctor Trading EST.,
Tel: +201-01-462-338 / +201-07-043-734
Iraq: NAKHLAT SHATT ALARAB - MEDICAL COMPANY,
Tel: +963-93-251-1258
Jordan: Osama Fadel Al-Deen Est, Tel: +962-6-5333115
KSA: Medical Vision Est., Tel: +966-1-405-7275
Kuwait: SAFWAN TRADING & CONTRACTING COMPANY,
Tel: +965-484-8952

Lebanon: RICHA DENTAL STORE, Tel: +961-5-452-555 /
PearlSmile sarl, Tel: +961-1-495-111
Oman: Sala Medical Complex "Sala Medical, Tel: +968-24-485-159
Palestine: High Professional Co., Tel: +972-59-967-0780
Qatar: Ebn Sina Medical, Tel: +974-4417953
Syria: Koucheh Trading Co., Tel: +963-41-450749
UAE: National Medical Supplies, Tel: +971-4-2857578
Yemen: Alasser Group, Tel: +967-73-379-7927

Botox and dermal fillers for every dental practice

The next big thing in dentistry may be expanding into the peri-oral and maxillofacial tissues

Esthetic dentistry has been an absolute boom over the last 30 years, especially when it comes to such innovative techniques as

teeth whitening and minimally-invasive veneers like Cristal Veneers by Aurum Ceramics.

Now that the teeth look good, what about the peri-oral and maxillofacial areas around the mouth and on the face? If the

teeth look good but we ignore the rest of the face, then we have severely limited what we have done in esthetic dentistry.

It is time to give serious consideration to extending the oral-systemic connection to the esthetic realms and facial pain areas of the face, which dentists are more familiar than any other health-care practitioner. As dentists, we can all do a magnificent job of making teeth look great and also give people a healthy and beautiful smile.

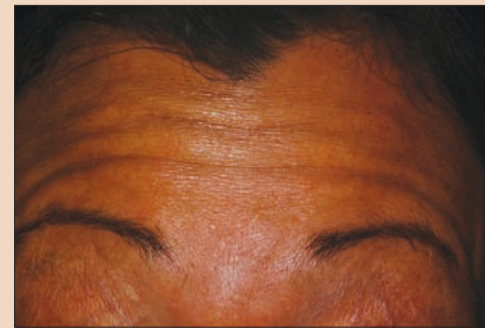

Fig. 1: Strong forehead muscle contractions cause pain and unsightly lines in the forehead.

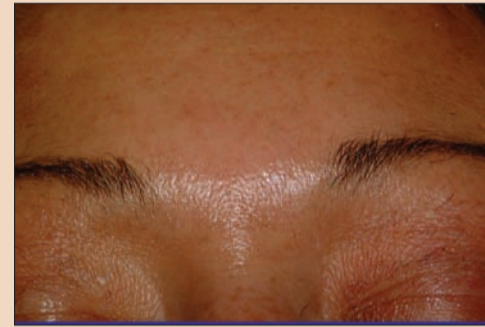

Fig. 2: Botox treatment gives a more esthetic appearance and eliminates facial pain.

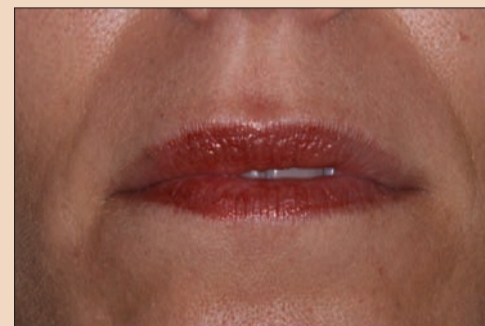

Fig. 3: 42-year-old female had moderate nasolabial lines and uneven lips.

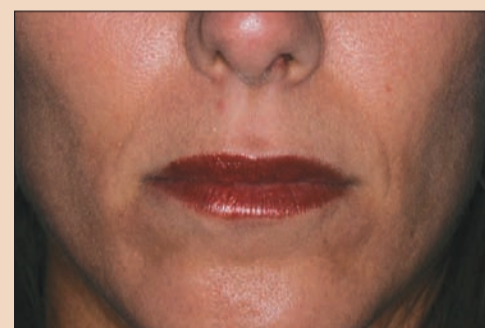

Fig. 4: Dermal filler therapy gives this patient a more youthful appearance and fuller lips with a desirable pout and creates soft tissue esthetics, which complement her teeth.

AD



Everyone has a shade And it's simple to match it

She's an A1B. And, with the improved, lifelike esthetics and "single-shade simplicity" of Filtek™ Z350 XT Universal Restorative, it's the only shade you'll need to restore

her beautiful smile.

Simple to use

- Exceptional handling
- More Body shades for single-shade restorations
- Bold, easy-to-read, color-coded labels

Lifelike esthetics

- Excellent polish
- Wide range of shades and opacities
- Improved fluorescence

Unique nanofiller technology

- Better polish retention than a microfill
- Wears better than leading competitors*
- Outstanding strength for anterior and posterior use

Your simple solution for lifelike restorations is Filtek Z350 XT Universal Restorative.



Filtek™ Z350 XT
Universal Restorative

© 3M 2010. All rights reserved. 3M, ESPE and Filtek are trademarks of 3M or 3M ESPE AG. *In vitro data on file.

3M ESPE

How does Botox work?

Botox is a trade name for botulinum toxin, which comes in the form of a purified protein. The mechanism of action for Botox is really quite simple.

Botox is injected into the facial muscles, but really doesn't affect the muscle at all. Botulinum toxin affects and blocks the transmitters between the motor nerves that innervate the muscle.

There is no loss of sensory feeling in the muscles.

Once the motor nerve endings are interrupted, the muscle cannot contract. When that muscle does not contract, the dynamic motion that causes wrinkles in the skin will stop.

The skin then starts to smooth out, and in approximately three to 10 days after treatment, the skin above those muscles becomes nice and smooth.

The effects of Botox last for approximately three to four months, at which time the patient needs retreatment.

Does Your Patient Suffer from Dry Mouth?

What is dry mouth?

We can all suffer from dry mouth at some point, for example, if we are nervous or stressed. So most of us are familiar with the feeling of not having enough saliva in our mouth to keep it moist and lubricated. For some people, however, dry mouth can be a regular problem. As we get older we are more likely to experience dry mouth, but it's also a problem that can affect people from their 30s onwards.

What causes dry mouth?

Dry mouth occurs when the salivary glands stop working effectively. Medicines are known to cause over 60% of dry mouth cases, with more than 400 different medications linked to dry mouth. The number of medicines a patient takes is also directly related to the likelihood of experiencing dry mouth. Health conditions are also linked to dry mouth, such as diabetes or Sjögren's syndrome. People who smoke, who are pregnant, stressed, anxious or dehydrated are also more likely to have dry mouth.

What are the symptoms?

The symptoms of dry mouth can include:

- difficulty in eating, especially with dry foods, such as cereals or crackers
- difficulty in swallowing and speaking
- a burning sensation in the mouth
- taste disturbances
- painful tongue
- dry, cracked, painful lips
- bad breath
- persistent difficulty in wearing dentures
- feeling thirsty, especially at night
- dry, rough tongue. Sometimes the amount of saliva a person produces may be reduced by up to 50% before these symptoms are noticed. These symptoms can sometimes have a profound effect on self confidence.

Does dry mouth cause other problems?

Saliva plays a very important protective role in the body. It not only keeps our mouth moist, it also helps to protect our teeth from decay, helps to prevent infections and helps to heal sores in the mouth.

Are your patients dry mouth sufferers?

Do they have difficulty swallowing certain foods? • Does their mouth feel dry when eating a meal? • Do they need to sip liquids to help you swallow dry foods? • Are they taking multiple medicines? If a patient answered yes to any of these, he/she may have dry

Products to ease dry mouth

The Biotène system is specifically designed to treat dry mouth. The different products in the Biotène system allow you to choose the ones that best meet your lifestyle and dry mouth needs:

- 1 product specifically designed to help relieve your dry mouth: the gel provides long lasting relief
- 2 products to help maintain healthy teeth and prevent tooth

decay in people with dry mouth: a toothpaste, with fluoride, and mouthwash which can be used twice a day in place of the usual products. These are designed to be gentle on your mouth as they are alcohol-free and don't contain harsh detergents. Biotène supplements the make-up of normal saliva to replenish dry mouths. It has a patented enzyme formulation that:

- helps supplement saliva's natural defences
- helps maintain the oral environment to provide protection against dry mouth
- helps supplement saliva's natural antibacterial system - weakened in a dry mouth. Biotène's gentle formulation is also free from alcohol and harsh detergents.

What else can a patient do to manage dry mouth?

Sip water or sugar-free drinks often • Avoid drinks which dry out the mouth, such as caffeine-containing drinks (coffee, tea, some fizzy drinks) and alcohol • Chew sugar-free gums or sweets to stimulate saliva flow • Avoid tobacco as this has a drying effect • Use a humidifier at night to keep the air full of moisture. To help

keep healthy teeth and avoid tooth decay: • Brush teeth with a soft toothbrush after meals and at bedtime • Floss teeth gently every day. If there is bleeding from gums when flossing, this could be a sign of gum disease. • Use an SLS-free, fluoride toothpaste, like Biotène, with its gentle formulation • Avoid alcohol-containing mouthwashes as these can dry out the mouth • Avoid sweet, sugary foods • Visit the dentist at least twice a year for a check-up.

AD

Do you suffer from dry mouth?



Try the biotène® range

A complete dry mouth treatment



Visit www.biotene.com to learn more about dry mouth.






Cutaneous sinus tracts: An endodontic approach

Diagnosis and treatment for a successful outcome

The article has been accredited by Health Authority - Abu Dhabi as having educational content and is acceptable for up to 2 (Category 1) credit hours.

Credit may be claimed for one year from the date of subscription.

Misdiagnosis of an extra-oral sinus tract usually leads to a destructive invasive treatment of the local skin lesions that is not curative and often mutilating (Fig. 1). Attempting to treat such lesions with a circular incision of the orifice of the cutaneous fistula and excision of its entire tract with all the ramifications is not consistent with the present standard of care. Unfortunately, cutaneous fistulae are sometimes treated as though they are independent dermatologic lesions with the pathogenic characteristics and treatment prognosis typical for mucosal fistulae. However, even skin biopsy may produce unnecessary scarring.

Correct diagnosis is the key to treating this kind of lesion. A gentle digital finger pad pressure on the apical region of the area suspected can create a discharge of pus. A DentaScan can provide reliable information that will help with the final diagnosis and the subsequent treatment plan. A correct diagnosis will lead to a simple, yet effective treatment—the removal of the infected pulp canal tissue from the root canal space—resulting in minimal cutaneous scarring.

Cutaneous sinus tracts of dental origin have been well documented in the medical literature, dental literature, and dermatological literature. However, these lesions continue to be a diagnostic dilemma. Patients suffering from cutaneous fistulae usually seek treatment from a physician or a plastic surgeon instead of a dentist and often undergo multiple surgical excisions, multiple biopsies and antibiotic regimens with eventual recurrence of the cutaneous sinus tract because the primary dental cause is frequently misdiagnosed.

The evaluation of a cutaneous sinus tract must begin with a thorough patient history and awareness that any cutaneous lesion of the face and neck could be of dental origin. The patient's history may include complaints of dental problems. However, patients may not have any history of an acute or painful onset. There may also be complaints of episodic bleeding or drainage from the cutaneous site with persistence of the cutaneous lesion. Occa-

sionally, there is a history of injury to the tooth.

Correct diagnosis of the cutaneous sinus of dental origin should be suspected by the gross appearance of the lesion. These cases typically present as erythematous, symmetrical, smooth, non-tender nodules of one to 20 mm in diameter with crusting and periodic drainage in some cases. The most characteristic feature of the nodule is its depression or retraction below the normal surface. This cutaneous retraction or dimpling is caused by the fixation of the tract to the underlying tissues and may be secondary to the healing process or a late finding in active disease. Lesions that previously underwent biopsy and treatment are usually characterised by the absence of at least part of the nodule and frequently by an orifice of draining sinus at the base of the fixed depression.

Endodontic infection, the product of cellular degeneration—bacterial toxins—and, occasionally, the bacteria themselves within the canal spread through the apical foramen into the surrounding tissue. Thus, a slow inflammatory process begins in the tissue contained within the periodontal ligament. Left to itself, it may manifest in a variety of ways, ranging from simple widening or thickening of the ligament to granuloma or cyst. Sometimes a fistula may develop, with the patient reporting intermittent discharge of pus.

The fistula provides a means of continuous drainage of the lesion. The opening of the fistula may be found on the mucosa overlying the tooth that sustains it, but often it may also be found at a considerable distance from the diseased tooth. In some cases, the fistula may run in the space of the periodontal ligament of the same tooth. It may even traverse the periodontal ligament of the adjacent healthy tooth, thus simulating a lesion of periodontal origin. In such cases, negative pulp tests performed on the crown of the tooth, indicated by a gutta-percha cone inserted into the fistula, assist in making the correct diagnosis.

If the drainage of the fistula is not continuous but intermittent, it is pre-

ceded by a slight swelling of the area as a result of the increased pressure of pus behind the closed orifice. When the pressure becomes strong enough to rupture the thin wall of soft tissue, the suppurative discharge issues externally through the small opening of the fistulous orifice. This orifice may heal and then re-close, only to re-open later. The discharge of pus is never accompanied by intense pain. At most, the patient will complain of slight soreness in the area prior to reopening of the external orifice. The pus creates a tract in the surrounding tissues, following the locus minoris resistentiae. It may exit, at any point, in the oral mucosa or even in the skin. It is not uncommon, particularly in young patients, to find a cutaneous fistula at the level of the mental symphysis, if lower incisors are involved, or in the sub-mandibular region, if a lower first molar is involved. Also, it may be found in the floor of the nasal fossa, if a central incisor is involved.

Attempts to treat cutaneous fistulae with a circular incision of the orifice of the cutaneous fistula and excision of its entire tract with all the ramifications cannot be considered to comply with the present standard of care and should be regarded as highly undesirable. Most of the time, root canal therapy is the ideal treatment for such lesions. However, Grossman states that such tracts are lined by granulation tissue. In his study, Grossman was unable to identify any epithelium at all. Bender and Seltzer also conducted histological studies of numerous fistulous tracts without finding an epithelium lining. Given the current state of knowledge and scientific data, there is no reason to recommend surgical removal of such tracts, just as there is no reason to believe that even epithelium-lined fistula tracts should not heal after appropriate endodontic therapy.

Obviously, these fistulae must be distinguished from congenital fistulae of the neck, both lateral—arising from the second brachial cleft—and medial—arising from rests of the thyroglossal duct—which are lined by an epithelium. Such fistulae are of a different pathogenesis and definitely do not resolve spontaneously but only after careful surgical excisions of the tract.

The differential diagnosis of the case in question included the following:

- localised infection of the skin, such as pyoderma, pimples, ingrown hairs and obstructed sweat glands;
- traumatic or iatrogenic lesions;
- osteomyelitis;
- tuberculosis; and
- actinomycosis.

Case presentation

The patient was referred to me from overseas with a large mandibular fistula, which had previously been misdiagnosed as an infection of the sub-mandibular gland. Surgery had been performed and his submandibular gland had been extracted. The wound had not healed and the clinical situation was fast worsening. Thus, the wound had opened and subinfected with a heavy discharge of pus.

A dentist invited to see the patient immediately telephoned me and sent a photo of the wound to me via his mobile phone. Following my recommendation, the patient was immediately put under double antibiotic therapy (Amoxicillin 1000mg twice daily, Metronidazole 500mg twice daily). The patient presented to my clinic the following day, where we started with a detailed questionnaire to collect all the information about the history of the wound. The patient reported that he had been suffering from this fistula for quite some time already with intermittent phases of discharge of an exudates and numbness of the lower lip. No dental pain was reported.

A panoramic X-ray showed some bone rarefaction under teeth 47 and 46, but no invasion of the mandibular nerve tract was evident (Fig. 2a). A dental scan with 0.5 mm increment was performed in order to gain a better idea of the clinical situation. One of the sagittal slides (015) clearly shows the lesion around the distal root of tooth 47, surrounding the apical part and destroying the cortical bone invading the lower soft tissue (Fig. 2b). Furthermore, the mesial root of tooth 46 showed apical radiolucency, invading the tract of the lower mandibular nerve (014; Fig. 3). This pathology explains the numbness of the lower lip, while the pathology around the distal root of tooth 47 explains the extra-oral fistula.

Careful review of the axial slides in the area of tooth 47 (006) offers an idea about the amount of bone destruction in the lower lingual area. The axial slide under tooth 46 reveals the communication between the lesion under the mesial root and the mandibular nerve tract (Fig. 4).

Next, we established a clear diagnosis that the lesion was an extra-oral cutaneous fistula of dental origin. The patient was suffering from a large, infected open wound and a suitable treatment plan had to be established quickly. The following solutions were presented:

1. Extraction of the teeth and curettage of the area, with extra attention paid to the mandibular nerve: This plan could provide the patient with a solution for eliminating the infection and allowing the wound to heal. Yet, two strategic molars would be lost with this solution and a replacement would not be an easy job with this amount of bone destruction in the infected area.

2. More conservatively, a root canal treatment in order to clean and disinfect the root canal systems of the two molars, followed by an internal medication and a 3-D obturation capable of blocking the bacteria from reaching the apical part and trapping the remaining bacteria inside the root canal system: This approach would allow the patient to keep his molars and would provide an environment in which the healing process could begin. The risk would be the establishment of an external biofilm that cannot heal by itself and may require microsurgical removal.

The patient and I decided to preserve the two molars. Immediately, root canal treatment, cleaning and shaping of the canal space using TF files (Sybron-Endo) with copious and alternate irrigation of Chlorhexidine, SmearClear (Sybron-Endo), distilled water, and sodium hypochlorite with ultrasonic activation in a well-established sequence, was performed. An apical enlargement to size 40 in .04 taper was performed after crown down with K3 files (Sybron-Endo), to disturb the biofilm mechanically and to help reduce the colony formation unit (CFU).

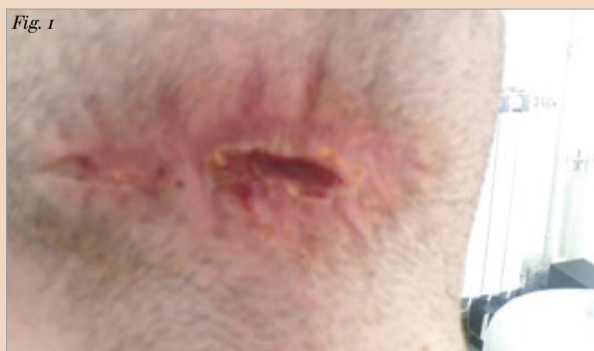

Fig. 1 Post-op photo one week after external surgery to remove the patient's sub-mandibular gland.

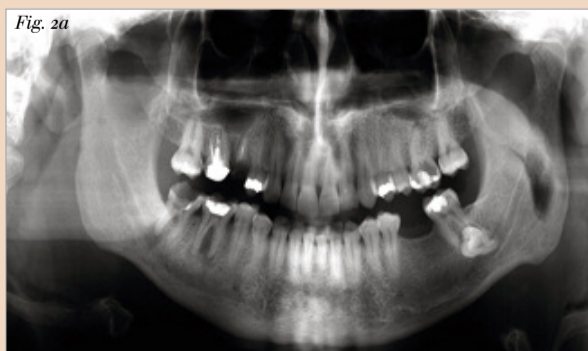

Fig. 2a Panoramic X-ray showing some bone rarefaction under teeth 47 and 46.

An intermittent paste was injected inside the shaped root canal system. The paste of two different antibiotics (Augmentin and Metronidazole) was manually mixed and injected with a paste filler. A hermetic temporary filling was placed for a week. The wound was covered with a dressing of steroids and antibiotic paste to prevent further external infection. A week later, the patient was already showing good progress. The wound had started to close and less inflammation and swelling were observed (Fig. 5). The root canal was reopened and cleaned, and no internal fluids were coming from the periapical region. RealSeal material was used as obturation material in a vertical condensation using RCPSL (Hu-Friedy) and an immediate build-up was performed. Thereafter, the patient was invited for regular control check-ups. A few weeks later, a post-op X-ray (Fig. 6) and photos were taken. The wound seemed to be in good condition and some skin and fibrous tissues were forming.

While I was writing this article, the patient visited Beirut and decided to come in for a check-up. He complained of a muscle disturbance of his lower lip, but all the previous numbness had disappeared. He agreed to perform an i-Cat scan in order to find out what was going on and to detect any pathology. I was amazed by the bone formation and complete healing (Figs. 7-9). The wound had also healed very well (Figs. 10a & b). I contacted a plastic surgeon and asked his opinion regarding the muscle disturbance. He posited that such symptoms may be caused by the tremendous loss of structure.

Discussion

An important diagnostic modality is the determination of the nature of fluid draining (if any) from the cutaneous sinus. During palpation, an attempt should be made to milk the sinus tract. Any discharge obtained should be scrutinised to determine its nature (saliva, pus or cystic fluid). Culture and sensitivity testing of the fluid should also be performed to rule out fungal and syphilitic infection.

Laskin elaborates on the physiological and anatomical factors that influence the spread and ultimate localisation of dental infections. Stoll and Solomon

also emphasise that the ultimate path of the sinus (irrespective of the source) depends on several factors: most importantly, the anatomy of the tooth involved, muscular attachments to the jaw, fascial planes of the neck, and involvement of permanent or deciduous teeth. Cutaneous rather than intra-oral lesions are likely to occur if the apices of the teeth are superior to the maxillary muscle attachments or inferior to the mandibular muscle attachments.

A pustule is the most common of all purulent draining lesions and is readily recognised by its superficial location and short course. Actinomycosis exhibits multiple draining lesions and characteristic fine yellow granules in the purulent discharge. The tooth is often not involved radiographically. If a sinus tract does not close after appropriate removal of the primary cause, the most common alternative cause is actinomycosis. (Fig. 5)

The challenge in these kinds of cases is to assemble all the pieces of the puzzle and build up a full idea of the clinical situation. Assembling the pieces means that all the diagnostic materials, such as a history questionnaire, X-rays, CT scans, and sometimes biopsy and bacteria culturing, must be provided in order to establish a correct diagnosis. Most of the time, the solution will only be a simple routine that must be performed in certain conditions. Turning to solutions that are more complicated—and that certainly can be more profitable—is not always the right choice, nor the most ethical one.

The author would like to thank Yulia Vorobyeva, PhD, interpreter and translator, for her help with this article. [D1](#)

About the author

Dr Philippe Sleiman received his DDS from the Lebanese University School of Dentistry in 1989. He conducted a DES in the endodontic programme at St Joseph University and a PhD at the Lebanese University Dental School. He has authored several international articles. He has his own line of instruments with the Hu-Friedy company and contributed to several project developments, and he has lectured internationally. Dr Sleiman is an instructor at the Lebanese University and an international trainer for the University of North Carolina. He is a fellow in the ICD and the AAE. Dr Sleiman maintains a private practice in Beirut, Lebanon, and in Dubai, UAE. Dubai, UAE and can be reached at phil2sleiman@hotmail.com.

Fig. 2b_Sagittal slide showing the lesion around the distal root of tooth 47.

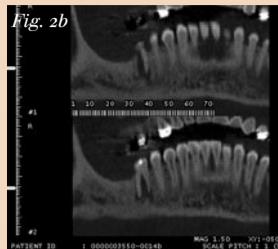


Fig. 3_The mesial root of tooth 46 showing apical radiolucency, invading the tract of the lower mandibular nerve (o14).

Fig. 4_Axial slide under tooth 46

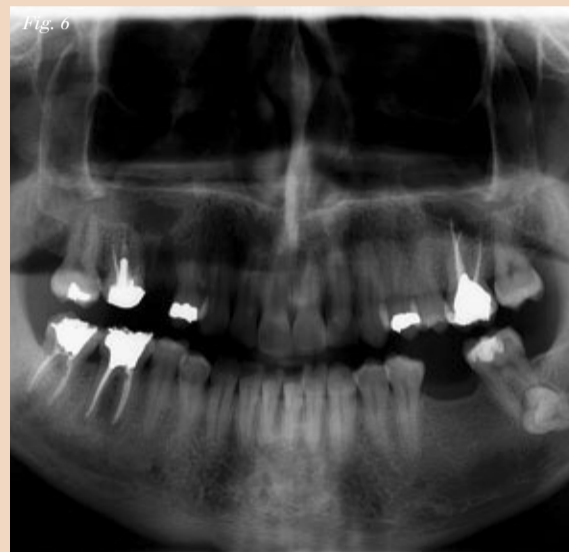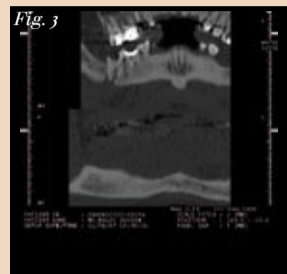
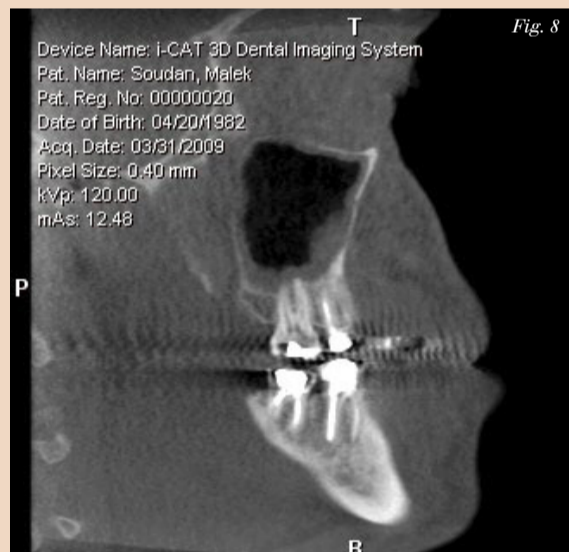

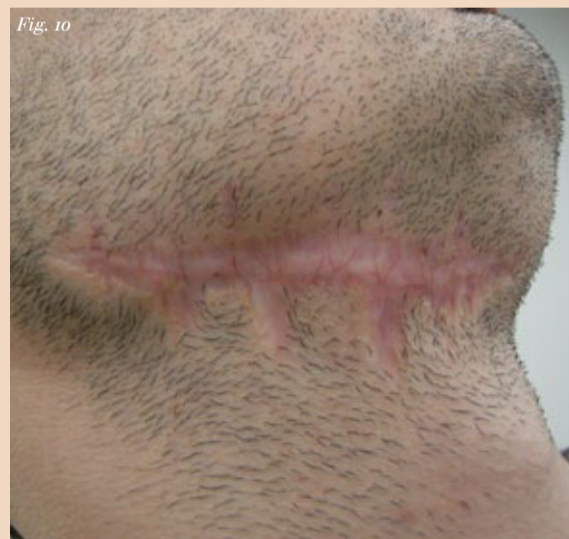
Fig. 6_Post-op X-ray a few weeks after treatment.



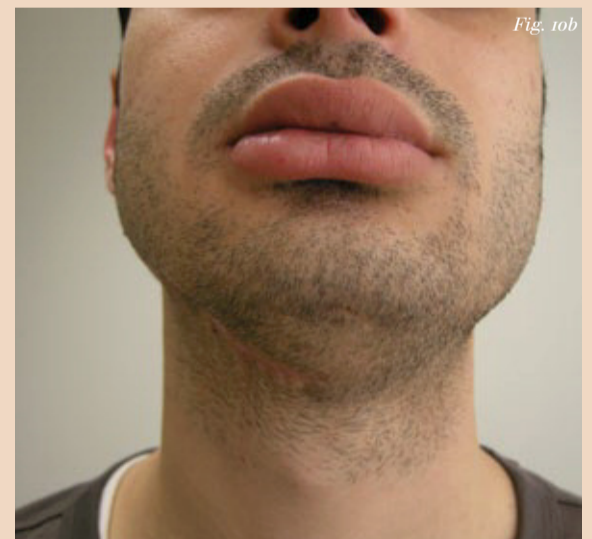
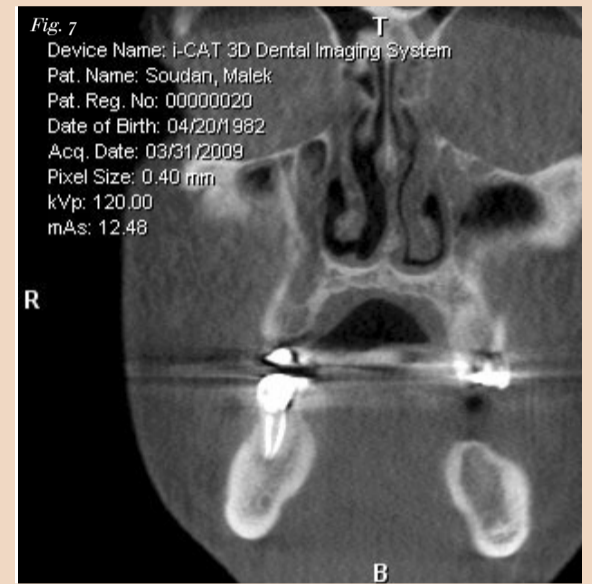
Figs. 7-9_i-Cat images showing good bone formation and complete healing.



Figs. 10a & b_Post-op woundhealing.

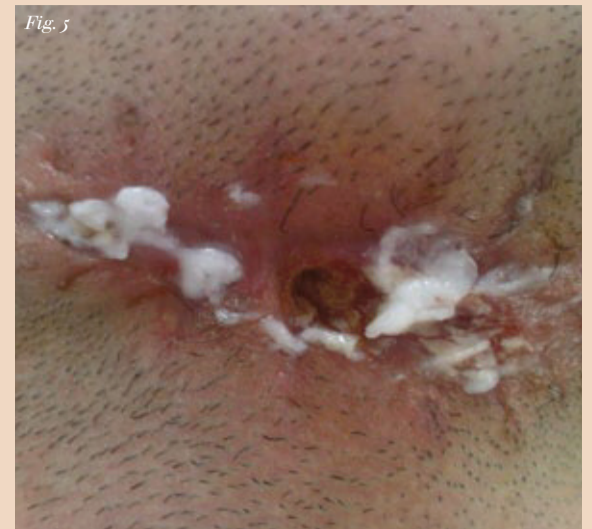

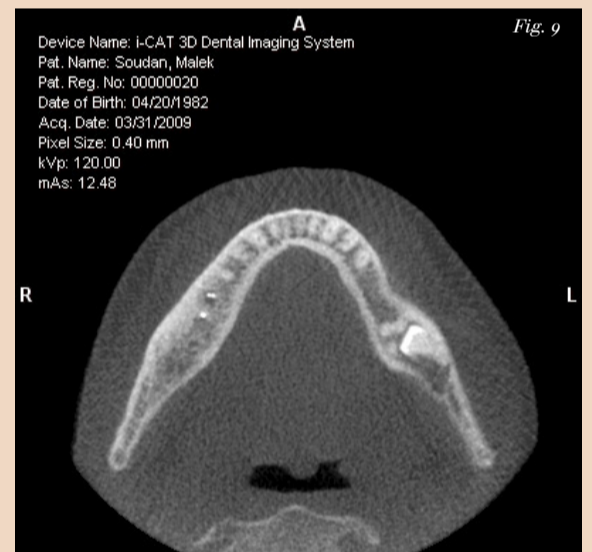Fig. 5_One week after steroids and antibiotic treatment.



regional outlook in terms of perspective and subject matter.
How can professionals enroll?
 They can either sign up for a one-year (10 exercises) by subscription for the magazine for one year (\$65) or pay (\$20) per article. After the payment, participants will receive their membership number and will be able to attend to the program.

How to earn CME credits?
 Once the reader attends the distance-learning program, he/she can earn credits in three easy steps:
 1. Read the articles.
 2. Take the exercises
 3. Fill in the Questionnaire and Submit the answers by Fax (+971 4 3686885) or
Email: info@cappmea.com

After submission of the answers, (name and membership number must be included for processing) they will receive the Certificate with unique ID Number within 48 to 72hours.
 Articles and Questionnaires will be available in the website after the publication.
www.cappmea.com

MEDIA CME Self-Instruction Program

Dental Tribune Middle East & Africa in collaboration with CAPP introduce to the market the new project mCME - Self Instruction Program. mCME gives you the opportunity to have a quick and easy way to meet your continuing education needs.

mCME offers you the flexibility to work at your own pace through the material from any location at any time. The content is international, drawn from the upper echelon of dental medicine, but also presents a

MIDDLE EAST EVENTS 2010

MAY

May 4, 2010 - May 6, 2010 -
Doha, Qatar

Qmedic 2010
CONEX

Tel: +974 4442270/71
Fax: +974 4422858
Mobile: +974 3595623
Email: qmedic@conexqatar.com
www.conexqatar.com
www.qmedic.net

Venue: Doha Exhibition Center,
Doha.

May 9, 2010 - May 12, 2010 -
Riyadh, Saudi Arabia

Saudi Dentistry 2010
Riyadh Exhibitions Co.

Tel: +966 1 2295604
Fax: +966 1 2295612
E-mail: esales@recexpo.com
Website: www.recexpo.com

Contact Person: Habib Alphonse
E-mail:

halphonse@recexpo.com
Venue: Riyadh International Ex-
hibition Center

May 13, 2010 - May 15, 2010 -
Colombo, Sri Lanka

APDC Asia Pacific Dental
Congress

C/o Sri Lanka Dental Associa-
tion

Tel/Fax: +94 11 2595147
E-mail: slda@sltnet.lk
Website: www.apdc2010.com //
www.slda.lk
Congress and Exhibition Venue:
Bandaranaike Memorial Con-
vention & Exhibition Centre

May 13, 2010 - May 14, 2010 -
Dubai, UAE

**4th CAD/CAM & Computer-
ized Dentistry International**
Conference

CAPP FZ L.L.C
Tel: +971 4 3616174
Fax: +971 4 3686885
Mob: +971 50 2795711
Email: info@cappmea.com
Website: www.cappmea.com
Venue: Dubai Marina

JUNE

Jun 13, 2010 - Jun 16, 2010 -
Tehran, Iran

IranMed 2010

**Iranian International Exhibi-
tions Company (IEC)**

Tel: +98 21 88206720-1 //
22662801-4
Fax: +98 21 88206720-1
E-mail: info@iranfair.com
Web: www.iranfair.com //
www.iranmedonline.com

Jun 16, 2010 - Jun 20, 2010 -
Damascus, Syria

SYRIAN DENTECH 2010

United for Int'l Exhibitions &
Conferences

General Manager: Ayman
Shamma'a

Tel: +963 11 3312123
Fax: +963 11 3312423
Mobile: +963 94 213131
E-mail: united.exh@mail.sy //
info@syrianmedicare.com
Web: www.syrianmedicare.com
Venue: Fairground- Airport
Road - Damascus - Syria

OCTOBER

Oct 29, 2010 - Oct 31, 2010 -
Mumbai, India

IDEM India 2010

KoelnMesse YA Tradefair Pvt.
Ltd.

Contact Person: Mr. Krunal
Goda

E-mail: k.goda@koelnmesse-in-
dia.com

Tel +91 22 42107805

Fax +91 22 40034433

Venue: Hall 6, Bombay Exhibiti-
on Centre, Mumbai - India

Oct 29, 2010 - Oct 31, 2010 -
Mumbai, India

World Dental Show 2010

Organizer:

Indian Dental Association

Co-ordinator WDS: Miss Tejal
Khanna

Tel: +91 22 43434545

Fax: +91 22 2368 5613

E-mail: info@wds.org.in

Website: www.wds.org.in

Venue: MMRDA Ground, Bandra
Kurla Complex, Bandra (East)
Mumbai, Maharashtra, India

NOVEMBER

Nov 2, 2010 - Nov 6, 2010 -
Alexandria - Egypt

AIDC 2010 - 17th Alexandria

International Dental Congress

Faculty of Dentistry, Alexandria

University

Tel: +203 481 1787

Fax: +203 486 8286

E-mail: info@aidc-egypt.org

E-mail: a-kahky@hotmail.com

www.aidc-egypt.org

Venue: Hilton Alexandria Green
Plaza Hotel

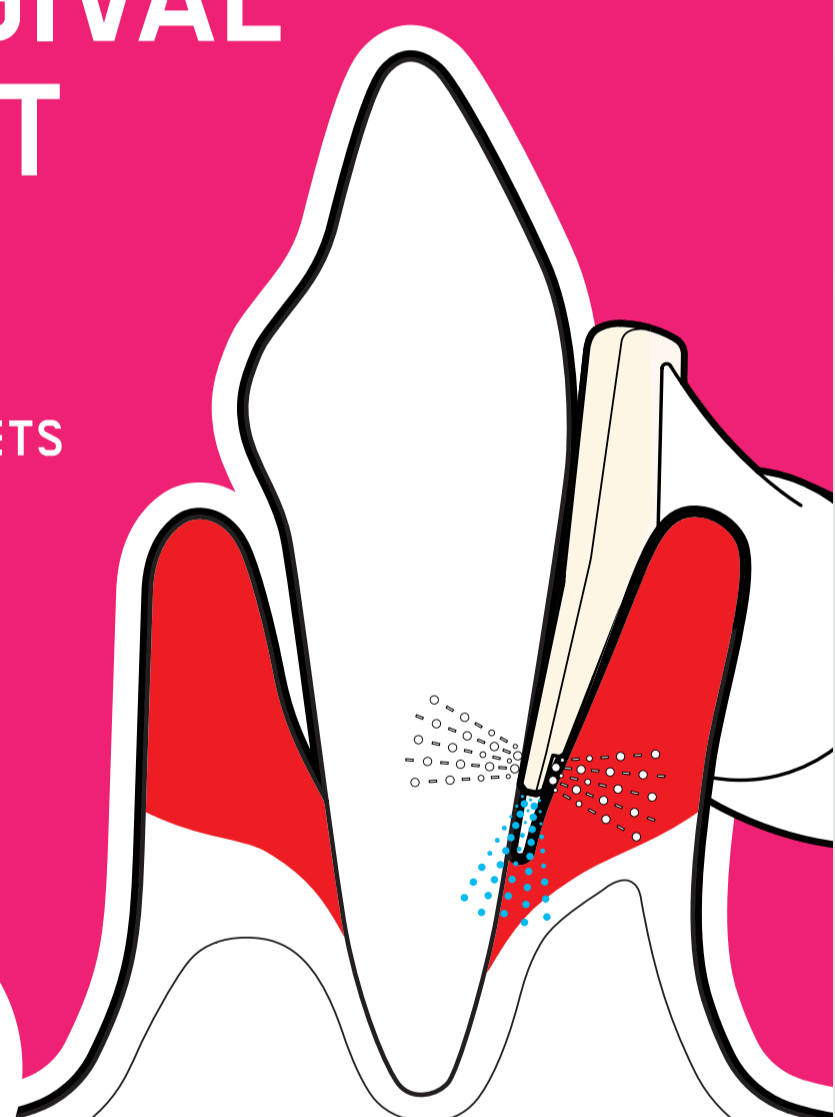
EMS-SWISSQUALITY.COM

EMS⁺
ELECTRO MEDICAL SYSTEMS

SUBGINGIVAL WITHOUT LIMITS

THE DEEPEST
PERIODONTAL POCKETS
NOW WITHIN REACH
WITH THE ORIGINAL
AIR-FLOW METHOD

**AIR-FLOW®
KILLS
BIOFILM**
ems-swissquality.com



> Subgingival application of the Original AIR-FLOW® method reduces periodontal pocket depth, removes biofilm, prevents periimplantitis

AIR-FLOW MASTER®

is the name of the world's first subgingival prophylaxis unit. With two application systems in one. For sub- and supragingival use with matching handpiece and powder chamber.

Incredibly easy to operate. Uniquely simple to use.

Touch 'n' flow: Highly sensitive 3-touch panel for easy choice of settings.



The inventor of the Original Air-Flow Method is now first to cross the boundaries of conventional prophylaxis.



For more information > welcome@ems-ch.com

AD

← Page 4

When is Botox used?

The areas that Botox is commonly used for smoothing of facial wrinkles are the forehead, between the eyes (glabellar region), and around the corners of the eyes (crow's feet) (Figs. 1, 2) and around the lips.

Botox has important clinical uses as an adjunct in TMJ and bruxism cases, and for patients with chronic TMJ and facial pain.

Botox is also used to complement esthetic dentistry cases; as a minimally-invasive alternative to surgically treating high lip line cases; for denture patients who have trouble adjusting to new dentures; for lip augmentation; and has uses in orthodontic and periodontic cases where facial muscle retraining is necessary.

No other health-care provider has the capability to help patients in so many areas as do dentists with Botox and dermal fillers.

What about dermal fillers?

Dermal fillers, such as hyaluronic acid (Juvederm Ultra and Restylane) are commonly used to add volume to the face in the nasolabial folds, oral commissures, lips and marionette lines (Figs. 3, 4).

As we age, collagen is lost in these facial areas and these lines start to deepen. These dermal fillers are injected right under the skin to plump up these areas so that these lines are much less noticeable.

Dermal fillers are also used for lip augmentation and are used by dentists for high lip line cases, uneven lips and to make the peri-oral area more esthetic. The face looks more youthful and is the perfect complement to any esthetic dentistry case that you do.

What's a dentist got to do with it?

We as dentists give injections all the time; this is just learning how to give another kind of injection that is outside the mouth, but is in the same area of the face that we inject all the time.

Dentists also have a distinct advantage over dermatologists, plastic surgeons, medical estheticians and nurses who commonly provide these procedures in that we can deliver profound anesthesia in these areas before accomplishing these filler procedures.

Patients who undergo such treatment by other health practitioners can be quite uncomfortable during the procedure, and indeed this is one of the biggest patient complaints about dermal fillers.

Many dentists are surprised to find that more than half of the United States allow dentists to provide Botox and dermal fillers to patients. Why wouldn't you provide these services if you already offer whitening and esthetic dentistry to your patients?

I would make the strong argument that dentists are the true specialists of the face, much more so than most other health-

care professionals, including dermatologists and plastic surgeons.

It is time to stand up for what we know and what we can accomplish.

Do patients want this?

Is there a market for these services? In 2008, close to \$5 billion was spent on botulinum toxin and dermal filler therapy in the U.S.

Think about this: that was money spent on non-surgical,

elective, esthetic procedures that could have been spent on esthetic dentistry, but the patient made a distinct choice.

Interestingly, these procedures become more popular in an uncertain economy because patients want to do something to look better that is more affordable than surgical esthetic options.

How do you get there?

Like anything else you do, offering this type of service requires training. The learning

curve is short because you already know how to give comfortable injections. I often give training sessions in Botox and dermal fillers and dentists are amazed how easy these procedures are to learn and accomplish compared to everything else we do.

Finding practice models is easy: start asking family and friends who will fight to have you practice on them.

If you want even more proof, ask women in your practice if

they have had or would like Botox or dermal filler therapy.

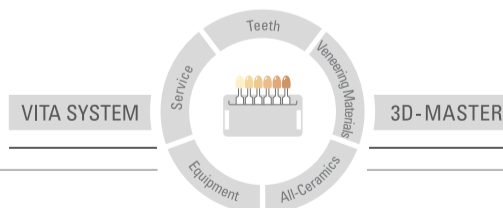
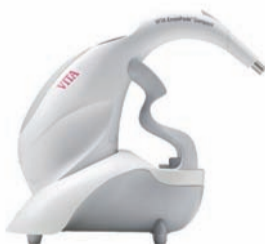You will be overwhelmed at the positive response and shocked at the number of people you know already receiving these treatments.

Conclusion

What's the next big thing in dentistry? It may come as we start expanding outside of the teeth and gums into the peri-oral and maxillofacial tissues, which is within every dentist's skill set.

AD

VITA Easyshade® Compact – The exact shade in the blink of an eye.



VITA

It's digital, cable-free, lightweight and mobile – there are a good many reasons for choosing the VITA Easyshade Compact. And every one of these is in itself a winner. With the new generation of digital shade measurement you determine and check the tooth shade in a matter of seconds. The VITA Easyshade Compact is

designed for all shades of the VITA SYSTEM 3D-MASTER and the VITA classical A1-D4 shades. This high-tech instrument impresses with a great accuracy of measurement using state-of-the-art spectrophotometric measurement technology. See for yourself. Find out more at www.vita-zahnfabrik.com.