

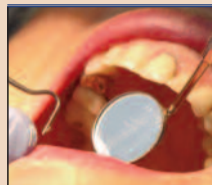# DENTAL TRIBUNE

— The World's Dental Newspaper · Middle East & Africa Edition —

PUBLISHED IN DUBAI

September 2010

No. 7 Vol. 8



**Trends & Applications**  
A Challenging Task

▶ Page 3



**Media CME**

Using resorbable barriers to make root recession coverage predictable

▶ Page 6



**Practice Matters**

Dental Care or Beauty Treatment?

▶ Page 8

## Diabetes Pill Actos May Pose Cancer Risk

### FDA Reviewing Suggesting Possible Link

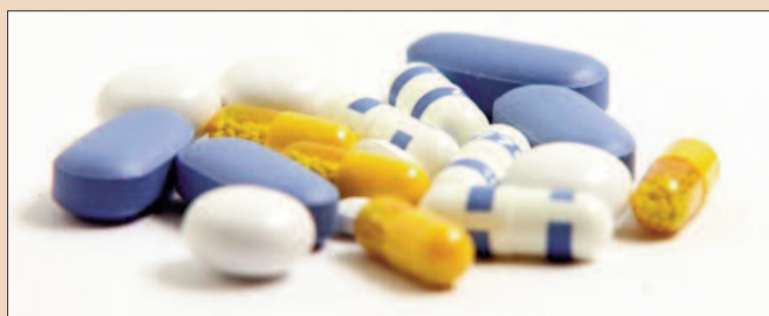WASHINGTON — The Food and Drug Administration is reviewing data suggesting a possible link between the widely used diabetes medication Actos and bladder cancer.

The agency said Friday that five-year results from an ongoing study show that patients who have taken Actos for the longest period of time had a higher risk of bladder cancer. Bladder cancer was also more prevalent in patients who had taken the largest cumulative dose of the drug.

Actos manufacturer Takeda Pharmaceuticals is conducting the study, which is scheduled to run 10 years.

"The agency has not concluded that Actos increases the risk of bladder cancer," the agency said in a statement. Patients should continue taking Actos unless told otherwise by their doctor, according to the agency statement.

Actos agreed to study the risk of bladder cancer with its drug in 2005. But a company executive said Friday the results are too



preliminary to make any conclusions about the drug.

"This interim analysis raises a question, but it doesn't answer anything," said Dr. Robert Spanheimer, vice president of medical affairs at Takeda. "We are committed to finishing the study because I think that's when you're going to get the greater understanding."

Prescriptions for Actos have risen since 2007, when its chief competitor, Avandia, was first associated with cardiovascular problems. The FDA is considering whether to withdraw Avandia, which is marketed by British drugmaker GlaxoSmithKline. Actos and Avandia work similarly

to control blood sugar and are the only drugs in their class currently on the market. A third drug called Rezulin was withdrawn in the U.S. in 1997 due to liver toxicity.

Critics of Avandia have called on the FDA to recall the drug, arguing that Actos offers the same benefits without risks of heart attack and stroke.

The FDA's review of Actos' cancer risks is preliminary, but could shape its decision on Avandia, which is expected in coming weeks.

U.S. sales of Actos have risen steadily - hitting \$5.4 billion last year - as Avandia's reputation has soured. Last year Avandia posted \$520 million in sales. [D](#)

## Kids without food in Pakistan floods face death

More than 100,000 children left homeless by Pakistan's floods are in danger of dying because they simply do not have enough to eat, according to UNICEF. Children already weak from living on too little food in poor rural areas before the floods are fighting to stay alive, as diarrhea, respiratory diseases and malaria attack their emaciated bodies.

Doctors roaming the 100-degree (38-degree Celsius) camp that reeks of urine and animal manure have warned Bunglani three times to take her children to the hospital, or they will die.



In this Sept. 13, 2010 photo, a Pakistani mother helps her child drink water in Sukkur, Sindh province, southern Pakistan. (AP Photo/Aaron Favila)

The mother says she knows they need help, but she cannot

→ [DT](#) page 2

**European Medical**  
Equipment Distribution - Middle East

**Dentistry of the 21st Century**  
Come and Join Us

October 15th 2010 at Movenpick Hotel Bur Dubai  
Four International speakers, Four different topics  
6 CME Credit hours

Email: [info@euro-med-me.com](mailto:info@euro-med-me.com)  
Contact number: 050 674 2359  
for more information visit [www.euro-med-me.com](http://www.euro-med-me.com)

AD

# PROMEDICA

Highest quality made in Germany

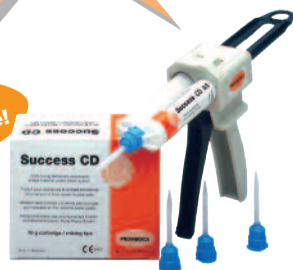- ▶ high quality glass ionomer cements
- ▶ first class composites
- ▶ innovative compomers
- ▶ modern bonding systems
- ▶ materials for long-term prophylaxis
- ▶ temporary solutions
- ▶ bleaching products...

All our products convince by

- ▶ excellent physical properties
- ▶ perfect aesthetical results

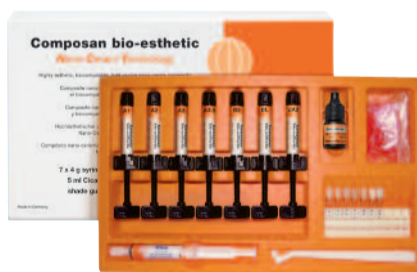Meet us at  
several exhibitions -  
[www.promedica.de](http://www.promedica.de)

New:  
Bleach Shade!



**Temporary crown and bridge material**

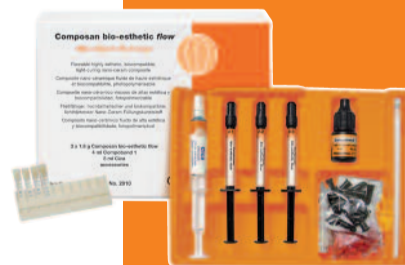- particular fracture and wear resistance
- now available in 6 attractive shades



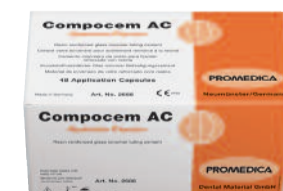**Light-curing nano-ceram composite**

- universal for all cavity classes
- comfortable handling, easy modellation
- highly esthetic and biocompatible

Nano-Ceram-Technology



• exact match of translucency and shade to the packable Composan bio-esthetic



**Resin-reinforced glass ionomer luting cement**

- strong adhesion, very low film thickness
- especially suited for zirconia-based pieces

**PROMEDICA**

**PROMEDICA Dental Material GmbH**

Tel. +49 43 21 / 5 41 73 · Fax +49 43 21 / 5 19 08

Internet: <http://www.promedica.de> · eMail: [info@promedica.de](mailto:info@promedica.de)



## Paste-free toothbrush endorsed by HK dental show



Daniel Zimmermann  
DTI - HONG KONG / LEIPZIG

**Germany:** A Japanese toothbrush that does not require tooth paste for removing dental plaque has been received special acknowledgement by the Hong Kong International Dental Expo and Symposium. The organisers awarded research presented by dental students from the University of Saskatchewan College of Dentistry in Canada who found that the brush prevents bleeding

associated with periodontal disease more effectively than a regular toothbrush.

In contrast to tooth paste that removes dental plaque through abrasion, the Soladey-J5X utilizes electrolysis to destroy cell structures of bacteria that form the biofilm inside the mouth. To achieve this, negatively-charged light particles or electrons are gathered by a solar panel and transmitted through a Titanium dioxide semiconductor on the

head of the brush where they chemically react with acids responsible for tooth decay.

The toothbrush, which has been awarded during the FDI Worldental Congress in Dubai, amongst others, is being developed and marketed by Shiken Co. Ltd., a manufacturer based in Osaka in Japan. Aside from a good light source to charge the solar panel, it does not require people to change their brushing habits, the company states. [DTI](#)

← DTI Page 1

leave the tent without her husband's consent. She must stay until he returns, even if it means risking her daughters' lives. "I am waiting for my husband," she says, still fanning flies from the sweating babies. "He is coming."

The floodwaters that began swamping a section of Pakistan larger than Florida six weeks ago continue to inundate new areas, forcing even more people to flee. At least 18 million have already been affected, and nearly half of them are homeless. Many have been herded into crude, crowded camps or left to fend for themselves along roads.

But doctors warn the real catastrophe is moving much slower than the murky water. About 105,000 kids younger than 5 are at risk of dying from severe acute malnutrition over the next six months, UNICEF estimates.

"You're seeing children who were probably very close to the brink of being malnourished, and the emergency has just pushed them over the edge," says Erin Boyd, a UNICEF emergency nutritionist working in southern Pak-

istan. "There's just not the capacity to treat this level of severe acute malnutrition."

The U.N.'s World Food Program alone has fed more than 4 million people since the crisis began, distributing monthly rations that include nutrition-packed foods for children. But the sheer geographic and human scale of the disaster is overwhelming, and U.N. Secretary-General Ban Ki-moon has called it the worst he has ever seen.

Even now, after the water has receded in many areas, some families who refused to abandon their villages remain marooned on islands cut off from all transport. The lucky ones sprint and dive for supplies dropped by choppers hovering above. But not everyone is being reached.

Bunglani says her two baby girls have had little to eat since the Indus River jumped its banks and turned one-fifth of the country into a muddy lake. She was working in the field when the water began surging, leaving her just enough time to grab a baby under each arm and run to safety.

The military transported the extended family to the camp on the outskirts of Sukkur, where she

said they typically receive one meal a day consisting of rice, vegetables or lentils. There is nothing for the babies, and the newborn simply was not strong enough to survive.

"They are getting bread. They don't have milk. She can eat rice," Bunglani says, pointing to Sughra, 2. "But the younger one cannot."

In the past day, Sughra has stopped eating altogether. She will not take rice or any other food. She just turns her head and shoves her mother's hand away. The little one, Heleema, 1, cannot sit on her own without support, even though she should be getting ready to walk by now.

"These kids are everything to me," Bunglani says. "I am worried about them, and everybody can see what condition they are in."

Post-flood data are lacking, but the World Health Organization says about 50 percent to 55 percent of children in Pakistan had stunted growth before the calamity, a sign of chronic malnutrition. Farming families have now been flushed from their homes, losing the vital crops and livestock that were sustaining them in one of the country's poorest areas. [DTI](#)

## Researchers say the best teeth whitener is fruit



A recent study by Harvard University revealed that eating fruit daily is the best way to whiten teeth. Through a three-month clinical study, it was determined that strawberries, orange peels and lemon juice are the most effective teeth whiteners in the world. Strawberries can be made into a puree and smothered on the teeth. Strawberries have a natural enzyme that removes tooth stains, according to teethwhitener.net.

Orange peels can be used to remove tooth stains, just by rubbing the inside of a peel against tooth surfaces.

A little lemon juice and salt work very well to remove stains. Just wash your mouth out with this or even rock salt and warm water will work at night to remove stains.

Baking soda has long been known to work wonders for smiles. It may taste awful, however adding

baking soda on a toothbrush along with mouthwash can help alleviate the negative taste. Also a strawberry mixture added to baking soda/peroxide not only adds a sweet taste to the concoction, but is yet another effective whitener.

It is best to not drink coffee, tea, colas or red wine, which are all known to stain teeth and cause some decay of the enamel. Apples and potatoes can cause discoloration, but they also tend to clean off the teeth. Mouth washing is important after eating apples.

Also, stop or slow down tobacco use, as both dipping and smoking can cause tooth discoloration. Avoid mouthwash, as it sometimes will stain teeth. Finally, remind patients that an ounce of prevention is worth more than a pound of cure. Going to the dentist once or twice a year for a cleaning and checkup is strongly suggested. [DTI](#)

## Mum's Miracle Cuddle Brings Baby Back to Life



**They were delivered at 27 weeks, weighing just 2lb, and though Mrs Ogg's little girl Emily was healthy, her brother Jamie was not breathing. After battling to save him for 20 minutes, medical staff told her he had not survived.**

"The doctor asked me had we chosen a name for our son," said Mrs Ogg. "I said 'Jamie' and he turned around with my son already wrapped up and said: 'We've lost Jamie, he didn't make it, sorry'. "It was the worst feeling I've ever felt. I unwrapped Jamie from his blanket. He was very limp."

Mrs Ogg said that she wanted to hold him next to her skin. "I took my gown off and arranged him on my chest with his head over my arm and just held him."

"He wasn't moving at all and we just started talking to him.

"We told him what his name was and that he had a sister. We told him the things we wanted to do with him throughout his life."

After two hours, he began showing signs of life. "Jamie occasionally gasped for air, which doctors said was a reflex action," Mrs Ogg explained.

"But then I felt him move as if he were startled, then he started gasping more and more regularly. I gave Jamie some breast milk on my finger, he took it and started regular breathing normally."

"I thought 'Oh my God, what's going on?' A short time later he opened his eyes. It was a miracle.

"Then he held out his hand and grabbed my finger. He opened his eyes and moved his head from side to side. The doctor kept shaking his head saying: 'I don't believe it, I don't believe it.' It is thought that the warmth of Mrs Ogg's body acted like an incubator to keep the baby warm and stimulated.

It adds weight to the theory of "kangaroo care", named after the way marsupials care for their young in their pouches. Some experts believe a skin-to-skin ap-

proach is more beneficial than taking newborn babies into intensive care incubators.

Jamie is now a healthy five month old.

His father David said: "Luckily I've got a very strong, very smart wife. She instinctively did what she did. If she hadn't done that, Jamie probably wouldn't be here." [DTI](#)

### Editorial Board

Prof. Abdullah Al-Shammary, Restorative Dentistry, KSA  
Prof. Hussain F. Al Huwaizi, Endodontics, Iraq  
Prof. Samar Burgan, Oral Medicine, Jordan  
Dr. Abdel Salam Al Askary, Implantology, Egypt

Dr. Talal Al-Harbi, Orthodontist, Qatar  
Dr. Mohammed H. Al Jishi, Bahrain  
Dr. Lara Bakaeen, Prosthodontist, Jordan  
Dr. Aisha Sultan, Periodontist, UAE  
Dr. Kamal Balaghi Mobin Aesthetics, Iran

### DENTAL TRIBUNE

The World's Dental Newspaper - Middle East & Africa Edition

### Published by Education Zone

in licence of Dental Tribune International GmbH

© 2010, Dental Tribune International GmbH. All rights reserved.

Dental Tribune makes every effort to report clinical information and manufacturer's product news accurately, but cannot assume responsibility for the validity of product claims, or for typographical errors. The publishers also do not assume responsibility for product names or claims, or statements made by advertisers. Opinions expressed by authors are their own and may not reflect those of Dental Tribune International.

President/CEO

Yasir Allawi  
y.allawi@dental-tribune.ae

Director mCME:

Dr. D. Mollova  
info@cappmea.com

Marketing manager

Khawla Najib  
khawla@dental-tribune.ae

Production manager

Hussain Alvi  
dentalme@dental-tribune.ae

PO Box 214592, Dubai, UAE, Tel + 971 4 591 0257  
Fax + 971 4 566 4512 [www.dental-tribune.com](http://www.dental-tribune.com)



# A challenging task

## Prof Dr Liviu Steier discusses how to restore the aesthetic zone with implant-supported restorations

Restoring the anterior aesthetic zone using implant-supported restorations is one of the most challenging tasks. Knowledge of related literature, impeccable skills, a lot of experience and a well-trained team compliment a successful treatment. Different implant systems claim to offer the only technology leading to success. The author describes a case where an “outdated” system, external hex implant system offers a similar success rate, by only following a correct protocol.

### Aesthetic 3-dimensional requirements

For optimal aesthetics, some literature suggests some key factors to be respected as they play an important role for long-term success:

- Availability of two mm buccal bone plate
- Implant tooth distance should be 1.5mm
- Implant to implant distance three mm
- Biologic width is indicated with two-three mm

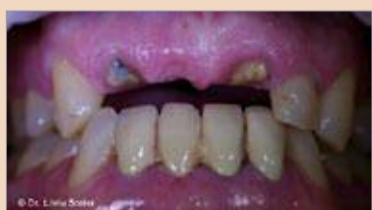### Clinical case

A 45-year-old male has been referred to the practice for rehabilitation of the anterior aesthetic zone. His medical and dental history, as well as his treatment desires, were recorded.

### Dental history

The patient lost tooth 11 due to trauma about 17 years ago. He was advised to restore the gap with a PFM bridge. He also reported multiple re-cementation sessions. Later, insufficient root canal treatments (X-rays) seemed to have weakened the remaining tooth structure. The clinical picture below demonstrates also fractured adhesive posts.

X-ray diagnosis proved vertical root fracture of both teeth. Poor prognosis led to immediate extraction recommendation, to avoid further infection (leakage) and optional bone loss.



Direct clinical view of fractured teeth 12 and 21 (including adhesive posts).

### Treatment plan

The following treatment options were identified and discussed with the patient:

- Extraction and no treatment

- Extraction and restoration with a removable device.
- Extraction and immediate implant placement.

Benefits and disadvantages of different treatment options AD

### Extraction and no treatment

- Benefits**
- Fast
  - No cost implication

### Disadvantages

- Aesthetic breakdown of the

- anterior area
- Function and speech alteration

### Extraction and restoration with a removable device

- Benefits**
- Fast
  - Minor cost implication

### Disadvantages

- Aesthetic breakdown of the anterior area
- Function and speech alteration.
- Removable device acts as an impediment

### Extraction and immediate implant placement

- Benefits**
- Preservation of bone
  - Optimal functional and aesthetic rehabilitation

### Disadvantages

- Cost implication
- Extended treatment need

Patient decided to go for the extraction and have im-

→ [D7](#) Page 4



**EMS**  
ELECTRO MEDICAL SYSTEMS

[EMS-SWISSQUALITY.COM](http://EMS-SWISSQUALITY.COM)

# AIR-FLOW KILLS BIOFILM

**THE NEW AIR-FLOW HANDY PERIO GETS RID OF THE ENEMY – WITH GENTLE ACTION AND UTMOST PRECISION**



**DEEP DOWN**, between tooth and gingiva, billions of bacteria managed to proliferate under the cover of malicious biofilm – until now.



Grain size ~ 25 µm

Together with the Original Air-Flow Powder Perio, the new Air-Flow handy Perio with its unique Perio-Flow nozzle tracks down biofilm, even in the deepest periodontal pockets.

Three horizontal nozzle apertures for the air-powder mixture, a separate vertical water nozzle aperture for rinsing: what used to be off limits is now easily reachable, through gentle action and without any risk of emphysema. And since the Air-Flow Powder Perio is particularly fine, the tooth surface is not damaged.



With its new Air-Flow handy Perio, Air-Flow has assigned its latest family member to combat – right on target for subgingival prophylaxis in your practice.

"I FEEL GOOD"

For more information > [welcome@ems-ch.com](mailto:welcome@ems-ch.com)



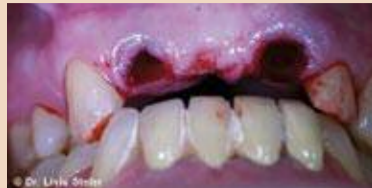← DT Page 5

mediate implants placed. Impressions were taken so the patient could be offered a removable temporary device once extraction and implants performed for the healing time.

#### Treatment procedure

Retained roots were extracted in local anesthesia (four per cent Articain) using minimal invasive procedure.

AD



Clinical picture showing the alveolae immediate after the atraumatic extraction

The alveolae were thoroughly scooped and cleaned. Available bone was sounded and found adequate for immediate implant placement. Two Biohorizons Ø4.0mm x 12mm external implants were inserted in the al-

veolae. The remaining buccal gap to the buccal bone wall was less than 1.5 mm so that no further attention (fill) was requested.

Implant in position 11 was performed ad modum flapless surgery. Once drill protocol as recommended by the manufacturer has been performed a Biohorizons Ø4.0mm x 12mm external implant could be seated.

Successful three-dimensional implant placement was performed

following the criterias mentioned in the introduction. Bony and soft tissue healing went extremely well also due to available thick gingiva phenotype.

#### After treatment

Allocated healing time was five months. Second stage surgery was performed under local anesthesia. Temporary abutments were screwed in place and temporary crowns performed. The emergence profile could be nicely shaped during the next visits.

Impression was taken once optimal conditions were achieved. The technician manufactured three zirconia abutments. The final impression was taken and the final restoration were delivered after a try-in session with bisque bake.

The final crowns were cemented while a retraction cord in place to enhance cement excess removal. Occlusion was checked and patient received hygiene instructions. Recall sessions were scheduled.

## كلية نيقولا وآسب الجامعية NICOLAS & ASP UNIVERSITY COLLEGE

The 1st Accredited Dental Postgraduate Training Programs in the UAE

Register NOW...

### Masters Degree in Pediatric Dentistry

- Next Intake - (February 2011)
- 3 years study in UAE
- Accredited by
  - UAE Ministry of Higher Education & Scientific Research



### Diploma in Advanced Education in General Dentistry (AEGD)

- New Intake - (October 2010)
- 2 years Higher Diploma in UAE
- Accredited by
  - UAE Ministry of Higher Education & Scientific Research

### Masters Degree in Orthodontics

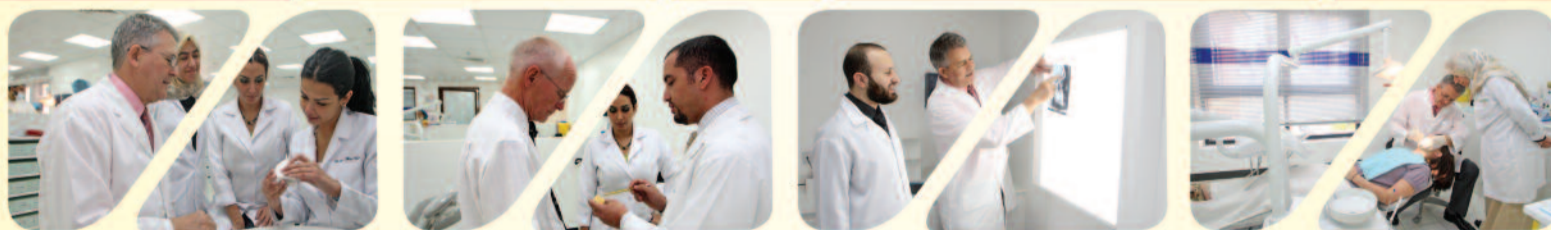- 5th Intake (February 2011)
- 3 years study in UAE
- Recognized by Swedish National Board of Health and Welfare
- In collaboration with Malmö University, Sweden
- Accredited by
  - UAE Ministry of Higher Education & Scientific Research
  - Saudi Commission for Health Specialities

### High Diploma in Oral Implantology

- 5th Intake (December 2010)
- 1 year (modules) for practicing dentists and specialists
- Program is offered in cooperation with Gothenberg University, Sweden
- Accredited By
  - UAE Ministry of Higher Education & Scientific Research

Unique group of European & American faculty

For more information: Tel.: 00971 43624788



#### Abu Dhabi Headquarters

Admission Office:  
Al Odaid Office Tower, Airport Road, Abu Dhabi, UAE  
10th Floor, Office 1201  
Telephone: +971 2 404 7141

#### Dubai Branch

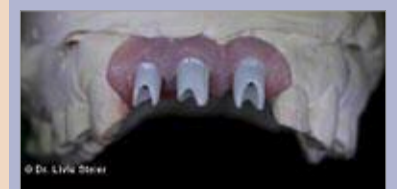Dubai Healthcare City  
Ibn Sina Building (No. 27)  
Block D, 3rd floor, Office 302  
Telephone: +971 4 3624787

Fax: +971 4 362 4793

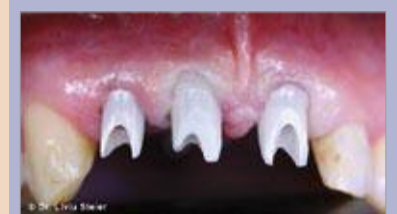P.O. Box: 53382, Dubai, UAE

Website: [www.dubaipostgraduate.com](http://www.dubaipostgraduate.com)

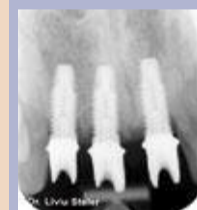
Email: [info@dubaipostgraduate.com](mailto:info@dubaipostgraduate.com)



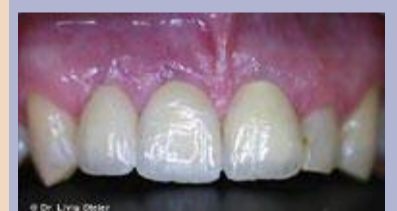Picture showing the master model with gingival mask and ceramic abutments



Direct clinical picture showing the ideal contour with adequate scalloped margins having thick collar and superbly mimicking natural conditions



X-ray control showing the optimal fit of the abutments as well as perfect crestal bone levels



Clinical picture at six months recall showing optimal soft tissue conditions, nice interdental papillae and natural emergence profile


#### Conclusion

It is of course only of anecdotal value to use a case presentation to exemplify the achievement of predictable aesthetics with conventional implant systems, but doubts might raised today about statements and claims made by modern implantology.

The author recommends the following criteria as mandatory:

- Good treatment planning
- Adequate protocols
- An excellent team (surgeon & restorative and laboratory technician) for predictable long-term success DT

#### About the author



Dr Liviu Steier (PhD) is Specialist fuer Prothetik ([www.dgzmk.de](http://www.dgzmk.de)) and specialist in Endodontics (GDC-UK). He is an honorary clinical associate professor at Warwick

Medical School and course director of the MSc in Endodontics ([www.warwick.ac.uk/go/dentistry](http://www.warwick.ac.uk/go/dentistry)). He is a member of the Scientific Advisory Board for the Journal of Endodontics (AAE) and maintains a private referral practice for endodontics, implantology, etc at 20 Wimpole Street, W1G 8GF London ([www.msdentistry.co.uk](http://www.msdentistry.co.uk)).



Under the patronage of  
**H. H. Sheikh Hamdan Bin Rashid Al Maktoum**  
Deputy Ruler of Dubai, Minister of Finance  
President of the Dubai Health Authority

هيئة الصحة بدبي  
DUBAI HEALTH AUTHORITY

**“Delivering Science & Technology”**

**DUBAI 2011**  
1-3 February  
Dubai International Convention & Exhibition Centre

Supported by  
**fdi**

**15<sup>th</sup> Anniversary**

**UAE INTERNATIONAL DENTAL CONFERENCE & ARAB DENTAL EXHIBITION**  
“Where Oral Health Professionals Meet”

- Keep up to date with the newest developments and techniques in dentistry through a series of lectures and specialized courses
- Enhance your dental practice with various management and clinical workshops
- Learn the optimal prevention and treatment services in the field of dental traumatology
- Visit 20,000 sqm. of exhibition space and explore the latest innovations and business practices
- Enjoy a panoramic view from Burj Khalifa, the world's tallest tower
- Ride the Metro and see Dubai !

[www.aeedc.com](http://www.aeedc.com)

Organised by: INDEX®  
Strategic Partner: Arab-African Scientific Centre  
Supported by: HORIZONS, Arab-African Scientific Centre, etc.

**INDEX® Conferences & Exhibitions Organisation Est.**  
P.O. Box: 13636 | Ibn Sina Bldg, #27 Block B, Office 203, Dubai Healthcare City | Dubai - United Arab Emirates  
Tel: +971 4 3624717 | Fax: +971 4 3624718 | E-mail: aeedc@index.ae | Website: www.index.ae

**AESTHETIC DENTISTRY MENA AWARDS 2010**

**AWARDS CEREMONY**  
05 NOVEMBER 2010  
DUBAI, UAE

Orthodontic Best Case  
Presented by EMA Dental Society and CAPP

- CONSERVATIVE AESTHETIC BEST CASE
- PROSTHETIC RESTORATION BEST CASE (FIXED AND REMOVABLE)
- IMPLANTOLOGY AND RED-AESTHETIC BEST CASE
- ORTHODONTIC BEST CASE
- CONGENITAL & MAXILO-FACIAL DEFORMITIES BEST CASE
- MULTIDISCIPLINARY THERAPY BEST CASE
- CHARITY TREATED PATIENT BEST CASE

Submit Your Case and be the Winner

[www.cappmea.com/awards2010](http://www.cappmea.com/awards2010)

**DENTISTRY 2010**

9 - 11 November 2010 • Abu Dhabi National Exhibition Centre, UAE

**Accreditation CME**

**The Definitive Dentistry Event in the Middle East**

The conference will feature the most up-to-date information on the diagnosis and treatments available from international experts including:

**Renowned Dental Personality**  
Prof Nasser Barghi, Professor and Head of Division - Esthetic Dentistry, University of Texas, San Antonio, USA

**Diplomate of the American Board of Oral Medicine**  
Prof Juan Yepes, Associate Professor and Director of Radiology, University of Kentucky, USA

**Award Winner: Excellence in Dental Education**  
Prof Patricia Reynolds, Director of Flexible Learning - Dental Institute, King's College, UK

Register your delegate place today  
[www.dentistryme.com](http://www.dentistryme.com)

Supported By: Ministry of Health UAE, Arab Health, etc.  
Organised By: Middle East, Arab Health  
Member Of: aeo  
Media Partners: Dental Tribune, Quintessenz Verlag, JMD, Smile, WorldDental, Passi Publications LLC, Greenleaf

+971 4 336 7334 +971 4 336 4021 dentistry@iirme.com  
[www.dentistryme.com](http://www.dentistryme.com)

**I NY** ANNUAL DENTAL TRIBUNE STUDY CLUB  
**SYMPOSIA AT THE GNYDM**  
NOVEMBER 28 - DECEMBER 1, 2010, 10:00 AM DAILY

Greater New York Dental Meeting  
[www.gnydm.com](http://www.gnydm.com)

For the third year in a row, the DTSC hosts its annual CE Symposia at the GNYDM, offering four days of focused lectures in various areas of dentistry. Find us on the Exhibition Floor in Aisle 6000, Room # 3.

Each day will feature a variety of presentations on topics, which will be led by experts in that field. Participants will earn ADA CERP CE credits for each lecture they attend. DTSC is the official online education partner of GNYDM.

PLEASE SEE PROGRAM DETAILS UNDER [WWW.DTSTUDYCLUB.COM/GNYDM](http://WWW.DTSTUDYCLUB.COM/GNYDM)

REGISTER NOW: [WWW.GNYDM.COM](http://WWW.GNYDM.COM)

FREE FOR REGISTERED GNYDM ATTENDEES, BUT PRE-REGISTRATION IS RECOMMENDED.  
For more information, please contact Julia E. Wehkamp, C.E. Director, Dental Tribune Study Club  
Phone: (416) 907-9836, Fax: (212) 244-7185, E-mail: j.wehkamp@DTStudyClub.com

**SUNDAY, NOVEMBER 28**  
10:00 - 11:00 Howard Glazer, DDS, FAGD  
BEAUTIFUL: GO WITH THE FLOW - COURSE: 3020  
11:20 - 12:20 John Flucke, DDS  
LIGHT CURED ADHESIVE DENTISTRY - SCIENCE AND SUBSTANCE - COURSE: 3030  
1:20 - 2:20 Martin Goldstein, DMD  
A SIMPLIFIED APPROACH TO MULTI-LAYER DIRECT COMPOSITE BONDING - COURSE: 3040  
2:40 - 3:40 Jay Reznick, DMD, MD  
3D IMAGING AND CT-GUIDED DENTAL IMPLANT SURGERY - 3050  
4:00 - 5:00 Louis Matcacher, DDS, MAGD  
TOTAL FACIAL ESTHETICS FOR EVERY DENTAL PRACTICE - COURSE: 3060

**MONDAY, NOVEMBER 29**  
10:00 - 11:00 Mrs. Nigel Brandon-Kelsch  
ECO-FRIENDLY INFECTION CONTROL-UNDERSTANDING THE BALANCE - COURSE: 4120  
11:20 - 12:20 Gregori Kurtzman, DDS  
INCORPORATING NEW ADVANCES IN DENTAL MATERIALS AND TECHNIQUES INTO YOUR RESTORATIVE PRACTICE - COURSE: 4130  
1:20 - 2:20 Various Speakers  
OPTIMIZING YOUR PRACTICE WITH 3D CONE-BEAM TECHNOLOGY - COURSE: 4140  
2:40 - 3:40 Daniel McEwen, DDS  
HIGH RESOLUTION CONE BEAM WITH PREXION 3D - COURSE: 4150  
4:00 - 5:00 Maria Ryan, DDS, PhD  
DETECTING CORONARY HEART DISEASE THROUGH PERIODONTITIS AND PERIIMPLANTITIS - COURSE: 4160

**TUESDAY, NOVEMBER 30**  
10:00 - 11:00 Fotinos Panagakos, DMD, PhD  
DENTIN HYPERSENSITIVITY - NEW MANAGEMENT APPROACHES - COURSE: 5110  
11:20 - 12:20 Greg Diamond, DDS  
LASERS IN PERIODONTAL THERAPY - COURSE: 5120  
1:20 - 2:20 Dov Almog, DMD  
INTRODUCTION TO CONE BEAM CT (CBCT), ESPECIALLY AS IT PERTAINS TO PREVENTION OF FAILURES IN ORAL IMPLANTOLOGY - COURSE: 5130  
2:30 - 3:30 Maria Ryan, DDS, PhD  
DETECTING CORONARY HEART THROUGH PERIODONTITIS AND PERIIMPLANTITIS - COURSE: 5140  
4:00 - 5:00 Dwayne Karateew, DDS  
CONTEMPORARY CONCEPTS IN TOOTH REPLACEMENT: PARADIGM SHIFT - COURSE: 5150

**WEDNESDAY, DECEMBER 1**  
10:00 - 11:00 Mr. Al Dube  
BEST MANAGEMENT PRACTICE, WASTE MANAGEMENT FOR THE DENTAL OFFICE, AND OSHA COMPLIANCE - COURSE: 6060  
11:20 - 12:20 Glenn van As, DMD  
HARD AND SOFT TISSUE LASERS - COURSE: 6070  
12:45 - 4:45 Drs. David Hoexter, Jeffrey Hoops, Dwayne Karateew, Enrique Merino, Kenneth Serota, Marius Steigmann  
REVOLUTIONARY IMPLANT DESIGN UNVEILED: A COLLECTION FROM THE MASTERS - COURSE: 6080

FREE ENTRANCE  
EARN 20 C.E. CREDITS  
20h CE

Dental Tribune  
**DT STUDY CLUB**  
COURSES | DISCUSSIONS | TECHNOLOGY | ON DEMAND





# Using resorbable barriers to make root recession coverage predictable

By Drs David L Hoexter, Nikisha Jodhan and Jon B Suzuki

(mCME articles in Dental Tribune (always page 6) has been approved by HAAD as having educational content acceptable for (Category 1) CME credit hours. Term of approval covers issues published within one year from the distribution date (September, 2010). This (Volume/Issue) has been approved by HAAD for 2 CME credit hours.

Gingival recession is defined as the location or displacement of the marginal gingiva apical to the cemento-enamel junction (CEJ).<sup>1</sup> Recession is the exposure of root surface, resulting in a tooth that appears to be of longer length.

From a patient's perspective, recession means an unaesthetic appearance and is associated with aging. The gingiva consists of free and attached gingival tissue, as seen macroscopically.

The free marginal gingiva, located coronal to the attached gingiva (AG), surrounds the tooth and is not attached to the tooth surface. The AG is the keratinised portion of gingival tissue (KG) that is dense, stippled and firmly bound to the underlying periodontium, tooth and bone.

In ideal health, the most coronal portion of the AG is located at the CEJ, where the most apical portion is adjacent to the muco-gingival junction (MGJ). The MGJ represents the junction between the AG (keratinised) and alveolar mucosa (non-keratinised).<sup>2</sup>

## Reasons for recession

There are numerous etiological factors that may result in recession. Generally, the etiology can be categorised as either mechanical or as a function of periodontal disease progression. Recession usually occurs due to tooth malposition<sup>3-5</sup>, alveolar bone recession<sup>6,7</sup>, high muscle attachments and frenal pull<sup>8</sup>, and iatrogenic factors related to restorative and periodontal treatment procedures.<sup>5,9</sup>

The detrimental effects of recession include compromised esthetics, an increase in root sensitivity to temperature and tactile stimuli, and an increase in root caries susceptibility due to cementum exposure. Thus, the main therapeutic goal of recession elimination is gingival root coverage in order to fulfill esthetic demands and prevent root sensitivity.

Miller classifies recession defects into four categories:

- Class I: marginal tissue recession does not extend to the MGJ
- Class II: marginal tissue recession extends to the MGJ, with no loss of interdental bone
- Class III: marginal tissue recession extends to or beyond the MGJ; loss of interdental bone is apical to the CEJ but coronal to the apical extent of the marginal tissue recession
- Class IV: marginal tissue recession extends beyond the MGJ; interdental bone extends apical to the marginal tissue recession.<sup>10</sup>

A possible treatment modality for recession includes restorative/mechanical coverage, such as cervical composite restorations. This kind of treatment may effectively manage root sensitivity and root caries. However, such treatment entails a long-term compromise from an esthetic perspective. Composite restorations stain over time, and any marginal leakage may lead to secondary caries, recurrence of sensitivity and/or local inflammatory changes.

Additionally, colour matching can be difficult and such restorations may involve the undesirable removal of vital tooth structure in

order to create adequate retention form. Thus, clinicians must determine whether the restorative benefits outweigh the esthetic shortcomings and whether it is possible to employ a treatment modality with few, if any, functional and esthetic disadvantages.

## Muco-gingival surgery

Another treatment modality for recession is muco-gingival surgery. Muco-gingival surgery refers to periodontal surgical procedures designed to correct defects in the morphology, position and/or amount and type of gingiva surrounding the teeth.<sup>11</sup>

In the early development of muco-gingival surgery, clinicians believed that there was a specific minimum apical-coronal dimension of AG that was necessary to maintain periodontal health.

However, subsequent clinical<sup>12-15</sup> and experimental studies<sup>16, 17</sup> have demonstrated that there is no minimum numerical value necessary.

However, for esthetics, a uniform colour and value of AG is desirable among adjacent teeth.<sup>18</sup> Some of the earliest techniques for correcting recession involved extension of the vesti-

bule.<sup>19</sup> The subsequent healing usually resulted in an increase of AG. However, within six months, as much as a 50 per cent relapse

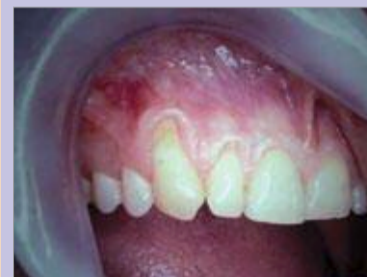

Fig. 1: Pre-op labial view of anterior teeth: recession on tooth #6; tooth #7 surrounded by a small adequate zone of keratinised apical tissue.

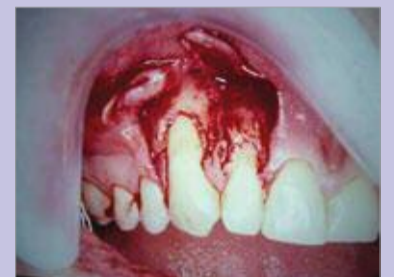

Fig. 2: Flaps reflected preserve the interproximal tissue, which preserves the blood supply and prevents black triangles (unesthetic interproximal spaces).

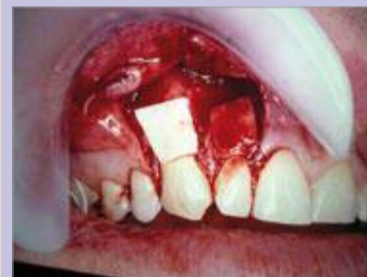

Fig. 3: The GTR membrane was shaped and placed over the root surfaces of teeth #6 and #7.

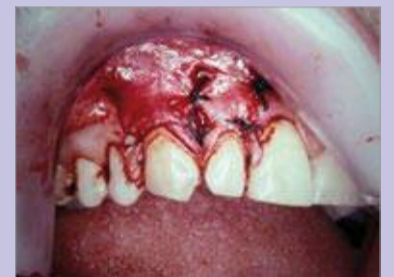

Fig. 4: Gingival tissue was coronally repositioned, covering the membranes and the roots of teeth #6 and #7, and sutured in place.

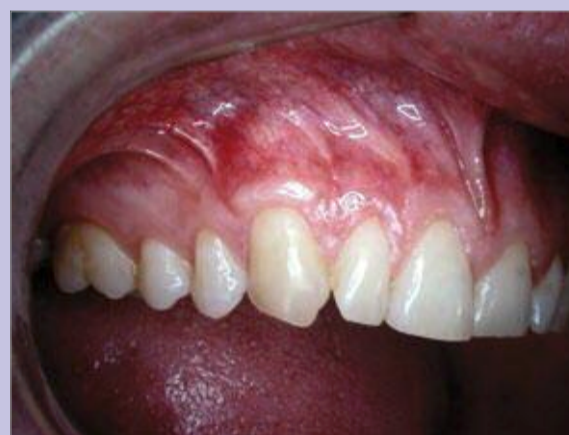

Fig. 5: Post-op view: the previously recessed roots of teeth #6 and #7 are covered with attached pink, keratinized gingival tissue, with no pocket depth upon probing.

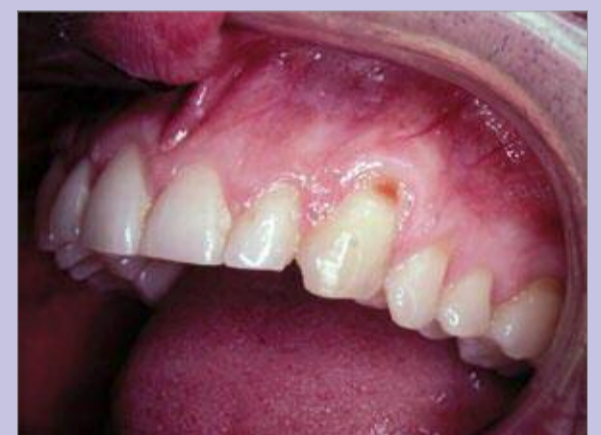

Fig. 6: Pre-op labial view of anterior teeth, with no pocket depth upon probing.

## MEDIA CME Self-Instruction Program

Dental Tribune Middle East & Africa in collaboration with CAPP introduce to the market the new project mCME - Self Instruction Program. mCME gives you the opportunity to have a quick and easy way to meet your continuing education needs.

mCME offers you the flexibility to work at your own pace through the material from any location at any time. The content is international, drawn from the upper echelon of dental medicine, but also presents a regional outlook in terms of perspective and subject matter.

### How can professionals enroll?

They can either sign up for a one-year (10 exercises) by subscription for the magazine for one year (\$65) or pay (\$20) per article. After the payment, participants will receive their mem-

bership number and will be able to attend to the program.

### How to earn CME credits?

Once the reader attends the distance-learning program, he/she can earn credits in three easy steps:

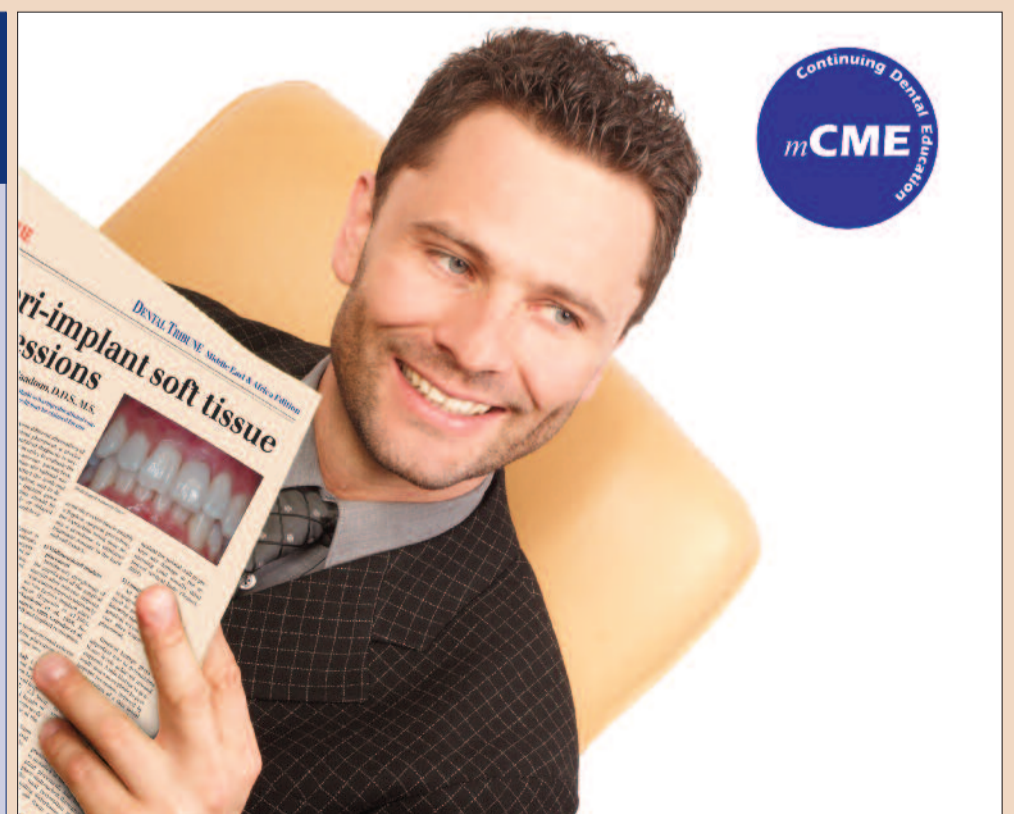1. Read the articles.
2. Take the exercises
3. Fill in the Questionnaire and Submit the answers by Fax (+971 4 3686885) or

Email : [info@cappmea.com](mailto:info@cappmea.com)

After submission of the answers, (name and membership number must be included for processing) they will receive the Certificate with unique ID Number within 48 to 72 hours.

Articles and Questionnaires will be available in the website after the publication.

[www.cappmea.com](http://www.cappmea.com)





of the soft tissue position was reported.<sup>20, 21</sup> Thus, these techniques did not adequately address recession.

In order to improve esthetics and increase KG for root coverage procedures, current periodontal surgery largely involves the use of gingival grafts. There are a multitude of surgical techniques, which can be distinguished based on the relationship between the donor and recipient sites.

Gingival graft procedures involve either (a) pedicle soft-tissue grafts, which maintain the pedicle blood supply or (b) free autogenous soft tissue grafts. Techniques involving the latter type require the clinician to prepare two surgical sites: one to harvest the tissue and another one to prepare the recipient site.

In this case, the autogenous soft tissue graft has a separate blood supply to the recipient site. Combinations of (a) and (b) have also been reported.<sup>22-24</sup>

#### Soft-tissue grafts

The pedicle soft-tissue graft was first described by Grupe and Warren in 1956.<sup>25</sup> This involved raising a full thickness flap and laterally positioning and then suturing donor tissue into place from an adjacent area while maintaining a pedicle blood supply. This technique and others that followed were designed to increase the zone of AG.

*'The goal is to restore gingival health, colour and esthetics by covering the exposed root predictably with healthy gingival tissue and, in doing so, decrease sensitivity'*

Later modifications of the technique included the double papilla flap<sup>26</sup> – introduced by Cohen and Ross in 1968 – the oblique rotational flap<sup>27</sup> and the rotational flap.<sup>28</sup> Another type of gingival movement flap was described later as the coronally repositioned flap.<sup>29</sup> This technique involves mobilising a full thickness flap and repositioning the tissue to the CEJ, thereby covering the exposed recession.

The use of free gingival grafts was described in the 1960s by Sullivan and Atkins.<sup>30</sup> The free autogenous graft can be made up of either epithelialised gingiva or connective tissue. Initially, the therapeutic goal was to increase the zone of KG. The clinical objective has now evolved to covering the recessed root with a zone of attached KG.

This can be achieved in one or two stages. Initially, Sullivan and

Atkins described a one-stage procedure in 1968. Its purpose was to increase the zone of KG without concentrating on coverage of a recessed root. In the 1980s, a two-stage modification was suggested for an increase in root coverage, which proved to be more successful with increased predictability. This involves first placing the free gingival graft or the free connective tissue graft apical to the area of recession and using the coronally repositioned technique after healing.

#### Autogenous grafts

Free autogenous grafts are predominantly harvested from the palate. Recently, materials other than gingival grafts have been explored. Using a guided tissue regeneration (GTR) technique, an acellular dermal matrix has been reported to yield favorable outcomes in root coverage.<sup>31,32</sup> This material may provide the patient with a less invasive alternative than a palatal donor site in order to achieve root coverage.

Procedures combining both free grafts and pedicle techniques have also been detailed. For instance, when a connective tissue graft is employed, the graft is placed sub-epithelially with a coronal advancement of the overlying keratinised tissue. GTR techniques have also been developed more recently. In 1992, Pino Prato et al. described a combination technique of sub-epithelial placement of a membrane with coronal advancement of the flap, such as e-PTFE.<sup>33</sup>

The function of the membrane is to maintain space during the healing period for tissue regeneration to occur. From a patient's perspective, biodegradable membranes with GTR might be preferable in order to avoid a second-stage surgery for membrane removal.

The goal is to restore gingival health, colour and esthetics by covering the exposed root predictably with healthy gingival tissue and, in doing so, decrease sensitivity. Using GTR and coronal repositioning techniques, we achieve predictably covered roots.

#### Other procedures

Variations in muco-gingival procedures have been developed to include root surface bio-modifications by treating the root surfaces with a variety of materials. These measures enhance the regeneration proc-

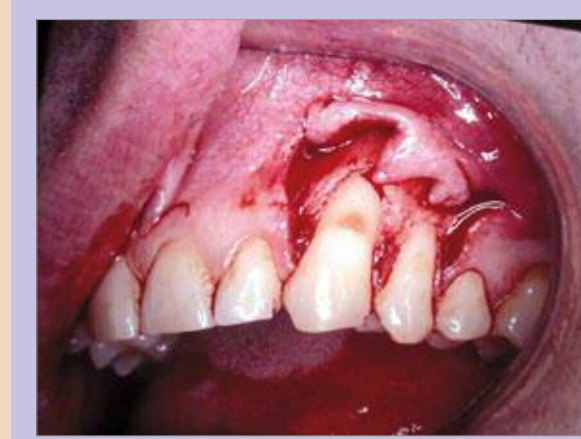

Fig. 7: Cervical groove on tooth #11 is solid, hard and non-carious.

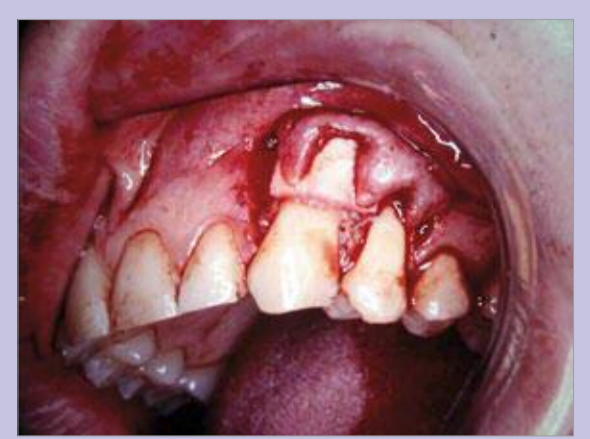

Fig. 8: GTR membrane placed over the root surface of tooth #11 only; no membrane was placed on the surface of the recession of tooth #12.

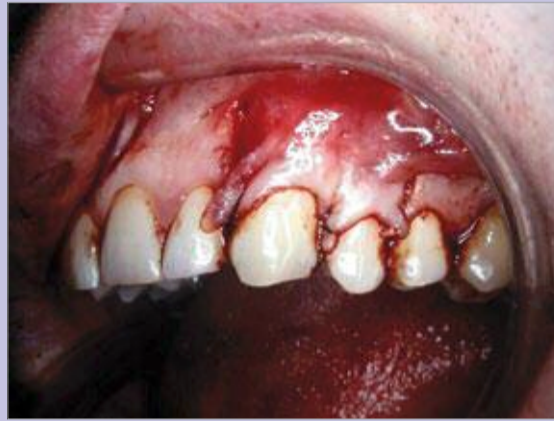

Fig. 9: Gingival tissue coronally repositioned to cover the GTR membrane on tooth #11 and tooth #12.

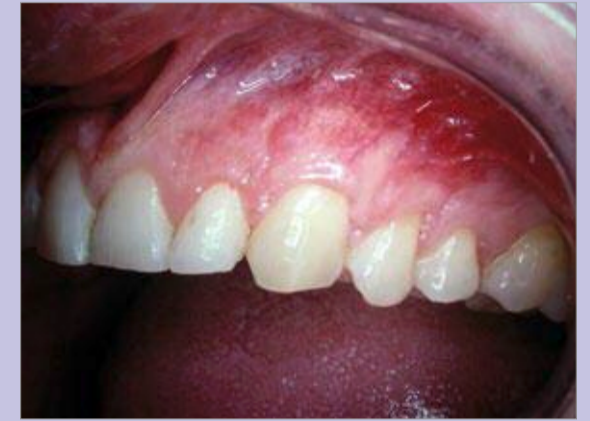

Fig. 10: Post-op view.

ess of a new connective tissue attachment. In order to increase root coverage, a new clinical attachment is necessary.

Root surface bio-modification involves treating the root surfaces with citric acid, tetracycline or EDTA in order to remove the smear layer and expose dentinal tubules and thus facilitate a new fibrous attachment. An enamel matrix derivative claimed to support the action of enamel matrix proteins by inducing acellular cementum, periodontal ligament and alveolar bone formation is also available in the range of root surface bio-modification materials.

The following case report considers predictable esthetic root coverage by comparing a GTR technique to a non-GTR technique in a split-mouth procedure involving the same patient.

#### Case report

A young, adult male patient presented with recession bilaterally in his maxilla. The upper right maxilla had extensive recession on teeth #6 and #7 (Fig 1). The upper left maxilla had similar recession on teeth #11 and #12. Additionally, tooth #11 had a cervical groove, which was stained and hard but not decalcified.

After local anesthesia using lidocaine, the desired flap design was completed. There was an adequate zone of KG present before treatment, which was preserved and repositioned coronally. Upon reflection of the tissue, the full extent of the underlying recession was evident (Fig 2). The area and recession were uncovered following re-

moval of debridement and granulosomatous tissue.

The resorbable membrane material was shaped and placed on the exposed roots. The membrane was first placed on tooth #6 and thus the tooth appeared darker as it absorbed blood. The membrane was placed on tooth #5 second and thus the tooth had not absorbed the blood at the time of the photograph, which accounts for the colour difference at this time.

The coronally repositioned flap was sutured in place with the flap covering the now submerged membranes and previous recession (Figs 3,4). Periodontal dressing (Coe-Pak, GC) was utilised as a bandage and placed over the surgical area. It was removed a week later at the same time as the sutures. The patient then lavaged and returned to the usual oral hygiene routine, initially lightly and gradually more vigorously.

Once healed and oral health was maintained, the recession was covered and health regenerated. Upon periodontal probing, no pockets were present (Fig 5). The final view presents a visual symmetry of health and colour that is maintainable.

Recession was also present at the maxillary left side (teeth #11 and #12; Fig 6). After local anesthesia of the areas involved, a full thickness muco-periosteal flap was completed. This exposed the extent of the recession defects (Fig 7). Tooth #11 was treated, as was the other side of the mouth, by utilising the GTR technique using an acellular connective tissue membrane to preserve the space for regeneration.

Tooth #12 was treated the same way, except that no membrane barrier, resorbable or non-resorbable, was used (Figs 8,9). Thus, there was no use of a GTR technique on tooth #12. Both teeth had the flap manipulated with the coronally repositioned graft, covering the recessed root and suturing to the CEJ level.

Both sides were covered with periodontal dressing. Antibiotics (tetracycline) and an analgesic (Tylenol-Codeine) were prescribed for the first week after the operation.

One week after the surgical phase, the dressing and sutures were removed and the mouth lavaged. Oral Hygiene was restored to good, maintainable habits following the healing phase of over two months. Upon observation, tooth #11, for which the GTR membrane had been employed, had reattached healthy gingiva that was not probable.

The recessed root and the stained cervical groove were covered. In contrast, tooth #12, for which no GTR membrane had been utilised, displayed recession as prior to the surgery (Fig 10).

In summary, this split-mouth technique demonstrated that using an acellular resorbable barrier membrane is more predictable for achieving root recession coverage than coverage of a recessed root without such a membrane. [D](#)

A complete list of references is available from Dr Hoexter.

#### About the author



Dr David L Hoexter, 654 Madison Avenue, New York, NY. To get in touch, you can call him on +1 212 555 0004 or email drdavidlh@aol.com.



# Dental Care or Beauty Treatment?

Denplan's Roger Matthews speaks to Prof Richard Ibbetson on the subject of ethics

The aesthetics of dental restorations have always been important and over the last few years there has been a big increase in both the demand for, and the supply of cosmetic dentistry. There are ultimately three factors responsible for this – the media, patients and dentists themselves.

However, the fact of the matter is that some modern cosmetic treatments may give little or no thought to the future of the patient or what will happen to them down the line. With treatments such as veneers and implants on the rise, dentists should be asking themselves, 'what is best for

the patient?' not 'what does the patient want right now?'

Denplan's Chief Dental Officer, Roger Matthews, interviews Professor Richard Ibbetson to discuss the ethical implications of 'selling' cosmetic dentistry and how much dentists should allow

themselves to be influenced by the desires of their patients.

**In your opinion, what is the dentist's ethical obligation to their patient when it comes to cosmetic treatments?**

"Dental care is about keeping people pain-free and healthy,

while trying to satisfy their cosmetic concerns. However, with magazines full of adverts for cosmetic dentistry and more people aspiring to celebrity ideals, aggressive dental treatments for aesthetic reasons alone are on the rise to a worrying degree.

"In my view, any dental treatment undertaken should always be:

- Safe
- Conservative
- Predictable
- Patient directed
- Dentist monitored

"Many patients will come into a surgery convinced of the treatment they want. It is the dentist's job to ensure the decision is not rushed, that less invasive routes are explored and that the risks are discussed in full. We are taught as business owners that the customer is always right, but when measuring the aesthetic outcomes of various treatments, what the customer perceives can be subjective. In fact, many patients will be open to trying less aggressive procedures first, when they are fully appraised of the potential downside of their initial preference."

**It has been a rising trend for many years now that amalgam fillings are being replaced with the more aesthetically pleasing composite fillings. Is this a problem?**

"In many cases dentists use composite as a matter of course, without ever giving patients the choice. There are some situations where composite is the best material for restoring a posterior tooth as it can be more conservative of tooth tissue. However, dentists know that direct composite fillings, particularly large ones, are more difficult to perform and have a significantly shorter life-span.

"As oral healthcare professionals, obliged by codes of practice, we should therefore always talk through potential risks with patients in order for them to make an informed decision. In the same way that dentists will often choose amalgam fillings for their own treatment, in practice I have found that patients are far more open to amalgam, when they understand that composite fillings are not without their disadvantages."

**What impact has celebrity culture had on the profession?**

"Celebrities such as Britney Spears and Simon Cowell have a lot to answer for when it comes to dental treatment! Their "too-perfect" teeth have all too often brought peo-

AD



## FIBERCONE™



Translucent quartz fiber



### THE ACCESSORY POST

You were dreaming of





## AL Rais Medical & Dental Trading FZE

P.O Box: 183775 , Dubai, Tel : +97 150 4325515  
Email : armdt@rakfzbc.ae



ple into the dental surgery with unrealistic goals, which subsequently can pose a moral issue for the treating dentist.

“The risks involved in porcelain veneers are significant, but this fact is often lost on people who are continually bombarded with images of ‘perfect’ teeth in the media. Although fracture or loss of cementation of a veneer is rare, deterioration in appearance particularly due to marginal discoloration is more common and constitutes a failure. Therefore, it is our responsibility to inform patients of the risks and benefits of veneers before they willingly agree to the removal of healthy tooth structure.

“Interestingly, an increasing number of people opt for veneers simply to make their teeth whiter. For a dentist to agree to this method of treatment solely for this reason is unethical, as more often than not, the results look unnatural, over the top and simply odd. In many cases, bleaching teeth can achieve much of the desired result without the loss of healthy tooth structure. It is one of the least harmful procedures and many patients who were considering aggressive treatments such as veneers are often completely happy with the results of whitening alone.”

“This illustrates why dentists should always explore a range of options with the patient (including no treatment), before agreeing to a more complex approach. Investigating other avenues allows the patient to make an informed decision and the dentist to convey the benefits and risks of each procedure, while protecting professional ethics. Remember, just because a patient says they want something, does not mean that a dentist must do it.”

**Another trend to appear in recent years is that of ‘instant orthodontics’. How do you think this will affect younger patients?**

“More and more patients, young adults in particular, are coming to dentists for treatments such as implants and veneers to avoid the traditional ‘train-track’ orthodontic route. This, however, is simply bad dentistry. To destroy good teeth for a quick aesthetic result is not only unethical but will subject the young patient to a lifetime

**Prof Richard Ibbetson**



**Richard Ibbetson** – Director, Edinburgh Postgraduate Dental Institute and Honorary Consultant in Restorative Dentistry, Lothian Primary Care NHS Trust. Richard graduated from Guy’s Hospital in 1974 and completed an MSc at the Eastman Dental Institute in 1979. He worked at the Eastman for 20 years before taking up the post of Director of Postgraduate Dental Institute in Edinburgh. His main clinical interests centre on the postgraduate teaching and practice of Fixed Prosthodontics.

of repeat treatments and recurring problems. “

“As a profession we should be ensuring that teeth outlast people, not the other way round. The first principle is to preserve the patient’s tooth structure wherever possible. The life of the tooth is far more important than the life of the crown or veneer. Treatments such as all ceramic crowns and aggressive preparations for veneers may mean the extensive removal of tooth tissue. In the event

of a restoration failure or future problems, there can be little tooth structure left to work with.

“As healthcare professionals we should be continually working under a system of compliance, education and communication. All dental treatments are temporary: deterioration and failure are inevitable. Dentists should reflect on modern trends and decide whether the demands of their patients outweigh their moral obligations. As such, it should be a matter of

professional pride to decline treatments if they are felt to be unnecessary or unethical. If we fail to do this it is only a matter of time before we are truly a lost profession.”

**Final thoughts**

I didn’t know it at the time, but back in the Seventies I became an enthusiast for minimally invasive dentistry. Back then, the idea of keeping as much tooth structure intact seemed much more appealing than gambling on the success of full dentures

and this is still true when looking at the costs of implants today.

It is clear that both Richard and I are keen supporters of prevention where possible and high-quality preservation when appropriate. To act otherwise is a breach of our professional ethics: and this should apply whether the impetus for treatment originates with the dentist’s diagnosis or the patient’s aspirations. Both are legitimate, and both need the same care in evaluating.

AD



www.gidedental.com

**2011**  
**gIDE/UCLA**  
**1 YEAR MASTER PROGRAM**  
**IN ESTHETIC DENTISTRY**

**EXPERT FACULTY**

DIDIER DIETSCHI, STEFAN PAUL  
SASCHA JOVANOVIC, BERNARD  
TOUATI, MAURO FRADEANI,  
ED MCLAREN, PASCAL & MICHEL  
MAGNE, BRIAN LESAGE  
AND OTHERS...



**For Registration & More Info:**

**Contact Person in Athens:**  
Lito Christophilopoulou  
Tel: +30 210 213 2084, +30 210 222 2637  
E-mail: lito@omnipress.gr

**Contact Person in London:**  
Nena Puga  
Tel.: +1 310 696 9025  
E-mail: nena@gidedental.com  
website: www.gidedental.com

**ESTHETIC CURRICULUM**

Master Program Chair: Dr. Ed McLaren & Dr. Sascha Jovanovic  
Session Chairs: Drs. Didier Dietschi, Mauro Fradeani, Stefan Paul & Bernard Touati

**SESSION I - FEBRUARY 25 - 28, 2011**  
**IN ATHENS, GREECE**

**DIRECT RESTORATIONS AND ADHESIVES**  
with DR. DIDIER DIETSCHI and others

**SESSION II - JUNE 24 - 27, 2011**  
**IN ATHENS, GREECE**

**INDIRECT RESTORATIONS, FULL CERAMIC CROWNS AND VENEERS**  
with DR. MAURO FRADEANI and others

**SESSION III - OCTOBER 7 - 10, 2011**  
**IN ATHENS, GREECE**

**ALL CERAMIC RESTORATIONS AND FIXED PROSTHODONTICS**  
with DR. STEFAN PAUL, DR. BERNARD TOUATI and others

**SESSION IV - NOVEMBER 28 - DECEMBER 2, 2011**  
**IN LOS ANGELES, CALIFORNIA**

**GRADUATING WEEK AT UCLA**  
with DRs. ED MCLAREN, SASCHA JOVANOVIC, BRIAN LESAGE  
TODD SCHOENBAUM, PASCAL & MICHEL MAGNE

**PROGRAM FEATURES**

- CLASSROOM EDUCATION
- LIVE PATIENT TREATMENTS
- CASE PRESENTATIONS
- HANDS-ON
- 90 HOURS SELF-STUDY
- 217 HOURS CE
- 2 CERTIFICATES from gIDE and UCLA