

DENTAL TRIBUNE

The World's Dental Newspaper · U.S. Edition

OCT. 27–NOV. 2, 2008

www.dental-tribune.com

VOL. 3, No. 38

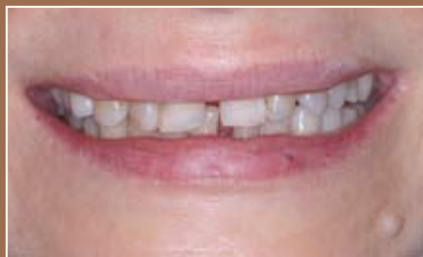Inside this week

Going to the Greater New York Dental Meeting?

If you are, you won't want to miss our "Getting started ..." Symposia, which are free for all attendees. If you've thought about getting started in endo, implants, cosmetic dentistry or digital dentistry then please join us!

Page 7

Cosmetic Tribune: gingival health



As dentists, we can directly affect the esthetics of the teeth and gingiva. However, we can also indirectly affect the lips and face by how we design teeth to sit in the oral cavity.

Page 9

Hygiene Tribune: smoking cessation, part 2

About 30 percent of patients in any given practice are current smokers. Although 70 percent of smokers say they are "interested" in quitting, only 10 percent to 20 percent plan to quit in the next month.

Page 13

Are you a 'cutting edge dentist'?

By Robin Goodman
Group Editor

Dr. Martha Cortes, current president of the American Academy of Cosmetic Dentistry New York Chapter and former co-chair of dentistry with the American Society for Laser Medicine and Surgery, took some time to talk about lasers with Dental Tribune.

What is the state of lasers in dentistry today?

Dental lasers are state-of-the-art technologies. Every dentist should own one and use it as an integral part of his or her practice, especially as they are much more affordable than they were 15 years ago when I got my first laser; I had the the Duopulse by Excel Quantronix, which has two separate lasers in one unit: a holmium and neodymium laser. I still have this unit in my office and use

it as a backup laser to my newer ones. Lasers can be used by themselves or as an adjunct tool as they are versatile and precise. A simple diode laser can be used to disinfect tooth structure, in crown lengthening, frenectomy, biopsy, periodontal disease and gingival sculpting, etc.

There are lasers like the Perio-lase MVP-7, which are specifically built around a patented soft-tissue technique for periodontitis — laser assisted new attachment procedure [LANAP]. There are hard-tissue (modifies lasers) as well as soft-tissue (modifies lasers) and there are lasers available today that combine both a soft and hard tissue laser in one unit. It all depends on the practice one has, or the one that you want to develop. Bottom line is that you cannot consider yourself a dentist on the cutting edge if you do not have and use a laser as part of your daily regimen regardless of what

type of dentistry you practice.

How about lasers and soft tissue such as gum and pulp?

I have developed a direct pulp capping technique involving a laser and the immediate placement of a porcelain restoration [CEREC]¹, which has a great success rate as the laser can reach places that antiseptics and antimicrobials cannot reach because of their shallow penetration into bacterial colonies [biofilms]. Lasers can be used on the delicate tissue of the pulp without causing necrosis by using the correct settings and the right lasers.

Nd:YAG's and diodes are great for sculpting the gingival tissue in crown lengthening, smile makeovers and gingivectomy. Both can be used in treating gum disease, although the diode is not as ideal as the Nd:YAG laser, as it is hotter, can cut deeper and has a potential greater zone of thermal damage in the wrong hands; it should not be used on pockets deeper than 4 mm. The Nd:YAG can

See ARE YOU, Page 2

The critical missing element to complete care: where dentistry and orofacial myofunctional therapy meet (Part 1 of 2)

By Joy L. Moeller, RDH, BS, COM

I. Problems that can be addressed

- Does your patient complain about chronic headaches?
- Does your patient have an open-mouth rest posture?
- Have your patient's teeth moved after orthodontic treatment?
- Does your patient exhibit an open bite?

- Does your patient complain of temporal mandibular joint dysfunction (TMD) or neck pain?
- Is the patient's tongue always "in the way" when you are drilling, scaling or examining the teeth?
- Does your patient exhibit a scalloped tongue from pressing against the teeth?
- Have you noticed oral habits such as thumb or finger sucking, nail biting, lip licking or hair twirling or chewing?
- Does your patient lisp when saying the "s" sounds?
- Do you see the tongue come forward against the teeth when swallowing?
- Is your patient a mouth breather

contributing to anterior gingivitis or open-mouth rest posture?

- Does your patient grind or clench his/her teeth?
- Does your patient have chronic stomachaches, burping, drooling, hiccups or acid reflex?
- Does your patient have a forward head posture?
- Does your patient have a short lingual frenum or a tight labial frenum?
- When you check for oral cancer on the sides of the tongue, have you found lesions from tongue thrusting causing chronic irritation?

These are all signs and symptoms of an orofacial muscle asymmetry that can be addressed by an orofacial myofunctional therapist.

History of orofacial myofunctional therapy (OMT)

OMT is an area of specialization
See COMPLETE CARE, Page 2

AD

CURE 4MM IN 10 SEC.

Fast, Easy, Durable

X-tra fil

Posterior Multi-Hybrid Composite

- Low shrinkage of 1.7%
- 86% filled for great wear resistance
- Highly radiopaque (330 Al%)

... the perfect amalgam alternative.

More info and FREE SAMPLE at www.vocoamerica.com

VOCO
creative in research

Call toll-free 1-888-658-2584

PRSR STD
U.S. Postage
PAID
Permit # 506
Mechanicsburg, PA

Are you

From Page 1

be used to pocket depths above 12 mm. Those interested in the Nd:YAG for gum disease should really look at the Periolase MVP-7 by Millennium Dental Technologies as the laser is sold with instruction/training in the laser and LANAP technique.

And for lasers and hard tissue such as tooth and bone?

Erbium lasers are great for disinfection of teeth and for osseous surgery as they are specifically made for disinfecting and cutting hard tissue. They are also ideal for preparing class I and class V restorations and removal of defective composite materials; however, they cannot be used on metal or porcelains, as these cannot be cut by a laser.

Metals and porcelains must first be removed using the drill; however, once they are removed the laser can be used directly to remove any underlying caries. If the caries are

very deep, the erbium laser can be used in a direct/indirect pulp-capping technique with the immediate placement of a CEREC 3-D porcelain restoration. An erbium laser like the Waterlase MD by Biolase can also be used in the direct treatment of root canals as it has laser endodontic tips that are used post instrumentation for cleaning and disinfecting the canal.

What are your thoughts on a connection between heart disease and periodontal disease?

I love it when patients tell me that they are fit and in good shape except, of course, for the severe gum disease they have. Unfortunately, we have grown up with faulty medical/dental health models that describe the body as distinct and disconnected units, and this shows up in how we view disease and the body. Severe infection in the body is dangerous as it can spread, especially to vulnerable organs.

Periodontitis is a bi-directional manifestation of disease. It can be

seen as a manifestation of systemic disease such as diabetes, cutaneous disease, joint disease and osteoporosis. It can also be seen separately from systemic ones as its own complete disease with the great potential of releasing bacterial emboli into the blood system that can travel to the heart, lungs and other major organs. It has been linked to cardiovascular disease since the late 1990s and rightly so, as oral bacteria are not contained but spread and are particularly dangerous for heart patients who are vulnerable to endocarditis, especially before open-heart surgery.

An Nd:YAG laser can reduce microbial colonies that inhabit periodontal pockets by 97 to 100 percent, as the laser is precise, site specific and does not rely on secondary or tertiary effects to kill microbes. It destroys microbes and their colonies on contact without any side effects.

Editor's Note: Please see Cosmetic Tribune in this edition for a clinical article by Dr. Cortes and her contact information.

DENTAL TRIBUNE

The World's Dental Newspaper - US Edition

Publisher

Torsten Oemus
t.oemus@dtamerica.com

President

Eric Seid
e.seid@dtamerica.com

Group Editor

Robin Goodman
r.goodman@dtamerica.com

Editor in Chief Dental Tribune

Dr. David L. Hoexter
d.hoexter@dtamerica.com

Managing Editor Endo Tribune

Fred Michmershuizen
f.michmershuizen@dtamerica.com

Managing Editor Implant Tribune

Sierra Rendon
s.rendon@dtamerica.com

Managing Editor Ortho Tribune

Kristine Colker
k.colker@dtamerica.com

Product & Account Manager

Mark Eisen
m.eisen@dtamerica.com

Product & Account Manager

Kimberly Price
k.price@dtamerica.com

Marketing Manager

Anna Wlodarczyk
a.wlodarczyk@dtamerica.com

Sales & Marketing Assistant

Lorrie Young
l.young@dtamerica.com

C.E. Manager

Julia E. Wehkamp
E-mail: j.wehkamp@dtamerica.com

Art Director

Yodit Tesfaye Walker
y.tesfaye@dtamerica.com

Dental Tribune America, LLC
215 West 35th Street, Suite 801
New York, NY 10001
Tel.: (212) 244-7181
Fax: (212) 244-7185



Published by Dental Tribune America
© 2008, Dental Tribune America, LLC.
All rights reserved.

Dental Tribune strives to maintain utmost accuracy in its news and clinical reports. If you find a factual error or content that requires clarification, please contact Group Editor Robin Goodman, r.goodman@dtamerica.com. Dental Tribune cannot assume responsibility for the validity of product claims, or for typographical errors. The publishers also do not assume responsibility for product names, or statements made by advertisers. Opinions expressed by authors are their own and may not reflect those of Dental Tribune America.

Editorial Board

Dr. Joel Berg
Dr. L. Stephen Buchanan
Dr. Arnaldo Castellucci
Dr. Gordon Christensen
Dr. Rella Christensen
Dr. William Dickerson
Hugh Doherty
Dr. James Doundoulakis
Dr. David Garber
Dr. Fay Goldstep
Dr. Howard Glazer
Dr. Harold Heymann
Dr. Karl Leinfelder
Dr. Roger Levin
Dr. Carl E. Misch
Dr. Dan Nathanson
Dr. Chester Redhead
Dr. Irwin Smigel
Dr. Jon Suzuki
Dr. Dennis Tartakow
Dr. Dan Ward

Complete care

From Page 1

arising out of orthodontics. The field of OMT is unique because the therapist helps the patient to make major life-enhancing changes, which affect the entire body.

Many dentists during the 1800s and early 1900s recognized that tongue rest posture, mouth breathing and oral habits influenced occlusion. Edward H. Angle — justly termed by some as the grandfather of orthodontics — wrote “Malocclusion of the Teeth,” appearing in Dental Cosmos in 1907, in which he recognized the influence of the facial muscles on dental occlusion. In his research, he concluded that mouth breathing was the chief etiological factor in malocclusion.

The first program of OMT began in 1918 with an article written by an orthodontist, Dr. Alfred P. Rogers,

titled “Living Orthodontic Appliances.” He was one of the first doctors in the United States who suggested that corrective exercises would develop tonicity and proper muscle function and thereby influence proper occlusion.

In the 1970s and '80s there were two different organizations representing therapists. Daniel Garliner and Dr. Roy Langer founded the Myofunctional Therapy Association, and Dr. Marvin Hanson, Richard Barrett, William Zickefoose, and Galen Peachey founded the International Association of Orofacial Myology (IAOM). Currently the IAOM is the main professional organization in the world promoting and developing orofacial myofunctional therapy.

The team approach

Today the field is expanding to include many professions. Through a team approach, the patient can experience the best of all worlds and achieve remarkable results. The

interdisciplinary approach to patient wellness includes but is not limited to:

- ▶ orthodontics
- ▶ general dentistry
- ▶ speech-language pathology
- ▶ dental hygiene
- ▶ periodontics
- ▶ oral surgery
- ▶ ear, nose and throat specialty
- ▶ cranial osteopathy
- ▶ allergology
- ▶ pediatric dentistry
- ▶ pediatrics
- ▶ physical therapy
- ▶ chiropractics
- ▶ gastroenterology
- ▶ plastic surgery

Failure to help many patients

Through 30 years of practicing orofacial myofunctional therapy, some questions patients or their parents asked me include:

- ▶ Why didn't someone tell me about this earlier?
- ▶ I knew I had a tongue thrust, I didn't know there was a special person to help me.
- ▶ Why didn't someone tell me my habit of tongue thrusting, thumb sucking or nail biting could be easily eliminated in therapy?
- ▶ I have tried multiple splints, functional appliances, medications and occlusal adjustments for my TMD problem. I was even referred to a psychologist for counseling because they told me it was stress related. Why didn't someone recognize my facial muscle dysfunction and refer me for orofacial muscle therapy sooner?
- ▶ This is the third time my orthognathic surgical result has relapsed. Why hasn't anyone referred me to an orofacial myofunctional therapist?
- ▶ My child was traumatized by wearing a “rake” in his mouth to stop his tongue thrust. His speech has gotten worse and he has with-

AD

The Team Building Event Of The Year



California Cruzin'

Nov. 7 & 8 • San Diego, CA

Join Sally and a fantastic line up of speakers for two days dedicated to **TEAM BONDING, TEAM BUILDING and TEAM BREAKTHROUGHS.**

Achieve **Total Team Success** and be cruizin' to better communication, superior customer service, and peak performance for starters.

Special “breakthrough” workshops...just for the Dental Assistants...just for the Hygienists...just for the Business staff...and just for the Dentist, will enable every member of your team to break through the barriers that are holding each of you back and idling your success. But it doesn't stop there. We'll have awards and prizes at our Saturday evening **CRUZIN' FUN FEST POOL PARTY** for the **BEST BONDED TEAM**, the **BEST TEAM PHOTO**, the **BEST TEAM DANCERS** and the **BEST TEAM SPIRIT!**

For more information visit:
www.mckenziemgmt.com
1.877.777.6151 • info@mckenziemgmt.com



MCKENZIE MANAGEMENT

Providing Success Proven Management Systems for 28 years.

drawn. After the rake was removed, the tongue thrust returned. Why wasn't I given the option of seeing a therapist who specialized in treating this disorder with exercises?

▶ My child wore a palatal expander for a high narrow palate. After the expander was removed, the palate collapsed because the tongue was resting down. Why wasn't I referred to an orofacial myofunctional therapist immediately following the expander being removed?

▶ I was told I was tongue-tied and needed a lingual frenectomy. After surgery, my tongue reattached and scar tissue formed and was worse than before we started! Why wasn't I told to see a therapist immediately following surgery to prevent re-attachment?

Patients can learn to develop healthy muscle patterns. Healthy muscle patterns, when permanently habituated, can be proactive in preventing or treating:

- ▶ orthodontic relapses,
- ▶ articulation disorders,
- ▶ breathing disorders due to allergies or mouth breathing habits,
- ▶ TMD when it is a muscle or habit-related issue,
- ▶ digestive disorders from not chewing properly or swallowing air,
- ▶ postural problems,
- ▶ faster normalization of the facial muscles and neuro-muscular facilitation post orthognathic surgery.

How can orofacial myofunctional therapy help the general dentist?

Orofacial myologists can assist the dentist in many aspects of his or her practice to:

- ▶ Re-educate muscle patterns that promote a stable orthodontic result.
- ▶ Reduce the time spent in fixed appliances.
- ▶ Normalize the inter-dental arch vertical rest posture dimension, the freeway space, also called the oral volume.
- ▶ Identify and eliminate orofacial noxious habits that interfere with stable occlusal results.
- ▶ Teach nasal breathing and remodel the airway through nasal cleansing and behavior modification.
- ▶ Reinforce compliance with wearing rubber bands, functional appliances and retainers.
- ▶ Develop a healthy muscle matrix and eliminate habits that contribute to TMD.
- ▶ Correct head and neck posture problems.
- ▶ Stabilize the periodontal condition by reducing tongue thrusting pressures and mouth breathing habits.

Because most of our patients are in need of orthodontic treatment or treatment by a functional dentist, if the patient was referred by a source outside of dentistry, we are certainly a great potential referral source for dentists.

The best time for the dentist to refer the patient to an orofacial myofunctional therapist is before inter-

vention by appliance therapy. It is always best to do the least invasive treatment first and eliminate habits that are interfering with treatment. This will ensure that the muscles are working with the forces of the appliances. Also, another good time to refer would be before the braces come off, depending on the patient's facial structure and motivation. We can work together to help the motivated patient achieve amazing results.

To elaborate on the importance of the working relationship between OMTs and the dental community, I have reached out to some of my esteemed colleagues for commentary.

According to Dr. John Kishibay, an orthodontist from Santa Monica, See Complete care, Page 4



Fig. 1a Fig. 1b Fig. 1c
Figs. 1a-c: Before therapy. Patient presented with a lateral tongue thrust, mouth breathing, stomach sleeping, orthodontic relapse, difficulty chewing and swallowing, and forward head posture.

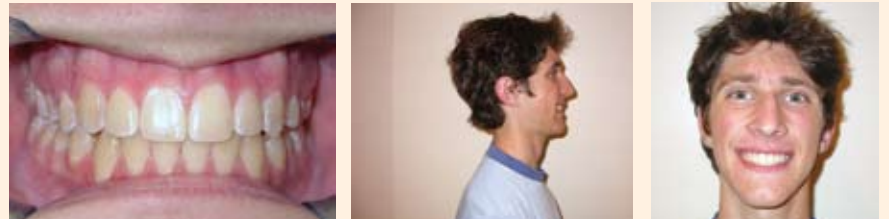


Fig. 1d Fig. 1e Fig. 1f
Figs. 1d-f: After 14 months of myofunctional therapy.

AD

GOLDEN MISCH
physics
forceps

simple • predictable • more efficient

DENTISTRY TODAY
TOP 100
PRODUCTS 2007
★★★★★

DENTISTRY TODAY
TOP 100
PRODUCTS 2008
★★★★★

Take advantage of our
90 day trial period

Visit us at the
Greater New York Dental
Meeting Booth # 3431 for a
Free DVD and convention
special offers.

*ORDERS NOW BEING ACCEPTED FOR
OUR NEW 3rd MOLAR INSTRUMENTS.

learn more about the physics forceps at
GOLDENMISCH.COM
1 877 987 2284

ADVANCEMENTS IN DENTISTRY

**Supporting Comments for the
New Extraction Forceps**



Anthony S. Feck, DMD

I have never looked forward to doing extractions in my practice. It can take just a few minutes or more than half an hour if I hear that dreaded 'cracking' sound indicating I have broken a crown or a root. Since using the Physics Forceps that sound is a thing of the past. These new forceps don't rely on brute force, but rather, use the simple concept of leverage. Instead of grasping, pushing, twisting and pulling the clinical crown, this technique employs a slow, steady rotational force that literally rolls the tooth free from the PDL. Seldom do new innovations come along that truly revolutionize the way a dentist approaches a service – this is one!



Louis Malcmacher, DDS, MAGD

Faster, easier and better - these are the three magic attributes that I look for whenever I evaluate new products. The GoldenMisch Physics Forceps are by far one of the greatest advancements I have seen in exodontia in my 28 year career. Using these unique instruments greatly reduces buccal bone loss during the extraction, making implant support and esthetic success much more predictable. The amount of time, effort and frustration saved is incredible, especially with challenging teeth. The Physics Forceps are an absolute must for every dental practice and I highly recommend them in my lectures.

Complete care

From Page 3

Calif., who is a professor at USC School of Dentistry: “Orofacial myofunctional therapy must be part of the treatment plan from the beginning. This way the patient understands from day one that the muscle adaptation is important for long-term stability. Especially important would be the orthognathic patient. The patient must learn to use the new space in an ergonomic manner, in both a functional patterning and habit elimination awareness.”

Dr. William Hang, an orthodontist practicing in Westlake Village, Calif., believes that OMT problems are one cause of poor facial development. He says: “Stability will continue to be

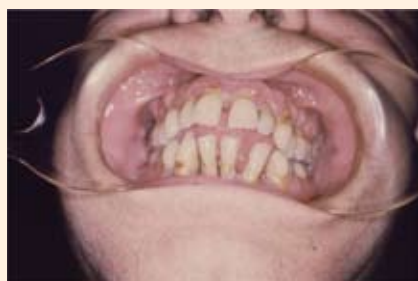

Fig. 2: Periodontal disease or orofacial myofunctional disorder?

an elusive, unachievable goal with poor facial balance frequently being the norm of the post orthodontic result. Myofunctional therapy must become the first line of defense in the quest for proper facial development rather than the rescue squad when the orthodontic result is going up in flames. When orthodontists

embrace myofunctional therapy, they stop treating symptoms and begin to focus on treating the cause of poor facial development [altered oral rest posture].”

Dr. Jerry Zimring, a practicing orthodontist for 44 years in Los Angeles, believes that attaining proper occlusion is a state of balance between the teeth, the muscles and the bones. He states, “Both my daughter and my grandson were treated with myofunctional therapy with excellent results that would not have been possible without this valuable treatment. I feel strongly that myofunctional therapy should be part of every orthodontic practice.”

Dr. Richard L. Jacobson, a Diplomate of the American Board of Orthodontics who has been in the exclusive practice of orthodontics

in Pacific Palisades, Calif., for the past 28 years, stated: “We know that form follows function and function can follow form. Therefore, it is vital to identify those patients that need myofunctional therapy. In these patients myofunctional therapy by a specialist is essential. Treatment is effective and orthodontic stability is enhanced.”

The author would like to thank Karen Macedonio, a Certified Life Coach (and patient), Barbara J. Greene, COM, and Licia Coceani-Paskay, MS, CCC-SLP, COM for their assistance with writing this article. A complete list of references is available from the publisher.

To find a therapist near you, go to www.iaom.com and look at the directory.

AD

The Whole Enchilada

With plenty of side dishes available



The whole kit and caboodle. Everything, and all of it. That describes PhotoMed. We've got everything you need for clinical photography. PhotoMed clinical camera systems feature the best digital camera equipment available. The system shown above is Nikon's D300 with the Micro-Nikkor 105mm VR macro lens and Nikon R1 Macro Flash. We complete the system with the new PhotoMed R1 Dual Point Flash Bracket that gives you incredible flash position flexibility. We also feature clinical systems built around Nikon's D60, D80 and D90.

We know that no one likes to spend time reading thick user manuals so your camera is delivered assembled, set and tested along with our concise custom instructions. And we include unlimited phone support and loan equipment if needed.

PhotoMed carries all of the accessories you may need: intraoral mirrors, retractors, Contrasters, printers, clinical photography books/training CDs and recreational lenses (the Nikkor 18-200 AF-S DX VR lens is a nice choice). Visit our website. Give us a call. Come see us at a dental meeting (there's a complete list of upcoming meetings at: www.photomed.net). We know you'll like us.



www.photomed.net • 800.998.7765

Mention the "enchilada ad" when you order for a complimentary side dish!

PhotoMed
INTERNATIONAL

Study OMT!

Joy Moeller will teach a five-day IAOM-approved course on orofacial myofunctional therapy Oct. 19–23 and a seven-day course (which includes two days of internship) on Feb. 11–17 and June 24–30, 2009 in Los Angeles with Barbara J. Greene, COM, and Licia Coceani-Paskay, MS, CCC-SLP, COM. For more information contact Greene at bgreene@tonguethrust.com or call (805) 985-6779.

Contact info



Joy Moeller, BS, RDH, COM, is a certified orofacial myofunctional therapist and a licensed registered dental hygienist. She is in the exclusive private practice of OMT in Pacific Palisades and Beverly Hills, Calif. She is currently an elected member of the Board of Directors of the IAOM and is the hygiene liaison. Joy is also a former associate professor at Indiana University School of Dentistry and an on-going guest lecturer at USC and UCLA to ortho, perio and pedo dental residents, and at Cerritos College to hygiene students.

15340 Albright St., #305
Pacific Palisades, Calif. 90272
Tel.: (310) 454-4044
Fax: (310) 454-0391
E-mail: joyleamoeller@aol.com
Web site: www.myofunctional-therapy.com

What is the key to managing stress?

By Roger P. Levin

What's the leading cause of stress? Is it even possible to pinpoint one cause when so many variables operate in busy dental practices? It's safe to say that every dental office experiences too much stress at one time or other. Some practices accept it as a fact of life, while others want something better. For them, total success includes having a low-stress practice.

Levin Group consultants have observed that stress usually results from a combination of factors. The most common problems are a lack of well-defined business systems, ineffective leadership skills and teams that are not as committed as they should be. All of these issues can be solved. The final result is a low-stress practice, which is the goal of every dentist who has ever gone into practice.

The Levin Group Method for Total Practice Success™ includes five steps doctors can take to have an immediate and positive impact on stress:

- 1) Empower the team
- 2) Hold morning meetings
- 3) Revise the schedule
- 4) Improve communication
- 5) Become a better leader

Empower the team

The doctor's best resource for reducing inefficiency and lowering stress is the dental team. Involve as many team members as possible in examining your systems. Everyone on the team will have valuable insights to contribute. Special staff meetings can be held to review the major systems such as scheduling, case presentation, hygiene, practice financial management and patient finance. Some strategies include:

- ▶ Ask team members to bring a list of 10 possible improvements to the next staff meeting.
- ▶ Organize an off-site, all-day retreat to focus on current issues and strategic planning for the practice. This approach creates an opportunity to bring people together, forge a team spirit and identify problem areas and solutions.
- ▶ Send your office manager to regularly scheduled continuing education courses to gain new perspectives and ideas on dental management.

Task the office manager with the project of creating a written operations manual for every major business system in the practice. These manuals must include a step-by-step analysis of each system so that a person not trained in dentistry can quickly learn how the office operates by following the manuals.

Hold morning meetings

Once the team has been empowered, it is a valuable asset to a daily morning meeting. Conducting morn-

ing meetings before patients arrive is a surefire method of proactively organizing the day and minimizing stress. During these meetings, the doctor and the team must identify times during the day when:

- ▶ Emergencies can be seen
- ▶ Time crunches are likely to occur.
- ▶ New patients will need extra attention from the dentist.
- ▶ Any special situations may affect the day.

Making preparations for what's ahead on a given day will greatly reduce stress in the practice.

Revise the schedule

The backbone of the practice is

the schedule, and it affects nearly every aspect of practice operations. Poorly constructed schedules can have chaotic results — frustrated patients, cancelled appointments, lost production and a stressful work environment for the staff. When this situation is left uncorrected, the practice risks losing good team members, thus creating even more stress for the remaining staff.

Examine how your practice schedule is constructed. For example, are there too many holes in the schedule? That's a sign that appointments are spaced too far apart. This scenario increases stress for the dentist and the team.

Levin Group recommends to its

clients Power Cell Scheduling™, a high-performance scheduling system using 10-minute units to accurately schedule appointments and allow more scheduling flexibility. Fifteen-minute units can result in under- or over-scheduling patients. For example, if a procedure takes 20 minutes, the practice using 15-minute units would have to schedule this as a 15-minute or a 30-minute appointment.

From one day to the next, the schedule's format should be very similar. Mornings should be reserved for longer, higher-revenue procedures that make up most of the day's production goal. Afternoons can then be scheduled with simpler procedures. Within this framework the dentist and dental team are less stressed. This type of schedule keeps

AD

The other no-prep veneer...
Vivaneers™





\$123

per unit
5 days in lab

Vivaneers™ are custom made in the U.S.A. using PrismaTik ThinPress® ceramic. It can be pressed as thin as 0.3 mm and has a flexural strength of 167 MPa (± 16 MPa).

Before



After






This 27-year-old female was unhappy with the spaces between her teeth. Cases with multiple diastema lend themselves to no-prep cases. In the after pictures, you can see the improvement in shape and size of the teeth. In addition, when viewed from the occlusal, you can see that no-prep veneers do not necessarily have to be bulky in the facial aspect.

Clinical dentistry by Michael DiTolla, DDS, FAGD.
Ceramics by Glidewell Laboratories.

Award-winning veneers
four years in a row



dental
townie
choice
awards 2007

Voted best service/lab for
"Veneer & High Esthetic Cases"

888-786-2177

www.glidewell-lab.com



GLIDEWELL
LABORATORIES

Serving Dentists Since 1970

What is
From Page 5

everyone on a steady, but not overwhelming, pace while allowing the practice to meet daily production goals.

Improve communication

Look at any successful practice and you will see an office that communicates extremely well. Communication affects every aspect of the patient experience, ranging from scheduling an appointment to case acceptance. For the dentist, the first step in improving communication is cultivating clear, positive and well-understood interactions with team members.

Throughout the day, the dentist has opportunities to coach team members, respond to questions and concerns, and motivate the team. Dentists should be providing positive feedback to team members throughout the day. Don't wait to recognize good performance until a staff meeting. When team members perform well, tell them that day.

Clear communication and supportive coaching become more critical as the practice grows. The dentist needs to inspire team members, individually and collectively, to achieve the highest levels of success.

Become a better leader

A mismanaged practice is a stressful place to work. Efficiency, productivity and communication are all

reflections of your leadership skills. Therefore, dentists who work to improve their leadership skills can measurably reduce the stress in their practices.

Good leaders have learned to work through their teams — not around them. The most successful dentists have figured out how to delegate responsibilities to team members. Delegating responsibility accomplishes two things: dentists reduce their stress and team members gain a sense of empowerment. Staff members *want* to feel they play an important part in practice success.

Leading by example is another facet of leadership. Team members learn how to act by watching the leader's behavior. A dentist who is positive and motivational inspires

team members to act in the same way. Lead the way and your team will be sure to follow!

Conclusion

Chronic stress indicates that some vital elements of leadership are underdeveloped on the doctor's part. Dentists can remedy this situation by taking more proactive measures as leaders of their practices. Team members are relying on the doctor to set the tone, solve problems and identify strategies to get control of problem areas that are sources of stress.

Yet paradoxically, dentists who are working to become good leaders learn to empower their teams as much as possible. Dentists become better leaders by tapping into team member's insights, abilities and skills. These five steps can help dentists become better leaders, build better teams and achieve total success.

Dental Tribune readers interested in learning more about how to survive and thrive in today's economy are entitled to receive a 20 percent courtesy on the Levin Group Total Practice Success™ Seminar held on November 20–21 in Chicago. To register and receive your discount, call (888) 973-0000 and mention "Dental Tribune" or e-mail customerservice@levingroup.com with "Dental Tribune" in the subject line.

AD



Well connected.

The CAMLOG® Implant System

Quality. Reliability. Simplicity.

Whether you are new to implant dentistry or have been placing implants for years, you will appreciate the easy handling and superior esthetic results possible with CAMLOG® dental implants.

- Precision engineering
- Simple and safe surgical placement
- User-friendly system makes restoration simple

Contact your Henry Schein Dental Sales Consultant to learn more about the CAMLOG® Implant System, or call CAMLOG directly at 1-877-537-8862.

www.camlogimplants.com



CAMLOG USA
1-877-537-8862
www.camlogimplants.com

camlog™ | HENRY SCHEIN®
BIOTECHNOLOGIES

About the author



Dr. Roger P. Levin is founder and chief executive officer of Levin Group, Inc., a leading dental practice management consulting firm that provides a comprehensive suite of lifetime services to its clients and partners. Since 1985, Levin Group has embraced one single mission — to improve the lives of dentists.

For more than 20 years, Levin Group has helped thousands of general dentists and specialists increase their satisfaction with practicing dentistry. Levin Group may be reached at (888) 973-0000 and customerservice@levingroup.com.

Minimally invasive dentistry in rapid fire fashion



Don't miss Dr. Jesse's and Dr. Kaminer's lecture at the Dental Tribune Symposia during the Greater N.Y. Dental Meeting at 3–4 p.m. on Dec. 1.

Topics to be discussed include the following: caries management by risk assessment; current concepts in cariology; minimally invasive endodontics; bonded fiber posts; dental lasers; minimally invasive periodontics; current advances in tooth whitening; bonding agents: separating the truth from the hype; and much more. This program will introduce concepts that will change the way you practice forever.

Earn C.E. credits! Attendance is free for all GNYDM visitors!

For more information and registration, please contact Julia Wehkamp: j.wehkamp@dtamerica.com.



Using 3-D X-ray imaging and planning to increase patient treatment acceptance



Catch Dr. Patel's lecture at the Dental Tribune Symposia during the Greater N.Y. Dental Meeting at 10 a.m.–1 p.m. on Dec. 1.

Dr. Patel will share a practical perspective of cone beam technology and its multiple uses in "real world" private practice. He will shed light on what the future has to offer and give insight into the impact CBCT technology can have from a business standpoint — return on investment (ROI)! By the end of the presentation, attendees should:

- ▶ Understand how 3-D technology can benefit the modern dental practice.
- ▶ Learn how state-of-the-art 3-D digital dentistry is being done today.
- ▶ Acquire the tools for implementing 3-D X-ray imaging and software in their practice.

Earn C.E. credits! Attendance is free for all GNYDM visitors!

For more information and registration, please contact Julia Wehkamp: j.wehkamp@dtamerica.com.



Bien-Air's Optima MX INT leads the way

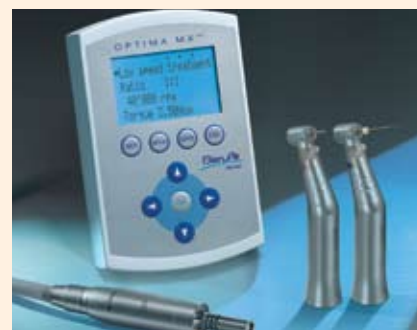Upgrade to the only system that can be seamlessly integrated into your current system — the Optima MX INT — and experience electrical operation of the highest order. Programmed with 40 preset memory settings, the sophisticated Optima INT grants you all the high speed, low speed and endo capabilities you'll ever need with just two attachments. Also, this powerful system has a user interface that is easy to use and also able to control three motors.

The Optima MX INT uses Bien-Air's Micromotor MX, which was the leader of the pack in an independent assessment by the ADA Professional Product Review (Vol. 2, Issue 1, Winter 2006). This review confirmed that a Micromotor MX Series motor has the highest torque (6 Ncm), the

most power, and the most broad rpm range that runs at the exact speeds it is set at.

The control unit utilizes a three-phased voltage delivery that provides the constant torque necessary to support high and slow speed application with only one attachment. This feature directly translates into savings, efficiency and precision. When taken together, the proper torque and an accurate display of slow-speed rpm help decrease the risk of snapping a file in a canal during endo procedures.

In addition, the Micromotor MX is the quietest motor and offers the best light transmission. (If you would like to read a full description of the tests conducted and methods used, please visit the ADA Web site at www.ada.org/goto/ppr.)



[org/goto/ppr](http://www.ada.org/goto/ppr).)

Upgrade to the Optima MX int for \$1,950 along with the trade-in of your system from any manufacturer (MSRP is \$3,260, so that's a 40% savings!), and you'll get the peace of mind that comes with a three-year warranty.

To learn more about Bien-Air products or for a free in-office demo, call (800) 433-2436. You can also visit us online at www.bien-air.com.

AD

+ Bien-Air 2008 4th Quarter Specials

SPECIAL OFFER N°1



Buy 1 Optima MX and 2 attachments 1:5 L and get 1 FO attachment 1:1 FREE

Retail Price \$7,157
Package Price \$4,291
SAVE \$2,866

SPECIAL OFFER N°2



Buy 1 Digipad MX int and 2 attachments 1:5 L and get 1 FO attachment 1:1 FREE

Retail Price \$7,157
Package Price \$4,291
SAVE \$2,866

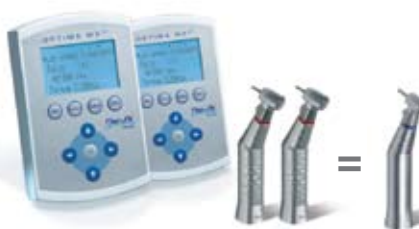SPECIAL OFFER N°3



Buy 2 Optima MX and 2 attachments 1:5 L and get 2 FO attachment 1:1 FREE

Retail Price \$11,686
Package Price \$6,611
SAVE \$5,075

SPECIAL OFFER N°4



Buy 2 Digipad MX int and 2 attachments 1:5 L and get 2 FO attachment 1:1 FREE

Retail Price \$11,686
Package Price \$6,611
SAVE \$5,075

HIGHSPEED AIR SPECIAL



Buy 3 BORA and get 1 FREE

Retail Price \$5,816
Package Price \$3,207
SAVE \$2,609

ELECTRIC ATTACHMENTS



Buy 2 1:5L and 2 1:1L attachments, Get 1 1:5L attachment FREE

Retail Price \$6,480
Package Price \$3,690
SAVE \$2,790

Promotion valid for orders taken at trade shows and must be purchased through authorized distributors only. Offers are valid from October 1, 2008 to December 31, 2008

For more information on products, please visit our website: www.bienair.com

Bien-Air USA, Inc. Tel. 1-800-433-BIEN
Irvine CA 92606 Fax 949-477-6051



REF2500255 EDITION: 06.08

‘Those troublesome occlusal shots’

By Martin B. Goldstein DMD

The following e-mail is typical of the trials and tribulations that doctors and staff encounter when attempting to add digital occlusal shots to their new patient exam protocols.

“My staff and I are still having problems with getting decent occlusal pictures. We even bought the newer occlusalmirror with an attached handle and the lip lifter. We already had mirrors, both large and small, without handles. It seems to be a problem with getting a good clear picture back to the second molars, and of course, the lower is even harder than the

upper. We blow air on the mirror to clear the fog. Perhaps the problem is that the patient is not reclined back in the chair enough, or is not opening wide enough. Should we be taking the picture from in front of the patient, or from behind? We take it from the front. Gagging is a problem all the time. I need some advice.”

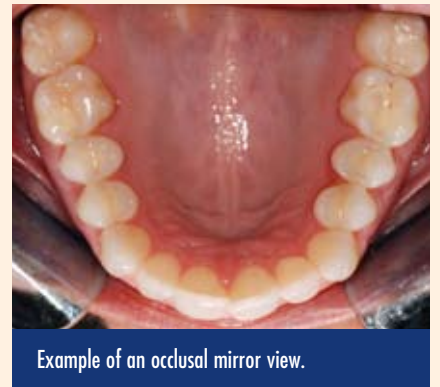Occlusal images may indeed be tough to get. Assuming your camera is properly set up, the following tips might help regardless of whether you are using auto or manual focus to take your occlusal shots. (Note: manual focus might be more predictable with respect to magnification and illumination, but auto-focus will

certainly speed up the process).

It’s important to retract the cheeks when taking occlusal shots. Wire retractors may aid the cause as mirrors can slide through them rather than bump into them as they do with the solid plastic retractors.

It helps to pull the retractors up and out when shooting the maxilla and down and out when shooting the mandible. This 45 degree tug will expose the second molars.

The patient is usually reclined to about 30 degrees with the photographer shooting from the front of the patient. (If you are shooting with manual focus, use 1:3 magnification.)



Example of an occlusal mirror view.

We often ask the patient to move his or her tongue behind the mirror when taking the occlusal shots. This often helps to clear the field.

Air is essential to defog the mirror and a bit of indirect lighting from the overhead light will help the camera to lock in focus.

Sounds crazy, but the wide end of the occlusal mirror goes in first, not the small end. (You’d be surprised at what I see at my hands-on seminars.)

Attempt to get the image as close to a perpendicular to the occlusal plane as possible; the bigger the mouth, the easier it is.

If I can’t get a good occlusal shot, I’ll take quadrant shots to make up for this using a smaller mirror.

Finally, realize that mirrored shots taken like this will need to be “mirror-flipped” vertically with image editing software to properly orient the arch prior to presentation.

I hope these tips are helpful. Practice makes perfect.

AD

MDI




Instant Gratification for Denture Patients

IMTEC Mini Dental Implant System

IMTEC’s Sendax MDI® Implant System offers a revolutionary one-hour, one-stage solution for long-term denture stabilization. This immediate loading mini dental implant system utilizes a patented, flapless placement protocol and works with the patient’s existing denture. The versatile MDI implant family includes the 1.8 and 2.1mm implants with standard thread design and the 2.4mm MAX thread for softer bone.


MDI Hybrid Implant
2.9mm Implant System

This one-piece implant enables placement with a procedure much like the Sendax MDI placement protocol, using MDI instrumentation, making it the most minimally invasive implant of its size.





2.1mm Collared O-Ball



Train Now!

IMTEC Seminar Schedule

November 15 - San Francisco, CA
November 15 - Austin, TX
December 5 - New York, NY
December 13 - Chicago, IL

MDI University Training

University of Oklahoma - November 8 & 9
Oklahoma City, OK

Use Code: DTUS1008

Call 1-800-879-9799 for your free technique CD or visit www.imtec.com/implants

IMTEC
a 3M Company



About the author



Dr. Martin Goldstein, a member of the International Academy of Dento-Facial Esthetics, practices general dentistry in Wolcott, Conn. Noted as a Dentistry Today C.E. Leader for the last five years, he lectures and writes extensively concerning cosmetics and the integration of digital photography into the general practice. A regular contributing editor for Dentistry Today, he has also authored numerous articles for multiple dental periodicals both in the United States and abroad. He can be contacted at martyg924@cox.net. His current speaking schedule can be found at www.drgoldsteinspeaks.com.

The importance of gingival health in a functional cosmetic case

By Martha Cortes

Complete dentistry is the esthetic and occlusal harmonization of the teeth with the gingiva, lips and face. As dentists, we can directly affect the esthetics of the teeth and gingiva. However, we can also indirectly affect the lips and face by how we design teeth to sit in the oral cavity.

It is paramount in an esthetic case to have healthy gum tissue that enhances the beauty of a full smile makeover. The best, quickest, healthiest and most profitable way of treating gum disease is by laser therapy.

Laser Assisted New Attachment Procedure™ (LANAP) is the standard of care for periodontal laser therapy and beyond that of conventional treatment, which amputates, leading to results that can be less than desirable. LANAP is a patented soft-tissue technique specifically utilizing the Periolase® MVP-7 Nd:YAG (1064 nm wavelength) laser (Millennium Dental Technologies, Inc.) with the aim of regeneration rather than traditional resection of the gum tissue, which is done solely for pocket maintenance.

The patient, a woman in her early 60s, came to my office because she was having problems with a bridge (lower left) that had recently been replaced; she was unable to chew well. During the discussion she revealed that she was also having problems on the lower right, indicating that the problem was not local but one that involved the bite.

On further examination, it was revealed that she not only had occlusal problems, but she also had moderate periodontitis throughout with bone loss especially impacting the lower anteriors. The patient had worn away her teeth and, as a result, suffered from severe malocclusion.

She had large diastemas between the upper and lower centrals with little occlusal guidance. Her temporal mandibular joints demonstrated hypermobility while opening and closing. The patient also had ill-fitting porcelain fused to metal crowns on teeth #5-5 and #51, #50, #12, #21 with metal exposure and a new zirconium bridge with flat occlusion on teeth #18-20. All prosthesis had poor color matching and flat occlusion.

The periodontitis and bone loss were partially due to a traumatic bite that improperly distributed the occlusal forces laterally rather than perpendicularly so that the loading forces were forcing the lower ante-

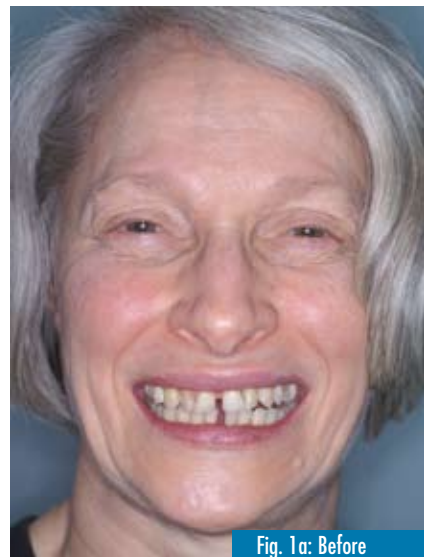

Fig. 1a: Before

riors to splay.

In order to inhibit the mechanical progression of the periodontitis and bone loss, and prevent the teeth from splaying further, it was decided to completely restore the teeth to a fully functional platform. The patient was at first intimidated by the idea of a complete smile makeover, and yet she was at the same time ready for this life-changing event. The patient understood that the esthetics would be built functionally so that the occlusion, teeth, arches and periodontium would support each other and thereby help keep the entire oral cavity healthy.

Having a functionally beautiful smile not only affects a patient's self-esteem, it also has an effect on the health of the head, neck and body as the patient tends to have better posture and better body integration, because aligned jaws might proprioceptively affect the body in space. Although the patient's main concern was dental health, the added benefit of gorgeous esthetics appealed to her greatly.

Due to her severe malocclusion, the patient's habitual centric bite could not be used as the guide for her smile-makeover. The proper functional height for the patient's teeth needed to be found and established. The patient had ground down her posterior teeth and much of the forces of mastication were pathologically loading on the lower anteriors, causing them to splay and repetitively injuring the gingiva.

LANAP's uniqueness allows for the prepping and placing of restorations without having to wait an inordinate amount of time for the gums to heal as the gingiva is not cut and sutured; therefore, healing is quicker and less traumatic and esthetically more pleasing.

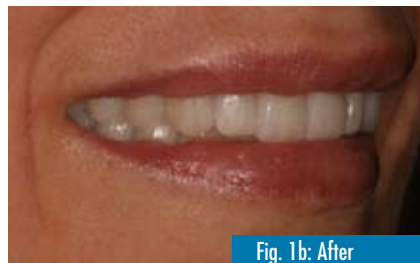

Fig. 1b: After

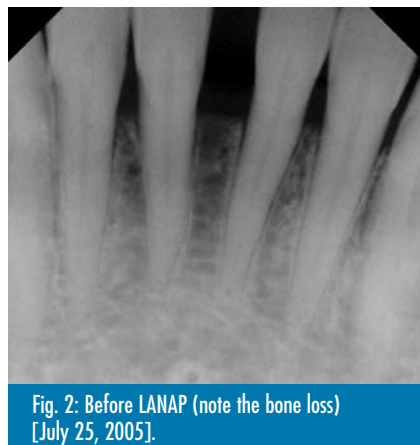

Fig. 2: Before LANAP (note the bone loss) [July 25, 2005].

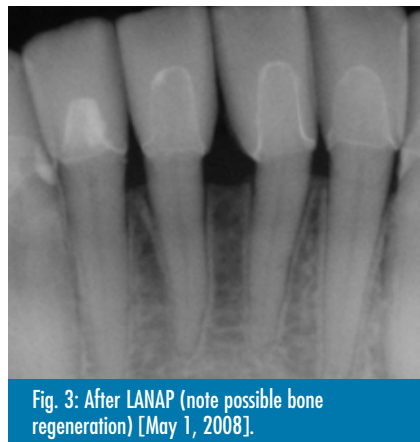


Fig. 3: After LANAP (note possible bone regeneration) [May 1, 2008].

The patient was neuromuscularly tested using the K7 Evaluation System (Myotronics) in order to determine where the bite ought to be before restoring. The patient received a fixed orthotic/occlusal device that was worn for approximately six months in order to relax the pathologic forces, arrive at the correct vertical dimension for the patient and gradually retrain the neuromuscular defects. The splint would also help to abate any negative forces affecting the gingiva.

The patient would be restored with an eye toward the correct Shim-bashi measurement and with golden proportion principles in mind. A myocentric position is derived from the orthotic, and the use of a transcutaneous electrical nerve stimulator (TENS) that erases the habitual bite and helps to create healthy neuromuscular conditions, which inhibits its occlusal breakdown.

She was tested again a few months later with the K7 to evaluate the temporal mandibular/neuromuscular complex with the occlusal device determining the health of the new vertical on the entire system. At approximately four months after the

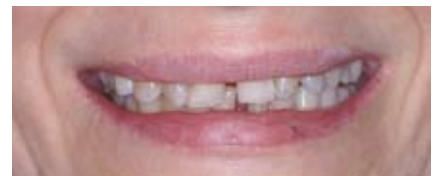

Fig. 4: Maloccluded smile with multiple diastemas.

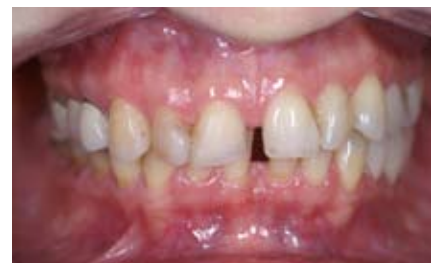

Fig. 5: Pre-op intraoral view: note the severe overbite and canted maxilla.

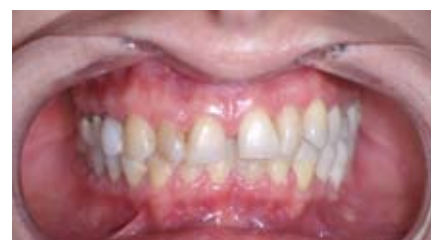

Fig. 6: Phase 1 with lower orthotic.

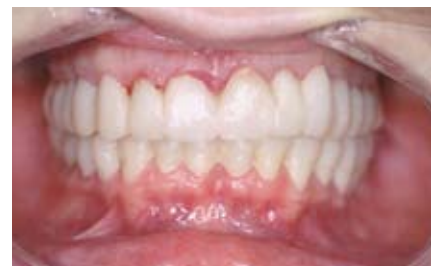

Fig. 7: Phase 2 with lower orthotic and provisionals on the uppers.

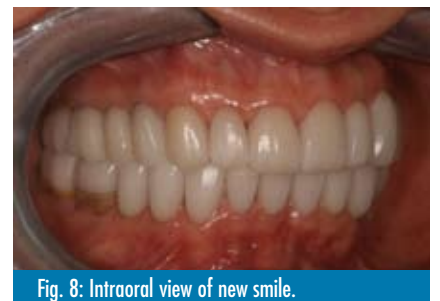

Fig. 8: Intraoral view of new smile.

mandibular trajectory was found, the upper teeth were ideally leveled with the provisionals to correct the maxillary cant by proportioning the anteriors canine to canine and harmonizing them with the posterior curve of Wilson.

The patient received LANAP on all quadrants using the Periolase MVP-7 laser for pockets that were between 4-7 mm, approximately three weeks before the orthotic was fixed to the lower arch. Had this been done conventionally, the patient would have needed to wait at least three months or more for the tissue to heal. Dental lasers are site specific, biostimulative, allow for excellent hemostasis

See The importance, Page 2